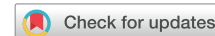

Twiddler syndrome and concomitant pocket infection: Double trouble



Michael P. Lavelle, MD, Jessica A. Hennessey, MD, PhD, Geoffrey A. Rubin, MD, Hiram Yarmohammadi, MD, MPH, FHRS

From the Division of Cardiology, Department of Medicine, Columbia University Vagelos College of Physicians and Surgeons, New York, New York.

Introduction

Twiddler syndrome is a well-known, though rare, complication of permanent pacemaker or implantable cardioverter-defibrillator (ICD) implantation. It was first described in 1968 by Bayliss and colleagues^{1,2} in an elderly woman who had twisted her device, which resulted in lead dislodgement and stimulation of the phrenic nerve and brachial plexus. This is an important clinical entity to be able to identify and treat rapidly. We describe a case of Twiddler syndrome in a patient who received a dual-chamber ICD for secondary prevention of ventricular fibrillation. He also developed a pocket infection, which complicated the management and required the input of an interdisciplinary team.

The objective of this case report is to identify Twiddler syndrome and how to prevent recurrence of Twiddler syndrome, and to identify the important aspects of the presentation.

Case report

A 64-year-old man with a history of diabetes mellitus, ischemic cardiomyopathy with end-stage heart failure treated with a HeartMate II left ventricular assist device (LVAD) 4 years ago as destination therapy, and ventricular fibrillation status post dual-chamber ICD presents to the electrophysiology device clinic complaining of twitching in his left arm and chest. Two months prior to the presentation, the patient presented to the hospital after being found unresponsive at home. Upon arrival to the hospital, his rhythm was ventricular fibrillation, which was terminated to normal sinus rhythm by defibrillation and intravenous amiodarone. He was subsequently admitted to the intensive care unit and was

KEY TEACHING POINTS

- Twiddler syndrome is a rare entity, but always needs to be considered with apparent device malfunction.
- There are many different patient- and device-related factors that can result in dislodgement of an implantable device.
- Management of Twiddler syndrome requires careful consideration of the specific etiology of the syndrome to best prevent further episodes.

found to have a small abscess and driveline infection. His infection was managed with incision and drainage and cefpodoxime to target the *Proteus* species cultured from the wound. He had complete neurologic recovery from his cardiac arrest and, after adequate treatment of his infection, had a dual-chamber ICD placed in a subcutaneous pocket for secondary prevention. The patient previously had episodes of sinus bradycardia and possibly sinus node dysfunction, which was the reason a dual-chamber device was placed. He was ultimately discharged home on indefinite cefpodoxime, as he had previous driveline infections.

Upon his arrival to the device clinic for routine follow-up, the patient's device was interrogated. Interrogation showed that the device was neither sensing intracardiac signals nor capturing myocardium in the atrial and ventricular leads. Exam was notable for visible left pectoral twitching, as well as mild fluctuance of the pocket without erythema or drainage, and he was afebrile. Laboratory data included a white blood cell count of $7.9 \times 10^3/\mu\text{L}$ and was otherwise unremarkable. The patient was referred for a chest radiograph, which showed dislodgement of the atrial and ventricular leads with the leads wrapped around the generator (Figure 1). It was also noted that the generator had slightly rotated from its original postprocedural position. Upon further review of the original interrogation, there were clear points in time when the device suddenly transitioned to 100% V pacing and then to 100% A pacing (Figure 2). These events represented when each lead became dislodged and

KEYWORDS Abscess; Adult; Defibrillators; Foreign-body migration; implantable; prevention & control
(Heart Rhythm Case Reports 2021;7:357–360)

Funding: This research did not receive any specific grant from funding agencies in the public, commercial, or not-for-profit sectors. **Conflict of Interest:** The authors have no conflict of interest to disclose. **Address reprint requests and correspondence:** Dr Hiram Yarmohammadi, 177 Fort Washington Ave, New York, NY 10032. E-mail address: Hy2567@cumc.columbia.edu.

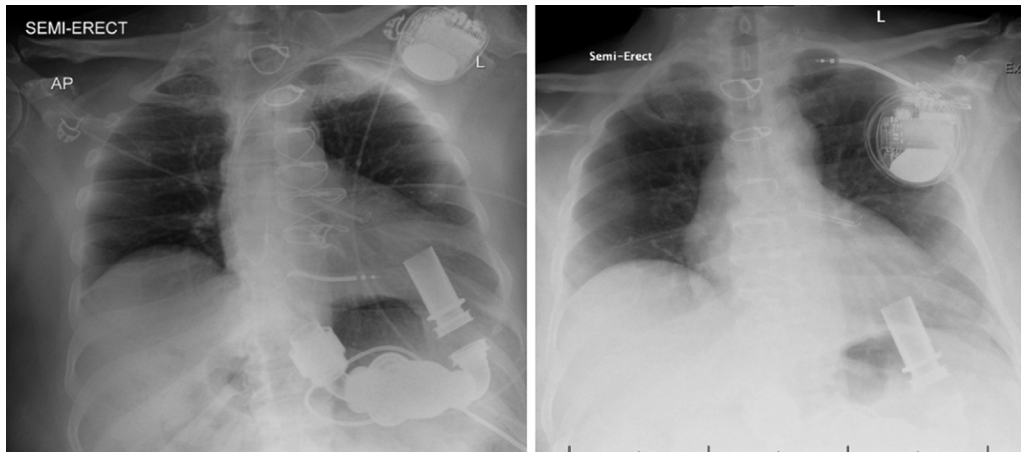


Figure 1 Chest radiograph immediately after implantation (left) and obtained on this presentation (right) showing dislodgement of atrial and ventricular lead. Note that in the right image the atrial lead is entirely extravascular and the generator is slightly more counterclockwise rotated.

could no longer sense cardiac signals. It was also noted that the device detected “atrial fibrillation” after the leads had become dislodged, which is suspected to be related to pectoral muscle activity (Figure 2). There is a significant increase in patient activity at this time, which may be due to free movement of the device within the pocket that the accelerometer detected as patient movement (Figure 2).

The device was placed in ODO mode and tachy-therapies were disabled. The patient was taken back to the lab with plan for extraction and possible reimplantation of a new device. However, upon opening the pocket, purulent fluid discharged and the leads were visibly coiled (Figure 3). The device was then explanted under the impression of a pocket infection and tissue cultures were sent. A Penrose drain was placed and the wound was left open to allow drainage. The patient had been maintained on cefpodoxime during his hospitalization for his previous driveline infection. In the presence of a new infection, the antibiotic treatment was broadened to intravenous vancomycin and cefepime pending the results of the culture. His drain was removed after 72 hours and the wound was closed using secondary closure method (the opening was approximated by steri-strips). Ultimately, cultures from the pocket and blood cultures all returned negative. After 1 week of intravenous antibiotics and in consultation with an infectious disease specialist, he was deemed safe for reimplantation and he underwent uncomplicated placement of a single-lead right-sided ICD. At this time, a single-lead device was chosen in place of a dual-chamber device, as he had no observed episodes of bradycardia and the overall risk of a second lead was outweighed by the benefits, given his infection and lead dislodgement. Implantation of a subcutaneous ICD was also considered owing to his infectious history. However, a transvenous device was pursued for 2 reasons. First, given the hemodynamic support provided by the LVAD, a transvenous device would allow for more aggressive attempts of antitachycardia pacing and possibly avoid a shock. Second, previous reports have shown potential interference of the sensing vectors of the subcutaneous ICD associated with the patient’s LVAD.¹ Following

placement of the new ICD, he was narrowed to oral amoxicillin–clavulanic acid and discharged home.

Discussion

Dislodgement of the leads of a cardiovascular implantable electronic device requires rapid identification and treatment, but also requires an understanding of the etiology. Over the years, there have been at least 3 distinct mechanisms described that have resulted in lead migration. Perhaps most well-known is the so-called Twiddler syndrome. In the initial description of the syndrome by Bayliss and colleagues,² a case was described of an elderly woman who had physically manipulated her generator, which resulted in rotation around the long axis of the device and subsequent dislodgement of the leads. She presented owing to stimulation of the phrenic nerve and brachial plexus, which caused pectoral and arm twitching, a frequent finding in Twiddler syndrome.² In our case, the patient’s ventricular lead had completely retracted within the pocket, while the atrial lead remained within the vasculature. Based upon the reported timing of his symptoms and review of the pacing output from his interrogation, his arm twitching was likely a result of direct stimulation of the pectoralis muscle rather than stimulation of a deeper nerve plexus.

Most commonly, this syndrome is caused by conscious or unconscious manipulation of the generator. However, this syndrome has also been described to occur in the absence of patient manipulation. In a case series of 3 patients, each one implanted with the St. Jude Fortify Assura ICD developed lead dislodgement without a clear history of “twiddling.”³ It was postulated to be the result of the peculiar shape of the generator, increasing the risk of its moving within the pocket. In our case, the patient was implanted with a Medtronic Evera device, which has not been speculated to be at increased risk of this syndrome. Further supporting the occurrence of this syndrome without a history of twiddling, Cooper and colleagues⁴ report a case of a young man with isolated retraction of the atrial lead of a dual-chamber ICD. In this case, there was no evidence of rotation of the generator within the pocket, and the isolated

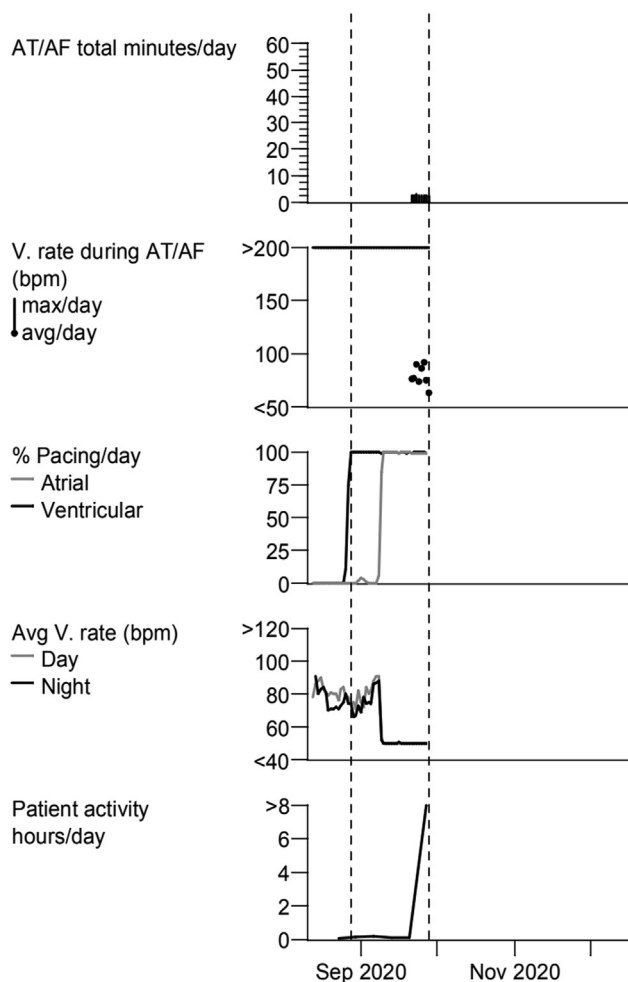


Figure 2 Interrogation upon presentation. There is an abrupt rise in the percentage of V pacing first, which likely is when the lead became dislodged. During this time the ventricular rate is tracking the atrial rate. Following this, the atrial lead also became dislodged, at which point the patient became 100% A-V paced at the backup rate of 50. When the atrial lead becomes dislodged, atrial fibrillation is detected, which is likely noise from pectoralis pacing. There is also an abrupt rise in his daily activity, which is possibly the result of rotation within the pocket or movement of the generator from pectoralis pacing.

retraction of the atrial lead made the typical scenario of conscious or unconscious device rotation an implausible etiology. It was postulated that natural friction forces within the pocket from muscle and subcutaneous tissue created a ratchet mechanism that resulted in isolated retraction of 1 lead. For our patient, this mechanism seems less likely, as the entire generator was visibly rotated and both leads were nearly fully retracted back into the pocket. Rather, a more recently described Reel syndrome was likely the cause of our patient's findings.⁵ This specific phenomenon, a variant of Twiddler syndrome, results from rotation of the pacemaker generator on the transverse axis rather than the long axis from either conscious or unconscious manipulation.⁶ Our patient adamantly denied any direct manipulation of his device. However, he did report that he frequently reached overhead while lying in bed to pull himself upwards. While he may not have physically manipulated his device, this repetitive

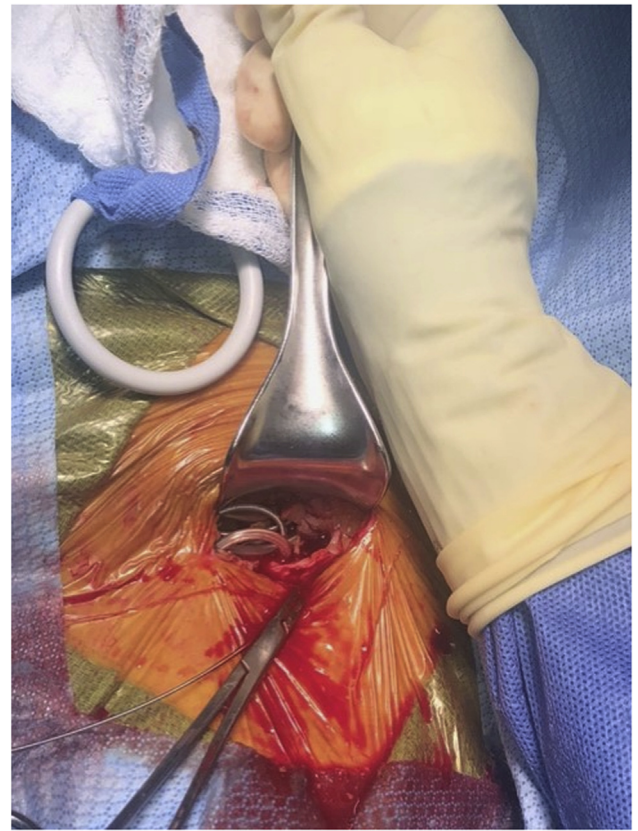


Figure 3 Visible coiling of the leads within the pocket.

overhead motion may have allowed for twisting of his generator and retraction of both atrial and ventricular leads. In general, ICDs are larger and heavier than small pacemakers and in aged soft tissue are more prone to migration. Thus, consideration of suturing both sides of the generator is recommended, especially if there is a risk for "twiddling" (eg, dementia or psychiatric illness). Additional procedural strategies that may prevent generator manipulation and lead retraction include subpectoral placement of the battery, avoidance of excessive subcutaneous tissue dissection, and secure and tight cinching of the suture ties around the lead sleeves connected to the underlying muscle. In this case, additional suturing of both sides of the device to the fascia in the subcutaneous pocket was performed to prevent rotation of the generator and recurrence of the syndrome.

The current case is unique in that he was also found to have an infection of his pocket upon device extraction. It is possible that the presence of infection allowed the generator to move more freely within the pocket and increase the risk for his findings. Our patient had been treated with chronic antibiotics for his prior driveline infection, which may explain the lack of obvious signs of infection on exam and negative cultures. In a retrospective study of patients with Twiddler syndrome who underwent device reimplantation, the use of an antimicrobial pouch/envelope was associated with no recurrence, compared to a 50% recurrence of "retwiddling" without the pouch.⁶ The exact mechanism is unclear, though

prevention of infection may play a role. As a result of our patient's infection, contralateral implantation was necessary in addition to considering precautions to prevent future device dislodgement. A TYRX™ absorbable antibacterial envelope (Medtronic plc, Mounds View, MN) was also placed in the pocket with the device to limit risk of reinfection.

Conclusion

Lead dislodgment owing to Twiddler, ratchet, or Reel syndrome is a rare but important entity and should be considered whenever there is malfunction of sensing or capturing of a cardiovascular implantable electronic device. Safe reimplantation of a device requires careful consideration of a many different patient factors, as highlighted by this case.

References

1. López-Gil M, Fontenla A, Delgado JF, Rodríguez-Muñoz D. Subcutaneous implantable cardioverter defibrillators in patients with left ventricular assist devices: case report and comprehensive review. *Eur Heart J Case Rep* 2019; 3:ytz057.
2. Bayliss CE, Beanlands DS, Baird RJ. The pacemaker-twiddler's syndrome: a new complication of implantable transvenous pacemakers. *Can Med Assoc J* 1968; 99:371–373.
3. Gul EE, Boles U, Haseeb S, et al. Spontaneous Twiddler's syndrome: the importance of the device shape. *Pacing Clin Electrophysiol* 2016;40:326–329.
4. Cooper JM, Mountantonakis S, Robinson MR. Removing the twiddling stigma: spontaneous lead retraction without patient manipulation. *Europace* 2010; 12:1347–1348.
5. Munawar M, Munawar D, Basalamah F, Pambudi J. Reel syndrome: a variant form of Twiddler's syndrome. *J Arrhythmia* 2011;27:338–342.
6. Osoro M, Lorson W, Hirsh JB, Mahlow WJ. Use of an antimicrobial pouch/envelope in the treatment of Twiddler's syndrome. *Pacing Clin Electrophysiol* 2018; 41:136–142.