

# Foreign body esophagus: Six years of silence

SAGE Open Medical Case Reports  
Volume 8: 1–3  
© The Author(s) 2020  
Article reuse guidelines:  
sagepub.com/journals-permissions  
DOI: 10.1177/2050313X20944322  
journals.sagepub.com/home/sco



Sudha Shahi<sup>1</sup> , Tika Ram Bhandari<sup>2</sup>, Prakash Bahadur Thapa<sup>1</sup>,  
Deependra Shrestha<sup>1</sup> and Kiran Shrestha<sup>3</sup>

## Abstract

Foreign body esophagus remains one of the common medical emergencies which may lead to significant morbidity and mortality. Sharp objects, batteries, and elderly with foreign body esophagus should be treated with emergent removal owing to the complications that might ensue. Endoscopic removal is the preferred choice of treatment but for large foreign body, sharp foreign body, and so on, rigid esophagoscopy removal might be more preferable. Foreign body esophagus though an obvious situation might at times be missed. It is important to make an early definitive diagnosis. We report a unique case of missed foreign body (denture) esophagus despite the obvious signs and symptoms. Definitive diagnosis was made only after 6 years due to the lack of definitive diagnostic procedures and expertise. The foreign body was impacted in the mucosal wall of the esophagus requiring Gastric resection and anastomosis (with McKeown procedure). With this we have tried to highlight the pitfalls in the diagnosis and management of foreign body esophagus. We report a case of a 55-year-old female who presented to the Emergency Room with history of progressive dysphagia and odynophagia for 6 years which was aggravated for the past 6 months. A radiological diagnosis was made. It was followed by a failed attempt of endoscopic removal which warranted the surgical removal of the foreign body.

## Keywords

Missed foreign body esophagus, esophageal perforation, complications, gastric resection and anastomosis

Date received: 9 January 2020; accepted: 29 June 2020

## Introduction

Foreign body (FB) esophagus remains one of the common medical emergencies which may lead to significant morbidity and mortality.<sup>1</sup> It is common among pediatric age group, elderly, prisoners, and patients with psychiatric illness and mental retardation. Most of the cases of FB esophagus would pass spontaneously but those that require intervention should however, be treated as soon as possible. Sharp objects, batteries, and elderly with FB esophagus should be treated with emergent removal owing to the complications that might ensue. Endoscopic removal is the preferred choice of treatment but for large FB, sharp FB, and so on, rigid esophagoscopy removal might be more preferable.<sup>2</sup> Plain radiographs are the first line of investigation and diagnostic in most of the cases. However, other modalities of diagnosis like upper gastrointestinal (GI) endoscopy and computed tomography (CT) scan chest and abdomen are required in cases where plain radiographs fail to make a definitive diagnosis. Very few cases of surgical intervention have been reported. Surgical approach usually is considered in cases where endoscopic removal fails.<sup>3</sup> Similar was the case in our patient. It took 6 years for the patient to get the proper diagnosis and

surgical management done. Most important of all, she adds up to those very few percentage of people (<1%) that undergo surgical intervention.

## Case report

A 55-year-old female presented to the Emergency Room (ER) with progressive dysphagia for 6 years. It was getting worse for the past 6 months. She also gave a history of accidental swallowing of denture 6 years back. With the complaints of progressive dysphagia, she had been visiting the primary health care hospitals on a regular basis. According to the patient, she had

<sup>1</sup>Department of Otorhinolaryngology Head and Neck Surgery, Bir Hospital, National Academy of Medical Sciences, Kathmandu, Nepal

<sup>2</sup>Department of General Surgery, People's Dental College and Hospital, Kathmandu, Nepal

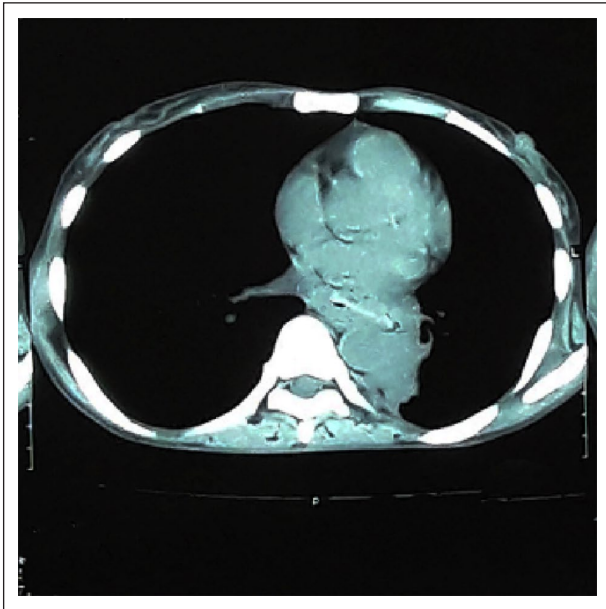
<sup>3</sup>Department of Cardiothoracic and Vascular Surgery, Bir Hospital, National Academy of Medical Sciences, Kathmandu, Nepal

### Corresponding Author:

Sudha Shahi, Department of Otorhinolaryngology Head and Neck Surgery, Bir Hospital, National Academy of Medical Sciences, Kathmandu 00977AQ1, Nepal.

Email: sudashahi@gmail.com



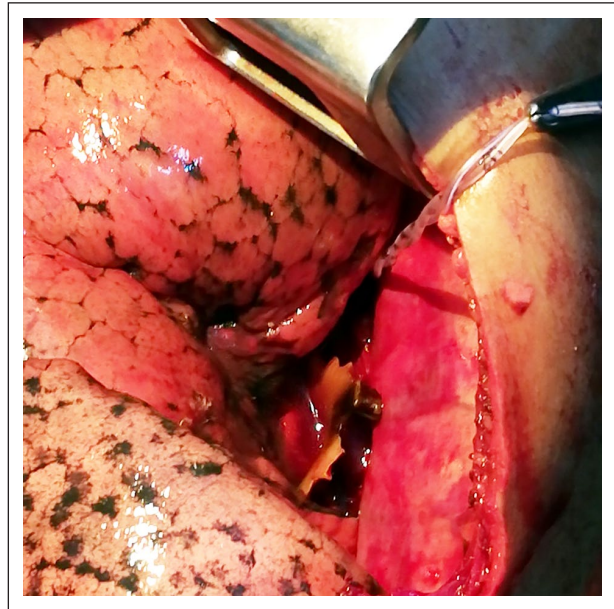


**Figure 1.** CT neck and chest showing hyperdense shadow impacted in the lower esophagus.

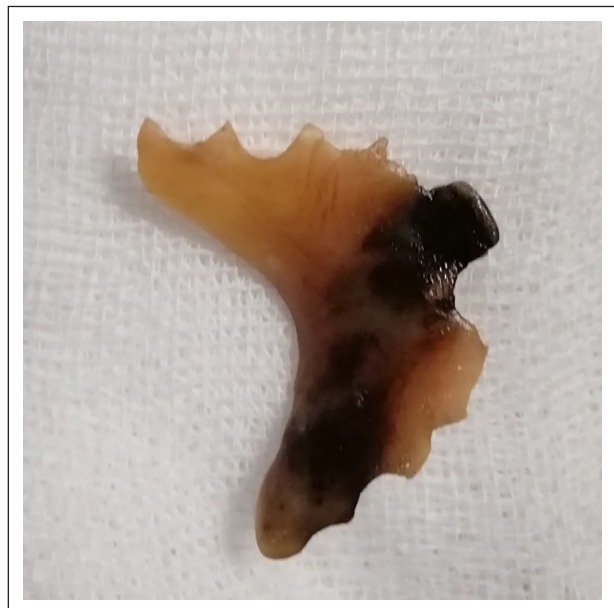undergone X-ray neck multiple times but none reaching to a definitive diagnosis. Every time she was prescribed some pain medications and antacids. Her condition was degrading so much so that in the past couple of months before the definitive diagnosis, she was only able to take semisolid diet. Thus, they finally visited a higher center in a nearby city where a definitive diagnosis of FB esophagus was made via an upper GI endoscopy. She was then referred to tertiary care center for further management. When she visited our hospital, she looked pale and cachexic but didn't complain of odynophagia, fever, or shortness of breath. Her vital signs were within normal range. Repeat X-ray soft tissue neck and chest was clear. Contrast enhanced scan of neck and chest was done which revealed irregular hyperdense structure with irregular linear projections lodged at the level of lower esophagus (Figure 1). Hence a FB (denture) esophagus was confirmed. Endoscopic removal was not successful. Discussion was done with Cardiothoracic and Vascular Surgery team and the final decision of surgical intervention was made. Ultimately, the patient underwent Gastric resection with resection anastomosis (McKeown procedure). Intraoperatively, a denture measuring around 10cm × 5cm was identified. It was embedded in the esophageal mucosa few centimeters above the Gastroesophageal junction (Figure 2). Post removal FB is shown in Figure 3. Feeding jejunostomy was placed. Postoperative period was uneventful. The patient was kept under IV antibiotics for 10 days and discharged. The feeding jejunostomy was removed after 6 weeks with no further complications.

## Discussion

With an annual incidence of 11 per 100,000 persons in the United States, FB still accounts for one of the common medical emergencies. It is more common among children and



**Figure 2.** Intraoperative removal of foreign body (denture) esophagus.



**Figure 3.** Foreign body esophagus (denture) post removal.

elderly followed by people with mental or neurological disorders. Studies have shown that food bolus, bones pieces, and dentures (4%–18%) were found more common in elderly and coins and toys more in children.<sup>2</sup> The cause of FB impaction in adult population has been found to be luminal narrowing of esophagus by webs, rings, strictures, tumors, achalasia, and esophagitis. In children, immature oropharyngeal coordination has been suggested.<sup>4</sup>

In elderly people, removal of impacted dental prosthesis can be a challenging problem. Delay in diagnosis and removal can lead to significant morbidity and mortality. The metal clasps or

retaining wires in the dentures predispose them to impaction when ingested.<sup>5</sup> Sharp foreign bodies when ingested may cause mucosal edema leading to airway compression, mucosal ulceration, inflammation, abscess, mediastinitis, empyema, perforation, FB migration into adjacent structures, fistula, and so on.<sup>2</sup>

Plain radiographs are diagnostic in most of the cases; however, in cases where plain radiographs are not sufficient, upper GI endoscopy and CT scan can add some value like in our case.<sup>6</sup>

Although majority of the foreign bodies are found to pass spontaneously without need of any intervention, every case should be treated as a medical emergency owing to the number of complications. Thus, the mainstay of management is early diagnosis and removal of the FB. Prior to 1947, rigid esophagoscope was the one routinely used. In 1966, removal of FB by Foleys catheter was reported by Richardson. Flexible esophagoscopy became famous by 1970s and 1980s.<sup>7</sup> Very few cases of surgical intervention have been reported. Surgical approach usually is considered in cases where endoscopic removal fails with few deciding factors like age > 70 years, foreign bodies in upper esophagus, maximal diameter of FB > 30 mm, and the time of presentation > 2 days.<sup>3,8</sup> In our case, thoracotomy and anastomosis surgery with gastric resection was performed due to failure of flexible endoscopy. Intraoperatively, a denture measuring 10 cm × 5 cm was removed from lower esophagus (Figure 3). However, there were no postoperative complications. Feeding jejunostomy was placed in situ which was removed 6 weeks later.

## Conclusion

FB esophagus is a common condition. It is more commonly seen in elderly and pediatric age group. No active intervention is required in majority of the cases. However, in certain percentage, surgical removal is required. Complications are rare but possible like in our case where the FB if goes unnoticed can migrate out of the lumen causing complications. So a proper diagnosis and early intervention must be done.

## Declaration of conflicting interests

The author(s) declared no potential conflicts of interest with respect to the research, authorship, and/or publication of this article.

## Funding

The author(s) received no financial support for the research, authorship, and/or publication of this article.

## Ethics approval

Our institution does not require ethical approval for reporting individual cases or case series.

## Informed consent

Written informed consent was obtained from the patient(s) for their anonymized information to be published in this article.

## ORCID iD

Sudha Shahi  <https://orcid.org/0000-0001-5080-5673>

## References

1. Triadafilopoulos G, Roorda A and Akiyama J. Update on foreign bodies in the esophagus: diagnosis and management. *Curr Gastroenterol Rep* 2013; 15(4): 317.
2. Boo SJ and Kim HU. [Esophageal foreign body: treatment and complications]. *Korean J Gastroenterol Taehan Sohwagi Hakhoe Chi* 2018; 72(1): 1–5.
3. Lee H-J, Kim H-S, Jeon J, et al. Endoscopic foreign body removal in the upper gastrointestinal tract: risk factors predicting conversion to surgery. *Surg Endosc* 2016; 30(1): 106–113.
4. Sung SH, Jeon SW, Son HS, et al. Factors predictive of risk for complications in patients with oesophageal foreign bodies. *Dig Liver Dis* 2011; 43: 632–635.
5. Stiles BM, Wilson WH, Bridges MA, et al. Denture esophageal impaction refractory to endoscopic removal in a psychiatric patient. *J Emerg Med* 2000; 18(3): 323–326.
6. Kim HU and Song HJ. Clinical characteristics of an esophageal fish bone foreign body from *Chromis notata*. *J Korean Med Sci* 2012; 27(10): 1208–1214.
7. Roffman E, Jalisi S, Hybels R, et al. Failed extraction of a sharp esophageal foreign body with a flexible endoscope: a case report and review of the literature. *Arch Otolaryngol Head Neck Surg* 2002; 128(9): 1096–1098.
8. Shreshtha D, Sikka K, Singh CA, et al. Foreign body esophagus: when endoscopic removal fails . . . *Indian J Otolaryngol Head Neck Surg* 2013; 65(4): 380–382.