

ORIGINAL ARTICLE

Postoperative pneumoperitoneum: guilty or not guilty?

Chang Ho Lee, Jong Hun Kim, Min Ro Lee

Department of Surgery, Chonbuk National University Medical School, Jeonju, Korea

Purpose: The aim of this study was to determine the incidence and duration of postoperative pneumoperitoneum on plain radiographs and to identify the radiologic findings associated with anastomotic leakage. **Methods:** A retrospective analysis was conducted on plain radiographs of 384 patients who underwent intra-abdominal anastomoses between March 2005 and December 2008. **Results:** Of the 384 patients, 93 patients (24.2%) had postoperative pneumoperitoneums. Of the 93 patients, 86 patients (92.5%) had physiologic pneumoperitoneums and 7 patients (7.5%) had pneumoperitoneums associated with anastomotic leakage. The initial air height was significantly greater in the leakage group than the physiologic air group (12.16 ± 7.65 mm vs. 7.71 ± 5.08 mm, $P = 0.04$). The area under the receiver operating characteristic curve of the initial height of free air for anastomotic leakage was 0.69 (95% confidence interval, 0.59 to 0.78). The best cut-off point was 11.7 mm. The height of the pneumoperitoneum increased with time in the leakage group. Ileus was significantly more prevalent in the leakage group than the physiologic air group ($P < 0.01$). **Conclusion:** Postoperative pneumoperitoneum is a common phenomenon after abdominal surgery. An initial air height > 11.7 mm, increasing air height over time, and the presence of ileus on plain radiographs suggest a high likelihood of anastomotic leakage.

Key Words: Pneumoperitoneum, Anastomotic leak, Plain radiographs

INTRODUCTION

A postoperative pneumoperitoneum (PP) following recent abdominal surgery may be a normal finding due to the air introduced during surgery or postoperative drains. However, a pneumoperitoneum on plain radiographs may also be an indicator of anastomotic leakage or gastrointestinal perforation [1-4]. When free air is visualized on plain radiographs, it may be unclear whether or not the free air represents a physiologic PP or progressive air development suggestive of infection or anastomotic leakage. Therefore, the utility of a PP in diagnosing a disruption in

the gastrointestinal tract during the early postoperative period is limited by the presence of physiologic free air from the laparotomy. Clinically, a variety of tools are used to diagnose postoperative peritonitis, including physical examinations and clinical signs, such as fever, abdominal pain, and distension. With respect to radiologic tools, abdominal computerized tomography (CT) is clearly superior to plain radiographs for the detection of free air and peritonitis in clinical settings [5]. However, abdominal CT may not be easily available whenever patients complain of abdominal symptoms. The costs of abdominal CT are relatively high and abdominal CT poses the additional risk of

Received October 10, 2011, Revised January 14, 2012, Accepted February 2, 2012

Correspondence to: Min Ro Lee
Department of Surgery, Chonbuk National University Medical School, San 2-20 Geumam-dong, Jeonju 561-180, Korea
Tel: +82-63-250-1570, Fax: +82-63-271-6197, E-mail: gsminro@chonbuk.ac.kr

© Journal of the Korean Surgical Society is an Open Access Journal. All articles are distributed under the terms of the Creative Commons Attribution Non-Commercial License (<http://creativecommons.org/licenses/by-nc/3.0/>) which permits unrestricted non-commercial use, distribution, and reproduction in any medium, provided the original work is properly cited.

radiation exposure. Alternatively, plain radiographs are simple, the cost is low, and plain radiographs are readily accessible. Therefore, plain radiographs are likely to be obtained first rather than abdominal CT in some insidious cases. Plain radiographs can also provide some information regarding the presence of free air, ileus, and bowel gas patterns. The aim of this study was to determine the incidence and duration of PP on plain radiographs and to identify the radiologic findings which may predict anastomotic leakage.

METHODS

After Institutional Review Board approval was obtained, we retrospectively identified 457 patients who underwent intra-abdominal anastomoses by two surgeons at Chonbuk National University Hospital between March 2005 and December 2008. Of the 457 patients, 384 patients had postoperative plain radiographs of the abdomen while standing erect, and in which the costovertebral angle was delineated. All radiographs were performed secondary to abdominal discomfort, including pain, distension, nausea, and vomiting. The initial radiograph was taken after the first appearance of the symptoms mentioned above. Follow-up radiographs were taken when the patients showed changes in symptoms, but we used radiographs taken on day 3, 6, 9, > 10 for our data analysis. Pneumoperitoneums were noted in 93 patients. These pa-

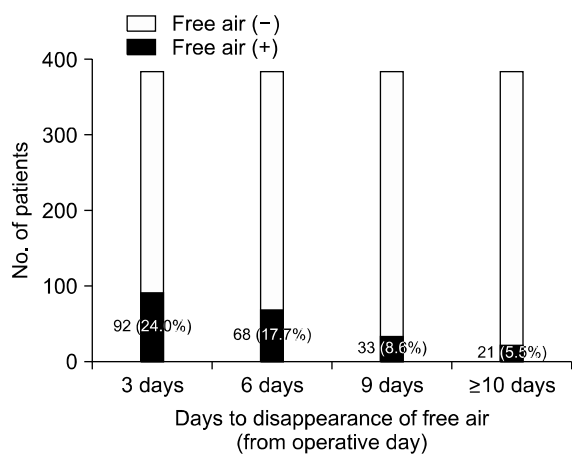


Fig. 1. Prevalence of free air (n = 384) with time.

tients were classified into physiologic air and anastomotic leakage groups to identify factors that could predict anastomotic leakage in patients with PP. The correlation was evaluated between the duration of physiologic air and clinical or radiologic variables, including patient age, weight, body mass index (BMI), operative time and type, duration and type of drainage, and initial height of air. The height of free air was defined as the longest distance from the superior to the inferior margin in right sub-diaphragmatic air. The data are expressed as the mean ± standard deviation or percentage according to the variable. To compare between the groups we used a standard t-test for continuous variables and a chi-square test or Fisher's exact test for categorical data. In addition, we performed receiver operating characteristic (ROC) analysis to calculate the area under the curve and identify the best cut-off point for initial air height to determine anastomotic leakage. P-values < 0.05 were considered statistically significant.

RESULTS

Of the 384 patients, 93 patients (24.2%) had PPs. Within this group, 86 patients (92.5%) were classified in the physiologic air group and 7 patients (7.5%) were classified in the anastomotic leakage group. Among the 7 anastomotic leakage patients, 6 underwent lower anterior resections for rectal cancer and 1 underwent a right hemi-colectomy for ascending colon cancer. The mean duration of physiologic air was 6.9 ± 2.4 days (range, 2 to 13 days). Among the 384 patients, 92 (24.0%), 68 (17.7%), 33 (8.6%), and 21

Table 1. Correlation of demographic and clinical parameters with the duration of physiologic air (n = 86)

Parameter	Correlation coefficient (r)	P-value
Age	-0.19	0.08
Weight	0.15	0.16
Body mass index	0.13	0.22
Operative time	0.20	0.06
Duration of drainage		
Tube drain (n = 13)	0.37	0.22
J-P drain (n = 73)	0.01	0.97
Initial height of air	-0.05	0.62

(5.5%) had visible sub-diaphragmatic free air on post-operative days 3, 6, 9, and >10, respectively (Fig. 1). In the physiologic group, there was no correlation between the time to disappearance of free air and our demographic and clinical parameters. These parameters included age, body weight, BMI, operative time, duration and type of drainage, and initial air height (Table 1). Comparison of the physiologic air group with the anastomotic leakage group yielded no measurable differences between age, gender, BMI, operative time, and open surgery versus laparoscopy. However, the initial air height was significantly higher in the leakage group than the physiologic air group (12.16 ± 7.65 mm vs. 7.71 ± 5.08 mm, $P = 0.04$). Additionally, the height of the pneumoperitoneum was increased over time in the leakage group, but decreased in the physiologic air group. Moreover, paralytic ileus, which was defined as a transient, functional impairment of intestinal motility and gaseous distension in radiographs occurring after surgery, was significantly more common in the leakage group than the physiologic air group ($P < 0.01$) (Table 2). The area under the ROC curve of the initial height of free air in patients with anastomotic leakage was 0.69 (95% confidence interval, 0.59 to 0.78). Using a cut-off point of 11.7 mm, we found that the sensitivity, specificity, positive predictive value, and negative predictive value were 57.1%, 83.7%, 22.2%, and 96.0%, respectively (Fig. 2).

DISCUSSION

Pneumoperitoneums are common following abdominal surgery, and can be detected by clinical examination [6] or imaging [7]. The standard method for confirmation of a pneumoperitoneum is plain radiography [8]. If performed correctly with the patient in the left lateral decubitus position for 10 to 20 minutes and in the upright position for 10 minutes prior to radiography, as little as 1 to 2 mL of free intraperitoneal air can be reliably detected [9]. Anastomotic leakage is a serious, life-threatening complication and early detection and emergent intervention is required to avert a catastrophic situation. Anastomotic leakage may initially present with vague abdominal discomfort without definitive peritoneal irritation signs, fe-

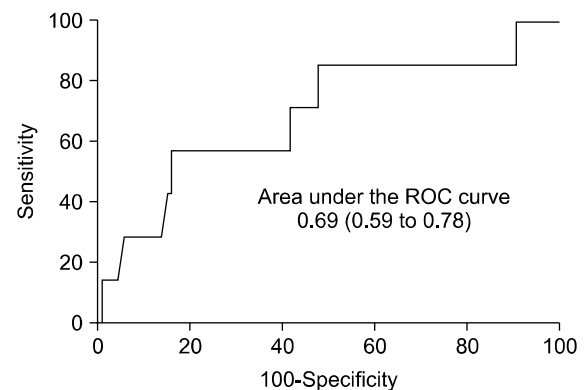


Fig. 2. The receiver operating characteristic (ROC) curve of initial height of free air in patients with anastomotic leakage.

Table 2. Comparison of demographic and clinical parameters between the physiologic air and anastomotic leakage groups

	Physiologic air group (n = 86)	Leakage group (n = 7)	P-value
Demographic factors			
Age (yr)	65.58 ± 11.36	71.29 ± 10.73	0.20
Gender (male/female)	59 (68.6)/27 (31.4)	5 (71.4)/2 (28.6)	1.00 ^{a)}
Body mass index (kg/m ²)	22.03 ± 3.06	23.84 ± 4.89	0.16
Operative findings			
Duration of surgery (min)	156.45 ± 49.80	204.86 ± 103.69	0.27
Surgery (open/laparoscopy)	79 (91.9)/7 (8.1)	6 (85.7)/1 (14.3)	0.48 ^{a)}
Radiologic findings			
Initial height of air (mm)	7.71 ± 5.08	12.16 ± 7.65	0.04
Decreased height of air	86 (100)	0 (0)	<0.01 ^{a)}
Ileus	8 (9.4)	7 (100)	<0.01 ^{a)}
Pulmonary complications	4 (4.7)	2 (28.6)	0.06 ^{a)}

Values are presented as mean ± SD or number (%).

^{a)}Fisher's exact test.

ver, and tachycardia. In such cases, plain radiographs would be obtained first, rather than an abdominal CT scan. In detecting PP by plain radiographs, we question whether or not intraperitoneal gas is benign or detrimental.

In our study, pneumoperitoneums were detected in 24.2% (93/384) of postoperative patients. Only 7.5% (7/93) of the PPs were due to anastomotic leakage. These findings are comparable to those of other studies [2,3,7-9]. The mean duration of physiologic air was 6.9 ± 2.4 days (range, 2 to 13 days), and the percentage of patients with visible free air decreased over time (observed in 24.0%, 17.7%, 8.6%, and 5.5% of patients on postoperative days 3, 6, 9, and >10, respectively). According to other studies, the prevalence of PPs after abdominal surgery within the first 3 postoperative days has been reported to be 21 to 53%, with PPs persisting in some patients for 5 to 18 days [2,3,7-12]. Indeed, PPs may sometimes be observed for several weeks [4,13-15]. Alternatively, there is a report that PPs are more prevalent in asthenic patients, in males, and in patients with intraperitoneal drains [16]; however, we did not show that any of these factors correlated with the duration of PPs, as in other studies [3,14]. Are there any radiologic findings which may predict anastomotic leakage?

Our study found that several factors might be used to differentiate anastomotic leakage from the normal physiologic state. An initial air height >11.7 mm, an increased height of air over time, and the presence of ileus may be indicators of anastomotic leakage. No previous study has reported a correlation between the height of free air and anastomotic leakage. It is not surprising that as the amount of intraperitoneal free air increased, the possibility of leakage increases. However, this finding should be evaluated further because of the small sample size, relatively low sensitivity, and low positive predictive value.

Our study had several limitations. First, not all leakage cases which we encountered were included. Because patients with definitive evidence of leakage underwent emergent surgery and patients with suspected leakage initially had an abdominal CT scan rather than a simple radiograph, this study only included mild or unquestioned cases, which might lead to selection bias. Second, our results should be applied to clinical situations with caution

due to the intrinsic limits of retrospective studies. Also, we do not claim that the radiologic demonstration of free air alone should play a major role in clinical decision-making about whether or not an exploratory laparotomy is required. Nevertheless, our results may be a useful adjunct in the management of patients with postoperative abdominal symptoms.

In conclusion, PPs are common after abdominal surgery. The findings of an initial air height >11.7 mm, increasing air height over time, and the presence of ileus on plain radiographs suggest a high likelihood of anastomotic leakage.

CONFLICTS OF INTEREST

No potential conflict of interest relevant to this article was reported.

ACKNOWLEDGEMENTS

This study was supported by research funds from Chonbuk National University Hospital in 2011.

REFERENCES

1. Han KS, Kong SK, Pyo CH. Pneumoperitoneum in acute diffuse peritonitis due to perforation of gastro-intestinal tract. *J Korean Surg Soc* 1970;12:55-8.
2. Bevan PG. Incidence of post-operative pneumoperitoneum and its significance. *Br Med J* 1961;2:605-9.
3. Bryant LR, Wiot JF, Kloecker RJ. A study of the factors affecting the incidence and duration of postoperative pneumoperitoneum. *Surg Gynecol Obstet* 1963;117:145-50.
4. Harrison I, Litwer H, Gerwig WH Jr. Studies on the incidence and duration of postoperative pneumoperitoneum. *Ann Surg* 1957;145:591-4.
5. Stapakis JC, Thickman D. Diagnosis of pneumoperitoneum: abdominal CT vs. upright chest film. *J Comput Assist Tomogr* 1992;16:713-6.
6. Mansy HA, Royston TJ, Sandler RH. Use of abdominal percussion for pneumoperitoneum detection. *Med Biol Eng Comput* 2002;40:439-46.
7. Earls JP, Dachman AH, Colon E, Garrett MG, Molloy M. Prevalence and duration of postoperative pneumoperitoneum: sensitivity of CT vs left lateral decubitus radio-

- graphy. *AJR Am J Roentgenol* 1993;161:781-5.
8. Markowitz SK, Ziter FM Jr. The lateral chest film and pneumoperitoneum. *Ann Emerg Med* 1986;15:425-7.
 9. Miller RE, Nelson SW. The roentgenologic demonstration of tiny amounts of free intraperitoneal gas: experimental and clinical studies. *Am J Roentgenol Radium Ther Nucl Med* 1971;112:574-85.
 10. Tang CL, Yeong KY, Nyam DC, Eu KW, Ho YH, Leong AF, et al. Postoperative intra-abdominal free gas after open colorectal resection. *Dis Colon Rectum* 2000;43:1116-20.
 11. Gayer G, Jonas T, Apter S, Amitai M, Shabtai M, Hertz M. Postoperative pneumoperitoneum as detected by CT: prevalence, duration, and relevant factors affecting its possible significance. *Abdom Imaging* 2000;25:301-5.
 12. Schauer PR, Page CP, Ghatas AA, Miller JE, Schwesinger WH, Sirinek KR. Incidence and significance of sub-diaphragmatic air following laparoscopic cholecystectomy. *Am Surg* 1997;63:132-6.
 13. Wiot JF, Benton C, McAlister WH. Postoperative pneumoperitoneum in children. *Radiology* 1967;89:285-8.
 14. Rice RP, Thompson WM, Gedgudas RK. The diagnosis and significance of extraluminal gas in the abdomen. *Radiol Clin North Am* 1982;20:819-37.
 15. Millitz K, Moote DJ, Sparrow RK, Girotti MJ, Holliday RL, McLarty TD. Pneumoperitoneum after laparoscopic cholecystectomy: frequency and duration as seen on upright chest radiographs. *AJR Am J Roentgenol* 1994;163:837-9.
 16. Gayer G, Hertz M, Zissin R. Postoperative pneumoperitoneum: prevalence, duration, and possible significance. *Semin Ultrasound CT MR* 2004;25:286-9.