

# A Paradigm Shift in Osteonecrosis Treatment with Bisphosphonates

## A 20-Year Study

Sanjay Agarwala D(Orth), MS(Orth), MCh(Orth), and Mayank Vijayvargiya, MS(Orth)

*Investigation performed at the Department of Orthopaedics, P.D. Hinduja National Hospital and Medical Research Centre, Mumbai, India*

**Background:** Bisphosphonates are proven to be effective in obviating the need for surgical intervention in osteonecrosis of the femoral head. However, the late onset of pain relief hampers compliance. We present the clinical and radiographic outcome of a combination therapy compared with alendronate-only therapy for the management of osteonecrosis of the femoral head.

**Methods:** The data of patients diagnosed with osteonecrosis of the femoral head from January 2001 to January 2017 were retrospectively analyzed. The first group, the alendronate treatment group, comprised 432 hips (358 patients) diagnosed from January 2001 to January 2009 and treated with 10-mg oral alendronate daily for 3 years. The second group, the combination treatment group, comprised 442 hips (386 patients) diagnosed from February 2009 to January 2017 and treated with a combination therapy of 35-mg oral alendronate twice weekly and 5-mg intravenous zoledronic acid once annually for 3 years. Clinical assessment was performed using the Harris hip score, the visual analog scale (VAS) pain score, and the clinical failure rate. Radiographic assessment was performed for progression and collapse.

**Results:** In the alendronate treatment group, at a mean follow-up of 129.6 months (range, 60 to 220 months), 74.5% did not require a surgical procedure, and, in the combination treatment group, at a mean follow-up of 69 months (range, 37 to 105 months), 88.9% did not require a surgical procedure. The clinical failure rate at 3 years was 4% for stage I, 11% for stage II, and 29% for stage III in the alendronate treatment group, and it was 5% for stage I, 9% for stage II, and 32% for stage III in the combination treatment group. Patients in the combination treatment group had a significantly better improvement in VAS score at 6 weeks (from 7.10 to 3.66) compared with patients in the alendronate treatment group (from 7.93 to 7.00).

**Conclusions:** Our study shows that both oral alendronate-only therapy and bisphosphonate combination therapy retard the progression of disease, reduce the rate of collapse, and, hence, reduce the need for joint replacement surgery. However, bisphosphonate combination therapy offers earlier improvement in pain and functional scores compared with oral alendronate therapy only.

**Level of Evidence:** Therapeutic Level III. See Instructions for Authors for a complete description of levels of evidence.

Osteonecrosis of the femoral head causes structural failure of the bone and may lead to secondary arthritis. If left untreated, collapse may occur in approximately 75% of patients<sup>1,2</sup>. Major surgical intervention is required in approximately 50% patients within 3 years of presentation<sup>1,2</sup>. Even though certain pharmacotherapies have been assessed, their results have not been encouraging<sup>3</sup>. Of the plethora of surgical options available, none has given a predictable or consistent result<sup>3</sup>. In a recent meta-analysis of 32 studies involving 2,441 patients, Hua et al. reported that core decompression has a

success rate of around 65% at a mean follow-up of 54 months<sup>4</sup>. However, in their recent review article, Mont et al.<sup>3</sup> suggested that core decompression may not be superior to nonoperative measures due to the lack of recently performed, randomized studies. Arthroplasty is the mainstay of management and, when performed in younger patients, may necessitate a revision surgical procedure. Hence, strategies to avert the need for surgical intervention are required.

Agarwala et al. were the first to report the successful use of alendronate for osteonecrosis of the femoral head in 2001<sup>5</sup>.

**Disclosure:** The **Disclosure of Potential Conflicts of Interest** forms are provided with the online version of the article (<http://links.lww.com/JBJSOA/A350>).

Copyright © 2021 The Authors. Published by The Journal of Bone and Joint Surgery, Incorporated. All rights reserved. This is an open-access article distributed under the terms of the [Creative Commons Attribution-Non Commercial-No Derivatives License 4.0](https://creativecommons.org/licenses/by-nc-nd/4.0/) (CCBY-NC-ND), where it is permissible to download and share the work provided it is properly cited. The work cannot be changed in any way or used commercially without permission from the journal.

**TABLE I Etiology of Osteonecrosis in Our Group of Patients (N = 744)**

Etiology	No. of Patients
Alcohol-induced	105 (14.1%)
Corticosteroid therapy	89 (12%)
Collagen vascular disease	52 (7.0%)
Sickle cell disease or other hemoglobinopathies	35 (4.7%)
Posttraumatic	32 (4.3%)
Chemotherapy	28 (3.8%)
Radiation therapy	25 (3.4%)
Renal transplantation	21 (2.8%)
Post-pregnancy	18 (2.4%)
Ochronosis	2 (0.3%)
Idiopathic	337 (45.3%)

Thereafter, in 2011, Agarwala and Shah published a 10-year follow-up of the results of oral alendronate, in which 87% of hips did not require arthroplasty<sup>6</sup>. They concluded that alendronate given for 3 years maintained its beneficial effect for 10 years. Subsequently, various authors have reported on the use of bisphosphonates in the management of osteonecrosis, which is now considered as one of the standard treatment options<sup>7-13</sup>.

The critical limitation of 10-mg alendronate was its late onset of pain relief (almost 12 weeks)<sup>11,14,15</sup>, which deterred compliance. In 2009, the sale of 10-mg oral alendronate was discontinued in India. Thereafter, the bisphosphonate protocol offered was 35-mg oral alendronate twice a week combined with once-annual 5-mg intravenous zoledronic acid, to offer earlier onset of pain relief. Zoledronic acid has a faster onset of action and higher bioavailability<sup>15</sup>, but it is not effective in preventing collapse in cases of osteonecrosis<sup>16</sup>. Combination therapy was based on the animal study by Astrand and Aspenberg, in which

resorption of necrotic bone was prevented by bisphosphonate doses 4 to 50 times higher than those used for the treatment of osteoporosis<sup>17</sup>. It was hence postulated that an intravenous loading dose of zoledronic acid would be more effective because of ensuing higher blood levels of bisphosphonate. The null hypothesis of our study was that the bisphosphonate combination therapy is not superior to oral alendronate-only therapy in obtaining early pain relief and preventing radiographic progression, collapse, and the need for a surgical procedure.

The clinical and radiographic outcome of this combination therapy was compared with the outcome in the group of patients with osteonecrosis treated before 2009 using oral alendronate-only therapy. To the best of our knowledge, such a study of a large cohort of patients with a long-term follow-up period ranging from a minimum of 3 years to 18 years on the use of bisphosphonates in the management of osteonecrosis of the femoral head has not been published until now.

## Materials and Methods

### Study Design and Approval

This is a retrospective evaluation of prospectively collected data of patients treated for osteonecrosis of the femoral head. All patients who presented with osteonecrosis of the femoral head were considered for inclusion in the study; we excluded patients with Ficat-Arlet<sup>18</sup> stage IV, those with intolerance to bisphosphonate therapy, and those with hepatorenal compromise. Patients were diagnosed with and treated for osteonecrosis of the femoral head; the alendronate treatment group was treated between January 2001 and January 2009, and the combination treatment group was treated between February 2009 and January 2017. Institutional review board approval was obtained.

### Participants

In the alendronate treatment group, 442 patients had osteonecrosis of the femoral head. We excluded 24 patients with stage-IV

**TABLE II Stage at Presentation and Clinical Failure Rates at the 3-Year and Latest Follow-ups**

Variable	Alendronate (N = 432)*	Combination (N = 442)*	Chi-Square Value	P Value
Stage at presentation			1.528	0.466
I	155 (35.9%)	171 (38.7%)		
II	211 (48.8%)	215 (48.6%)		
III	66 (15.3%)	56 (12.7%)		
Underwent operation at 3-year follow-up			0.199	0.656
Yes	48 (11.1%)	45 (10.2%)		
No	384 (88.9%)	397 (89.8%)		
Underwent operation at latest follow-up			16.882	<0.001
Yes	110 (25.5%)	58 (13.1%)		
No	322 (74.5%)	384 (86.9%)		

\*The values are given as the number of hips, with the percentage in parentheses.

TABLE III Radiographic Progression, Collapse, and Surgical Procedures at the Mean 3-Year Follow-up

Initial Stage*	Radiographic Progression			Radiographic Collapse			Surgical Procedure		
	Alendronate †	Combination †	Z Value (P Value)	Alendronate †	Combination †	Z Value (P Value)	Alendronate †	Combination †	Z Value (P Value)
I	62 (40.0%)	56 (32.7%)	1.371 (0.371)	16 (10.3%)	18 (10.5%)	-0.059 (0.953)	6 (3.9%)	8 (4.7%)	-0.356 (0.721)
II	112 (53.1%)	98 (45.6%)	1.552 (0.121)	112 (53.1%)	98 (45.6%)	1.552 (0.121)	23 (10.9%)	19 (8.8%)	0.727 (0.467)
III	24 (36.3%)	24 (42.8%)	-0.732 (0.464)	—	—	—	19 (28.8%)	18 (32.1%)	-0.394 (0.693)
Total	198 (45.8%)	178 (40.3%)	1.644 (0.100)	128 (29.6%)	116 (26.2%)	1.121 (0.262)	48 (11.1%)	45 (10.2%)	0.431 (0.666)

\*These values are the Ficat and Arlet stage at the commencement of treatment. †The values are given as the number of hips, with the percentage in parentheses.

osteonecrosis, 13 patients with intolerance to bisphosphonates, and 47 patients who were lost to follow-up (dropout, 10.6%). Thus, 432 hips of 358 patients received treatment in the alendronate treatment group; of these patients, 284 had unilateral involvement and 74 had bilateral involvement.

The combination treatment group had 488 patients with osteonecrosis of the femoral head. We excluded 39 patients with stage-IV osteonecrosis, 19 patients with intolerance to bisphosphonates, and 44 patients who were lost to follow-up (dropout, 9.0%). Thus, 442 hips of 386 patients received treatment in the combination treatment group; of these patients, 330 had unilateral involvement and 56 had bilateral involvement.

### Management

Patients in the alendronate treatment group were treated with 10-mg oral alendronate daily for 3 years. Patients in the combination treatment group received 5-mg intravenous zoledronic acid at the first visit and thereafter once annually along with 35-mg oral alendronate, twice-weekly doses for 3 years. Patients in both of the groups received daily 1,000-mg calcium and 800-IU vitamin D. Partial weight-bearing using axillary or elbow crutches was advised for the first 3 months.

### Outcome Measures

Demographic data, the visual analog scale (VAS) score for pain, the Harris hip score<sup>19</sup> (HHS), and the radiographic stage of osteonecrosis using the Ficat and Arlet grading system<sup>18</sup> were

recorded at the time of presentation. Follow-up was done at 3 weeks, 3 months, 6 months, 1 year, and annually thereafter. At each follow-up visit, patients were assessed clinically using the VAS score and the HHS and radiographically using radiographs of both hips in anteroposterior and lateral views. Magnetic resonance imaging (MRI) was performed for all of the patients at their first follow-up visit but was not repeated at every follow-up due to financial constraints.

Clinical failure was defined as increasing pain or disability that warranted surgical intervention. Hips that did not require a surgical procedure were considered as survived hips. Radiographic failure was defined as the progression in radiographic staging by 1 to 2 stages as defined by the Ficat and Arlet criteria. Radiographic collapse was the progression of Ficat stage I or II to the collapse stage of Ficat stage III.

### Statistical Analysis

Data analysis was done using Stata 13.0 (StataCorp). Descriptive statistics such as the mean, standard deviation, frequency, and percentage were obtained to summarize data. The independent t test was performed to compare the means of 2 independent groups. The Wilcoxon signed rank test was applied to check the difference of various parameters at 2 time periods. Throughout the study, significance (alpha error) was set at 5%.

### Source of Funding

There was no source of external funding for this study.

TABLE IV Radiographic Progression, Collapse, and Surgical Procedures at the Latest Follow-up

Initial Stage*	Radiographic Progression			Radiographic Collapse			Surgical Procedure		
	Alendronate †	Combination †	Z Value (P Value)	Alendronate †	Combination †	Z Value (P Value)	Alendronate †	Combination †	Z Value (P Value)
I	98 (63.2%)	70 (40.9%)	4.131 (<0.001)	48 (30.9%)	37 (21.6%)	1.911 (0.056)	18 (11.6%)	14 (8.1%)	1.372 (0.170)
II	170 (80.5%)	134 (62.3%)	4.247 (<0.001)	170 (80.5%)	134 (62.3%)	4.247 (<0.001)	54 (25.5%)	20 (9.3%)	2.626 (0.009)
III	53 (80.5%)	35 (62.5%)	2.222 (0.026)	—	—	—	38 (57.6%)	24 (44.4%)	2.798 (0.005)
Total	321 (74.3%)	239 (54.1%)	6.375 (<0.001)	218 (50.5%)	171 (38.7%)	3.503 (<0.001)	110 (25.5%)	58 (13.1%)	4.075 (<0.001)

\*These values are the Ficat and Arlet stage at the commencement of treatment. †The values are given as the number of hips, with the percentage in parentheses.

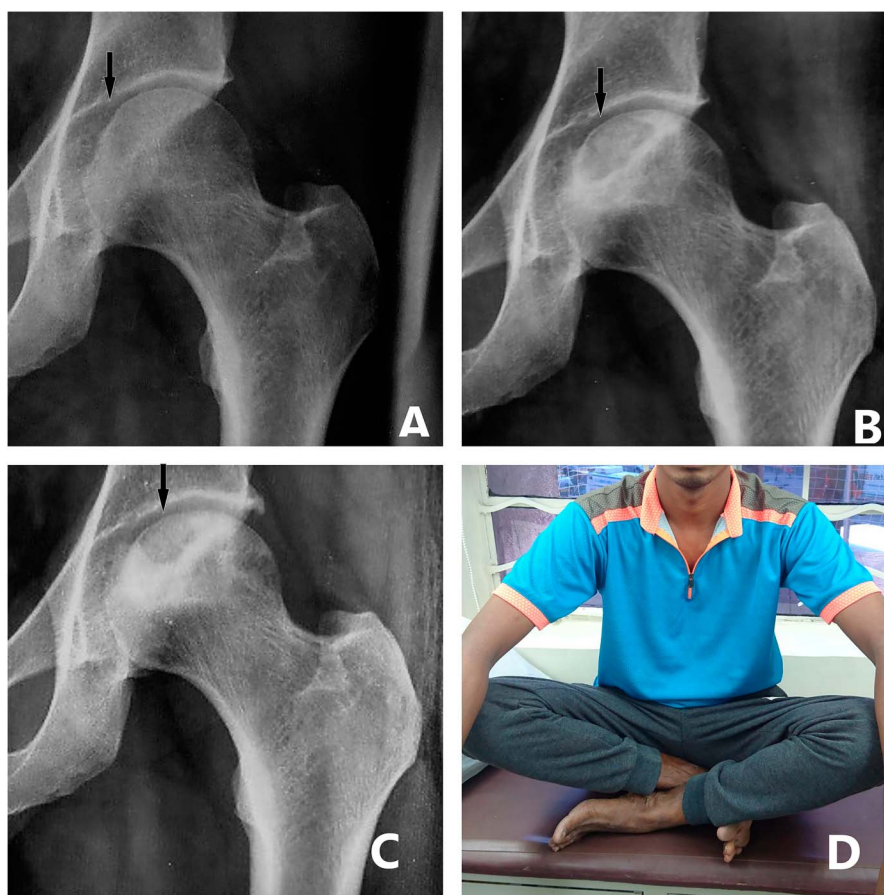


Fig. 1  
A 24-year-old male patient in the combination treatment group demonstrating Ficat-Arlet stage-II osteonecrosis of the left femoral head. **Fig. 1-A** Anteroposterior radiograph made prior to treatment. The black arrow indicates Ficat-Arlet stage-II osteonecrosis of the left femoral head. **Fig. 1-B** Radiograph made at 3 years after treatment demonstrating no radiographic progression of the disease (indicated by the black arrow). **Fig. 1-C** Radiograph made at the latest follow-up of 9 years showing no radiographic progression of the disease (indicated by the black arrow). **Fig. 1-D** Clinical photograph showing that the patient was able to sit cross-legged; he had good functional outcomes.

## Results

### Demographic Characteristics

The etiology of the osteonecrosis in our study is shown in Table I. There was no significant difference between the groups with respect to the stage at presentation ( $p = 0.47$ ) (Table II).

### Follow-up

In the alendronate treatment group, the latest follow-up duration averaged 129.6 months (range, 60 to 220 months), whereas, in the combination treatment group, it was 69 months (range, 37 to 105 months). Therefore, outcomes were also compared at 3 years after starting the treatment, which allowed us to make a comparison between the 2 treatment regimens.

### Clinical Failure Rate

At 3 years, in the alendronate treatment group, 384 (88.9%) of 432 hips had a satisfactory clinical result and did not require a surgical procedure, whereas, in the combination treatment

group, 397 (89.8%) of 442 hips had a satisfactory clinical outcome and did not require a surgical procedure ( $p = 0.67$ ) (Table III). There was no significant difference in stage-wise clinical failure rates between the 2 groups (Table III).

In the alendronate treatment group, at the latest follow-up, 322 hips (74.5%) had a satisfactory outcome and did not require a surgical procedure and 110 hips (25.5%) required a surgical procedure (Table IV). In the combination treatment group, only 58 (13.1%) of 442 hips required a surgical procedure; thus, 384 hips (86.9%) had a satisfactory clinical outcome.

### Radiographic Progression and Collapse Rates

There was no difference in the radiographic progression and collapse rates between the 2 groups at 3 years (Table III). The progression rate and the collapse rate at the latest follow-up between the 2 groups are shown in Table IV. The radiographic progression rate at 3 years was 40% for stage I, 53% for stage II, and 36% for stage III in the alendronate treatment group and



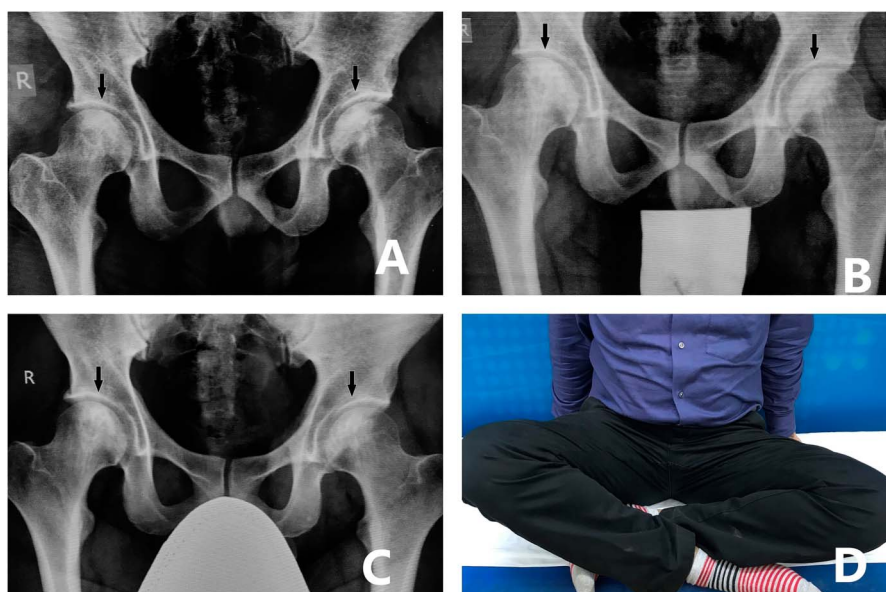


Fig. 2  
A 33-year-old male patient in the combination treatment group demonstrating Ficat-Arlet stage-II osteonecrosis of both femoral heads. **Fig. 2-A** Anteroposterior radiograph made prior to treatment. The black arrows indicate Ficat-Arlet stage-II osteonecrosis of both femoral heads. **Fig. 2-B** Radiograph made at 3 years after treatment demonstrating no radiographic progression of the disease (indicated by the black arrows). **Fig. 2-C** Radiograph made at the latest follow-up of 8 years showing no radiographic progression of the disease (indicated by the black arrows). **Fig. 2-D** Clinical photograph showing that the patient was able to sit cross-legged; he had good functional outcomes.

33% for stage I, 46% for stage II, and 43% for stage III in the combination treatment group; the radiographic progression rate did not differ significantly between the treatment groups for any stage. The radiographic collapse rate at 3 years was 10% for stage I and 53% for stage II in the alendronate treatment group and 10% for stage I and 46% for stage II in the combination treatment group; the radiographic collapse rate did not differ significantly between the treatment groups for any stage. Case examples are shown in Figures 1, 2, and 3.

#### VAS and HHS Comparison Between the Groups

From the start of therapy to 6 weeks later, the mean VAS score (and standard deviation) improved from  $7.93 \pm 0.85$  to  $7.00 \pm 0.82$  in the alendronate treatment group and from  $7.10 \pm 0.69$  to  $3.66 \pm 1.47$  in the combination treatment group. At 3 months, the mean VAS score in the alendronate treatment group was  $4.02 \pm 0.816$  compared with  $3.06 \pm 1.60$  in the combination treatment group, which was significant ( $p = 0.001$ ) (Fig. 4).

At presentation, the mean HHS in the alendronate treatment group was  $41.3 \pm 2.12$ , which improved to  $45.5 \pm 1.78$  at 6 weeks and  $57.9 \pm 1.43$  at 3 months. In the combination treatment group, the mean HHS was  $40.9 \pm 3.07$  at presentation, which improved to  $55.3 \pm 4.69$  at 6 weeks and  $63.12 \pm 7.59$  at 3 months. There was a significant difference in the HHS between the 2 groups at 6 weeks ( $p = 0.001$ ) and 3 months ( $p = 0.004$ ) (Fig. 5).

#### Adverse Effects

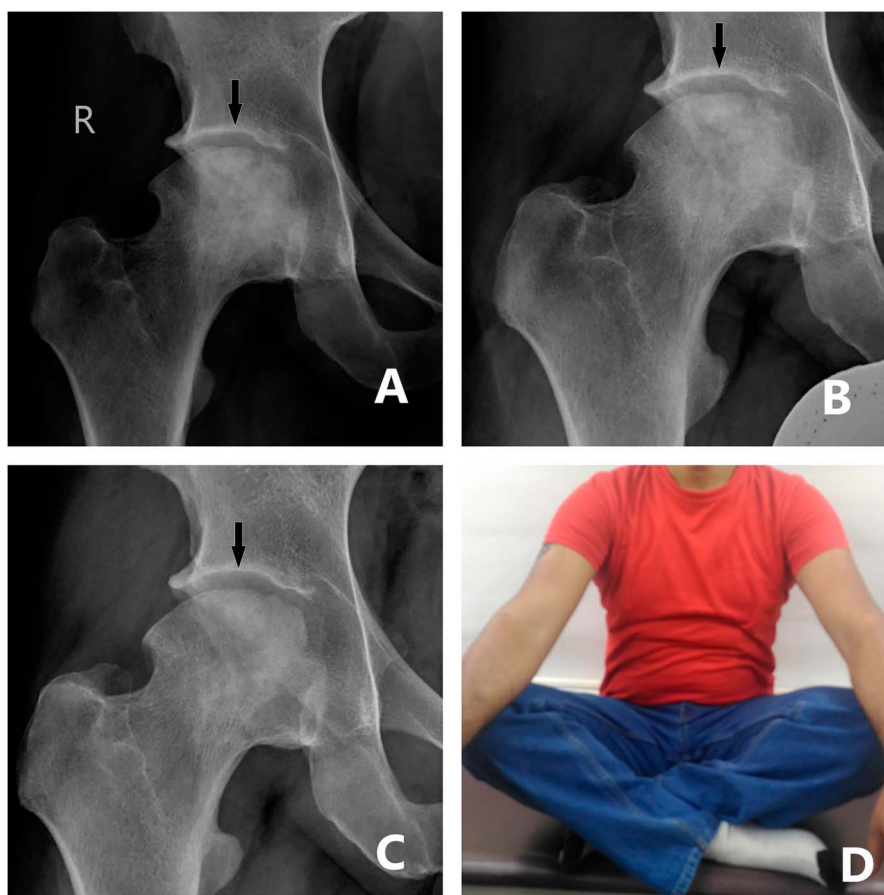
Thirteen patients in the alendronate treatment group and 19 patients in the combination treatment group developed dys-

peptic symptoms due to oral alendronate, requiring a cessation of therapy, and were excluded from the study. Thirteen patients in the combination treatment group experienced influenza-like symptoms after receiving the first infusion of zoledronic acid, which lasted for 2 to 3 days and were managed conservatively. Subsequent infusions in these cases did not evoke any reactions. No cases of atypical femoral fractures or osteonecrosis of the jaw were seen.

#### Discussion

The natural history of osteonecrosis is uncertain, with the clinical progression rate ranging from 77% to 98% and the radiographic collapse rate ranging from 68% to 75% at a mean follow-up of 3 years<sup>20-22</sup>. In a review article involving 819 hips followed for 3 years, 78% of the hips required a surgical procedure<sup>23</sup>.

In our study, which included 874 hips (432 hips in the alendronate treatment group and 442 hips in the combination treatment group), the clinical failure rate necessitating total hip replacement was 11.1% (48 of 432 hips) in the alendronate treatment group and 9.95% (44 of 442 hips) in the combination treatment group at 3 years. When comparing our results with historical controls, both of the treatment groups had a greater clinical success rate at 3 years. Further, there was no significant difference in the proportion of patients who underwent an operation at 3 years between the 2 groups. This implies that both of the treatment methods of daily oral alendronate-only therapy and combined biweekly oral and annual intravenous therapy are effective in terms of the freedom from surgical intervention at 3 years.



**Fig. 3**  
A 40-year-old male patient in the alendronate treatment group diagnosed with Ficat-Arlet stage-III osteonecrosis. **Fig. 3-A** Anteroposterior radiograph made prior to treatment showing collapse of the fragmented necrotic femoral head (indicated by the black arrow). **Fig. 3-B** Radiograph made at 3 years demonstrating no radiographic progression of the disease (indicated by the black arrow). **Fig. 3-C** Radiograph made at 15 years after the treatment demonstrating the complete incorporation of the collapsed fragment of the femoral head with no progression to the arthritic stage (indicated by the black arrow). **Fig. 3-D** Clinical photograph of the patient showing a good functional outcome following the bisphosphonate therapy with no requirement for a surgical procedure.

The clinical failure rate at 3 years in our study was 4% for stage I, 11% for stage II, and 29% for stage III in the alendronate treatment group and 5% for stage I, 9% for stage II, and 32% for stage III in the combination treatment group, which is much lower than that reported by Mont and Hungerford<sup>23</sup>: 65% for stage I, 69% for stage II, and 87% for stage III. The radiographic progression rate at 3 years in our study was 46% in the alendronate treatment group and 40% in the combination treatment group, compared with rates of 68% to 75% reported in the literature<sup>1,22,24,25</sup>. In the current study, the 3-year radiographic collapse rates were 30% in the alendronate treatment group and 26% in the combination treatment group, which are less than half of the collapse rates of 80% reported by Ohzono et al.<sup>26</sup> and the 76% rate reported by Lai et al.<sup>10</sup>.

#### *Onset of Pain Relief*

In the combination treatment group, there was a mean reduction in pain scores of 50% at 6 weeks compared with

baseline, whereas the reduction was only 18% in the alendronate treatment group, which was significant. It is interesting that it took 3 months to observe the same mean drop in VAS scores (50%) in the alendronate treatment group. Thus, combined bisphosphonate therapy offers the same pain relief in nearly half the time as compared with oral alendronate-only therapy.

#### *Rationale for Combination Therapy*

In an animal study, Tägil et al. reported that the prevention of necrotic bone resorption during revascularization is dose-dependent<sup>27</sup>. The bisphosphonate dose required to prevent resorption of necrotic bone is 4 to 50 times more than that used to prevent osteoporosis<sup>17</sup>. Bisphosphonate distribution is less in a necrosed femoral head compared with a revascularized femoral head; thus, to have sufficient concentration of bisphosphonate in the necrosed bone, continued administration of the drug is required<sup>28</sup>.

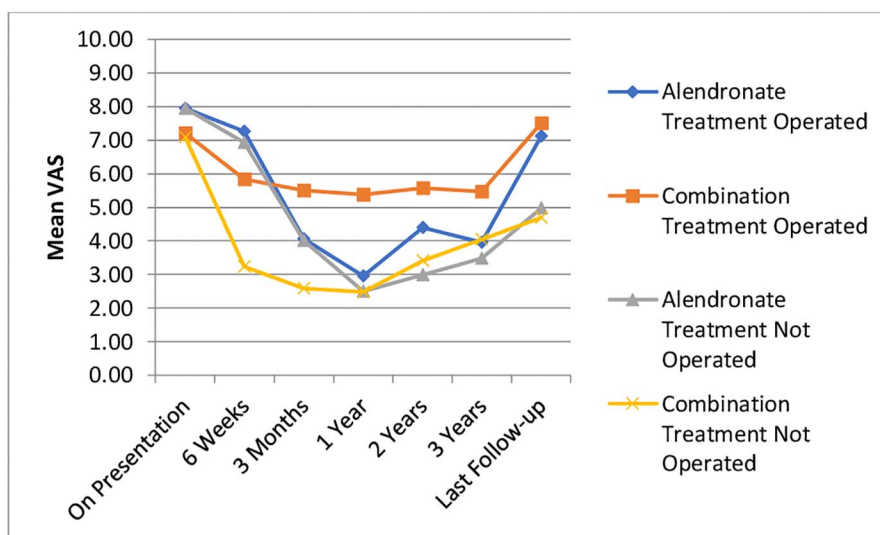


Fig. 4

Line graph showing the improvement in VAS at various follow-ups between the 2 groups.

We believe that the early improvement in pain (VAS scores) and function (HHS) seen in the combination treatment group at 6 weeks and 3 months compared with the alendronate treatment group could be attributed to the dose-related effect of bisphosphonate. It has also been reported that urine NTX (N-telopeptide of type-I collagen) levels are detected as early as 1 week after zoledronic acid compared with 12 weeks after alendronate<sup>15</sup>. Even though zoledronic acid can achieve desired serum levels earlier, reflecting an earlier onset of pain relief, zoledronic acid alone is not effective in preventing radiographic collapse<sup>12,13,16</sup>. In the combination treatment group of our study, zoledronic acid complemented alendronate in achieving an early onset of pain relief and improvement in functional scores. However, the overall

radiographic progression, collapse, and clinical failure rates remained the same between the 2 groups at the 3-year follow-up.

#### Previous Studies on Bisphosphonate Combination Therapy

Kraenzlin et al.<sup>29</sup> reported the beneficial effects of a combination of intravenous pamidronate (120 mg divided into 3 to 4 dosages given over 2 weeks) and oral alendronate (70 mg given weekly for 4 to 6 months) for managing knee osteonecrosis. There was a significant decrease in VAS scores from  $8.2 \pm 1.2$  at the start of therapy to  $5.02 \pm 0.6$  after 4 to 6 weeks. Combined therapy was found to be safe and was well tolerated.

Agarwala et al. reported that the combination therapy of oral alendronate and intravenous zoledronic acid was effective in

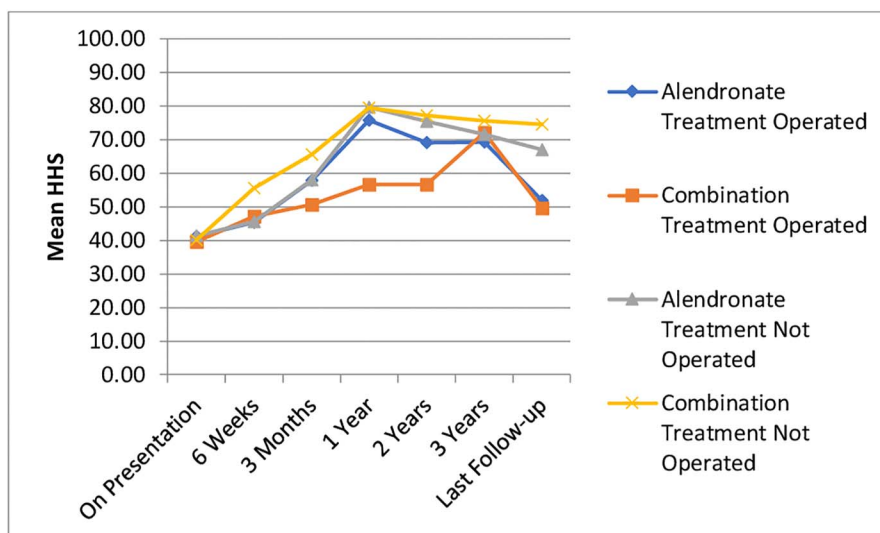


Fig. 5

Line graph demonstrating the improvement in HHS at various follow-ups between the 2 groups.

preventing collapse and obviating the need for a surgical intervention in the management of post-chemotherapy osteonecrosis in leukemia survivors<sup>12</sup>. They reported excellent clinical and radiographic outcome with the combination therapy and a drop in the mean VAS score at 5.2 weeks (range, 3 to 11 weeks) after the start of therapy. This combination therapy was found to be safe, effective, and well tolerated.

Bisphosphonate combination therapy was also found to be safe and effective in the management of non-femoral osteonecrosis<sup>13</sup>. The drop in the VAS score was observed at 4.3 weeks (range, 3 to 13 weeks) after starting therapy and a 50% reduction in mean analgesic requirement was achieved in the first 6 weeks (range, 2 to 11 weeks). Collapse was reported in only 6 of 18 cases<sup>13</sup>.

### Adverse Effects

The dose used in our study is considerably smaller than that being used routinely in cancer management. Higher doses of zoledronic acid (4 mg every 3 to 4 weeks) are routinely used in the prevention of skeletal-related events in cancer management with manageable side effects<sup>30</sup>. Ramachandran et al.<sup>31</sup> used a 0.025 to 0.05-mg/kg dose of zoledronic acid given over 30 minutes after the diagnosis, at 6 weeks after the injury, at 3 months after the injury, and every 3 months thereafter, demonstrating acceptable tolerability. Similarly, Agarwala et al. showed that the combination therapy of zoledronic acid and oral alendronate in the same doses was safe and tolerable<sup>12,13</sup>.

### Limitations and Strengths of the Study

The limitations of this study included retrospective analysis and the inability to measure the concordance of clinical outcomes with serum levels of bisphosphonates. Other limitations were the inability to assess the relation of various etiologies with the

outcome and loss of a large group of patients to follow-up (10.6% in the alendronate treatment group and 9% in the combination treatment group). There is a need for a prospective randomized controlled study to further support our findings and establish the role of bisphosphonates in the management of osteonecrosis of the femoral head. The current study has multiple strengths, which include its real-world, long-term, and large-scale nature.

### Conclusions

The duration of follow-up in our study exceeded that of any other study, allowing us to conclude that bisphosphonate therapy given for 3 years maintains its benefits for up to 18 years in some patients. This study provides us with yet another equally efficacious bisphosphonate regimen for the management of osteonecrosis of the femoral head because 10-mg oral alendronate is no longer sold in India. Bisphosphonate combination therapy offers earlier improvement in pain and functional scores compared with oral alendronate-only therapy, which was reflected in enhanced patient compliance. ■

Note: The authors would like to acknowledge Ms. Blossom Fernandes and Ms. Manisha Tuscano for helping out in data collection.

Sanjay Agarwala D(Orth), MS(Orth), MCh(Orth)<sup>1</sup>  
Mayank Vijayvargiya, MS(Orth)<sup>1</sup>

<sup>1</sup>Department of Orthopaedics, P.D. Hinduja National Hospital and Medical Research Centre, Mumbai, India

Email for corresponding author: drsa2011@gmail.com

### References

- Merle D'Aubigné R, Postel M, Mazabraud A, Massias P, Gueguen J, France P. Idiopathic necrosis of the femoral head in adults. *J Bone Joint Surg Br.* 1965 Nov; 47(4):612-33.
- Arlot J. Nontraumatic avascular necrosis of the femoral head. Past, present, and future. *Clin Orthop Relat Res.* 1992 Apr;(277):12-21.
- Mont MA, Salem HS, Piuze NS, Goodman SB, Jones LC. Nontraumatic osteonecrosis of the femoral head: where do we stand today? A 5-year update. *J Bone Joint Surg Am.* 2020 Jun 17;102(12):1084-99.
- Hua KC, Yang XG, Feng JT, Wang F, Yang L, Zhang H, Hu YC. The efficacy and safety of core decompression for the treatment of femoral head necrosis: a systematic review and meta-analysis. *J Orthop Surg Res.* 2019 Sep 11;14(1):306.
- Agarwala S, Sule A, Pai BU, Joshi VR. Study of alendronate in avascular necrosis of bone. *J Assoc Physicians India.* 2001 Sep;49:949-50.
- Agarwala S, Shah SB. Ten-year follow-up of avascular necrosis of femoral head treated with alendronate for 3 years. *J Arthroplasty.* 2011 Oct;26(7):1128-34.
- Agarwala S, Jain D, Joshi VR, Sule A. Efficacy of alendronate, a bisphosphonate, in the treatment of AVN of the hip. A prospective open-label study. *Rheumatology (Oxford).* 2005 Mar;44(3):352-9.
- Agarwala S, Sule A, Pai BU, Joshi VR. Alendronate in the treatment of avascular necrosis of the hip. *Rheumatology (Oxford).* 2002 Mar;41(3):346-7.
- Agarwala S, Shah S, Joshi VR. The use of alendronate in the treatment of avascular necrosis of the femoral head: follow-up to eight years. *J Bone Joint Surg Br.* 2009 Aug;91(8):1013-8.
- Lai KA, Shen WJ, Yang CY, Shao CJ, Hsu JT, Lin RM. The use of alendronate to prevent early collapse of the femoral head in patients with nontraumatic osteonecrosis. A randomized clinical study. *J Bone Joint Surg Am.* 2005 Oct;87(10): 2155-9.
- Nishii T, Sugano N, Miki H, Hashimoto J, Yoshikawa H. Does alendronate prevent collapse in osteonecrosis of the femoral head? *Clin Orthop Relat Res.* 2006 Feb;443(443):273-9.
- Agarwala S, Banavali SD, Vijayvargiya M. Bisphosphonate combination therapy in the management of postchemotherapy avascular necrosis of the femoral head in adolescents and young adults: a retrospective study from India. *J Glob Oncol.* 2018 Sep;4:1-11.
- Agarwala S, Vijayvargiya M. Bisphosphonate combination therapy for non-femoral avascular necrosis. *J Orthop Surg Res.* 2019 Apr 24;14(1):112.
- Waalén J. Current and emerging therapies for the treatment of osteoporosis. *J Exp Pharmacol.* 2010 Aug 27;2:121-34.
- Saag K, Lindsay R, Kriegman A, Beamer E, Zhou W. A single zoledronic acid infusion reduces bone resorption markers more rapidly than weekly oral alendronate in postmenopausal women with low bone mineral density. *Bone.* 2007 May;40(5):1238-43.
- Padhye B, Dalla-Pozza L, Little DG, Munns CF. Use of zoledronic acid for treatment of chemotherapy related osteonecrosis in children and adolescents: a retrospective analysis. *Pediatr Blood Cancer.* 2013 Sep;60(9):1539-45.
- Astrand J, Aspenberg P. Systemic alendronate prevents resorption of necrotic bone during revascularization. A bone chamber study in rats. *BMC Musculoskelet Disord.* 2002 Aug 7;3:19-23.
- Ficat RP, Arlot J. Necrosis of the femoral head. In: Hungerford DS, editor. *Ischemia and necrosis of bone.* Williams and Wilkins; 1980.
- Harris WH. Traumatic arthritis of the hip after dislocation and acetabular fractures: treatment by mold arthroplasty. An end-result study using a new method of result evaluation. *J Bone Joint Surg Am.* 1969 Jun;51(4):737-55.
- Patterson RJ, Bickel WH, Dahlin DC. Idiopathic avascular necrosis of the head of the femur. A study of fifty-two cases. *J Bone Joint Surg Am.* 1964 Mar;46:267-82.



- 21.** Romer U, Wettstein P. Results of treatment of 81 patients with INFH. In: Zinn WM, editor. Idiopathic ischemic necrosis of the femoral head in adults. Georg Thieme Publishers; 1971. p 205-12.
- 22.** Zizic TM, Hungerford DS. Avascular necrosis of bone. In: Kelly WN, Harris ED, Ruddy S, Sledge CB, editors. Textbook of rheumatology. W. B. Saunders; 1985. p 1689-710.
- 23.** Mont MA, Hungerford DS. Non-traumatic avascular necrosis of the femoral head. *J Bone Joint Surg Am.* 1995 Mar;77(3):459-74.
- 24.** Aaron RK, Gray RL. Osteonecrosis: etiology, natural history, pathophysiology, and diagnosis. In: Callaghan JJ, Rosenberg AG, Rubash HE, editors. The adult hip. 2nd ed. Lippincott Williams and Wilkins; 2007. p 463.
- 25.** Bradway JK, Morrey BF. The natural history of the silent hip in bilateral atraumatic osteonecrosis. *J Arthroplasty.* 1993 Aug;8(4):383-7.
- 26.** Ohzono K, Saito M, Sugano N, Takaoka K, Ono K. The fate of nontraumatic avascular necrosis of the femoral head. A radiologic classification to formulate prognosis. *Clin Orthop Relat Res.* 1992 Apr;(277):73-8.
- 27.** Tägil M, Astrand J, Westman L, Aspenberg P. Alendronate prevents collapse in mechanically loaded osteochondral grafts: a bone chamber study in rats. *Acta Orthop Scand.* 2004 Dec;75(6):756-61.
- 28.** Kim HK, Sanders M, Athavale S, Bian H, Bauss F. Local bioavailability and distribution of systemically (parenterally) administered ibandronate in the infarcted femoral head. *Bone.* 2006 Jul;39(1):205-12.
- 29.** Kraenzlin ME, Graf C, Meier C, Kraenzlin C, Friedrich NF. Possible beneficial effect of bisphosphonates in osteonecrosis of the knee. *Knee Surg Sports Traumatol Arthrosc.* 2010 Dec;18(12):1638-44.
- 30.** Berenson JR. Recommendations for zoledronic acid treatment of patients with bone metastases. *Oncologist.* 2005 Jan;10(1):52-62.
- 31.** Ramachandran M, Ward K, Brown RR, Munns CF, Cowell CT, Little DG. Intravenous bisphosphonate therapy for traumatic osteonecrosis of the femoral head in adolescents. *J Bone Joint Surg Am.* 2007 Aug;89(8):1727-34.