



Superomedial Portal (Ejnisman's Portal) and Modified "Chicken-Wing" Patient Position for Scapulothoracic Arthroscopy

Carlos Vicente Andreoli, M.D., Ph.D., Alberto de Castro Pochini, M.D., Ph.D.,
Cassiano Diniz Carvalho, M.D., Paulo Santoro Belangero, M.D., Ph.D.,
Benno Ejnisman, M.D., Ph.D., Moisés Cohen, M.D., Ph.D., and Flavio Faloppa, M.D., Ph.D.

Abstract: Scapulothoracic arthroscopy is performed to treat scapulothoracic joint disorders, such as scapulothoracic bursitis, snapping scapula, and osteochondroma of the anterior scapula surface, and in the extraction of firearm projectiles. This article describes this treatment using an alternative superomedial portal and modified chicken-wing position to improve access to the scapulothoracic space and thus perform the procedure as safely as possible, with less morbidity and excellent results for the patients.

Scapulothoracic joint disorders may be characterized according to their etiology.^{1,2} The presence of mechanical symptoms may denote a bony protrusion or abnormal morphology of the joint soft tissue³ or can also be caused by a foreign body. These structural abnormalities frequently result in inflammation, bursitis, and scapular crepitus. In cases without mechanical symptoms, pain is related to the occurrence of overload syndrome, resulting in symptomatic bursitis. The latter phenomenon characteristically occurs in young, active patients and athletes who throw.⁴

Scapulothoracic joint arthroscopy was first described by Ciullo and Jones (1,992) and has been continuously improved over time.⁵⁻⁸ Although its indications

are restricted, including snapping scapula syndrome, decompression for scapulothoracic bursitis, foreign

From the Sports Medicine Division (P.S.B.), Department of Orthopedics and Traumatology (C.V.A., C.D.C., A.d.C.P., B.E.), Universidade Federal de São Paulo (UNIFESP), Escola Paulista de Medicina (M.C., F.F.), São Paulo, SP, Brazil.

The authors report that they have no conflicts of interest in the authorship and publication of this article. Full ICMJE author disclosure forms are available for this article online, as [supplementary material](#).

Received December 27, 2018; accepted August 27, 2019.

Address correspondence to Carlos Vicente Andreoli, M.D., Ph.D., Chief of Sports Medicine of Department of Orthopedics and Traumatology, Universidade Federal de São Paulo (UNIFESP), Escola Paulista de Medicina, Rua Iara 123 apto 91 raritate, Bairro Itaim, São Paulo, SP-cep 04542-30, Brazil. E-mail: andreolicruz@uol.com.br

© 2019 by the Arthroscopy Association of North America. Published by Elsevier. This is an open access article under the CC BY-NC-ND license (<http://creativecommons.org/licenses/by-nc-nd/4.0/>).

2212-6287/181567

<https://doi.org/10.1016/j.eats.2019.08.019>

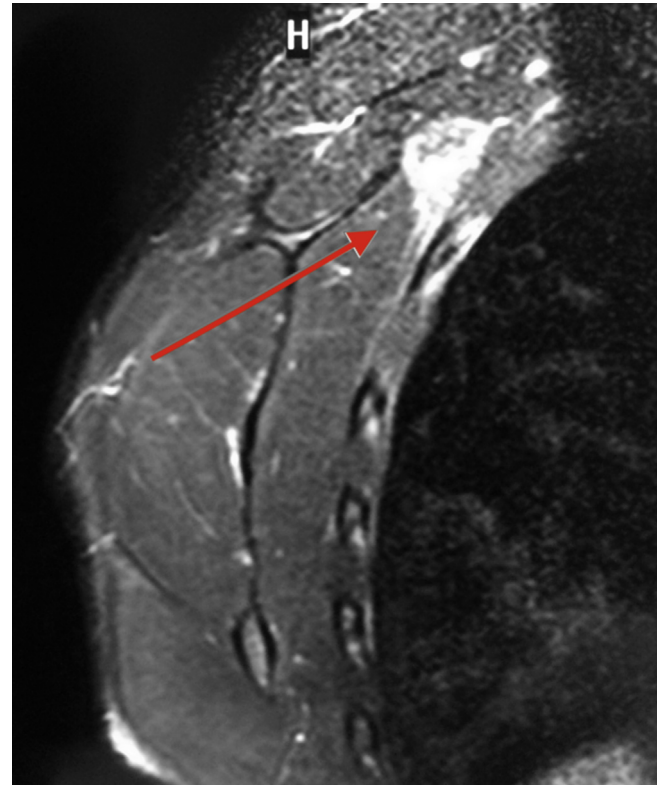


Fig 1. Magnetic resonance imaging of a left scapula on T2 demonstrating the inflammatory process in the superomedial angle of the scapula (red arrow).

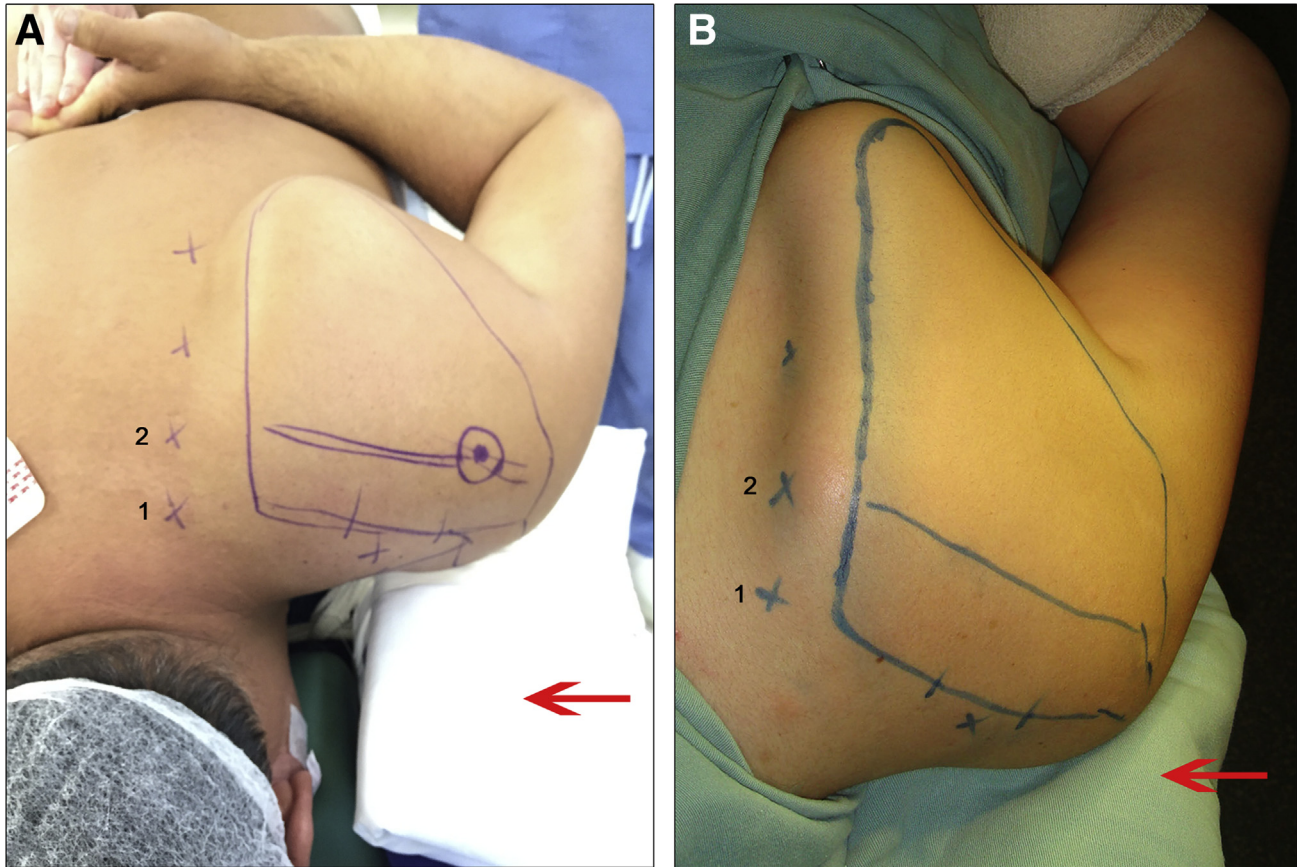


Fig 2. (A-B) Ventral decubitus with the affected left limb in maximum internal rotation (chicken-wing position) using a pad anterior to the shoulder (red arrow) with posteriorization of the scapula.²²

body resection, benign tumor resection, and treatment of chronic pain refractory to conservative treatment,⁵⁻²² arthroscopy is associated with lower morbidity, better esthetic results, and faster rehabilitation.³

The arthroscopic scapulothoracic anatomy was described in cadaveric studies performed by Ruland et al.,¹¹ who listed the relevant neurovascular structures and suggested safe portals to avoid injuring noble structures. The scapulothoracic joint includes 2 triangular spaces, the serratus anterior space, and the subscapularis space, which are divided obliquely by the serratus anterior muscle. The boundaries of the anterior serratus space include the anterior serratus muscle posteriorly, the rhomboid muscle medially, and the chest wall anteriorly. The subscapularis space is bounded by the anterior serratus muscle, the subscapularis muscle posteriorly, and the axilla laterally.⁶

In an anatomic study conducted with cadavers, Andreoli et al.²² showed that arthroscopy becomes safer through modification of the classic patient positioning, which further allows for safe use of the superomedial portal. The aim of the present study was to describe the surgical technique for scapulothoracic arthroscopy using a modified chicken-wing position and 2 medial

portals only, including the superomedial portal, i.e. Ejnisman's portal.

Clinical Findings

Although diagnosis is mainly clinical, radiographs are taken. An example of Luschka's tubercle, characterized by a hooked superomedial angle of the scapula as evidenced by computed tomography, while magnetic resonance imaging detected local inflammation, is shown in [Figure 1](#).

Surgical Technique

The surgical procedure is begun by placing the patient on ventral decubitus with the affected limb in maximum internal rotation (chicken-wing position), which is modified by placing a pad underneath the scapula (pad anterior to the affected scapula) and with lateral support of the shoulder in the medial direction, with consequent posteriorization of the scapula, as described by Andreoli et al. This modification of the chicken-wing position using a pad anterior to the shoulder allows placement of the scapula perpendicular to the chest plane and

Table 1. Pearls and Pitfalls

Pearls	Pitfalls
Place the patient in the chicken-wing position, which is modified by placing a pad underneath the scapula (pad anterior to the affected scapula) with consequent posteriorization of the scapula.	Be careful of a thin scapula; do not dry more than 2 cm.
Two portals only are marked 2 cm lateral to the medial border of the scapula: Ejnisman’s portal—at the level of the superomedial angle of the scapula—and the portal at the level of the scapular spine.	The ideal surgery time is approximately 30-50 min, which minimizes the possibility of adverse events and complications.

increases the space between the rib cage and scapula (Fig 2A and B).

Portals

The portals are marked 2 cm lateral to the medial border of the scapula:

- o Portal 1: Ejnisman’s portal—at the level of the superomedial angle of the scapula²³
- o Portal 2: at the level of the scapular spine
- o Portal 3: between the scapular spine and the inferior angle of the scapula; and
- o Portal 4: Bell’s portal—between the upper two-thirds of the scapular spine.⁶

An infusion pump at 40-mm Hg pressure was used in all cases and using a 30° arthroscope (Karl Storz, Tuttlingen, Germany). A summary of the pearls and pitfalls, advantages, and disadvantages is listed in Tables 1 and 2.

Bursectomy (With Video Illustration)

The use of a portal at the level of the superomedial angle of the scapula provides direct access for bursectomy and resection of the superomedial angle of the scapula of up to 2 cm, thus avoiding the need for levator scapulae muscle disinsertion.

The described patient position and Ejnisman’s portal were used (Fig 3). All cases were performed the bursectomy and resection the superomedial angle of scapula (Fig 4, Video 1).

Discussion

Scapulothoracic arthroscopy has precise indications, such as snapping scapula,^{5,10,14,21,24-26} resection of foreign bodies²⁷ or benign tumors,^{19-21,28} fracture malunion,⁹ and chronic pain refractory to conservative treatment.⁵ Intra-articular extraction of firearm projectile fragments has been described for the knee, elbow, hip, and subtalar joints.²⁹⁻³⁴ In 2003, Proctor

and Stanert²⁷ described the same procedure for the scapulothoracic joint.

Arthroscopic intervention has been increasingly reported in the literature since its first description by Ciullo.¹⁰ Ruland et al.¹¹ described safe portals in their 1,995 study of the anatomy of the scapulothoracic region; new portals for arthroscopy have been described since that time.^{6,7,35,36}

The following anatomical landmarks for portals^{6,8,11,35,36} were used in our procedure: 2 cm medial to the superior angle of the scapula; 2 cm medial to the scapular spine; midpoint between the spine and the inferior pole of the scapula, 2 cm medial to the

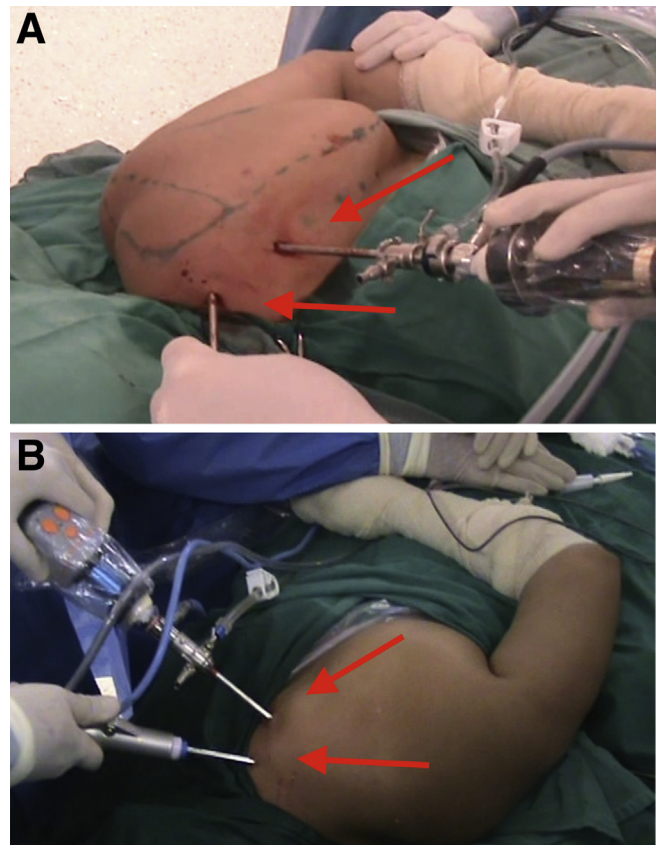


Fig 3. Scapulothoracic arthroscopy in the left with 2 portals (red arrows) from snapping scapula. (A) Ejnisman’s portal—scapular superomedial portal. (B) Portal at the level of the scapular spine.

Table 2. Advantages and Disadvantages

Advantages	Disadvantages
<ul style="list-style-type: none"> • Lower morbidity • Lower postoperative pain 	<ul style="list-style-type: none"> • Learning curve • Control of vascular injury

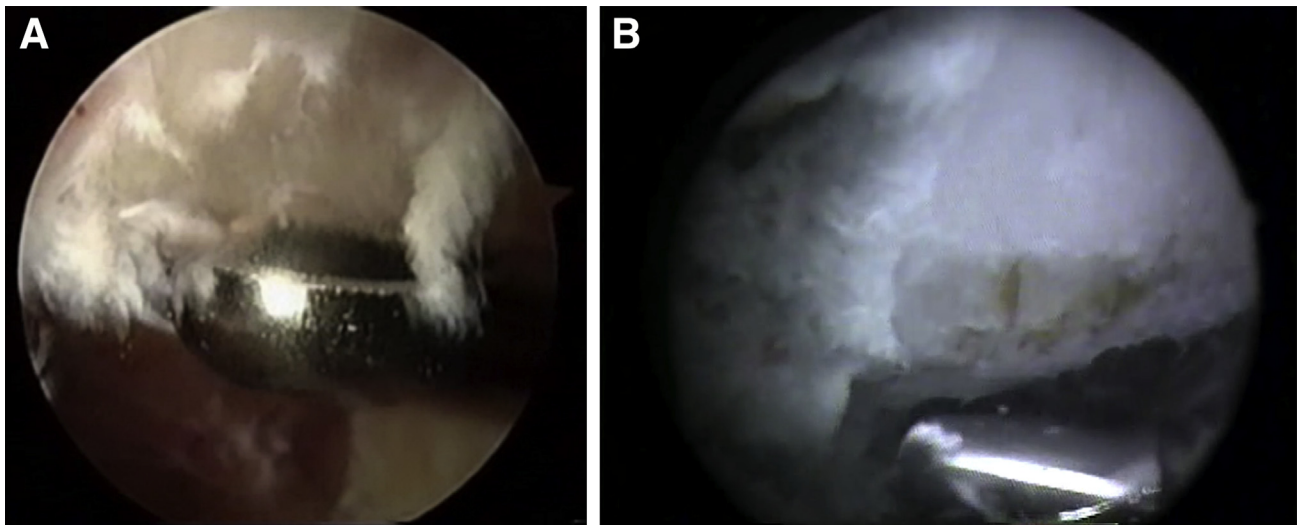


Fig 4. Superomedial arthroscopic images. (A) Bursectomy with full radius. (B) Resection of the scapula with an acromionizer.

medial border of the scapula; and the inferior angle of the scapula. The portals are made 2 to 3 cm medially to the medial border of the scapula and inferiorly to the spine of the scapula to reduce the risk of injuring the main neurovascular bundles.³

Andreoli et al.²² tested the “chicken-wing” position combined with placement of a pad underneath the shoulder in 20 cadavers and observed an increase in the space between the scapula and the chest wall.^{9,35} This space may be further enlarged through medial compression of the lateral shoulder, thereby causing additional bayonet apposition of the body of the scapula.³ We believe that modified position is safer, as it increases the mean distance to the spinal accessory nerve, which is intimately related to the scapulothoracic bursa wall, from the usual 2.4 cm with the typical position to 3.2 cm (Fig 5).

In the aforementioned anatomical study with cadavers, Andreoli et al.²² safely used the superomedial portal, which is the same portal we used in our case series, thus demonstrating its reliable reproducibility. This portal is named Ejnisman’s portal.²³

According to the literature, the ideal duration of surgery is 30 minutes, and to avoid the occurrence of complications, the procedure should not last longer than 50 minutes, as reported by Andreoli et al.²² Those authors defined edema as a parameter for complications and categorized edema as follows: mild as localized swelling of the scapular region, however, allowing for visualization of the scapula contours; moderate as loss of the scapula contours; and severe as loss of the scapula contours and swelling extends to other regions such as the neck, inferior dorsal region, and contralateral side of the thoracic spine.²²

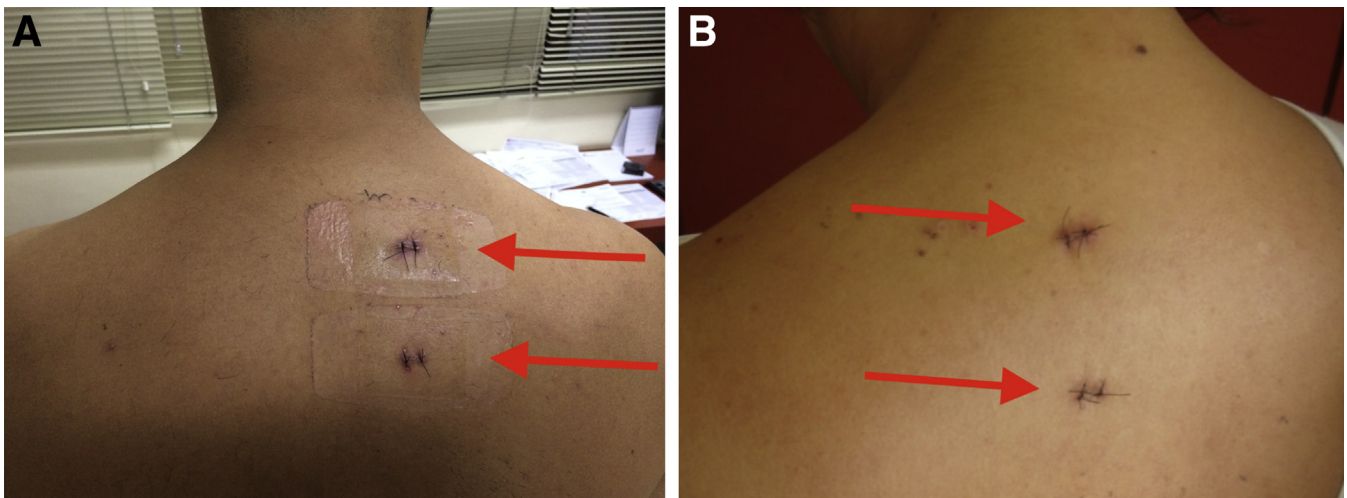


Fig 5. (A-B) Image of the 2 portals (red arrows) after surgery in the left scapula.

Millett et al.⁹ were not able to find any report of complications in the literature; nonetheless, arthroscopic techniques require additional training, and they emphasize that the technique is still under development. It is necessary to avoid the risk of neurovascular injury. In the present study by Andreoli et al. no case of neurovascular injury or thoracic penetration occurred.

Ejnisman's (superomedial) portal can be safely used, especially when the modified "chicken-wing" position is adopted, provided that the surgeon has mastery of the anatomy of the region targeted in the surgical procedure, as well as the surgical technique.

References

- Milch H. Snapping scapula. *Clin Orthop* 1961;20:139-150.
- Kibler WB. Snapping scapula. *Arthroscopy* 2010;26:299-300.
- Millett PJ, Gaskill TR, Horan MP, van der Meijden OA. Technique and outcomes of arthroscopic scapulothoracic bursectomy and partial scapulectomy. *Arthroscopy* 2012;28:1776-1783.
- Manske RC, Reiman MP, Stovak ML. Nonoperative and operative management of snapping scapula. *Am J Sports Med* 2004;32:1554-1565.
- Harper GD, McIlroy S, Bayley JI, Calvert PT. Arthroscopic partial resection of the scapula for snapping scapula: A new technique. *J Shoulder Elbow Surg* 1999;8:53-57.
- Chan BK, Chakrabarti AJ, Bell SN. An alternative portal for scapulothoracic arthroscopy. *J Shoulder Elbow Surg* 2002;11:235-238.
- Lehtinen JT, Macy JC, Cassinelli E, Warner JJ. The painful scapulothoracic articulation: Surgical management. *Clin Orthop Relat Res* 2004;423:99-105.
- Van Riet RP, Bell SN. Scapulothoracic arthroscopy. *Tech Shoulder Elbow Surg* 2006;7:143-146.
- Millett PJ, Pacheco IH, Gobeze R, Warner JJP. Management of recalcitrant scapulothoracic bursitis: Endoscopic scapulothoracic bursectomy and scapuloplasty. *Tech Shoulder Elbow Surg* 2006;7:200-205.
- Ciullo JV; Subscapular bursitis. Treatment of "snapping scapula" or "washboard syndrome. *Arthroscopy* 1992;8:412-413.
- Ruland LJ, Ruland CM, Matthews LS. Scapulothoracic anatomy for the arthroscopist. *Arthroscopy* 1995;11:52-56.
- Carlson HL, Haig AJ, Stewart DC. Snapping scapula syndrome: Three case reports and an analysis of the literature. *Arch Phys Med Rehabil* 1997;78:506-511.
- Nicholson GP, Duckworth MA. Scapulothoracic bursectomy for snapping scapula syndrome. *J Shoulder Elbow Surg* 2002;11:80-85.
- Pavlik A, Ang K, Coghlan J, Bell S. Arthroscopic treatment of painful snapping of the scapula by using a new superior portal. *Arthroscopy* 2003;19:608-612.
- Richards RR, McKee MD. Treatment of painful scapulothoracic crepitus by resection of the superomedial angle of the scapula. A report of three cases. *Clin Orthop Relat Res* 1989;247:111-116.
- Sisto DJ, Jobe FW. The operative treatment of scapulothoracic bursitis in professional pitchers. *Am J Sports Med* 1986;14:192-194.
- Percy EC, Birbrager D, Pitt MJ. Snapping scapula: A review of the literature and presentation of 14 patients. *Can J Surg* 1988;31:248-250.
- Saboeiro GR, Sofka CM. Imaging-guided treatment of scapulothoracic bursitis. *HSS J* 2007;3:213-215.
- Kumar N, Ramakrishnan V, Johnson GV, Southern S. Endoscopically-assisted excision of scapular osteochondroma. *Acta Orthop Scand* 1999;70:394-396.
- Fukunaga S, Futani H, Yoshiya S. Endoscopically assisted resection of a scapular osteochondroma causing snapping scapula syndrome. *World J Surg Oncol* 2007;5:37.
- Andreoli CV, Ejnisman B, Pochini AC, Monteiro GC, Cohen M, Faloppa F. Arthroscopy of scapulothoracic articulation. *Rev Bras Ortop* 2009;44:351-356.
- Andreoli C, Pochini A, Monteiro G, Ejnisman B, Cohen M, Faloppa F. Scapulothoracic articulation arthroscopy: A new patient positioning. *Eur Orthop Traumatol* 2011;2:127-132.
- Ejnisman B, Andreoli CV, Carvalho CD, Pochini AD. Image-guided scapulothoracic arthroscopy for removing firearm projectiles. *BMJ Case Rep* 2014 Dec 5 2014.
- Cole D, Ginn A, Smith A, Poehling GG. Scapulothoracic arthroscopy: Indications, review of literature, and report of 24 patients. *Arthroscopy* 2006;22:e8-e9.
- Lien SB, Shen PH, Lee CH, Lin LC. The effect of endoscopic bursectomy with mini-open partial scapulectomy on snapping scapula syndrome. *J Surg Res* 2008;150:236-242.
- Pearse EO, Bruguera J, Massoud SN, Sforza G, Copeland SA, Levy O. Arthroscopic management of the painful snapping scapula. *Arthroscopy* 2006;22:755-761.
- Proctor CS, Stanert K. Endoscopic removal of a bullet from the scapulothoracic space. *J Shoulder Elbow Surg* 2003;12:89-90.
- Van Riet RP, Van Glabbeek F. Arthroscopic resection of a symptomatic snapping subscapular osteochondroma. *Acta Orthop Belg* 2007;73:252-254.
- Berg EE, Ciullo JV. Arthroscopic debridement after intraarticular low-velocity gunshot wounds. *Arthroscopy* 1993;9:576-579.
- Cameron SE, Travis MT, Kruse RW. Foreign body arthroscopically retrieved from the elbow. *Arthroscopy* 1993;9:220-221.
- Goldman A, Minkoff J, Price A, Krinick R. A posterior arthroscopic approach to bullet extraction from the hip. *J Trauma* 1987;27:1294-1300.
- Haspl M, Bojanic I, Pecina M. Arthroscopic retrieval of metal foreign bodies from the knee joint after war wounds. *Injury* 1996;27:177-179.
- Jazrawi L, Egol KA, Astion DJ, Rose DJ. Arthroscopic removal of bullet fragments from the subtalar joint. *Arthroscopy* 1999;15:762-765.
- Nikolić D, Vulović R. Arthroscopy of the knee in war injuries. *Injury* 1996;27:175-176.
- Lehtinen JT, Tetreault P, Warner JJ. Arthroscopic management of painful and stiff scapulothoracic articulation. *Arthroscopy* 2003;19:E28.
- O'Holleran J, Millett P, Warner JJ. Arthroscopic management of scapulothoracic disorders. In: Miller M, Cole B, eds. *Textbook of arthroscopy*. Philadelphia: WB Saunders, 2004;277-287.