

Cone-beam computed tomography a reliable tool for morphometric analysis of the foramen magnum and a boon for forensic odontologists

Subhasish Mustafi,
Rupam Sinha,
Debarati Roy, Suman Sen,
Subhadeep Maity,
Pritha Ghosh

Department of Oral Medicine
and Radiology, Haldia Institute of
Dental Sciences and Research,
Haldia, West Bengal, India

Address for correspondence:

Dr. Subhasish Mustafi,
F-34/4, Karunamoyee Housing
Estate, Salt-Lake City, Sector-2,
Kolkata - 700 091, West Bengal,
India.
E-mail: subhasish2632@gmail.co

Abstract

Background/Aim: The aim of this pilot study was to perform morphometric analysis of the foramen magnum (FM) using cone-beam computed tomography (CBCT). **Materials and Methods:** This study included CBCT images of 120 individuals (60 males and 60 females). The sagittal and transverse diameters and circumference of the FM were measured. The data were statistically analyzed with Chi-square and *t*-tests to assess the level of significance for sex and age. **Results:** The means of its sagittal and transverse diameters and also circumference were higher in males than in females. Statistically significant differences were found between transverse and circumference in case of males and females for all variables ($P < 0.05$). No statistically significant difference ($P > 0.05$) was found in sagittal diameter and age groups for all variables. **Conclusion:** CBCT images can provide valuable information regarding FM and the measurements of its sagittal and transverse diameters and also its circumference may be reliably used for sexual dimorphism in anthropometric analysis and forensic medicine.

Key words: Cone-beam computed tomography, foramen magnum, forensic odontology, sex determination

Introduction

Clinical anatomists perform morphometric analyses of the cranium routinely because identification of anatomical structures is essential before several surgical procedures. Morphometric analysis of the cranium is also performed in case of skeletal identification and anthropological studies. Anthropologists can categorize individuals and populations via physical morphology of the head and face as well as age, sex, and race discrimination.^[1]

Skeletal identification which includes sex discrimination is a challenging task in forensic medicine and for forensic anthropology. Determination of sex is also crucially significant in the identification from unknown skeletal remains at the time of war, explosion, and mass disaster. This criterion is said to be important because it can help to dissolve and clarify legal and social issues.^[2,3] Different regions of the skeleton such as the pelvis, femur, and skull

Submitted: 02-May-19

Revised: 20-Mar-20


Accepted: 14-Apr-20

Published: 03-Jun-20

This is an open access journal, and articles are distributed under the terms of the Creative Commons Attribution-NonCommercial-ShareAlike 4.0 License, which allows others to remix, tweak, and build upon the work non-commercially, as long as appropriate credit is given and the new creations are licensed under the identical terms.

For reprints contact: WKHLRPMedknow_reprints@wolterskluwer.com

How to cite this article: Mustafi S, Sinha R, Roy D, Sen S, Maity S, Ghosh P. Cone-beam computed tomography a reliable tool for morphometric analysis of the foramen magnum and a boon for forensic odontologists. J Forensic Dent Sci 2019;11:153-7.

Access this article online	
Website: www.jfds.org	Quick Response Code 
DOI: 10.4103/jfo.jfds_42_19	

are used for sex identification. After the pelvis, the skull is the most vital portion of the skeleton for sexual determination, but the determination of the sex from the skull is not reliable until well after the puberty. The hard tissue composition of the craniofacial structures makes it relatively indestructible and makes it is one of the most vital portions of the human skeleton for sexual determination. Among various portions of the skull, the foramen magnum (FM) is one of the portion which helps forensic odontologists in sex discrimination.^[4-7]

The FM is a large opening in the base of the skull, it is oval, and it is wider behind, with the greatest diameter being anteroposterior. The transmission of key structures such as the lower end of the medulla oblongata, meninges, vertebral arteries, and the spinal accessory nerve through the FM makes FM as an important landmark in the region of the skull and spine. The FM is a wide communication between posterior cranial fossa and the vertebral canal.^[8,9] The surrounding features of the FM and location in the base of the skull place the FM in a favorable anatomical position, as it is covered by the soft tissue and the skeleton of the head that protects it from direct impact, thus preserving this area for forensic examination.^[10]

The instigation of cone-beam computed tomography (CBCT) specifically dedicated to imaging the maxillofacial region became a unique example of two-dimensional (2D) to a 3D approach to data acquisition and image reconstruction.^[11,12] CBCT as an imaging tool in dentistry has got varied clinical applications, one of which is viewing FM.^[13] The accuracy of measurement with CBCT is also commendable because there are negligible chances of superimposition and positioning errors. This relatively recently-developed technology is currently used to assess various cranial pathologies and anatomy. In the present scenario, preferred advantage of CBCT over conventional computed tomography (CT) in terms of less exposure, less scan time, and also cost-effectiveness led to speedy ingress into the field of dentistry with demand for the commitment of dental professional and dental educators to explore the applications of CBCT technology.^[14]

Materials and Methods

This retrospective study was carried out in the Department of Oral Medicine and Radiology at Haldia Institute Of Dental Sciences and Research, West Bengal, India. The study was designed to measure the dimensions of the FM for sexual dimorphism using CBCT. This study was submitted to and approved by the Committee for Ethics in Research. The initial material of the study comprised 120 CBCT images of the FM which were divided into two main groups which consisted of CBCT scans of 60 males and 60 females. Hence, when it is converted into percentage $[(60/100) \times 100 = 50\%]$, among total of 120 CBCT images of the FM, 50% of the CBCT images belong to male category and another 50% belong to female. The inclusion criteria of this study were CBCT scans of individuals with no history of trauma, surgery, or any other

pathological lesion (congenital/acquired) in the region of skull base, scans that were covering the entire extent of the FM, and individuals >18 years of age (stabilization of size of the FM occurs between 18 and 20 years). The occipital and sphenoid become united, forming a single bone). The exclusion criteria were low-quality images with blurring or artifacts caused by metallic objects, scans of individuals with a history of trauma, surgery, or any other pathological lesion (congenital/acquired) in the region of the skull base, scans that were not covering the entire extent of the FM, and patients who are <18 years of age.

The CBCT images were obtained using SkyView 3D CBCT machine, operating at 60 kVp, 9–14 mA, with a 0.3 mm × 0.3 mm × 0.6 mm voxel size, exposure time of 8 s, and a field of view of 8 cm.

Four independent observers (both experienced radiologists) blind to the details of age and sex of the patients used the digital image communication in medicine compatible iRYS multi-desktop 3D/2D image viewer software to analyze the images of FM. Observers were allowed to use twofold magnifications and modify screen brightness as well as scroll through the axial cross section.

The size of the FM in sagittal and transverse directions and also its circumference were measured on CBCT scans.

The following parameters were included in the study:

- Sagittal diameters or length of the FM: The maximum internal length of the FM along the mid-sagittal plane as the distance between the basion and opisthion.
- Transverse diameter or width of the FM: The maximum internal width of the FM perpendicular to the mid-sagittal plane as the greatest width of the FM.
- Circumference of the FM: Automatically given after tracing the bony margin of the FM on the CBCT image.

FM measurements (sagittal, transverse, circumference, and shape) were obtained from reformatted axial sections using CBCT scans.

Data analysis

The data obtained were statistically analyzed with the help of Epi Info™ 7.2.2.2 statistical software for epidemiology developed by Centers for Disease Control and Prevention (CDC) in Atlanta, Georgia (US). Using this software, the means with corresponding standard deviations of different variables were calculated *t*-test was used to test the significant difference between means. $P < 0.05$ was considered statistically significant.

Results

After statistical analysis, the following results which are represented in tables and graphs were obtained.

In a total 120 individuals, 60 females (50%) and 60 males (50%) were examined [Table 1 and Figure 1]. For each measurement, sagittal diameter, transverse diameters, and

the circumference of the FM were calculated in both males and females, with the maximum and minimum diameters, mean values, and standard deviations. Regarding the age group, though the mean age of the males was higher than that of the females, there was no statistically significant difference found in the mean age of the males and females because the value of *P* was found to be 0.092 [Table 2 and Figure 2]. This *P* value was constant for all other four observers.

All measurements including the means of sagittal and transverse diameters and circumference of the FM were greater in males than in females. Statistically significant differences were found between males and females for transverse diameter and circumference. The mean transverse diameter of males was significantly higher than that of the females because the value of *P* was found to be 0.023 [Table 3 and Figure 3]. The mean circumference of males was significantly higher than that of the females because the value of *P* was found to be 0.005 [Table 4 and Figure 4]. Although the mean sagittal diameter of the males was higher than that of the females, there was no significant difference found in the mean sagittal diameter of the males and females because the value of *P* was found to be 0.189 [Table 5 and Figure 5]. The value of *P* < 0.05 was considered statistically significant and it was kept constant for denoting statistical significance in case of all the parameters.

Similarly, all the other four observers cross-checked 120 CBCT images and measured the sagittal diameter, transverse diameters, and the circumference of the FM individually. Statistical significant differences were found by them also between males and females for transverse diameter and circumference. The mean transverse diameter of males was significantly higher than that of the females because the value of *P* value was found to be 0.023, 0.021, 0.020, and 0.025, respectively, by all other four observers with a mean *P* = 0.02.

The other four observers also found the statistical significant difference in case of circumference measurement because the value of *P* was found to be 0.003, 0.001, 0.006, and 0.002,

respectively, with a mean *P* value of 0.003. No changes in measurement were found by other four observers in case of sagittal diameter measurement. The mean sagittal diameter of the males was higher than that of the females; there was no significant difference found in the mean sagittal diameter of the males and females because the value of *P* was found to be 0.189 and this reading was the same for all the other four observers.

Discussion

CBCT is an absolutely recent imaging technology used to create 3D interpretations of subjects. After the introduction of CBCT, unparalleled abilities to maxillofacial imaging

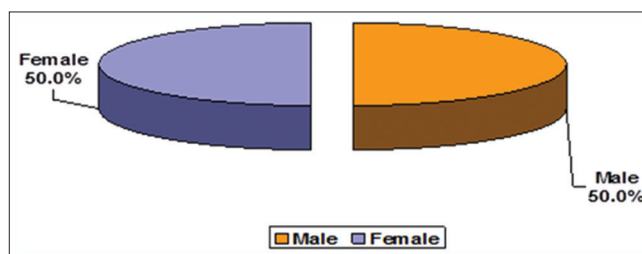


Figure 1: Distribution of the gender in a total sample size

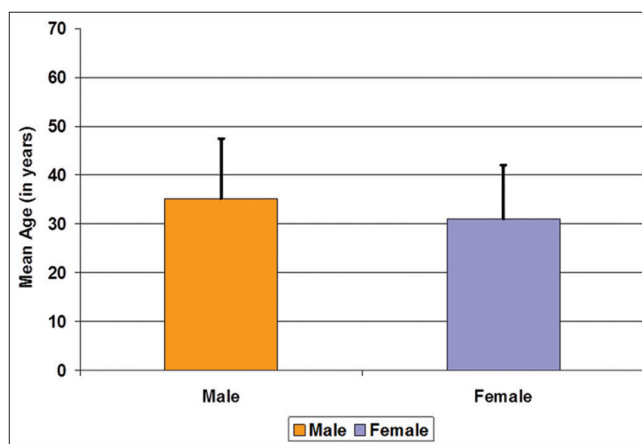


Figure 2: Comparison of the mean age of the males and females

Table 1: Distribution of the gender in total sample size

Group	n (%)
Male	60 (50.0)
Female	60 (50.0)
Total	120 (100.0)

Out of the 120 individuals 60 (50.0%) were males and the rest 60 (50.0%) were females

Table 2: Comparison of the mean age of the males and females

Age (years)	Male (n=60)	Female (n=60)	Test statistic (<i>t</i> ₁₁₈)	<i>P</i>
Mean ± SD	35.10 ± 12.36	31.00 ± 11.04	1.707	0.092
Median	32.00	28.00		(NS)
Range	19-61	16-61		

Although the mean age of the males was higher than that of the females, there was no significant difference in the mean age of the males and females (*t*₁₁₈ = 1.707; *P* = 0.092). NS: Statistically not significant, SD: Standard deviation

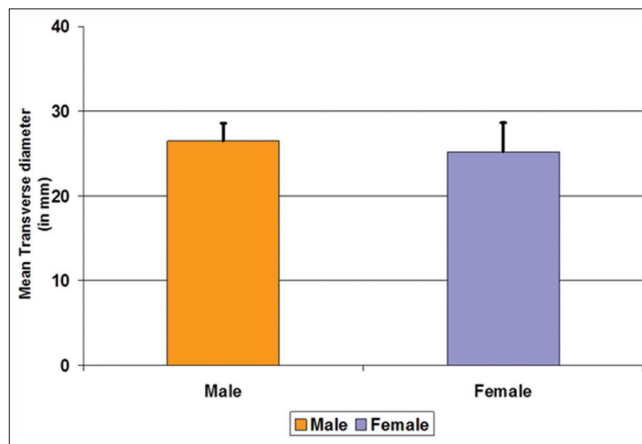


Figure 3: Comparison of the mean transverse diameter of males and females

Table 3: Comparison of the mean transverse diameter of the males and females

Transverse diameter (mm)	Male (n=60)	Female (n=60)	Test statistic (t_{118})	P
Mean±SD	26.48±2.10	25.21±3.42	2.305	0.023
Median	26.80	24.95		
Range	21.1-30.8	18.3-38.0		

The mean transverse diameter of males was significantly higher than that of the females ($t_{118}=2.305$; $P=0.023$). SD: Standard deviation

Table 4: Comparison of the mean circumference of males and females

Circumference (mm)	Male (n=60)	Female (n=60)	Test statistic (t_{118})	P
Mean±SD	100.26±9.01	95.04±9.05	2.854	0.005 (S)
Median	97.70	93.80		
Range	86.6-125.4	63.8-113.8		

The mean circumference of males was significantly higher than that of the females ($t_{118}=2.854$; $P=0.005$). S: Statistically significant, SD: Standard deviation

Table 5: Comparison of the mean sagittal diameter of the males and females

Sagittal diameter (mm)	Male (n=60)	Female (n=60)	Test statistic (t_{118})	P
Mean±SD	30.87±3.06	30.03±3.23	1.325	0.189 (NS)
Median	30.60	29.50		
Range	25.7-44.8	16.3-38.3		

Although the mean sagittal diameter of the males was higher than that of the females, there was no significant difference in the mean sagittal diameter of the males and females ($t_{118}=1.325$; $P=0.189$). NS: Statistically not significant, SD: Standard deviation

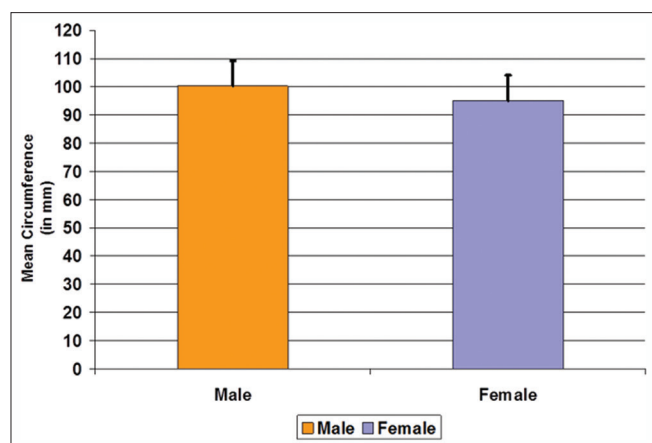


Figure 4: Comparison of the mean circumference of the males and females

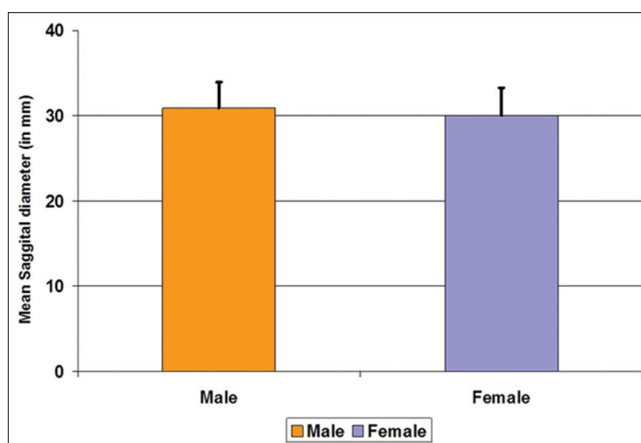


Figure 5: Comparison of the mean sagittal diameter of males and females

emerged, immensely expanding the role of imaging within diagnostics and treatment. The benefits of good image quality, volumetric analysis, short scan time, and relatively less radiation dose than conventional medical CT have resulted in greater ubiquity as an imaging modality within all disciplines of dentistry. Many fields including periodontics oral surgery, implant dentistry, periodontics, and endodontics find the unique ability of the 3D reconstructions provided by CBCT.^[15]

The FM is an important position of the skull base and is of particular interest in anthropology, anatomy, forensic medicine, and other medical fields. 3D digital imaging capability of a CBCT machine provides accurate and reliable linear measurements for reconstruction and imaging of dental and maxillofacial structures.

The present study has been engrossed in determining the sexual dimorphism of the FM using CBCT. The present study

was conducted in the Department of Oral Medicine and Radiology, Haldia Institute of Dental Sciences and Research.

In the present study, a total of 120 individuals were included in the study. To avoid gender bias, 120 individuals were divided into two equal groups, 60 (50.0%) were males and the rest 60 (50.0%) were females.

The present study gives favorable results in accordance to the studies conducted by Catalina-Herrera *et al.*,^[16] Uysal *et al.*,^[17] and Uthman *et al.*,^[18] Radhakrishna *et al.*,^[19] Jain *et al.*,^[20] and Roma Patel.^[21] In all the mentioned studies, sexual dimorphism of the FM was found positive, while some studies done by Kanchan *et al.*^[22] and Shepur *et al.*^[23] have stated that the FM does not show sexual dimorphism. Their study result suggested that the dimensions of the FM and its area are not a very reliable indicator in the estimation of the sex of an unknown skull.

Regarding transverse diameter and circumference measurement aspect, the present study gives favorable results in accordance to the studies conducted by Uysal *et al.*,^[17] Uthman *et al.*,^[18] Murshed *et al.*,^[24] Abdel-Karim *et al.*,^[25] and Akay *et al.*^[4] In case of all the above-mentioned studies, the mean transverse diameter and circumference of FM was found to be significantly higher in males than that of the females. In the current study also, the mean transverse diameter and circumference of FM of males was significantly higher than that of the females with *P* value 0.023 and 0.005, respectively. Hence, it shows that CBCT images can provide valuable information regarding FM, and the measurements of its transvers diameters and also its circumference may be reliably used for sexual dimorphism in anthropometric analysis and forensic medicine.

Regarding the sagittal diameter, the result of the present study differs from the study conducted by Uysal *et al.*,^[18] Uthman *et al.*,^[19] Murshed *et al.*,^[24] Abdel-Karim *et al.*,^[25] and Akay *et al.*^[5] because in the present study, though the mean sagittal diameter of the males was higher than that of the females, there was no statistical significant difference found in the mean sagittal diameter of the males and females because the value of *P* was found to be 0.189. The value of *P* < 0.05 was considered statistically significant. These observations reported in the present study vary from the observations reported by other researchers which may be caused by different population groups or due to different methodologies employed.

Conclusion

Considering the high sex predictability of FM dimensions in the present study and the studies preceding it, the foramen measurements can be used to supplement other sexing evidence available to precisely ascertain the sex of the skeleton. The 3D digital imaging capability of a CBCT machine provides accurate and reliable linear measurements for reconstruction and imaging of dental and maxillofacial structures. The accuracy of measurement with CBCT is also commendable because there are negligible chances of superimposition and positioning errors. CBCT is now a newer modality which came into existence in the present scenario and is better than CT in terms of less exposure, less scan time required, and also cost-effectiveness. Based on these advantages and qualities, CBCT can be a reliable tool in the morphometric analysis of FM and can be a better modality to study sexual dimorphism.

Financial support and sponsorship

Nil.

Conflicts of interest

There are no conflicts of interest.

References

- Kanchan T, Krishan K, Gupta A, Acharya J. A study of cranial variations based on craniometric indices in a South Indian population. *J Craniofac Surg* 2014;25:1645-9.
- Holland TD. Use of the cranial base in the identification of fire victims. *J Forensic Sci* 1989;34:458-60.
- Günay Y, Altinkök M. The value of the size of foramen magnum in sex determination. *J Clin Forensic Med* 2000;7:147-9.
- Akay G, Güngör K, Peker İ. Morphometric analysis of the foramen magnum using cone beam computed tomography *Turk J Med Sci* 2017;47:1715-22.
- Kamath VG, Asif M, Shetty R, Avadhani R. Binary Logistic Regression Analysis of Foramen Magnum Dimensions for Sex Determination. *Anat Res Int* 2015;2015:459428.
- Gamba Tde O, Alves MC, Haiter-Neto F. Mandibular sexual dimorphism analysis in CBCT scans. *J Forensic Leg Med* 2016;38:106-10.
- Tambawala SS, Karjodkar FR, Sansare K, Prakash N. Sexual dimorphism of maxillary sinus using cone beam computed tomography. *Egypt J Forensic Sci* 2015;6:120-e125.
- Nayak G, Das S R. A morphometric study of foramen magnum. *IJSR* 2017;6:31-2.
- Gruber P, Henneberg M, Böni T, Rühli FJ. Variability of human foramen magnum size. *Anat Rec (Hoboken)* 2009;292:1713-9.
- Krogman WM. The human skeleton in forensic medicine. *I. Postgrad Med* 1955;17:A-48.
- Scarfe WC, Farman AG. What is cone-beam CT and how does it work? *Dent Clin North Am* 2008;52:707-30, v.
- Isaza J, Díaz CA, Bedoya JF, Monsalve T, Botella MC. Assessment of sex from endocranial cavity using volume-rendered CT scans in a sample from Medellín, Colombia. *Forensic Sci Int* 2014;234:186.e1-10.
- Jaju PP, Jaju SP. Clinical utility of dental cone-beam computed tomography: Current perspectives. *Clin Cosmet Investig Dent* 2014;6:29-43.
- Jaitley M, Phulambrikar T, Kode M, Gupta A, Singh SK. Foramen magnum as a tool for sexual dimorphism: A cone beam computed tomography study. *Indian J Dent Res* 2016;27:458-62.
- Scarfe WC, Farman AG. What is cone-beam CT and how does it work? *Dent Clin North Am* 2008;52:707-30, v.
- Catalina-Herrera CJ. Study of the anatomic metric values of the foramen magnum and its relation to sex. *Acta Anat (Basel)* 1987;130:344-7.
- Uysal S, Gokharman D, Kacar M, Tuncbilek I, Kosa U. Estimation of sex by 3D CT measurements of the foramen magnum. *J Forensic Sci* 2005;50:1310-4.
- Uthman AT, Al-Rawi NH, Al-Timimi JF. Evaluation of foramen magnum in gender determination using helical CT scanning. *Dentomaxillofac Radiol* 2012;41:197-202.
- Radhakrishna SK, Shivarama CH, Ramakrishna A, Bhagya B. Morphometric analysis of foramen magnum for sex determination in South Indian population. *Nitte Univ J Health Sci* 2012;2:20-2.
- Jain SK, Choudhary AK, Mishra P. Morphometric evaluation of foramen magnum for sex determination in a documented North Indian sample. *J Evol Med Dent Sci* 2013;2:8093-8.
- Patel R, Mehta CD. Morphometric study of foramen magnum at the base of human skull in South Gujarat. *IOSR-JDMS* 2014;13:23-5.
- Kanchan T, Gupta A, Krishan K. Craniometric analysis of foramen magnum for estimation of sex. *Int J Med Health Biomed Pharm Eng* 2013;7:111-3.
- Shepur MP, Magi M, Nanjundappa B, Havaladar PP, Gogi P, Saheb SH. Morphometric analysis of foramen magnum. *Int J Anat Res* 2014;2:249-55.
- Murshed KA, Çiçekbaşı AE, Tuncer I. Morphometric evaluation of the foramen magnum and variations in its shape: A study on computerized tomographic images of normal adults. *Turk J Med Sci* 2003;33:301-6.
- Abdel-Karim RI, Housseini AM, Hashish RK. Adult sex estimation using three dimensional volume rendering multislice computed tomography of the foramen magnum and occipital condyles: A study in Egyptian population. *Int J Adv Res* 2015;3:1212-5.