

ORIGINAL ARTICLE

Reconstruction of fully shaped fingers using a free great toe nail flap combined with a second toe tissue flap

Chengcai Hou¹ | Aiping Zhang² | Xiuyue Yu² | Hui Han¹

¹Department of Hand, Foot and Ankle Surgery, Zaozhuang Municipal Hospital, Zaozhuang, China

²First Department of Surgery, Yicheng District Hospital of Traditional Chinese Medicine, Zaozhuang, China

Correspondence

Chengcai Hou, Department of Hand, Foot and Ankle Surgery, Zaozhuang Municipal Hospital, 41 Longtou Middle Road, Zaozhuang, Shandong 277100, China.
Email: houchengcai333@163.com

Abstract

To explore the clinical outcome of a free great toe nail flap (GTNF) combined with a second toe tissue flap (STTF) for fully shaped finger reconstruction (FSFR). From January 2013 to January 20, 2019, patients with finger defects underwent finger reconstruction using free GTNF combined with an STTF. All 20 fully shaped, reconstructed fingers survived without complications. The average follow-up time was 44.4 months (range 12-60 months). The reconstructed fingers had better function and appearance. The length of the fingers was close to normal, and the joint positions were normal. The fingers were able to extend -15° to -5° and flex 40° to 85° . The reconstructed fingers had no pain or numbness, and the function of the feet was restored well. The reconstruction of fully shaped fingers using GTNF combined with an STTF results in better function and appearance. This surgical method is worthy of promotion. This article introduces a new surgical method that is related to finger reconstruction. Finger defects bring psychological and functional regrets to patients and their families. Through this operation, the reconstructed finger is more perfect in appearance and function. I think this technology is very effective and worth promoting.

KEYWORDS

finger, free transplantation, fully shaped reconstruction, great toe nail flap, second toe

Key Messages

- the reconstructed fingers are more perfect in function, and the angle of flexion and extension of the fingers can be within the normal range, which can meet the needs of daily work and life
- the reconstructed fingers are more beautiful in appearance, which overcomes the shortcomings of short fingers after reconstruction in the past
- it is proposed for the first time in the article that two sets of blood supply systems should be anastomosed, which improves the success rate of the operation compared with the previous series anastomoses

Abbreviations: FSFR, fully shaped finger reconstruction; GTNF, great toe nail flap; PIP, proximal interphalangeal joint; SIPJ, second interphalangeal joint; STTF, second toe tissue flap.

This is an open access article under the terms of the [Creative Commons Attribution-NonCommercial-NoDerivs](https://creativecommons.org/licenses/by-nc-nd/4.0/) License, which permits use and distribution in any medium, provided the original work is properly cited, the use is non-commercial and no modifications or adaptations are made.

© 2021 The Authors. *International Wound Journal* published by Medicalhelplines.com Inc (3M) and John Wiley & Sons Ltd.

- the toe can retain part of the nail to increase the aesthetics of the toe
- all the toes can be kept

1 | INTRODUCTION

With developments in microsurgery and medicine, various finger reconstruction techniques have been developed. However, each technique has limitations, including the following: (a) simple toe transplantation and reconstruction of the finger is not aesthetically pleasing; (b) false fingers can physically replace fingers but not sensory-motor function¹; (c) wraparound flaps result in a good appearance but lack a joint²; (d) connected bilateral second toes for long finger reconstruction are associated with poor functionality and appearance³; and (e) ray amputation is usually a good approach for amputation through the base of the proximal phalanx, but it results in a narrow palm and decreases grip strength.⁴

Corbett first reported a technique for thumb reconstruction in 1969.⁵ Morrison reported the use of nail flaps to reconstruct fingers in 1980.⁶ For finger defects, free second toe transplantation was used in the past to reconstruct the thumb,⁷ but the appearance and function were

not satisfactory for patients. Foucher et al introduced a twisted-toe technique in 1980 that involved the creation of a partial onychocutaneous flap from the great toe and the osteotendinous portion of the second toe to create a “custom-made” distal finger.⁸ Yu and He⁹ and Tsai and Aziz¹⁰ described the use of a wraparound flap from the great toe and the vascularized joint from the second toe for thumb reconstruction. This technology combines the nail flap and the second interphalangeal joint (SIPJ) to improve the appearance and function of the reconstructed finger.

From January 2013 to January 2019, we used a free great toe nail flap (GTNP) combined with a second toe tissue flap (STTF) to reconstruct the finger and achieved excellent clinical results.

2 | PATIENTS AND METHODS

In this group of 20 patients with finger defects, including 14 males and 6 females, a free nail flap combined with an

No.	Sex	Age, y	Diagnosis	Type of operation
1	Male	28	Left ring finger	Finger reconstruction
2	Female	34	Left thumb	Finger reconstruction
3	Female	25	Left thumb	Finger reconstruction
4	Male	26	Left ring finger	Finger reconstruction
5	Male	32	Left index finger	Finger reconstruction
6	Male	28	Right little finger	Finger reconstruction
7	Female	27	Right middle finger	Finger reconstruction
8	Male	39	Left index finger	Finger reconstruction
9	Male	44	Right thumb	Finger reconstruction
10	Female	26	Right thumb	Finger reconstruction
11	Female	30	Right middle finger	Finger reconstruction
12	Male	24	Left middle finger	Finger reconstruction
13	Male	40	Right thumb	Finger reconstruction
14	Female	36	Left thumb	Finger reconstruction
15	Male	38	Right thumb	Finger reconstruction
16	Male	30	Left index finger	Finger reconstruction
17	Male	33	Left ring finger	Finger reconstruction
18	Male	26	Right index finger	Finger reconstruction
19	Male	31	Left little finger	Finger reconstruction
20	Male	24	Left ring finger	Finger reconstruction

TABLE 1 Comparison of the preoperative

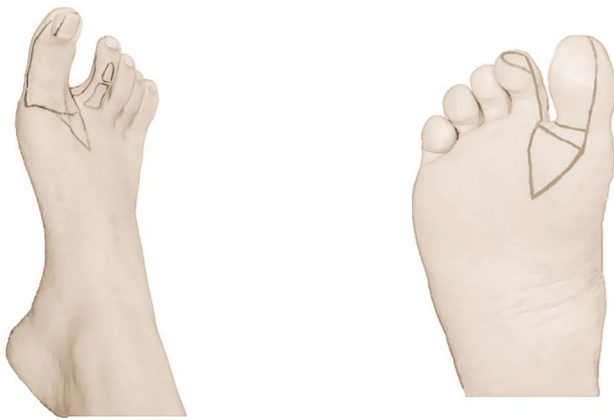

FIGURE 1 Design of the skin flap on the donor foot: nail flap designed on the back of the toe and on the sole of the foot and interphalangeal joint marked on the second toe

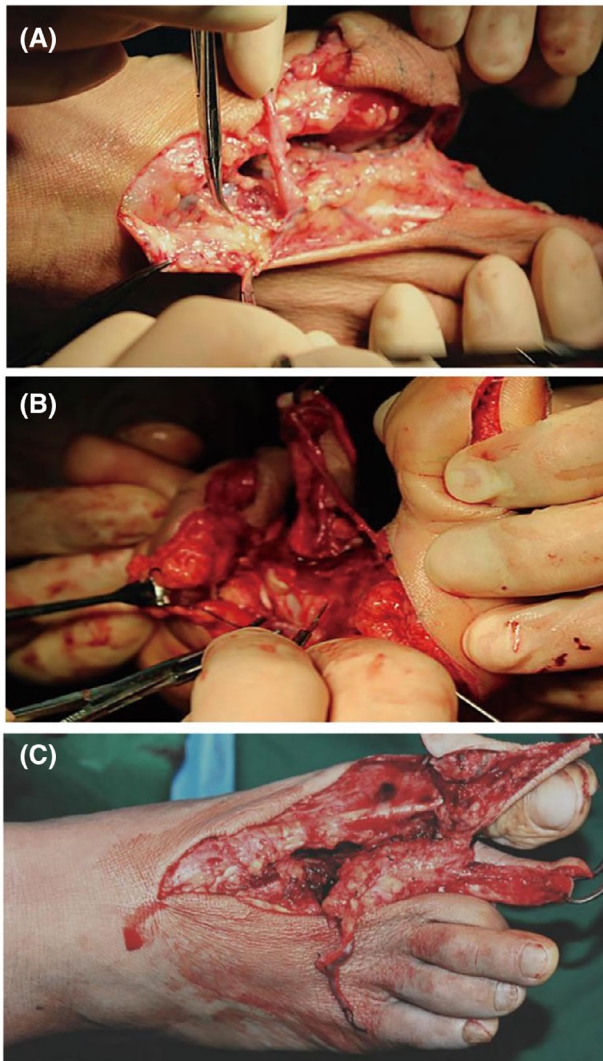


FIGURE 2 Image A shows the dorsal foot, dorsal metatarsal, and dorsal toe arteries and veins. Image B shows plantar nerves and tendons. Image C shows the cut in the middle of the metatarsal bone and the second interphalangeal joint

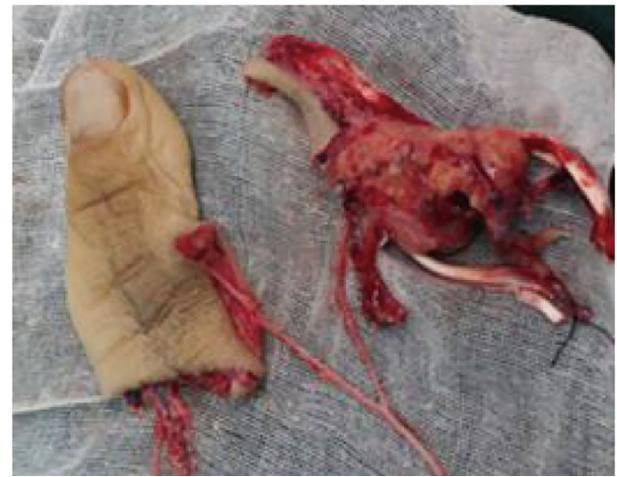

FIGURE 3 The great toe nail flap is on the left, including the toenail and the distal phalanx, the dorsal metatarsal artery vein, and the great toe fibular side artery nerves. On the right is the second interphalangeal joint, the second toe tibial side artery nerves, and the flexor and extensor toe tendons. The middle artery is an anastomosis of the fibular artery of the great toe and the tibial side artery of the second toe

STTF was used to reconstruct the affected finger. The average age of the patients was 31 years (range 24-44 years). The finger defects were a result of machine strangulation (n = 12), crush injury (n = 5), and necrosis after replantation of the thumb (n = 3). Our institutional review board approved the study, and all patients provided informed consent (Table 1).

2.1 | Surgical technique

Wound treatment: If the skin contracture was obvious, the skin was cut on the back of the hand and palm, the cephalic vein was dissected, and the area of the hand skin defect was measured.

2.2 | Flap design

A comprehensive preoperative assessment was performed, and a personalized reconstruction plan was developed for each patient. The following parameters of the contralateral finger were measured: finger circumference (taken at the mid-lines of the proximal and middle phalanx, the proximal interphalangeal [PIP] joint, and the nail eponychium), joint position, nail width, and defect length. The skin flap was designed, and the outline was drawn on the donor (Figure 1).

2.3 | Cut skin flap

According to the measurement parameters of the unaffected finger, the GTNF and second phalanx incision line were drawn on the back of the foot, great toe, and second toe. The GTNF was designed on the back of the foot, the triangular skin flap was designed at the proximal end, and the skin was cut in an arc. The dorsum of the foot and dorsal metatarsal veins were freed, followed by the dorsum of the foot, the first metatarsal dorsal, the fibular side of the great toe, and the tibial side floor of the second toe (Figure 2). Removal of the great toe fibular side nail flap with part of the terminal phalanx was completed. The second toe was then incised from the mid-line of the tibial side. The tibial side of the vascular nerve was preserved on the phalanx, the vascular nerve of the second metatarsophalangeal joint was preserved, and the distal interphalangeal joint of the second toe remained in situ, which was cut off from the proximal metatarsophalangeal joint at approximately 3 cm. The metatarsophalangeal joint and the second phalanx were retained, and the first common plantar nerve at the

proximal end of the toe was freed and separated from the proximal end. A sufficient amount of the flexor digitorum and extensor digitorum longus tendon was removed as well (Figure 3). To prevent the blood vessels from rotating and twisting, the blood vessels were ligated between the first and second toe webs. The nail flap is supplied by the proper fundus arteries, and the second toe, metatarsophalangeal joints, and tendon system are supplied by the first dorsal metatarsal artery system.

2.4 | Construction of the compound flap

The second phalanx was wrapped with the distal phalanx, and the distal phalanx was fused to the middle of the second phalanx. The two phalanges were sutured and fixed to form a reconstructed thumb, and the metacarpal and metatarsal bones were connected, fixed, and fused with Kirschner wires in an abducted and opposing position. Once the position of the fluoroscopic view was good, the Kirschner wires were fixed to place the finger in extension. The long flexor tendon of the thumb and the

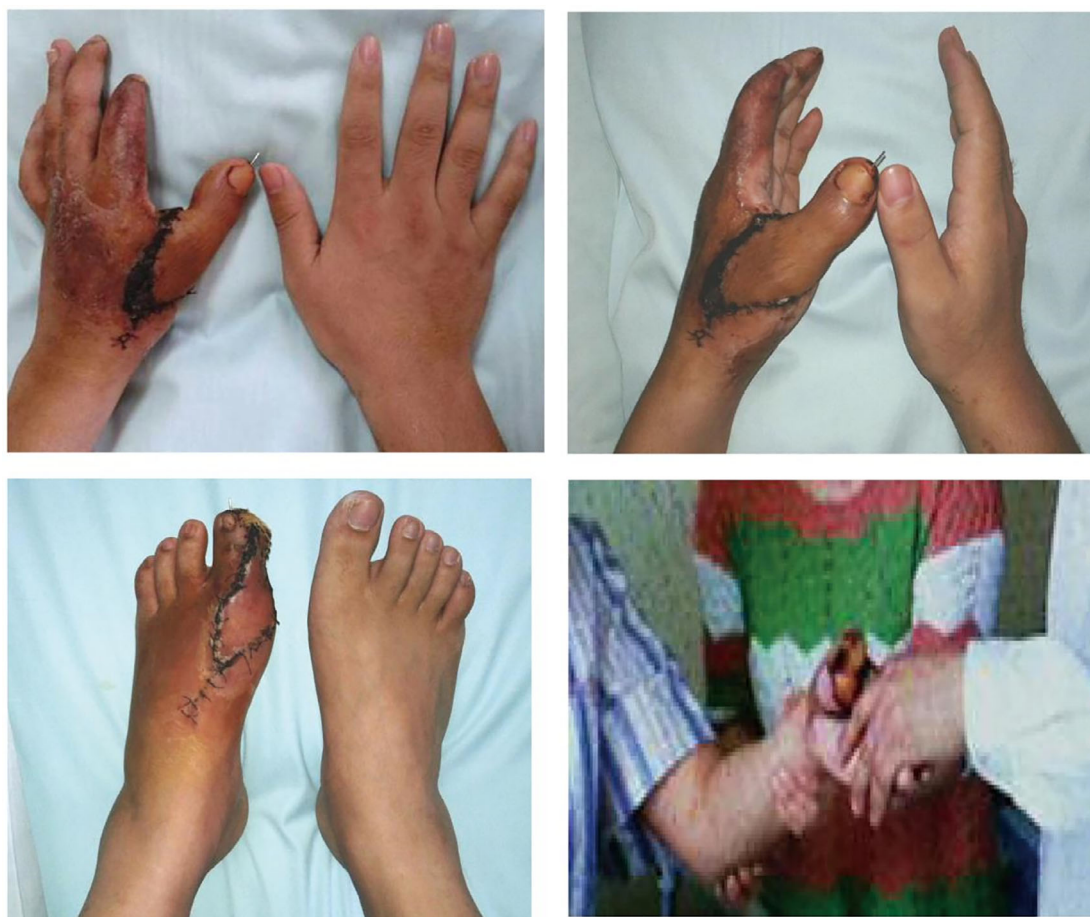

FIGURE 4 The top two images are postoperative photographs, the bottom left is a photograph of the donor foot, and the bottom right is a photograph of a patient shaking hands

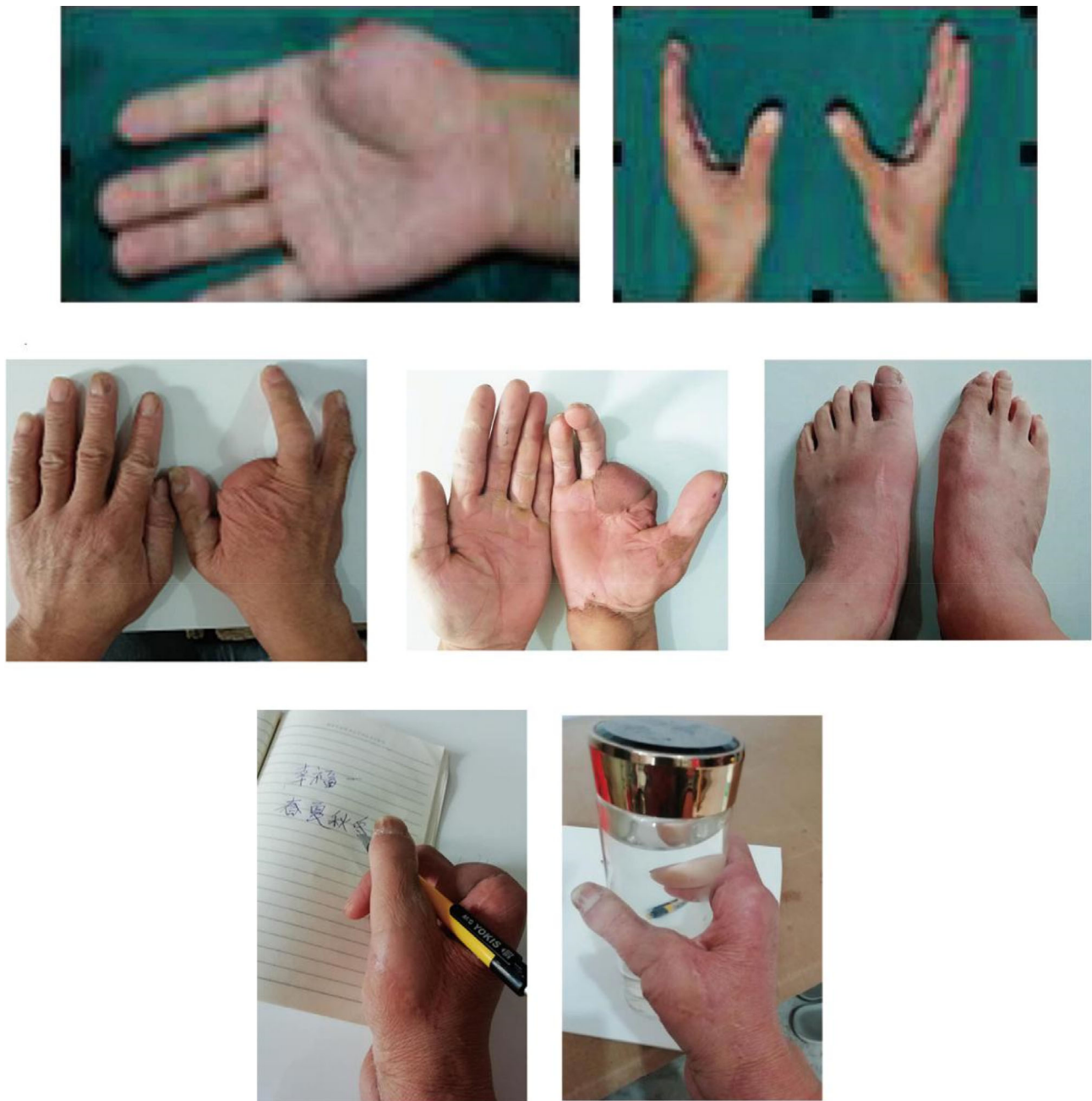

FIGURE 5 The upper two photographs were taken 2 years after thumb reconstruction; the middle three photographs were taken 3 years after thumb reconstruction upon re-examination, including both hand and donor site images; and the lower two photographs show that the right hand can write normally and pick up a teacup

toe long flexor tendon were sutured, followed by the long extensor tendon of the thumb and long extensor tendon of the toe. The dorsal foot flap was used to cover the skin defect. The nail flap nerve and second toe nerve were anastomosed with the proper thumb nerve, the great toe fibular side artery and the proper finger artery were anastomosed, the second toe artery and the branch of the radial artery were anastomosed, and the nail flap vein and dorsal hand vein were anastomosed (A:V = 1:2). The second toe vein was anastomosed with the dorsal hand

vein (A:V = 1:1), the peroneal nerve of the great toe was anastomosed with the finger propria nerve, and the tibial side nerve of the second toe was anastomosed with the superficial branch of the radial nerve. Once the fingertips of the reconstructed fingers were rosy and the skin flaps had a good blood supply, postoperative management involved heat preservation, immobilization, and symptomatic treatment; bed rest for 1 week; close monitoring of the blood circulation of the reconstructed fingers; active and passive functional exercises for the

reconstructed fingers for 3 weeks after the operation; and plaster cast removal 4 weeks after the operation with internal fixation for active and passive functional training.

2.5 | Results

All 20 cases of fully shaped, reconstructed fingers survived without complications. The average follow-up time was 44.4 months (range 12-60 months). The reconstructed fingers had better outcomes in function and appearance, with their length and joint position close to normal. Range of motion: extension of -15° to -5° and flexion of 40° to 85° . The reconstructed fingers had no pain or numbness, and the donor sites recovered function well (Figures 4 and 5) (Table 2).

3 | DISCUSSION

Humankind has an increasing pursuit of beauty, and the length, appearance, joint movement, and sensation of reconstructed fingers should be the primary considerations for surgery. Currently, there are many ways to

reconstruct finger defects, and the surgical method varies between surgeons. The most suitable method should be selected according to the needs of the patient. If the surgical method is not appropriate, the results will not be ideal. For example, in 1966, Professor YudongGu successfully implemented the world's first second toe transplantation reconstruction, but the finger's appearance and function were not ideal after toe transplantation alone. In 1983, Professor Zhongjia Yu successfully completed bilateral toe reconstruction, which was reproducible. The fingers failed to achieve patient satisfaction. According to our clinical experience, the surgical method of reconstructing the finger with the nail flap and the SIPJ results in a finger that is recognizable and satisfactory to the patient, with good clinical evaluation results. This approach has many advantages: (a) the reconstructed finger looks more natural and feels better, with better function; (b) the ideal combination of an interphalangeal joint and metacarpophalangeal joint can attain 90% of normal finger movement; (c) the operation can be completed at one time, shortening the course of disease and reducing the pain of the operation; and (d) the donor site is less damaged.

During the operation, the following points should be considered: (a) When designing the great nail flap, the nail should be 2 mm wider than the contralateral side,

TABLE 2 Comparison of the preoperative findings

No.	Anaesthesia	Alive	Time of follow-up, mo	Range of motion, deg	Second operation
1	General	Yes	48	0 to 60	No
2	General	Yes	46	-5 to 55	No
3	General	Yes	60	5 to 50	No
4	General	Yes	22	0 to 75	No
5	General	Yes	21	-5 to 75	No
6	General	Yes	12	-5 to 60	No
7	General	Yes	36	-10 to 80	No
8	General	Yes	28	-15 to 50	No
9	General	Yes	26	0 to 45	No
10	General	Yes	50	-5 to 85	No
11	General	Yes	56	0 to 75	No
12	General	Yes	52	5 to 80	No
13	General	Yes	60	0 to 50	No
14	General	Yes	48	-5 to 70	No
15	General	Yes	56	0 to 40	No
16	General	Yes	42	-5 to 45	No
17	General	Yes	40	0 to 65	No
18	General	Yes	50	-5 to 60	No
19	General	Yes	42	0 to 55	No
20	General	Yes	41	-5 to 60	No

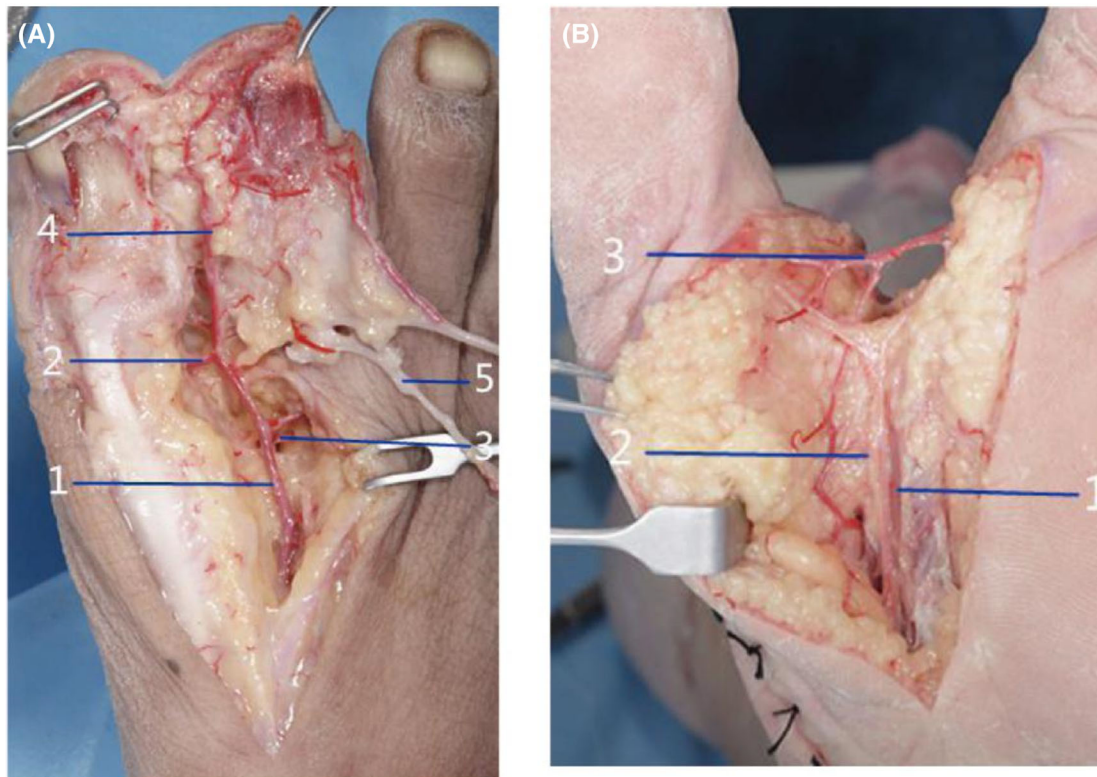


FIGURE 6 (A) 1 Dorsal metatarsal artery, 2 Hallux transverse artery, 3 Second toe tibial side artery, 4 Hallux fibular side artery, 5 Dorsal foot vein. (B) 1 Artery in the sole of the first toe, 2 Nerve in the sole of the first toe, 3 Intersection of the hallux fibular side artery and second toe tibial side artery

which can make the nail more aesthetic, and the proximal end of the flap should be triangular in shape to prevent the vascular pedicle from being compressed and scarring. The flap should be 7 mm wider and 7 mm longer than the corresponding healthy finger to prevent finger atrophy from affecting appearance. (b) The toenail, nail bed, and distal phalanx can be cut together, which is conducive to fixation of the blood supply of the toenail and bone support. (c) The tongue flap is left on the plantar side of the toe to allow better weight bearing. (d) Reconstruction of sensation can be achieved by anastomosis of the plantar nerve and the proper finger nerve. (e) After the first dorsal metatarsal artery and the first common plantar artery intersect, two branches are issued to supply the nail flap and the SIPJ (Figure 6). After cutting, the nail flap and the SIPJ are combined, and the vascular pedicle can easily rotate 360°. This leaves it prone to vascular crisis, the prevention of which is the key to the success of the operation. According to our experience, the arteries of the nail flap and the SIPJ should be ligated, disconnected, and divided into two sets of blood supply systems, which should be anastomosed to the proper digital artery and superficial branch of the radial artery to increase the survival rate of the transplant; the vein should be treated in the same manner.

The reconstruction of a fully shaped finger described in this article broadens the vision for finger reconstruction, overcoming the limitations of simple toe transplantation. While it requires meticulous operation and teamwork, the method yields a successfully reconstructed finger with good range of motion and normal appearance; thus, it is worthy of promotion.

DATA AVAILABILITY STATEMENT

All data provided in the text are true and reliable, hereby declare.

REFERENCES

1. Elbeshbeshy B, Paksima N. Post-traumatic thumb reconstruction. *Bull Hosp Jt Dis.* 2001;60:130-133.
2. Hofer SOP, Cronin KJ, Morrison WA. A long-term study of ring finger transfer in the reconstruction of transmetacarpal amputations. *J Hand Surg Am.* 2002;27:1087-1094.
3. Wei FC, Chen HC, Chuang CC, Noordhoff MS. Reconstruction of the thumb with a trimmed-toe transfer technique. *Plast Reconstr Surg.* 1988;82:506-515.
4. Peimer CA, Wheeler DR, Barret A, Goldschmidt PG. Hand function following single ray amputation. *J Hand Surg Am.* 1999;24:1245-1248.
5. Cobbett JR. Free digital transfer. Report of a case of transfer of a great toe to replace an amputated thumb. *J Bone Joint Surg Br.* 1969;51:677-679.

6. Morrison WA, O'Brien BM, Maeleod AM. Thumb reconstruction with a free neurovascular wrap-around flap from the big toe. *J Hand Surg Am*. 1980;5(6):575-583.
7. Yang D, Minming W, Yudong G. A report of 40 cases of thumb reconstruction with free second toe transplantation. *Chin J Surg*. 1977;15(1):13-15.
8. Foucher G, Merle M, Maneaud M, Michon J. Microsurgical free partial toe transfer in hand reconstruction: a report of 12 cases. *Plast Reconstr Surg*. 1980;65:616-627.
9. Yu ZJ, He HG. Thumb reconstruction with free big toe skin-nail flap and bones, joints, and tendons of the second toe—report of the cases. *Chin Med J*. 1985;98:863-867.
10. Tsai TM, Aziz W. Toe-to-thumb transfer: a new technique. *Plast Reconstr Surg*. 1991;88:149-153.

How to cite this article: Hou C, Zhang A, Yu X, Han H. Reconstruction of fully shaped fingers using a free great toe nail flap combined with a second toe tissue flap. *Int Wound J*. 2022;19(6): 1389-1396. doi:[10.1111/iwj.13732](https://doi.org/10.1111/iwj.13732)