



ORIGINAL ARTICLE

Serial neurosonography in fetuses with congenital heart defects shows mild delays in cortical development

Sheila M. Everwijn¹  | Jiska F. van Bohemen² | Nan van Geloven³ |
Fenna A. Jansen¹  | Aalbertine K. Teunissen¹ | Lieke Rozendaal⁴ | Nico Blom⁴ |
Jan M. van Lith¹ | Monique C. Haak¹

¹Department of Obstetrics and Prenatal Diagnosis, Leiden University Medical Center, Leiden, The Netherlands

²Department of Obstetrics and Gynecology, HAGA Hospital, The Hague, The Netherlands

³Department of Biomedical Data Sciences, Leiden University Medical Center, Leiden, The Netherlands

⁴Department of Pediatric Cardiology, Leiden University Medical Center, Leiden, The Netherlands

Correspondence

Sheila M. Everwijn, Leiden University Medical Center, Department of Obstetrics – Prenatal diagnosis and Fetal Therapy K6-P, Postbus 9600-2300 RC, Leiden, The Netherlands.
Email: s.m.everwijn@lumc.nl

Abstract

Introduction: Neurodevelopmental delay is more common in children born with congenital heart defects (CHD), even with optimal perinatal and peri-operative care. It is hypothesized that fetuses with CHD are prone to neurological impairment in utero due to their cardiac defect, possibly leading to delayed cortical development. **Methods:** Cerebral cortical maturation was assessed with advanced neurosonographic examinations every 4 weeks in fetuses with CHD and compared to control fetuses. Five different primary fissures and four areas were scored (ranging 0–5) by blinded examiners using a cortical maturation scheme.

Results: Cortical staging was assessed in 574 ultrasound examinations in 85 CHD fetuses and 61 controls. Small differences in grading were seen in Sylvian and cingulate fissures. (Sylvian fissure: -0.12 grade, 95% CI $(-0.23; -0.01)$ $p = 0.05$, cingulate fissure: -0.24 grade, 95% CI $(-0.38; -0.10)$ $p = <0.001$. Other cortical areas showed normal maturation as compared to control fetuses.

Conclusion: Small differences were seen in three of the nine analyzed cortical areas in CHD fetuses, in contrast to previous reports on progressive third-trimester delay. The clinical implications of the small differences however, remain unknown.

Key points

What is already known about this topic?

- Neurodevelopmental delay is more prevalent in children with congenital heart defects
- Intrauterine hemodynamics are hypothesized to play a role in fetal cerebral abnormalities found in imaging studies

What does this study add?

- Delays were seen in the Sylvian, cingulate and calcarine fissures by serial neurosonography
- The differences we found were stable throughout pregnancy, contradicting previous studies on progressive delay over time

This is an open access article under the terms of the Creative Commons Attribution-NonCommercial-NoDerivs License, which permits use and distribution in any medium, provided the original work is properly cited, the use is non-commercial and no modifications or adaptations are made.

© 2021 The Authors. Prenatal Diagnosis published by John Wiley & Sons Ltd.

1 | INTRODUCTION

Congenital heart defects (CHD) are known to be associated with impaired neurodevelopmental outcome in children and adolescents, even in the absence of genetic syndromes.^{1,2} Behavioral, executive function problems, and lower scores on IQ tests are found to be more prevalent in these children, even in cases with optimal perinatal and perioperative care.^{3,4} Hypoxemia and hemodynamic changes during fetal life are known to influence the development of the cerebral cortex in growth restricted fetuses.⁵ In fetuses with CHD, it is hypothesized that the altered cardiac anatomy results in reduced blood flow or oxygen delivery in the brain, comparable to IUGR fetuses, which would cause a delay in cerebral development. Studies in fetuses with CHD show a smaller head circumference and a smaller cerebral volume assessed by ultrasound⁶ and magnetic resonance imaging (MRI).⁷ Furthermore, a delay in the development of sulcation was seen in neonates with transposition of the great arteries and hypoplastic left heart syndrome prior to surgery,^{8,9} suggesting a fetal origin of neurodevelopmental delay as well. Studies have shown that severe CHD that are expected to have worse cerebral oxygenation, are more prone to altered neurodevelopment.¹⁰ However, the exact mechanisms are not known yet and a genetic, epigenetic, and placental origin have to be considered as well.¹¹ The aim of this study is to assess cortical development in fetuses with a CHD. We hypothesized that cortical development in fetuses with various isolated CHD is delayed compared to control fetuses.

2 | METHODS

Consecutive cases of isolated congenital heart defects were prospectively included in the ongoing heart and neurodevelopment (HAND) study from September 2013 onwards. A group of healthy volunteers with normally developing pregnancies was recruited to create a control group. Both groups were included after informed consent. All subjects underwent fetal neurosonography according to the ISUOG guidelines¹² every 4 weeks from 20 weeks onwards (around 20–24–28–32 and 36 weeks), by experienced sonographers (SE/FJ/AK). Fetuses were scanned in all cranial planes (axial, sagittal, coronal, and parasagittal) using Voluson E8 and E10 systems (General Electric) with a RAB 6-D three-dimensional transducer. Non-isolated cases (defined as cases with multiple abnormalities or positive results with genetic testing during pregnancy or in the first year of life), multiple pregnancies, referred cases >32 weeks and cases with postnatal normal cardiac anatomy, were excluded from participation or analysis. The sample size was calculated based on two MRI studies,^{13,14} which showed a 2-week delay in brain development compared to control cases. The current presented study analyses cortical grading as a proxy for brain development. We have calculated both the case and control groups to consist of at least 60 subjects, to have a 90% power to detect a mean difference of 2 weeks (SD 1 week), evaluated with a two-sided level of significance.

The obtained images and clips were analyzed offline by three researchers (SE/JvB/FJ) who were blinded for group allocation,

gestational age (GA), and outcome. The grading system proposed by Pistorius¹⁵ was used to score the development of the fetal brain during pregnancy. Nine cerebral cortical fissures and cortical areas that are representative of cerebral development were scored: Sylvian Fissure, parieto-occipital sulcus, central sulcus, cingulate sulcus and the calcarine sulcus, and the frontal, parietal, temporal, and occipital areas. The grading system is shown in Figures 1–3, and progresses from 0 (no visible development) to 5 (end-stage sulcation). All three researchers underwent a training period of 30 subjects not included in this study, in which differences in scores were agreed upon by consensus. After this initial training period, the intra-observer agreement was calculated on the included subjects. In cases with a cephalic position, transvaginal ultrasound could be included to optimize visibility after maternal approval.

2.1 | Statistical analysis

The intraclass correlation coefficient was calculated with a two-way random model, to quantify intra-observer agreement on the included subjects (thus not using the cases scored during the initial training period). The nine different brain fissures and areas were analyzed to compare differences in cortical development stage between CHD-

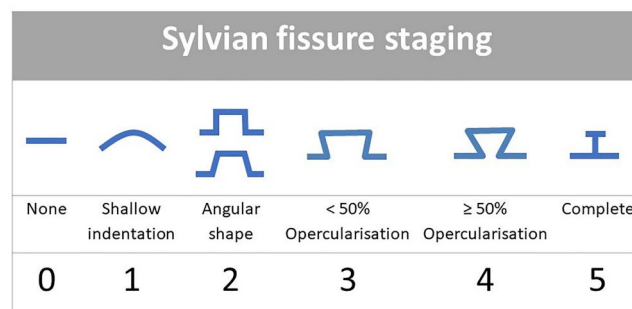


FIGURE 1 Sylvian fissure staging. Sylvian fissure progressing from no visible echoscopic sign of sulcation to end-stage sulcation [Colour figure can be viewed at wileyonlinelibrary.com]

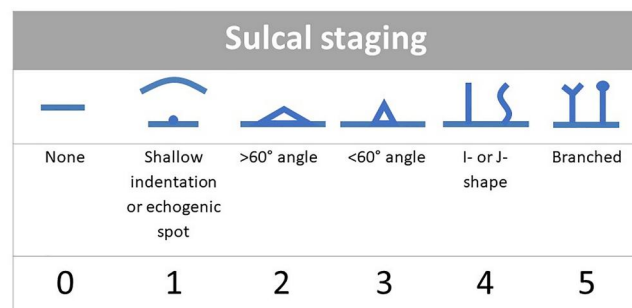


FIGURE 2 Sulcal staging. Sulcus: parieto-occipital, central, superior temporal, calcarine and cingulate progressing with gestational age from no visible echoscopic sign of sulcation to end-stage sulcation [Colour figure can be viewed at wileyonlinelibrary.com]




FIGURE 3 Cortical area staging. Frontal, parietal, temporal, and occipital cortical areas progression with gestational age from no visible echoscopic sign of sulcation to end-stage sulcation [Colour figure can be viewed at wileyonlinelibrary.com]

cases and controls. To account for multiple assessments of cortical development within the same fetus over the course of pregnancy, linear mixed model regression was applied. For each of the five brain fissures and the four areas, a linear mixed model was used with the grades as outcome to analyze the differences in cortical development between CHD-cases and controls during pregnancy. We chose the variance/covariance structure according to the best model fit assessed by the Akaike information Criterion. The included covariates were GA (grouped into five age categories), the group (CHD-cases and controls), and the interaction between GA and group. Two effects were described for all nine different brain fissures and areas. Main group differences were reported as an overall mean difference with confidence interval. The interaction effect was calculated to determine differences in development speed with advancing GA. These effects were also calculated after adding the following five potentially confounding variables to the model: maternal age, BMI, diabetes, parity, and fetal gender. Results from this adjusted model were primarily used for presentation of results. All statistical analyses were performed using IBM SPSS statistics version 24.0.0.0 (IBM). Statistical significance was set at $p \leq 0.05$.

3 | RESULTS

In the study period, 97 cases of isolated CHD were included in this study (Table 1). Twelve cases were excluded, encompassing 4 cases with a normal heart after birth (all suspected of coarctation of the aorta), and 8 cases with postnatal diagnosis of a genetic syndrome (2 cases with Kabuki syndrome, 4 cases with CHARGE syndrome, 2 cases with clear dysmorphic traits after birth, with no genetic diagnosis following whole exome sequencing (all patients died)). Of the 85 cases eligible for inclusion, 81 cases resulted in a live-born neonate, in which the prenatal diagnosis was confirmed with a postnatal echocardiogram. Of the 85 included cases, 4 decided to terminate the pregnancy. In these cases, no consent was given for postmortem examination, thus the prenatal diagnosis was adopted as the final diagnosis, as discrepancy rates are very low in our unit.¹⁶ Second, 61 controls were included in this study following the same study protocol. Also, controls were examined postnatally with a

cranial ultrasound without showing any abnormalities and displayed normal neurodevelopment up to 1 year of age.

In total, 608 ultrasound examinations were performed in 85 CHD-cases and 61 controls. Five hundred seventy-four ultrasound examinations comprised of advanced neurosonography examinations, 280 examinations in the control group (mean 4.56 examinations per control), 294 exams in the CHD-cases (mean 3.47 examinations per case). In 34 examinations (3 from control group, 31 from CHD-cases), ultrasonographers were not able to produce all planes according to ISUOG guidelines due to fetal position or poor ultrasound quality, these examinations were excluded from analyses (5.6%).

For all the analyzed primary sulci and areas, the mean grade and standard deviation was calculated per age category and displayed in Figures 4A–E and 5A–D. The method of scoring gyri and sulci was found to have excellent intraobserver variation with an ICC (95% CI) of 0.97 (95% CI, 0.95–0.98).

Of the analyzed fissures, statistically significant delayed development was found in Sylvian and cingulate fissures as compared to controls: average difference (range 0–5) was for Sylvian fissure: adjusted difference -0.12 , 95% CI $(-0.23; -0.01)$ $p = 0.05$ and for cingulate fissure: adjusted difference -0.24 , 95% CI $(-0.38; -0.10)$ $p = <0.001$. These two fissures showed no significant difference in speed of development with advancing GA. The remaining three fissures (parieto-occipital, calcarine, and central) showed no significant differences in the adjusted models as compared to controls (Table 2). The parieto-occipital did show significant difference in speed of development: $p = 0.02$, indicating that the difference between cases and controls decreased as GA progressed (as is visible in Figure 4B). None of the analyzed cortical areas showed significant differences in cortical development as compared to controls (Table 3).

4 | DISCUSSION

This study describes the largest number of extended neurosonography examinations performed in a consecutive cohort of fetuses with isolated congenital heart defect cases. The Sylvian and cingulate fissures were found to be significantly delayed in CHD fetuses as compared to controls. In line with previous work from our group, the differences are, however, very small, less than 0.25 grade point per fissure. It remains the question, whether this finding is clinically relevant and explains the reported neurodevelopment delay in CHD children.

Mild delays in maturation were observed in the Sylvian and cingulate fissures in our cohort. The magnitude of delay did not change during the course of pregnancy. In a study describing newborns prior to cardiac surgery, sulcal depth differences were found in the peri-Sylvian region.⁸ Two ultrasound studies in fetuses with a comparable design as ours, but with a smaller sample size,^{17,18} showed results that were not in agreement with each other. Peng et al. showed reduced Sylvian fissure depth comparable to our results, but Koning et al. only found reduced insular depth. In contrast to our study in which we found normal development of the parieto-

TABLE 1 Baseline characteristics for congenital heart defect cases and controls

Characteristics	CHD cases 97 subjects	Controls 61 subjects	p-Value
Maternal age in years—mean (SD)	29 (4.2)	32 (4.6)	0.01
BMI (kg/m ²)—Mean (SD)	23.7 (4.3)	23.6 (3.9)	0.97
Maternal diabetes—n (%)	3 (3)	0	0.17
Primigravidae—n (%)	36 (37)	20 (33)	0.35
Male gender—n (%)	60 (62)	28 (46)	0.04
No. of CHD cases			n.a.
Aortic arch hypoplasia and/or aortic stenosis—n (%)	24 (25)		
Tetralogy of Fallot or Fallot-like defect—n (%)	14 (14)		
Transposition of the great arteries—n (%)	14 (14)		
Tricuspid or pulmonary atresia—n (%)	6 (6)		
HLHS—n (%)	5 (5)		
(Un)balanced atrioventricular septal defect—n (%)	5 (5)		
Ventricular septal defect—n (%)	3 (3)		
Other major CHD ^a —n (%)	17 (18)		
Other minor CHD ^b —n (%)	9 (9)		
Excluded cases—n (%)			
Postnatal normal heart	4 (4)		
Non-isolated cases	8 (8)		
Pregnancy outcome—n (%)			n.a.
Live birth	81 (95)	61 (100)	
Termination of pregnancy	4 (5)	0 (0)	
Mean GA at scanning—mean (SD)			
20 weeks	20.9 (0.8)	21.1 (0.8)	0.49
24 weeks	24.1 (0.8)	24.2 (1.0)	0.77
28 weeks	28.3 (0.8)	28.1 (0.8)	0.36
32 weeks	32.2 (0.8)	32.1 (0.6)	0.49
36 weeks	36.2 (0.7)	35.9 (0.5)	0.04

Abbreviations: AVSD, atrioventricular septal defect; CHD, congenital heart disease; HLHS, hypoplastic left heart syndrome; TGA, transposition of the great arteries.

^aOther major CHD include truncus arteriosus, multiple level left obstruction syndrome (Shone's complex), double outlet right ventricle-TGA, congenitally corrected TGA without additional cardiac anomalies, AVSD with pulmonary atresia, aortic-left ventricular tunnel with severe distention of the left ventricle.

^bOther minor CHD include persistent left caval vein without obstruction of the left atrioventricular flow, restrictive foramen ovale, mild pulmonary stenosis.

* $p \leq 0.05$, statistically significant.

occipital fissure, both Peng and Koning found this fissure to be delayed in development. The differences between our results and Peng and Koning may be explained by the fact that they performed measurements of fissure depth whereas we used a grading system with excellent intra-observer variation that allows complete and more accurate assessment of a fissure. Furthermore, our study describes a much larger cohort than Koning¹⁷ and Peng¹⁸ which allows more robust conclusions.

MRI has also been performed to study cortical development in fetuses. In addition to sulcal depth, MRI is able to express the extent of delay by assessment of cortical development, white matter aspect and gyrification index. These studies showed statistically significant delays compared to control fetuses for the Sylvian fissure and all other visible sulci.^{19–22} The extent of the delays found in these MRI-studies are much more profound than in the ultrasound studies, which suggests this to be a more precise

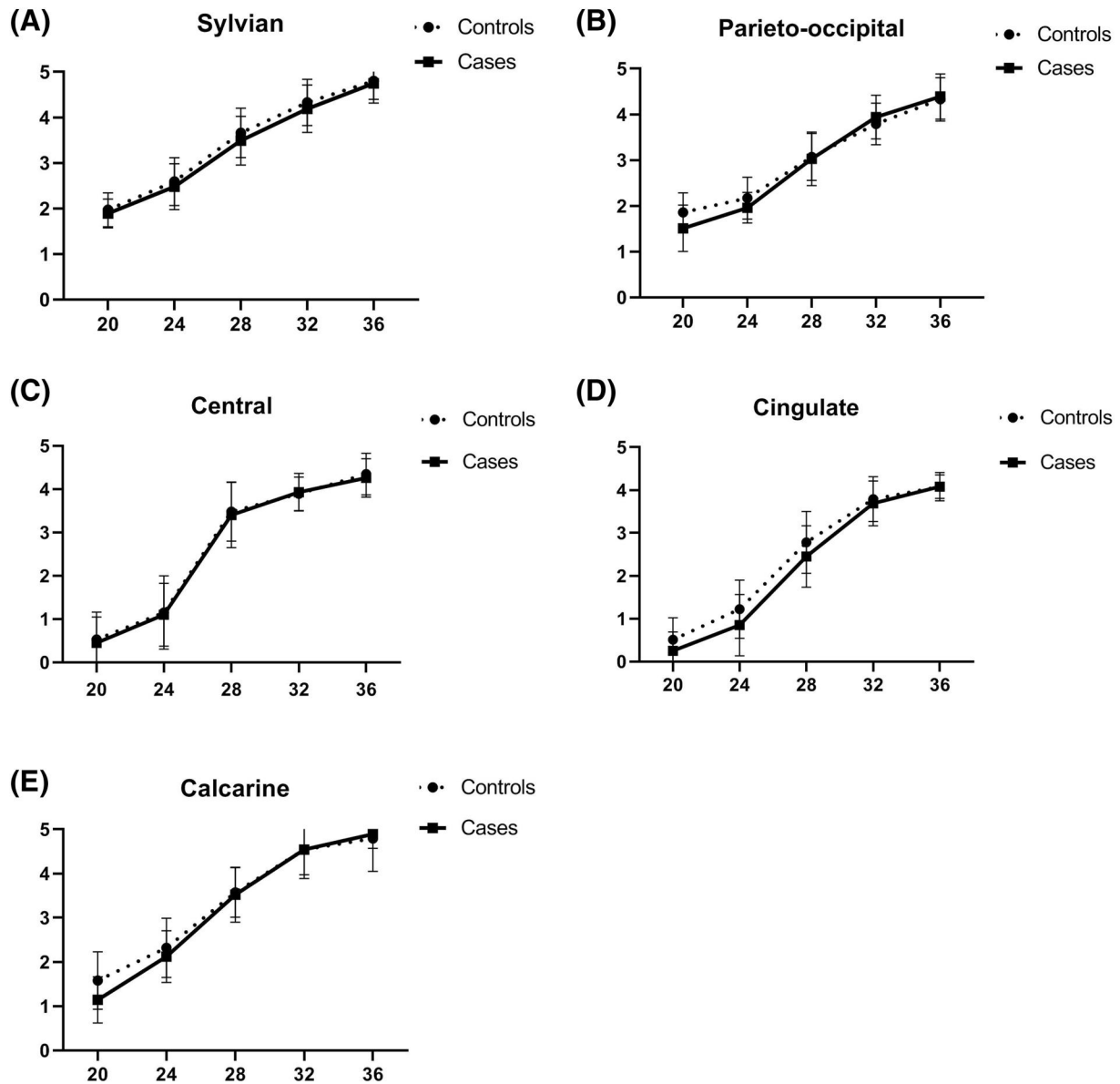


FIGURE 4 Progression of sulcal staging throughout pregnancy. (A) Sylvian fissure development. (B) Parieto-occipital sulcus development. (C) Central sulcus development. (D) Cingulate sulcus development. (E). Calcarine sulcus development. Continuous line (---), CHD-fetuses; dotted line (...) control fetuses; x-axis, sulcal grades; y-axis, gestational age in weeks

modality to detect changes in fissure depth. The generalizability of these MRI studies towards all CHD fetuses is, however, questionable, as these concerned a single measurement in a broad range of gestational ages and included only cases at the severe end of the spectrum.^{1,22}

The advantage of the assessment of brain development by ultrasound—in the hands of experienced sonographers—is the low cost and the availability of ultrasound technology, providing the possibility to perform serial neurosonography scans to assess cortical development during the course of pregnancy to all cases that present in a fetal cardiology unit, which prevents selection bias.

The exact mechanisms behind the described delays in neurodevelopment are, however, not fully understood. Theoretically, the

brain of a fetus with severe CHD resides in a state of relative hypoxia due to the cardiac lesion,²³ and it is thus conceivable that the effect on cortical maturation is similar to studies in lamb fetuses in hypoxia.²⁴ Several studies, that categorized their cases according to their effect on oxygenation toward the fetal brain, have shown that fetuses with hypoxic cardiac lesions show delayed cortical development, increased frequency of brain lesions, and smaller head circumferences.^{6,25,26} However, long-term neurodevelopmental outcome in these fetuses, is generally good, with normal IQs,²⁷ if we take TGA children as an example (with prenatal detection, and optimal peripartum, and perioperative care). A second indication that hemodynamic effects are not the sole explanation for alterations in the fetal brain is the fact that reduced head circumference is found in fetuses with non-hypoxic CHDs as well.¹¹ Therefore, we have chosen to

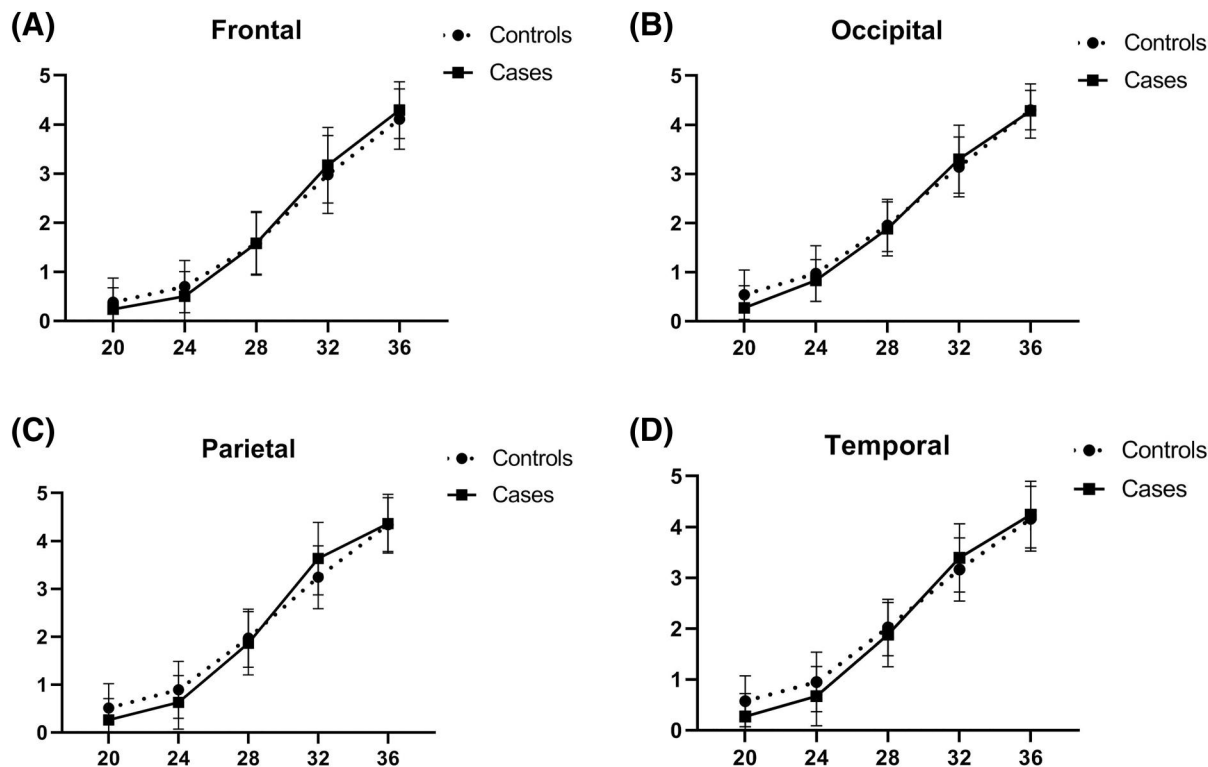


FIGURE 5 Progression of brain area staging throughout pregnancy. (A) Frontal area development. (B) Parietal area development. (C) Temporal area development. (D) Occipital area development. Continuous line (---), CHD-fetuses; dotted line (...) control fetuses; x-axis, sulcal grades; y-axis, gestational age in weeks

TABLE 2 Results of mixed model analysis in fissure grading

		Average difference in grade over all times			Difference in maturation speed <i>p</i>
		Difference	95% CI	<i>p</i>	
Sylvian	Unadjusted	-0.11	-0.21; -0.01	0.03*	0.90
	Adjusted	-0.12	-0.23; -0.01	0.05*	0.97
Parieto-occipital	Unadjusted	-0.08	-0.18; 0.02	0.11	0.01*
	Adjusted	-0.05	-0.16; 0.06	0.36	0.02*
Central	Unadjusted	-0.08	-0.19; -0.04	0.21	1.00
	Adjusted	-0.06	-0.21; 0.09	0.44	0.98
Cingulate	Unadjusted	-0.22	-0.34; -0.11	<0.01*	0.08
	Adjusted	-0.24	-0.37; 0.10	<0.01*	0.19
Calcarine	Unadjusted	-0.13	-0.24; 0.02	0.02*	0.04*
	Adjusted	-0.09	-0.21; 0.03	0.15	0.07

Note: Overall difference in grading represents the mean difference between scores in CHD and control cases. Speed of maturation represents the test on differences in progression with GA between scores of CHD and control cases. Unadjusted: Outcome of mixed model analysis, unadjusted for confounders. Adjusted: Outcome of mixed model analysis adjusted for maternal age, maternal BMI, maternal diabetes, parity and fetal gender.

* $p < 0.05$ is considered statistically significant.

analyze all types of CHD together, to prevent selection bias as we included a consecutive cohort of fetuses.

Many authors have studied the insular region of the fetal brain, as altered development of the insular region is correlated to decreased Sylvian fissure depth because of the close relation of both

regions. Since the insula is known to have connections to many other parts of the brain, reduced development of this structure is associated with cognitive and behavioral deficits, the insular region is correlated with speech, emotion-regulation, and social interaction.^{28,29} Reduced insular cortical thickness in growth-restricted

TABLE 3 Results of mixed model analysis in cortical area grading

		Average difference in grade over all times			Difference in maturation speed <i>p</i>
		Difference	95% CI	<i>p</i>	
Frontal	Unadjusted	−0.01	−0.12; 0.13	0.97	0.10
	Adjusted	−0.11	−0.26; 0.04	0.14	0.38
Parietal	Unadjusted	−0.07	−0.19; 0.05	0.24	0.01*
	Adjusted	0.10	−0.25; 0.04	0.16	0.06
Temporal	Unadjusted	−0.09	−0.22; −0.03	0.15	0.01*
	Adjusted	−0.12	−0.26; 0.03	0.11	0.09
Occipital	Unadjusted	−0.07	−0.17; 0.03	0.23	0.08
	Adjusted	−0.08	−0.20; 0.04	0.17	0.47

Note: Overall difference in grading represent the difference between scores in CHD and control cases. Speed of maturation represents the test on differences in progression with GA between scores of CHD and control cases. Unadjusted: Outcome of mixed model analysis, unadjusted for confounders. Adjusted: Outcome of mixed model analysis, adjusted for maternal age, maternal BMI, maternal diabetes, parity, and fetal gender.

* $p < 0.05$ is considered statistically significant.

fetuses correlates with altered neurobehavior.⁵ As CHD children display deficits on multiple domains including attention deficit disorder, the found delay in both the Sylvian fissure as well as the cingulate fissure, which is close to the insula as well, might be associated with these problems later in life. As CHD-children have been known to display deficits on multiple cognitive domains,^{4,30} the delays found in the Sylvian fissure in our study might play a role in these restrictions. Moreover, alterations in the cingulate fissure area, as were found in our study, are associated with attention deficit disorder,^{31,32} which is significantly more prevalent in CHD children.³³ Therefore, it is possible the delay in maturation found in our study in the Sylvian and cingulate fissures are associated with altered cognitive and behavioral problems in later life.

Alternative pathways that could explain cognitive and behavioral impairment in CHD-children have to be considered. Multiple factors, like genetics, epigenetics, the absence of a prenatal detection of the defect, peripartum setting, and complications around cardiothoracic procedures play a role in the long-term neurodevelopment in these children.

A strength of the current study is the prospective inclusion of a large number of consecutive cases with congenital heart defects, and the thorough scrutiny of included cases, resulting in the exclusion of cases with additional abnormalities and suspected or proven genetic syndromes.

Another strength of the methodology is the use of the grading system, which allows to view the morphology of a fissure instead of depth alone, to express the development numerically. We feel that measuring a sulcus could potentially overestimate the development of a sulcus, and therefore lead to incorrect conclusions.

As previously discussed, the findings in our large US study in isolated CHD cases underline cortical delays found in previous MRI studies. The found delays are, however, much smaller, making us question the extent of delay mentioned in previous studies. The modest differences in CHD-cases compared to controls (uncorrected

for multiple testing) found in our study may also mean that these differences have little clinical implications.

In the current study, transabdominal scanning of sufficient quality (only 5.6% of scans were excluded due to suboptimal quality) was obtained. Since we have scanned both groups with the same protocol and baseline characteristics are similar, both groups are considered comparable to each other. In our ongoing cohort of CHD cases, we are including transvaginal sequences in addition to transabdominal imaging, as transvaginal scanning in vertex presenting fetuses can produce superior image quality.³⁴

The absence of the possibility to correlate of our findings with postnatal neurodevelopment at this stage is a limitation of the current study, since small differences in fetal life could theoretically lead to cumulative delays in childhood.

5 | CONCLUSION

Minor changes in cortical development were observed in fetuses with congenital heart defects, in the areas that are associated with cognitive and behavioral deficits detected with serial ultrasonography. However, these changes were less profound than previously reported, and mostly stable throughout pregnancy, which limits firm conclusion on prenatal decelerated maturation in CHD.

ACKNOWLEDGMENT

No funding was received for the completion of this work.

CONFLICT OF INTEREST

The authors have no conflict of interest to report.

ETHICAL STATEMENT

All included controls and cases were counseled and signed informed consent prior to enrolling in the HAND-study. The HAND-study was

approved by the local ethics committee on March 17, 2014 under ref. no. P13.107. It was agreed that the severe neurodevelopmental delay found in children with CHD found in previous studies warrants additional ultrasound scans.

DATA AVAILABILITY STATEMENT

The data that support the findings of this study are available from the corresponding author upon reasonable request.

ORCID

Sheila M. Everwijn  <https://orcid.org/0000-0003-0653-1841>

Fenna A. Jansen  <https://orcid.org/0000-0002-5258-1957>

REFERENCES

- Majnemer A, Limperopoulos C, Shevell MI, Rohlicek C, Rosenblatt B, Tchervenkov C. A new look at outcomes of infants with congenital heart disease. *Pediatr Neurol.* 2009;403:197-204.
- Jansen FA, Everwijn SM, Scheepjens R, et al. Fetal brain imaging in isolated congenital heart defects – a systematic review and meta-analysis. *Prenat Diagn.* 2016;367:601-613.
- Bellinger DC, Wypij D, Duplessis AJ, et al. Neurodevelopmental status at eight years in children with dextro-transposition of the great arteries: the Boston Circulatory Arrest Trial. *J Thorac Cardiovasc Surg.* 2003;1265:1385-1396.
- Bellinger DC, Wypij D, Rivkin MJ, et al. Adolescents with d-transposition of the great arteries corrected with the arterial switch procedure: neuropsychological assessment and structural brain imaging. *Circulation.* 2011;12412:1361-1369.
- Egana-Ugrinovic G, Sanz-Cortes M, Figueras F, Couve-Perez C, Gratacós E. Fetal MRI insular cortical morphometry and its association with neurobehavior in late-onset small-for-gestational-age fetuses. *Ultrasound Obstet Gynecol.* 2014;443:322-329.
- Masoller N, Martinez JM, Gomez O, et al. Evidence of second-trimester changes in head biometry and brain perfusion in fetuses with congenital heart disease. *Ultrasound Obstet Gynecol.* 2014;442:182-187.
- Limperopoulos C, Tworetzky W, McElhinney DB, et al. Brain volume and metabolism in fetuses with congenital heart disease: evaluation with quantitative magnetic resonance imaging and spectroscopy. *Circulation.* 2010;1211:26-33.
- Ortinou C, Alexopoulos D, Dierker D, Van Essen D, Beca J, Inder T. Cortical folding is altered before surgery in infants with congenital heart disease. *J Pediatr.* 2013;1635:1507-1510.
- Licht DJ, Shera DM, Clancy RR, et al. Brain maturation is delayed in infants with complex congenital heart defects. *J Thorac Cardiovasc Surg.* 2009;1373:529-537. discussion 36-7.
- Masoller N, Sanz-Cortes M, Crispi F, et al. Severity of fetal brain abnormalities in congenital heart disease in relation to the main expected pattern of in utero brain blood supply. *Fetal Diagn Ther.* 2016;394:269-278.
- Matthiesen NB, Henriksen TB, Gaynor JW, et al. Congenital heart defects and indices of fetal cerebral growth in a nationwide cohort of 924,422 liveborn infants. *Circulation.* 2016;133(6):566-575.
- International Society of Ultrasound in O, Gynecology Education C. Sonographic examination of the fetal central nervous system: guidelines for performing the 'basic examination' and the 'fetal neurosonogram'. *Ultrasound Obstet Gynecol.* 2007;291:109-116.
- Clouchoux C, Kudelski D, Gholipour A, et al. Quantitative in vivo MRI measurement of cortical development in the fetus. *Brain Struct Funct.* 2012;2171:127-139.
- Mlczoch E, Brugger P, Ulm B, et al. Structural congenital brain disease in congenital heart disease: results from a fetal MRI program. *Eur J Paediatr Neurol.* 2012;17(2).
- Pistorius LR, Stoutenbeek P, Groenendaal F, et al. Grade and symmetry of normal fetal cortical development: a longitudinal two- and three-dimensional ultrasound study. *Ultrasound Obstet Gynecol.* 2010;366:700-708.
- van Velzen CL, Clur SA, Rijlaarsdam ME, et al. Prenatal diagnosis of congenital heart defects: accuracy and discrepancies in a multi-center cohort. *Ultrasound Obstet Gynecol.* 2016;475:616-622.
- Koning IV, van Graafeiland AW, Groenenberg IAL, et al. Prenatal influence of congenital heart defects on trajectories of cortical folding of the fetal brain using three-dimensional ultrasound. *Prenat Diagn.* 2017;3710:1008-1016.
- Peng Q, Zhou Q, Zang M, et al. Reduced fetal brain fissures depth in fetuses with congenital heart diseases. *Prenat Diagn.* 2016;3611:1047-1053.
- Masoller N, Sanz-Cortes M, Crispi F, et al. Mid-gestation brain Doppler and head biometry in fetuses with congenital heart disease predict abnormal brain development at birth. *Ultrasound Obstet Gynecol.* 2016;471:65-73.
- Ortinou CM, Rollins CK, Gholipour A, et al. Early-emerging sulcal patterns are atypical in fetuses with congenital heart disease. *Cerebr Cortex.* 2018;29(8):3605-3616.
- Clouchoux C, du Plessis AJ, Bouyssi-Kobar M, et al. Delayed cortical development in fetuses with complex congenital heart disease. *Cerebr Cortex.* 2013;2312:2932-2943.
- Jaimes C, Rofeberg V, Stopp C, et al. Association of isolated congenital heart disease with fetal brain maturation. *AJNR Am J Neuroradiol.* 2020;418:1525-1531.
- Lauridsen MH, Ulbjerg N, Henriksen TB, et al. Cerebral oxygenation measurements by magnetic resonance imaging in fetuses with and without heart defects. *Circ Cardiovasc Imaging.* 2017;1011:e006459.
- Rees S, Stringer M, Just Y, Hooper SB, Harding R. The vulnerability of the fetal sheep brain to hypoxemia at mid-gestation. *Brain Res Dev Brain Res.* 1997;1032:103-118.
- Sun L, Macgowan CK, Sled JG, et al. Reduced fetal cerebral oxygen consumption is associated with smaller brain size in fetuses with congenital heart disease. *Circulation.* 2015;13115:1313-1323.
- Kelly CJ, Makropoulos A, Cordero-Grande L, et al. Impaired development of the cerebral cortex in infants with congenital heart disease is correlated to reduced cerebral oxygen delivery. *Sci Rep.* 2017;71:15088.
- Lim JM, Porayette P, Marini D, et al. Associations between age at arterial switch operation, brain growth, and development in infants with transposition of the great arteries. *Circulation.* 2019;139:2728-2738.
- Peschke C, Ziegler W, Eisenberger J, Baumgaertner A. Phonological manipulation between speech perception and production activates a parieto-frontal circuit. *Neuroimage.* 2012;591:788-799.
- Gasquoine PG. Contributions of the insula to cognition and emotion. *Neuropsychol Rev.* 2014;242:77-87.
- Morton PD, Ishibashi N, Jonas RA. Neurodevelopmental abnormalities and congenital heart disease: insights into altered brain maturation. *Circ Res.* 2017;1206:960-977.
- Nakao T, Radua J, Rubia K, Mataix-Cols D. Gray matter volume abnormalities in ADHD: voxel-based meta-analysis exploring the effects of age and stimulant medication. *Am J Psychiatry.* 2011;16811:1154-1163.
- Zhu CZ, Zang YF, Cao QJ, et al. Fisher discriminative analysis of resting-state brain function for attention-deficit/hyperactivity disorder. *Neuroimage.* 2008;401:110-120.

33. DeMaso DR, Calderon J, Taylor GA, et al. Psychiatric disorders in adolescents with single ventricle congenital heart disease. *Pediatrics*. 2017;1393.
34. Malinge G, Paladini D, Haratz KK, Monteagudo A, Pilu GL, Timor-Tritsch IE. ISUOG Practice Guidelines (updated): sonographic examination of the fetal central nervous system. Part 1: performance of screening examination and indications for targeted neurosonography. *Ultrasound Obstet Gynecol*. 2020;563:476-484.

How to cite this article: Everwijn SM, van Bohemen JF, van Geloven N, et al. Serial neurosonography in fetuses with congenital heart defects shows mild delays in cortical development. *Prenat Diagn*. 2021;41(13): 1649-1657. <https://doi.org/10.1002/pd.6038>