

# Rhinocerebral mucormycosis after functional endoscopic sinus surgery

## A case report

Cha Dong Yeo, MD<sup>a</sup>, Jong Seung Kim, MD, PhD<sup>a,b</sup>, Sam Hyun Kwon, MD, PhD<sup>a,b,\*</sup>, Eun Jung Lee, MD, PhD<sup>a,b</sup>, Min Hee Lee, MD<sup>c</sup>, Su Geun Kim, MD<sup>a</sup>, Yeon Seok You, MD<sup>a</sup>, June Sun Kim, MD<sup>a</sup>, Jong Hwan Lee, MD<sup>a</sup>, Ji Seob Ryu, MD<sup>a</sup>

### Abstract

**Rationale:** Mucormycosis is a rare fungal infection which mainly develops in compromised hosts and the associated mortality rate is high.

**Patient concerns:** We report a case of mucormycosis in a 59-year-old woman following routine endoscopic sinus surgery. The patient had a history of diabetes mellitus (DM) and bronchial asthma.

**Diagnoses:** On follow-up 4 weeks after the first functional endoscopic sinus surgery (FESS), she complained of a severe headache and was readmitted for a second period. Endoscopic examination revealed bony erosion and a whitish discharge on the left middle turbinate, which was confirmed as mucormycosis by endoscopic biopsy.

**Interventions:** Endoscopic debridement of the necrotic tissue and middle turbinectomy were performed and the patient was treated with intravenous amphotericin B for 3 months (3.5 mg/kg/day).

**Outcomes:** About 1 month into the second period of hospitalization, left Bell's palsy had occurred. The facial palsy improved naturally after 2 months of hospitalization. One year after endoscopic debridement, follow-up endoscopy showed that there was no residual lesion.

**Conclusion:** This is the first report of mucormycosis after routine endoscopic sinus surgery. We did not miss headache symptom after FESS surgery, and diagnosed mucormycosis through early endoscopic biopsy, which played an important role in curing the patient. In addition to the importance of medical therapy such as DM control for patients, emotional support and psychiatric treatment are also important factors as these patients require hospitalization for a long period, 3 months in the case of this patient.

**Abbreviations:** CT = computed tomography, DM = diabetes mellitus, FESS = functional endoscopic sinus surgery, WBC = white blood cell count.

**Keywords:** functional endoscopic sinus surgery, mucormycosis, mycoses, nose diseases

## 1. Introduction

Mucormycosis is a rare fungal infection caused by fungi in the family *Mucoraceae* which mainly develops in compromised hosts, and the associated mortality rate is high. The overall mortality rates quotes in literature range from 30% to 80%.<sup>[1]</sup> It usually occurs in patients with metabolic abnormalities or who

are immunocompromised with prolonged neutropenia.<sup>[2]</sup> However, it can also occur in patients without any underlying disease process. Patients without any underlying disease process have a 2.5% mortality versus 40 and 80% mortality for patients with metabolic abnormalities and immunocompromised patients, respectively.<sup>[3]</sup> Timely diagnosis as well as intervention is important for successful management. The treatment of choice is surgical debridement of necrotic tissue and systemic antifungal therapy, including amphotericin B. We encountered a patient with rhinocerebral mucormycosis after endoscopic sinus surgery. The patient was a 59-year-old woman with a past medical history of type-2 diabetes mellitus (DM) and asthma, and she was being treated for chronic rhinosinusitis with nasal polyps by endoscopic sinus surgery.

This study was approved by the institutional review board of Chonbuk National University Hospital, Korea. Informed written consent was obtained from the patient for publication of this case report and accompanying images.

## 2. Case report

A 59-year-old woman, with type-2 diabetes mellitus (DM) for 14 years and asthma for 11 years presented with nasal obstruction which had been present for several weeks. She came to our outpatient clinic for further evaluation. At first admission,

Editor: N/A.

The authors have no funding and no conflicts of interest to disclose.

<sup>a</sup> Department of Otolaryngology-Head and Neck Surgery, <sup>b</sup> Research Institute of Clinical Medicine of Chonbuk National University-Biomedical Research Institute of Chonbuk National University Hospital, <sup>c</sup> Department of Internal Medicine, Division of Allergy and Pulmonology, Presbyterian Medical Center, Jeonju, Republic of Korea.

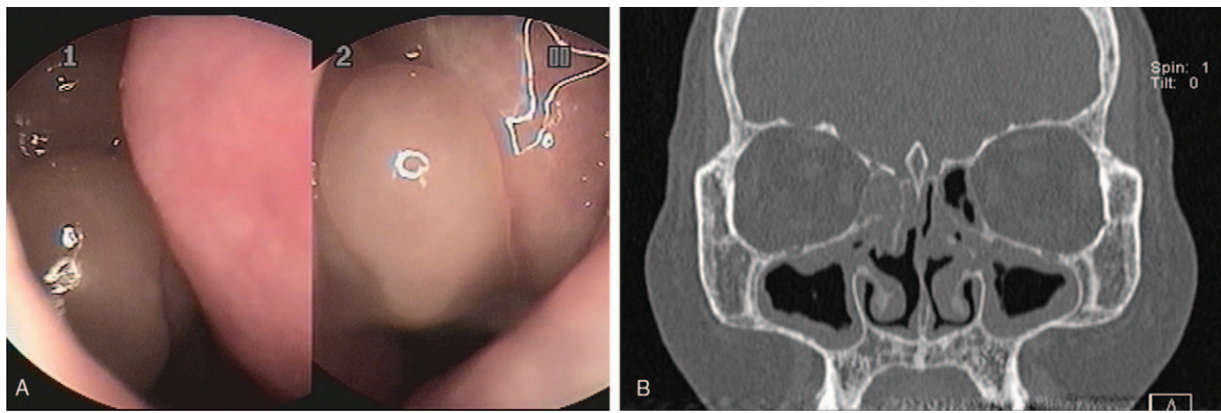
\* Correspondence: Sam Hyun Kwon, 2-20 Keum-Am-Dong Department of Otorhinolaryngology-Head and Neck Surgery, Chonbuk National University Medical School, Jeonju 561-180, Korea (e-mail: shkwon@bnu.ac.kr).

Copyright © 2018 the Author(s). Published by Wolters Kluwer Health, Inc. This is an open access article distributed under the terms of the Creative Commons Attribution-Non Commercial-No Derivatives License 4.0 (CCBY-NC-ND), where it is permissible to download and share the work provided it is properly cited. The work cannot be changed in any way or used commercially without permission from the journal.

Medicine (2018) 97:51(e13290)

Received: 15 June 2018 / Accepted: 24 October 2018

<http://dx.doi.org/10.1097/MD.0000000000013290>



**Figure 1.** (A) Nasal endoscopy showed nasal polyps in both nasal cavities. (B) CT scan of the paranasal sinuses showed pansinusitis. CT = computed tomography.

laboratory findings showed that her white blood cell count (WBC) was  $6410/\text{mm}^3$  (neutrophils  $3560/\text{mm}^3$ , eosinophils  $500/\text{mm}^3$ ), total IgE was  $94.4\text{ IU/mL}$ , serum glucose level was  $116\text{ mg/dL}$ , and HbA1c was  $6.5\%$ .

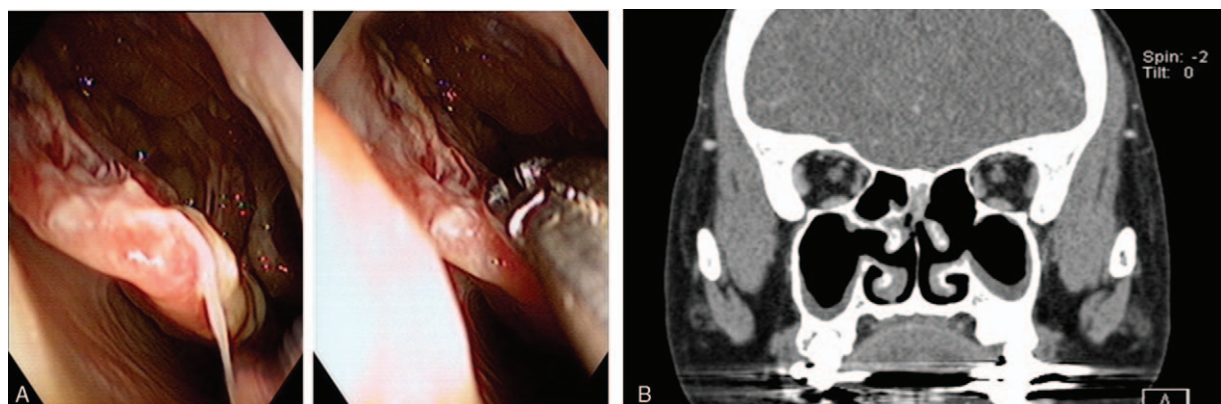
Endoscopic examination revealed nasal polyp and yellowish discharge from both nasal cavities, and a computed tomography (CT) scan of the paranasal sinuses showed pansinusitis (Fig. 1A and B). The patient underwent functional endoscopic sinus surgery (FESS) and was discharged without any complications. She was prescribed antibiotics for 1 week in the first week of follow-up, and a weekly oral steroid ( $30\text{ mg/day}$ ) in the second week.

On follow-up 4 weeks later, she complained of a severe headache. Endoscopic examination revealed bony erosion and a whitish discharge on the left middle turbinate (Fig. 2A and B) so an endoscopic biopsy was carried out. The histopathologic report on the nasal tissue showed fungal hyphae (periodic acid-Schiff stain (PAS) positive). These fungal hyphae were non-septate, irregularly wide and showed right-angled branching. The histological diagnosis was mucormycosis (Fig. 3) and the patient was treated with intravenous liposomal amphotericin B ( $3.5\text{ mg/kg/day}$ ). During the hospitalization for FESS, pre-meal blood glucose level was  $150$  to  $200\text{ mg/dL}$  and post-meal blood glucose level was under  $250\text{ mg/dL}$ . However, when the patient was hospitalized with a severe headache a month later, blood glucose level was increased which premeal blood glucose level was  $200$  to

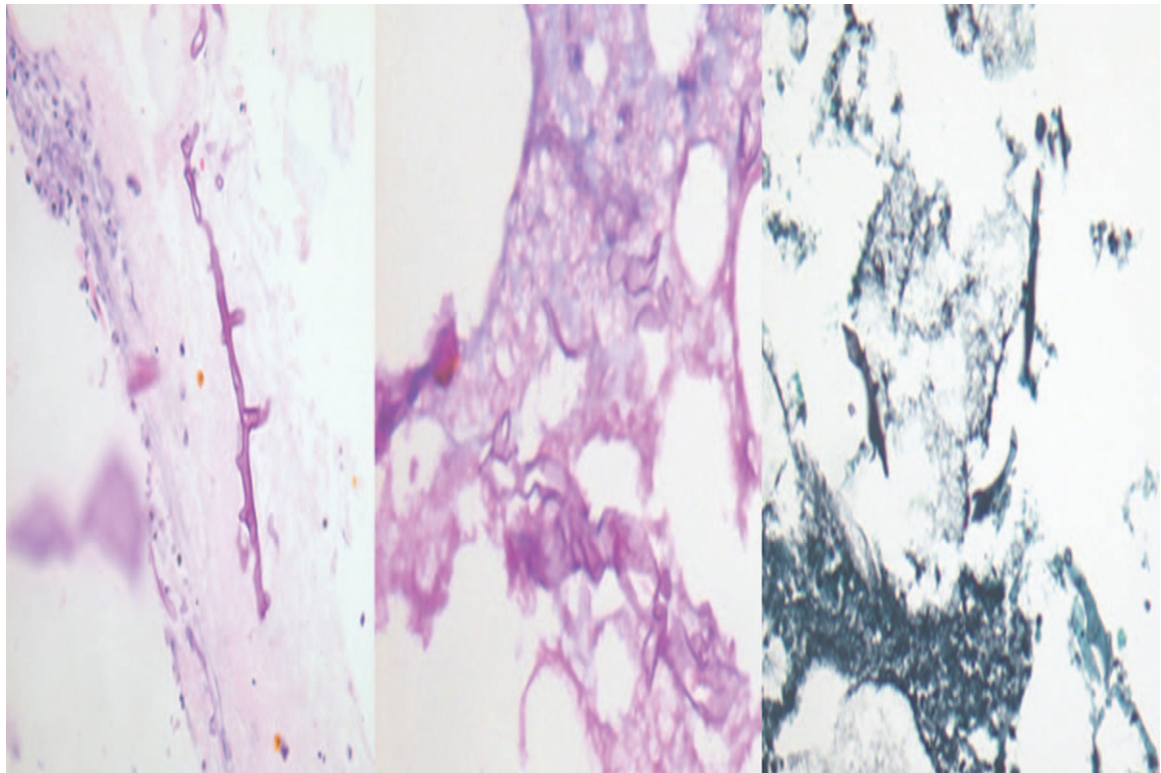
$250\text{ mg/dL}$  and postmeal blood glucose level was  $250$  to  $350\text{ mg/dL}$ . It was believed to be due to steroids. So the patient stopped using steroids and strictly controlled the blood sugar level.

While in hospital, endoscopic debridement of the necrotic tissue and middle turbinectomy were performed. Intraoperative findings revealed a yellowish lesion extending from the middle turbinate to the frontal recess. Intraoperative specimens from the left nasal cavity and middle turbinate were submitted to the laboratory for histology and microbiological investigation. Microscopy of these specimens revealed chronic granulomatous inflammation and no evidence of fungal organism.

About 1 month after the second admission, left facial paralysis occurred (Fig. 4A). The type of paralysis was peripheral type, thus we suspected Bell's palsy (House–Brackmann Grade IV). We did not use steroids to treat the facial palsy because of the invasive fungal infection. During the hospitalization period, the patient found it very difficult to endure the long treatment, and there was one suicide attempt, but she overcame this with emotional support from the medical staff and caregivers. After 2 months of hospitalization, the facial palsy had improved to House–Brackmann Grade II (Fig. 4B). The patient completed 3 months of amphotericin B and was then discharged. After 2 weeks, 1 month, 2 months, 3 months, 6 months, and 9 months after discharge, follow-up endoscopy showed that there was no recurrence or complications and the patient did not complain any symptoms.



**Figure 2.** (A) Bony erosion and whitish discharge was noted on the left middle turbinate. (B) CT scan of the paranasal sinuses showed that there was no significant lesion to suspect mucormycosis. CT = computed tomography.



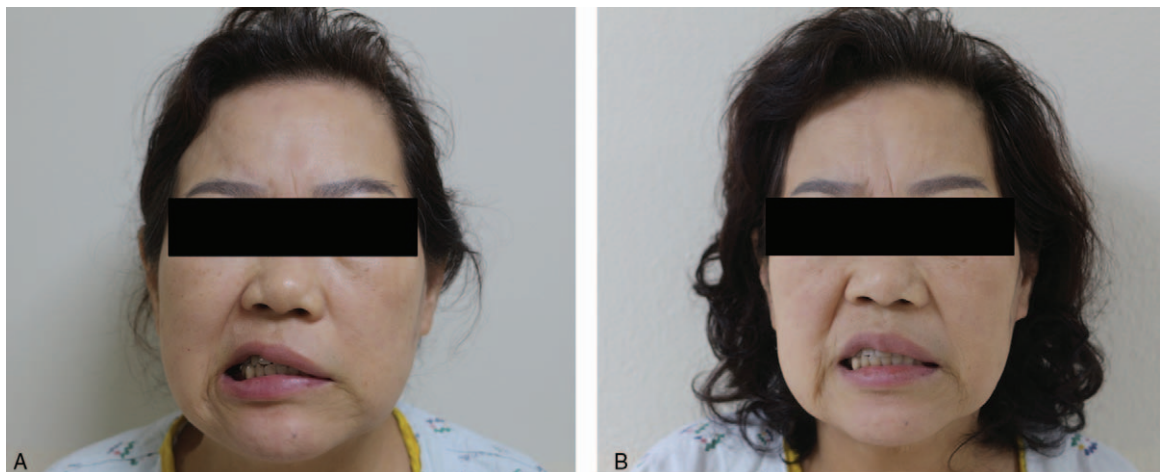
**Figure 3.** (A) Microscopic examination showed wide, non-septated, irregular fungal hyphae with right-angled branching (hematoxylin and eosin stain; magnification,  $\times 400$ ). (B) Irregular and ribbon-like hyphae and spores were noted (periodic acid-Schiff stain; magnification,  $\times 400$ ). (C) Another microscopic examination showed black colored, wide, nonseptated fungal hyphae with right-angled branching (Grocott's methenamine silver stain; magnification,  $\times 400$ ).

### 3. Discussion

Rhinocerebral mucormycosis is a serious, relatively uncommon invasive fungal infection and one of the most aggressive and lethal invasive mycoses. The underlying diseases for mucormycosis include uncontrolled diabetes, organ transplant, malignancies such as lymphoma and leukemia, immunosuppressive therapy, renal failure, and acquired immune deficiency syndrome (AIDS).<sup>[2]</sup> The unique point of our case is that mucormycosis occurred after FESS. It is common to use antibiotics after FESS and oral or topical steroids may be used to reduce edema

intermittently. The main reason for our mucormycotic infection after FESS may have been the use of steroids or antibiotics after surgery.

The disease is acquired by inhalation of fungal spores into the nasal cavity with subsequent invasion of the sinus mucosa. Fever, headache and nasal congestion, accompanied by facial pain and swelling are the earliest symptoms reported. Diagnosis is mainly dependent on culture and histological examination of specimens by microscopy.<sup>[4]</sup> Although many symptoms may occur in patients after FESS, severe headache is a symptom that doctors



**Figure 4.** (A) Left facial palsy (House-Brackmann Grade IV) occurred 1 month after hospitalization. (B) The facial palsy had improved at discharge with House-Brackmann Grade II after 2 months of hospitalization.



should not miss. If we neglected the symptoms of headache in our patient, we would not have been suspicious of other diseases, which would have made it impossible to find fatal mucormycosis.

Successful management of mucormycosis includes both medical and surgical modalities. The initial medical approach to mucormycosis consists of aggressive treatment of the underlying predisposing medical condition and the use of systemic antifungal agents. Amphotericin is commonly used in patients with mucormycosis, and some studies have reported overall survival rates of up to 72%.<sup>[5]</sup> Surgical management is crucially important and should involve early debridement of all infected and necrotic tissue.

The exact duration and dose of amphotericin B needed for cure of rhinocerebral mucormycosis have not been accurately established.<sup>[6]</sup> Cure is known to require at least several months of duration and doses of 1.5 to 5 mg/kg/day. We would like to emphasize that emotional support for patients during this period is also important. In our patient, mucormycosis developed after routine FESS, and long-term hospitalization could have made her mentally unstable. Unfortunately, there was one suicide attempt, but she overcame this with emotional support from the medical staff and caregivers and appropriate anti-depressive medication.

In rhinocerebral mucormycosis, facial palsy is an unsurprising concomitant symptom. In some reports, 11% to 22% of mucormycosis patients suffered from facial paralysis.<sup>[7,8]</sup> Other authors have reported that 3 out of 4 mucormycosis patients suffer from facial paralysis.<sup>[9]</sup> Although facial palsy is not a rare symptom in patients with mucormycosis, the exact mechanism of facial palsy is unknown. In our patient, when facial palsy first developed 1 month after treatment, it was unclear whether this was due to direct fungal invasion or Bell's palsy without cause. If facial palsy was caused by direct fungal invasion, there was no longer a site for surgery such as necrotic tissues and bony erosion lesion. Moreover, if Bell's palsy was the cause of facial palsy, the spontaneous recovery rate reaches 80%, so we continued to be dedicated to antifungal treatment.<sup>[10]</sup>

#### 4. Conclusion

It is well known that extensive debridement and sufficient amphotericin B should be used for rhinocerebral mucormycosis. We did not miss headache symptom after FESS, and diagnosed mucormycosis through early endoscopic biopsy, which played an important role in cure of the patient. In addition to the importance of medical therapy such as DM control for patients, emotional support and psychiatric treatment are also important factors as patients require hospitalization for a long period.

#### Acknowledgments

This paper was supported by the Fund of Biomedical Research Institute, Chonbuk National University Hospital.

#### Author contributions

**Conceptualization:** Cha Dong Yeo, Su Geun Kim.

**Data curation:** Cha Dong Yeo, Su Geun Kim.

**Formal analysis:** Cha Dong Yeo, Su Geun Kim.

**Investigation:** Cha Dong Yeo, Eun Jung Lee, Min Hee Lee.

**Methodology:** Cha Dong Yeo, Eun Jung Lee, Min Hee Lee, Yeon Seok You.

**Project administration:** Eun Jung Lee, Min Hee Lee, Yeon Seok You.

**Resources:** Eun Jung Lee, Yeon Seok You.

**Supervision:** Jong Seung Kim, Cha Dong Yeo, Sam Hyun Kwon.

**Validation:** Jong Seung Kim, Cha Dong Yeo, Sam Hyun Kwon.

**Visualization:** Jong Seung Kim, Sam Hyun Kwon.

**Writing – original draft:** Jong Seung Kim, Cha Dong Yeo, Sam Hyun Kwon.

**Writing – review & editing:** June Sun Kim, Jong Hwan Lee, Ji Seob Ryu.

#### References

- [1] Ryan P, McSpadden , Martin James R, et al. Mucormycosis causing Ludwig angina: a unique presentation. *J Oral Maxillofac Surg* 2017;75:759–62.
- [2] Sahota R, Gambhir R, Anand S, et al. Rhinocerebral mucormycosis: report of a rare case. *Ethiop J Health Sci* 2017;27:85–90.
- [3] Spellberg B, Edwards J, Ibrahim A. Novel perspectives on mucormycosis: pathophysiology, presentation, and management. *Clin Microbiol Rev* 2005;18:556.
- [4] Mahomed S, Basanth S, Mlisana K. The successful use of amphotericin B followed by oral posaconazole in a rare case of invasive fungal sinusitis caused by co-infection with mucormycosis and aspergillus. *IDCases* 2015;2:116–7.
- [5] Mahmood N, Quraishi FA, Shahid SMH, et al. Rhinocerebral mucormycosis with post surgical complications in diabetes: a case report. *AKMMC J* 2016;7:56–62.
- [6] Handzel O, Landau Z, Halperin D. Liposomal amphotericin B treatment for rhinocerebral mucormycosis: how much is enough? *Rhinology* 2003;41:184–6.
- [7] Yohai RA, Bullock JD, Aziz AA, et al. Survival factors in rhino-orbital-cerebral mucormycosis. *Surv Ophthalmol* 1994;39:3–22.
- [8] Ferguson BJ. Mucormycosis of the nose and paranasal sinuses. *Otolaryngol Clin North Am* 2000;33:349–65.
- [9] Karadeniz Uğurlu Ş, Selim S, Kopar A, et al. Rhino-orbital mucormycosis: clinical findings and treatment outcomes of four cases. *Turk J Ophthalmol* 2015;45:169–74.
- [10] Grosheva M, Beutner D, Volk GF, et al. Idiopathic facial palsy. *HNO* 2010;58:419–25.