

# Surgical Techniques of Eccentric Rotational Acetabular Osteotomy

Yukiharu Hasegawa, MD, PhD

Based on an original article: *J Bone Joint Surg Am.* 2014 Dec 3;96(23):1975-82.

## Introduction

This report describes the operative indications and essential techniques of eccentric rotational acetabular osteotomy for hip dysplasia in patients with pre-osteoarthritis, early arthritis, or in some cases even advanced osteoarthritis of the hip.

Acetabular dysplasia is one of the most common causes of osteoarthritis of the hip<sup>1,2</sup>. Periacetabular osteotomy is an excellent procedure for young active patients with symptomatic acetabular dysplasia or early-stage osteoarthritis<sup>3-8</sup>. There are many surgical methods for periacetabular osteotomy, such as Ganz periacetabular osteotomy, rotational acetabular osteotomy, and eccentric rotational acetabular osteotomy<sup>9-11</sup> (Video 1).

Medialization and distalization of the femoral head are essential to reduce the resultant force on the lateralized hip. Acetabular osteotomies for the treatment of pre-osteoarthritis and early-stage osteoarthritis have been reported to provide satisfactory long-term results<sup>3-8</sup>. Previously, our institution reported the results of eccentric rotational acetabular osteotomy after a mean duration of follow-up of twenty years<sup>12</sup>. The advantage of a transtrochanteric approach is a wider exposure, which enables visualization of the iliac and ischial osteotomy lines<sup>11</sup>. This method is demanding but allows for an accurate and reproducible spherical osteotomy.

The eccentric rotational acetabular osteotomy is performed according to the technique that we described in 2002<sup>11</sup>. The techniques and postoperative care have been improved on for over twenty-five years. Eccentric rotational acetabular osteotomy is a reproducible reorientation osteotomy for hip dysplasia with lateralization of the femoral head. The acetabular fragment can be rotated the same number of degrees as determined in the preoperative plan to normalize the femoral head position. Separate harvesting of autologous bone for grafting is not usually needed. We developed multiple surgical instruments, including a spherical osteotomy guide (Meira), a three-dimensional (3D) curved chisel (Mizuho), and a curved chisel (Mizuho) to perform a precise spherical osteotomy (Fig. 1).

The procedure is done with the following steps.

## Step 1: Patient Positioning

*An accurate lateral decubitus position of the pelvis is important.*

- Administer general anesthesia and consider adding epidural anesthesia for pain management extending through the twenty-four-hour perioperative period.
- Place the patient in an accurate lateral decubitus position with the involved extremity draped free on the table. The pelvis should be positioned vertically in relationship to the floor, with care taken to avoid any rotational malalignment.
- Before the surgery, examine the congruity of the joint by using a fluoroscopic image intensifier with the hip in maximum abduction. An accurate lateral decubitus position is important to evaluate the medialization and distalization of the acetabular fragment. The intraoperative image intensifier is used to confirm the appropriate height of the osteotomy from the joint line (20 mm) and the direction of the osteotomy according to the preoperative plan. The image intensifier is also used to confirm the coverage of the acetabular fragment after reorientation of this fragment.

## Step 2: Skin Incision

*Make a bikini skin incision and elevate the skin flap.*

- Make a 20-cm curved skin incision, the so-called bikini skin incision, 3 cm proximal to the tip of greater trochanter, convex in the proximal direction (Fig. 2).
- Elevate the skin flap subcutaneously using electrocautery.

## Step 3: Transtrochanteric Approach

*Make a Y-shaped incision, retract the innominate fossa, and detach the greater trochanter with an oscillating saw.*

- Make a Y-shaped incision (Video 1, time point 00:26, Fig. A) of the tensor fasciae latae to allow complete anterior and posterior exposure of the gluteus medius and minimus muscles (Fig. 3-A).
- Tag and divide the short external rotator muscles, except for the quadratus femoris (Fig. 3-B).
- Retract the short external rotator muscles to expose the innominate fossa between the ilium and ischium with a Hohmann retractor under the femoral neck and a Langenbeck retractor on the edge of the posterior column (ischium) to expose the osteotomy line (Fig. 3-C).
- Detach the greater trochanter with an oscillating bone saw and a 40-mm-wide chisel and reflect the gluteus medius and minimus muscles proximally (Fig. 4). The osteotomy line extends from the innominate eminence of the greater trochanter to beneath the gluteus minimus muscle. The optimal thickness of the fragment of the greater trochanter is 15 to 20 mm and, after completion of the acetabular osteotomy, will be fixed with two AO cancellous 6-mm screws and washers. Pre-drill the screws before the osteotomy to ensure the repair.
- Detach the gluteus medius and minimus muscles along the supraacetabular bone from the outer surface of the ilium, reflect them proximally 30 mm from the acetabular rim, and hold them with a Charnley pin retractor affixed to the ilium (Fig. 5).

#### Step 4: Deep Dissection to Mark the Osteotomy Lines

*Partially release and divide the rectus femoris, detach the iliacus, and retract the iliopsoas.*

- Begin the deep dissection by extending the hip to relax to posterior hip muscles, thereby facilitating exposure, and internally rotate the hip as necessary to improve the view of the surgical field. Extension is more important than internal rotation to obtain a better surgical field.
- Do not release the direct head of the rectus femoris muscle but partially release the reflected head to access the iliopubic prominence (pubic eminence) (Fig. 6). Divide the anterior part of the direct head of the rectus femoris muscle, and detach the iliacus muscle. Detach the underside of the reflected head of the rectus femoris muscle along the joint capsule and elevate it to enable the curved chisel to reach the pubic bone. Retract the iliopsoas tendon anteriorly, exposing the iliopubic prominence (pubic prominence). The osteotomy line of the pubic bone is 5 mm proximal to the iliopubic prominence (Fig. 7).
- A shallow spherical osteotomy line is made with

a 20-mm-wide curved chisel. The short rotator muscles are retracted to expose the posterior innominate fossa, and the posterior osteotomy line is marked with the electrocautery (Fig. 8).

#### Step 5: Osteotomy of Ilium and Ischium

*It is essential to use an osteotomy guide to perform an accurate spherical osteotomy.*

- The osteotomy line in the ilium and ischium is located by identifying the joint line and marking a distance approximately 20 mm from the joint line as verified with an injection needle.
- The osteotomy is begun with a 15-mm-wide straight chisel to a depth of approximately 5 to 10 mm (Fig. 9). The angle and direction of the osteotomy performed with a curved chisel is determined with an image intensifier according to the preoperative plan (Fig. 10). To prevent osteonecrosis, the acetabular fragment should be thicker than 15 mm.
- It is essential to use an osteotomy guide (Meira) to perform an accurate spherical osteotomy (Fig. 11). The radius of the osteotomy guide slot is 45 mm, with an outer edge surface and inner edge surface radius of 50 and 40 mm, respectively. If the radius of the acetabular fragment is 45 mm, use the slot within the guide. Use the outer edge surface for an acetabular fragment with a 50-mm radius and the inner edge for a 40-mm radius. First fix the osteotomy guide with the curved and straight chisels. Perform the osteotomy along the osteotomy guide slit. Perform the deep osteotomy with the curved and 3D chisels. Move the osteotomy guide posteriorly and anteriorly.
- For the entire length of the osteotomy along the ilium and ischium, start the osteotomy line using a straight chisel and deepen it with a 20-mm-wide 3D chisel (Fig. 12). Extend the osteotomy line, using the spherical osteotomy guide for assistance, to make a complete circle around the iliac and ischial borders of the acetabulum, thereby creating a spherical osteotomy.
- Complete and deepen the osteotomy medially around the inner wall of the acetabulum with the curved chisel, in a step-by-step manner by tilting the chisel anteriorly and posteriorly. When performing the anterior osteotomy of the ilium, be aware of a possible serious vascular injury. To prevent such an injury, an assistant should insert a retractor over the anterior aspect of the ilium beneath the iliacus muscle for retraction. As the osteotomy is enlarged and deepened, continue to replace the Hohmann and Langenbeck retractors as needed.
- It is important that the anterior and posterior

parts of the ilium be osteotomized meticulously in a spherical fashion with use of the spherical osteotomy guide, a 3D chisel, and a curved chisel so that the femoral head can shift medially and distally according to the preoperative plan (Fig. 13). As the spherical osteotomy guide has a limited arc, it is necessary to reposition the guide to obtain a complete osteotomy arc around the acetabulum.

### Step 6: Osteotomy of the Pubic Bone

*The osteotomy of the pubic bone is technically demanding.*

- Detaching the underside of the reflected head of the rectus femoris muscle along the joint capsule with an elevator enables the curved chisel to reach the pubic bone.
- With a deep muscle retractor, retract the iliopsoas muscle anteriorly, and palpate the temporary osteotomy line of the iliopubic eminence, previously made in Step 4, with the index finger of your nondominant, or assisting, hand.
- Start the pubic osteotomy using a 20-mm curved chisel in a spherical fashion (Fig. 7). The starting site of the pubic osteotomy is 5 mm proximal to the iliopubic prominence. Palpate the top of the iliopubic prominence firmly with the index finger of your nondominant hand, and insert the 20-mm curved chisel along your index finger into the previously made osteotomy cut. The curved chisel in the ilium and pubic bone should be used in a spherical manner. Continue and extend the pubic osteotomy in the direction of the iliac osteotomy, thereby joining the two osteotomy lines together. While directing the pubic osteotomy, make constant adjustments to ensure that it joins together with the iliac osteotomy.

### Step 7: Reorientation of the Acetabular Fragment

*The acetabular fragment can be rotated to the intended position as determined by the preoperative planning.*

- Retract the acetabular fragment with a bone hook.
- After trimming of bone and fibrous tissue, the acetabular fragment can be readily rotated to the intended position to the same degree as determined by the preoperative planning (Fig. 14). The two sharp hook retractors can control the direction of rotation because the acetabular fragment is spherical.
- Reorient the acetabular fragment only in the

lateral direction for a patient with pre-osteoarthritis or early-stage osteoarthritis (Fig. 15); do not rotate the acetabular fragment anteriorly to prevent femoroacetabular impingement. Rotate the acetabular fragment laterally and slightly anteriorly (1 cm) in patients with advanced-stage osteoarthritis.

- Verify the coverage of the femoral head and medialization and distalization with an image intensifier before temporarily fixing the acetabular fragment with a Kirschner wire (Fig. 16). The rotation is determined by the position of the sourcil, which should be horizontal.
- Once the reorientation of the acetabular fragment is optimal, fix it with three absorbable poly-L-lactic acid screws (NeoFix screw; Takiron) (Fig. 17). We ordinarily use three screws, two posteriorly and one anteriorly. If no absorbable screws are available, metal screws might suffice. If there is unusual space between the host bone and acetabular fragment, use autologous bone graft from the trimmed acetabular fragment; this is usually not necessary.

### Step 8: Reattachment of the Greater Trochanter

*Fix the greater trochanter with two AO cancellous screws.*

- Irrigate the operative field with saline solution.
- Fix the greater trochanter with two AO cancellous screws (diameter, 6 mm) and a washer (Fig. 18). Absorbable screw fixation is not recommended because of the high prevalence of fixation failure.
- Suture the short rotator muscles, and insert a suction drain below the fascia.

### Step 9: Postoperative Care

*Walking with a walker and partial weight-bearing begins one day after surgery, and full weight-bearing starts at two months postoperatively.*

- Patients should be allowed to walk as soon as possible to prevent deep vein thrombosis.
- One day after surgery, patients walk using a walker with 10 kg of partial weight-bearing. Full weight-bearing begins approximately two months after surgery.
- The ambulation schedule may be slower for patients with advanced osteoarthritis.

## Results

The clinical and radiographic outcomes in the first 126 consecutive patients (132 hips) who had undergone eccentric rotational acetabular osteotomy at our institution were retrospectively assessed<sup>12</sup>. Two patients (two hips) who were followed for less than fifteen years were excluded; thus, 124 patients (130 hips) were evaluated. Their mean age was thirty-seven years at the time of surgery, and the average duration of follow-up was twenty years. There was no serious complication such as major vascular injury or deep infection. The mean preoperative Harris hip score of 70 points improved to a mean of 88 points at the time of follow-up. Thirty hips had a fair clinical outcome (Harris hip score <80 points). Conversion to a total hip arthroplasty was performed in seventeen hips. The cumulative survivorship at fifteen years and at the time of final follow-up at twenty-three years was 97% and 80%, respectively.

## What to Watch For

### Indications

#### Best Candidates

- Symptomatic adults with hip dysplasia and pre-osteoarthritis or early-stage osteoarthritis (Tönnis grade 0 or 1), with no or slight joint space narrowing.
- Patients between fifteen and fifty years old with a good range of motion and joint congruity rated as excellent or good, according to the method described by Yasunaga et al.<sup>13,14</sup>, on an antero-posterior radiograph of the hip made in maximum abduction.

### Relative Indication

- Advanced-stage osteoarthritis (Tönnis grade 2) is a relative indication because the long-term results in patients with advanced osteoarthritis with a minimum joint space of  $\leq 2.0$  mm were significantly poorer than those in patients with advanced osteoarthritis with a minimum joint space of  $>2.0$  mm<sup>12</sup>.

### Contraindications

- Open triradiate cartilage
- End-stage osteoarthritis with a minimum joint space of  $\leq 2.0$  mm
- Poor joint congruity as seen on maximum abduction radiographs

### Pitfalls & Challenges

- The osteotomy site is approximately 20 mm (not less than 15 mm) from the joint space, and the angle and direction of the osteotomy are determined with an image intensifier based on the preoperative radiographic planning.
- In patients with early-stage osteoarthritis, fragment rotation is lateral, not anterior, to prevent femoroacetabular impingement and to maintain good flexion angles.
- To prevent the osteotomy from accidentally entering the hip joint, visually confirm the contour of the femoral head with an image intensifier and do not tilt the curved chisel too much toward the joint. If the chisel is tilted too much, it will enter the hip joint, especially when it used for the pubic osteotomy and the osteotomy of the posterior aspect of the ilium.

Yukiharu Hasegawa, MD, PhD

Department of Orthopedic Surgery, Nagoya University, Graduate School of Medicine, 65 Tsurumai-cho, Showa-ku, Nagoya City 466-8550, Japan. E-mail address: hassey@med.nagoya-u.ac.jp

**Disclosure:** The author received no payments or services, either directly or indirectly (i.e., via his institution), from a third party in support of any aspect of this work. Neither the author nor his institution has had any financial relationship, in the thirty-six months prior to submission of this work, with any entity in the biomedical arena that could be perceived to influence or have the potential to influence what is written in this work. Also, the author has not had any other relationships, or engaged in any other activities, that could be perceived to influence or have the potential to influence what is written in this work. The complete **Disclosures of Potential Conflicts of Interest** submitted by authors are always provided with the online version of the article.

## References

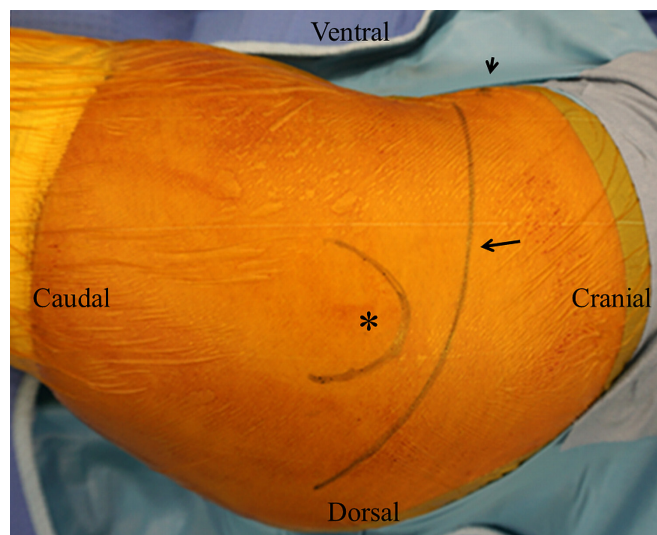
1. Cooperman DR, Wallensten R, Stulberg SD. Acetabular dysplasia in the adult. *Clin Orthop Relat Res.* 1983 May;175:79-85.
2. Hasegawa Y, Iwata H, Mizuno M, Genda E, Sato S, Miura T. The natural course of osteoarthritis of the hip due to subluxation or acetabular dysplasia. *Arch Orthop Trauma Surg.* 1992;111(4):187-91.
3. Schramm M, Hohmann D, Radespiel-Troger M, Pitto RP. Treatment of the dysplastic acetabulum with Wagner spherical osteotomy. A study of patients followed for a minimum of twenty years. *J Bone Joint Surg Am.* 2003 May;85(5):808-14.

4. Steppacher SD, Tannast M, Ganz R, Siebenrock KA. Mean 20-year followup of Bernese periacetabular osteotomy. *Clin Orthop Relat Res*. 2008 Jul;466(7):1633-44. Epub 2008 May 1.
5. Siebenrock KA, Schöll E, Lottenbach M, Ganz R. Bernese periacetabular osteotomy. *Clin Orthop Relat Res*. 1999 Jun;363:9-20.
6. Nakamura S, Ninomiya S, Takatori Y, Morimoto S, Umeyama T. Long-term outcome of rotational acetabular osteotomy: 145 hips followed for 10-23 years. *Acta Orthop Scand*. 1998 Jun;69(3):259-65.
7. Nozawa M, Shitoto K, Matsuda K, Maezawa K, Kurosawa H. Rotational acetabular osteotomy for acetabular dysplasia. A follow-up for more than ten years. *J Bone Joint Surg Br*. 2002 Jan;84(1):59-65.
8. Miller NH, Krishnan SG, Kamaric E, Noble PC. Long-term results of the dial osteotomy in the treatment of high-grade acetabular dysplasia. *Clin Orthop Relat Res*. 2005 Apr;433:115-23.
9. Ninomiya S, Tagawa H. Rotational acetabular osteotomy for the dysplastic hip. *J Bone Joint Surg Am*. 1984 Mar;66(3):430-6.
10. Ganz R, Klaue K, Vinh TS, Mast JW. A new periacetabular osteotomy for the treatment of hip dysplasias. Technique and preliminary results. *Clin Orthop Relat Res*. 1988 Jul;232:26-36.
11. Hasegawa Y, Iwase T, Kitamura S, Yamauchi Ki K, Sakano S, Iwata H. Eccentric rotational acetabular osteotomy for acetabular dysplasia: follow-up of one hundred and thirty-two hips for five to ten years. *J Bone Joint Surg Am*. 2002 Mar;84(3):404-10.
12. Hasegawa Y, Iwase T, Kitamura S, Kawasaki M, Yamaguchi J. Eccentric rotational acetabular osteotomy for acetabular dysplasia and osteoarthritis: follow-up at a mean duration of twenty years. *J Bone Joint Surg Am*. 2014 Dec 3;96(23):1975-82.
13. Yasunaga Y, Takahashi K, Ochi M, Ikuta Y, Hisatome T, Nakashiro J, Yamamoto S. Rotational acetabular osteotomy in patients forty-six years of age or older: comparison with younger patients. *J Bone Joint Surg Am*. 2003 Feb;85(2):266-72.
14. Yasunaga Y, Ochi M, Terayama H, Tanaka R, Yamasaki T, Ishii Y. Rotational acetabular osteotomy for advanced osteoarthritis secondary to dysplasia of the hip. *J Bone Joint Surg Am*. 2006 Sep;88(9):1915-9.



**Fig. 1**

Surgical instruments: Charnley pin retractor (**Fig. 1-A**), 15-mm-wide curved chisel (**Fig. 1-B**), 20-mm-wide curved chisel (**Fig. 1-C**), 3D spherically curved chisel (45-mm radius in three dimensions) (**Fig. 1-D**), and spherical osteotomy guide (45-mm radius in three dimensions) (**Fig. 1-E**). We developed a very thin osteotomy guide that will adjust the radius 45 or 40 mm. We tried many osteotomy guides and found thick rigid guides to be problematic.



**Fig. 2**

The left hip is prepared and draped. (The patient's head is to the right side of the photograph. The upper side is ventral and the bottom side is dorsal.) The bikini skin incision (larger arrow) is made approximately 3 cm proximal to the tip of the greater trochanter. The smaller arrow points to the anterior inferior iliac spine. The asterisk indicates the greater trochanter.

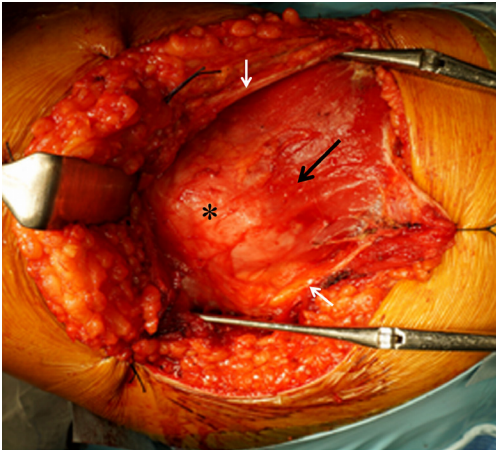


Fig. 3-A

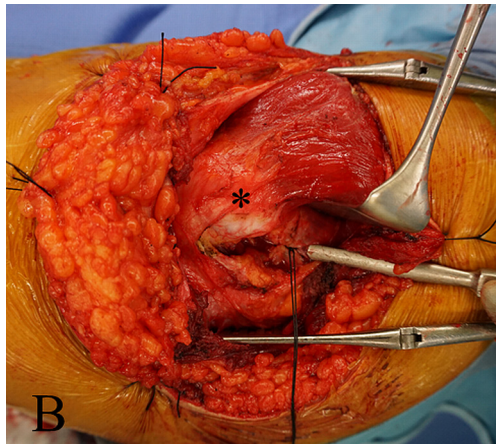


Fig. 3-B

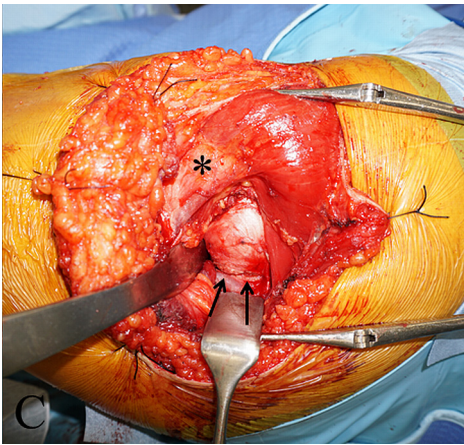


Fig. 3-C

**Fig. 3-A** The superficial dissection exposes the greater trochanter (asterisk). A Y-shaped incision of the tensor fasciae latae (white arrows) allows complete anterior and posterior exposure of the gluteus medius muscle (black arrow) and gluteus minimus muscle. **Fig. 3-B** The short external rotator muscles have been tagged and divided. **Fig. 3-C** The innominate fossa is exposed by using a Hohmann retractor beneath the inferior aspect of the femoral neck and a Langenbeck retractor on the posterior edge of the posterior column, thereby exposing the posterior osteotomy line (arrows). The asterisks indicate the greater trochanter.

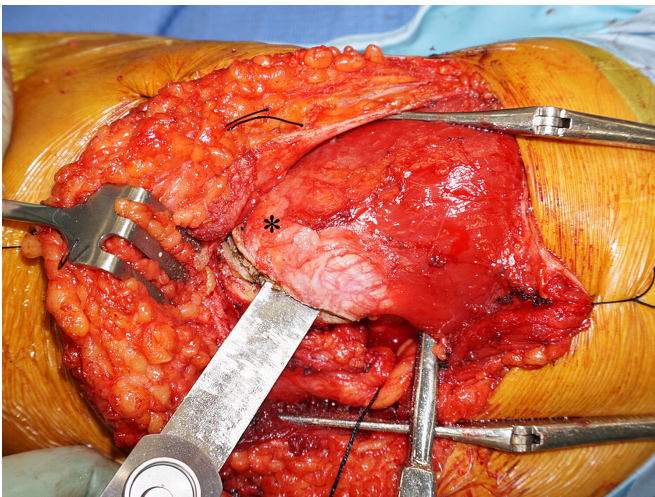


Fig. 4

The greater trochanter (asterisk) is detached with an oscillating bone saw.

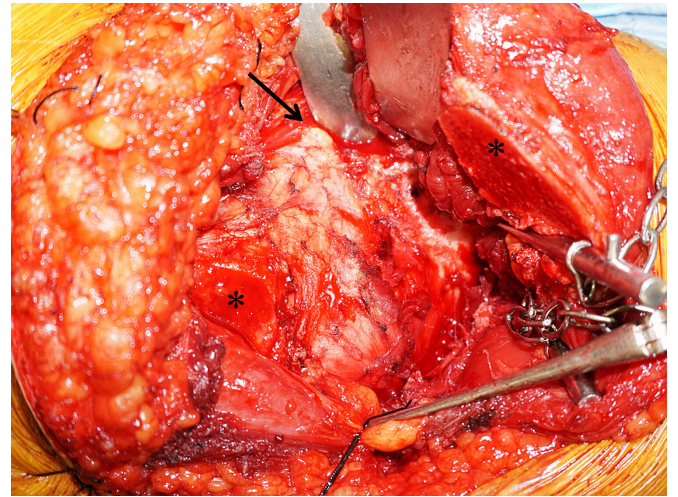
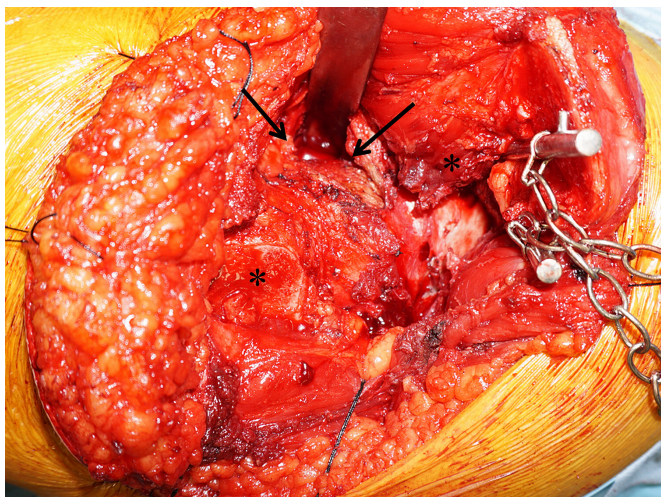
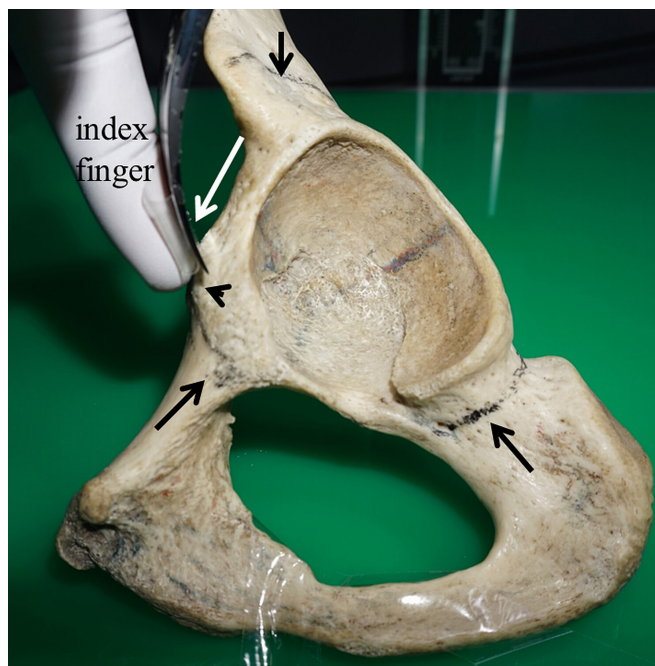


Fig. 5

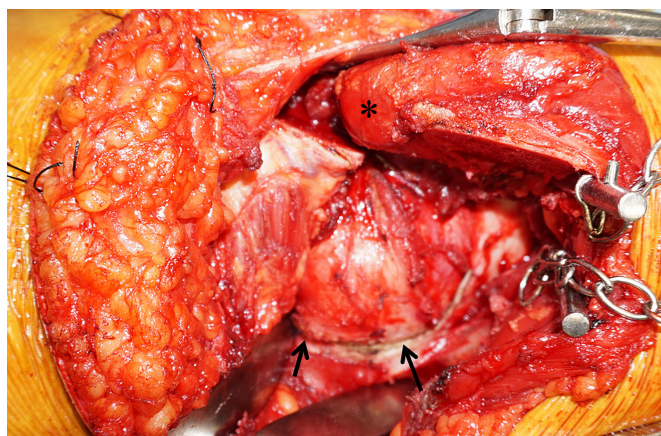
The gluteal muscles are detached, reflected proximally 30 mm away from the acetabular rim, and held with a Charnley pin retractor. The direct head of the rectus femoris (arrow) is exposed. The underside of the reflected head of the rectus femoris muscle is detached along the joint capsule to palpate the iliopubic prominence. The asterisks indicate the greater trochanter.



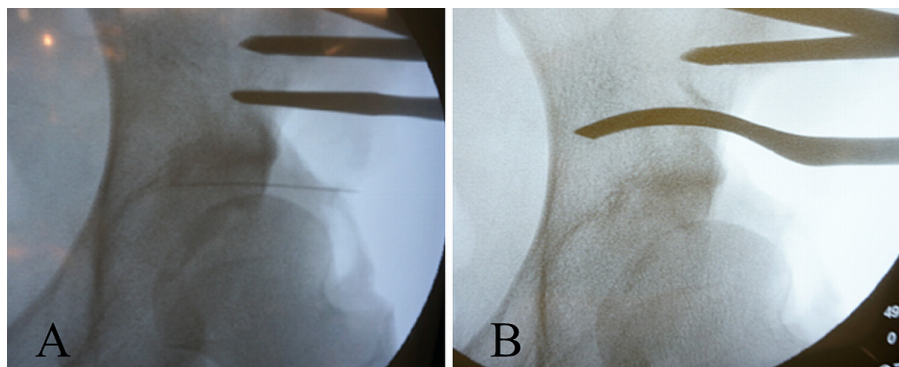
**Fig. 6**  
The direct head of the rectus femoris is not released, but the reflected head (arrows) is partially released to access the iliopubic prominence (just below the arrows). The asterisks indicate the greater trochanter.



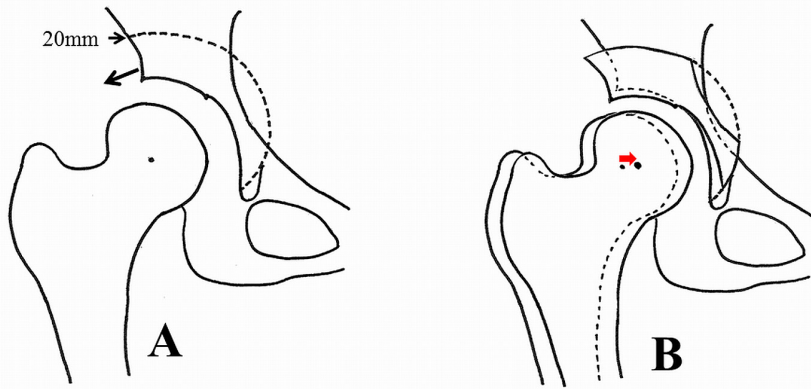
**Fig. 7**  
Bone model showing the pubic osteotomy site 5 mm proximal to the iliopubic prominence. The top of the iliopubic prominence (arrowhead) is palpated with the index finger of the surgeon's nondominant hand. A curved chisel (20 mm in width) is inserted along the index finger (white arrow). A shallow osteotomy is made to identify the osteotomy site. The iliac osteotomy line (short black arrow) and the pubic and ischial osteotomy lines (longer black arrows) are drawn on the model.



**Fig. 8**  
The posterior innominate fossa is exposed and the posterior osteotomy line (arrows) is marked. The asterisk indicates the greater trochanter.

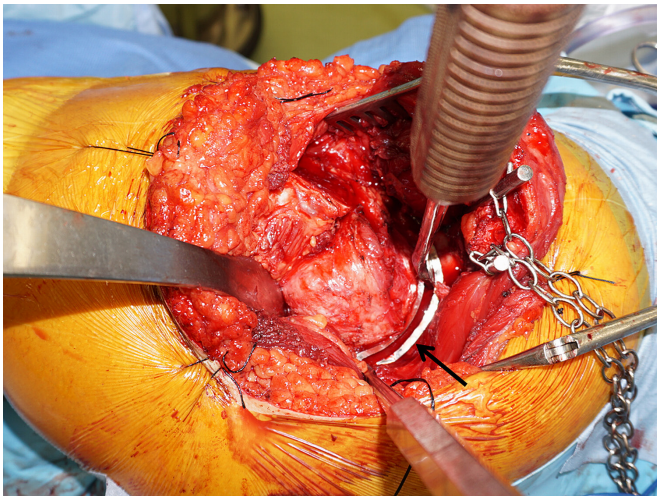


**Fig. 9**  
The osteotomy site, which is approximately 20 mm from the joint space, is marked with a straight chisel (Fig. 9-A), and the osteotomy is performed with a 15-mm-wide curved chisel (Fig. 9-B) according to the preoperative plan.



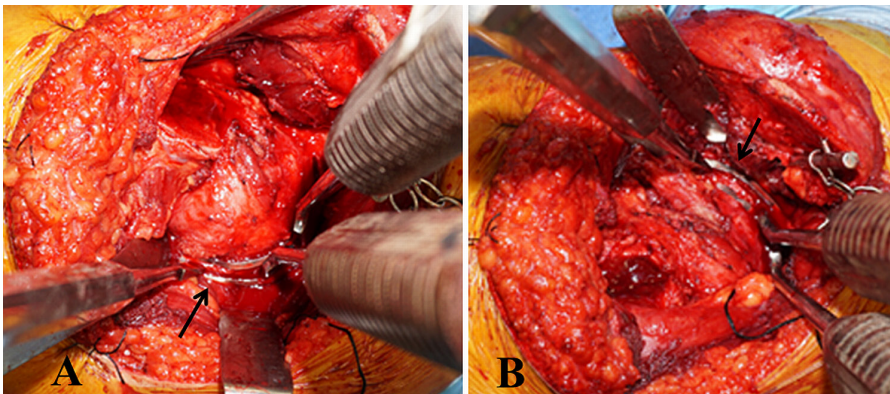
**Fig. 10**

Preoperative plan for the osteotomy. **Fig. 10-A** The osteotomy line is 20 mm from the joint space. **Fig. 10-B** The source is maintained horizontal to cover the femoral head with the acetabular bone fragment. The center of the femoral head is moved medially (red arrow).



**Fig. 11**

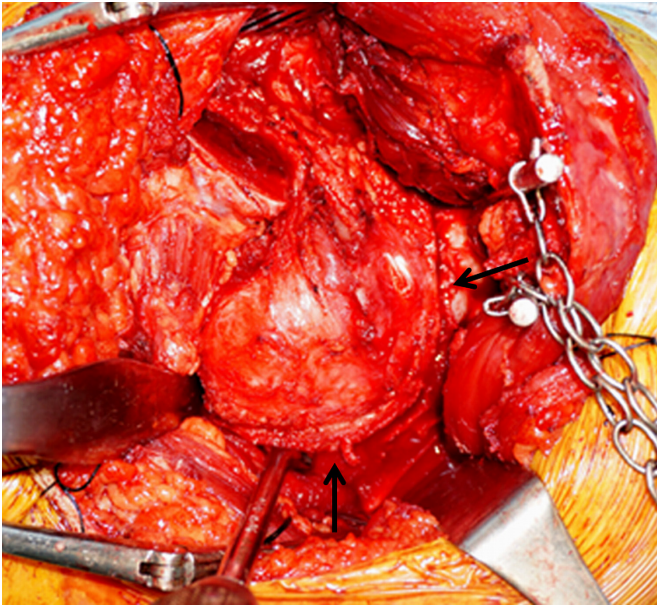
The spherical osteotomy guide (arrow) is fixed by two chisels in the ilium to enable the surgeon to make an accurate osteotomy line. The osteotomy is performed along the slit of the osteotomy guide.



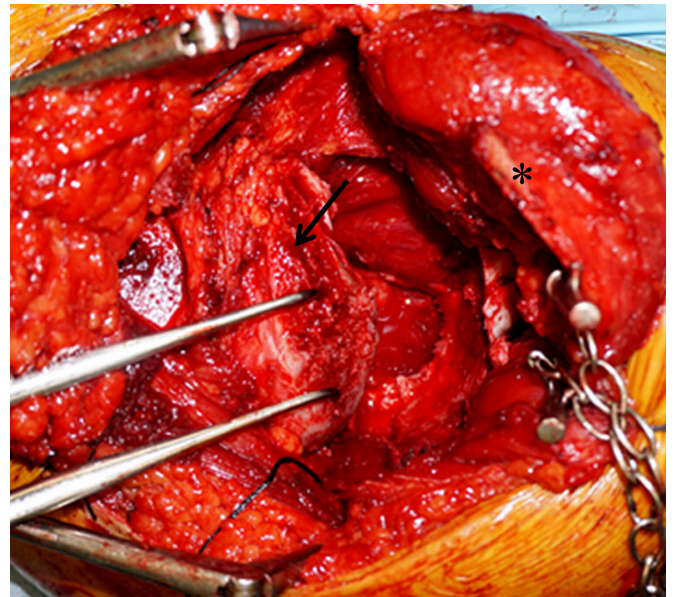
**Fig. 12**

The osteotomy line is deepened, and the osteotomy is performed in a spherical fashion with use of a 3D curved chisel. **Fig. 12-A** Posterior iliac osteotomy (arrow). **Fig. 12-B** Anterior iliac osteotomy (arrow).

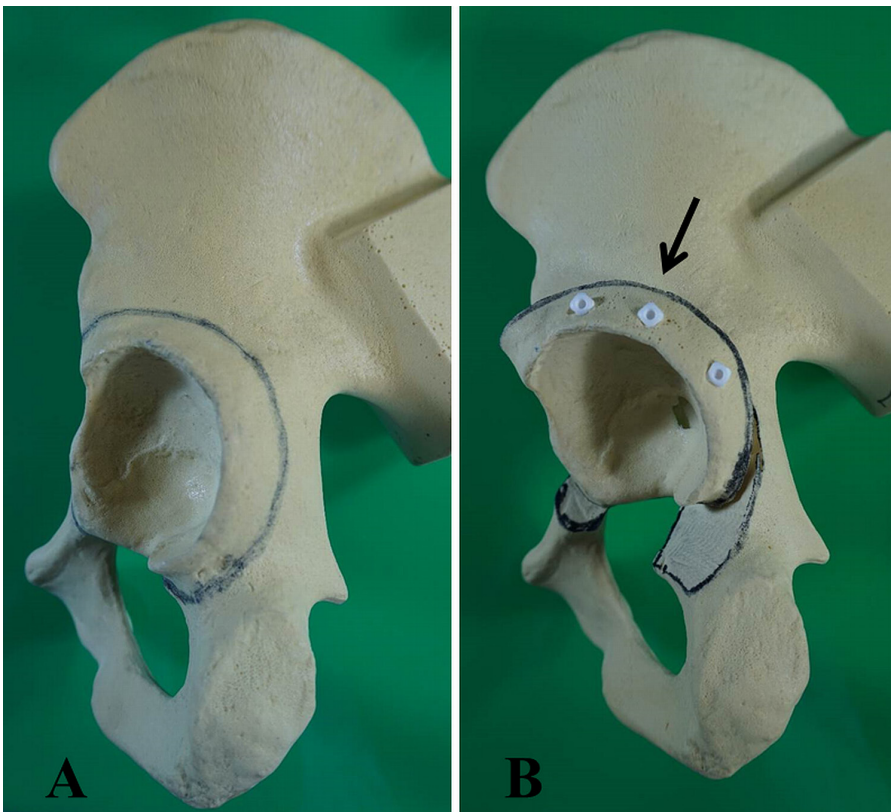




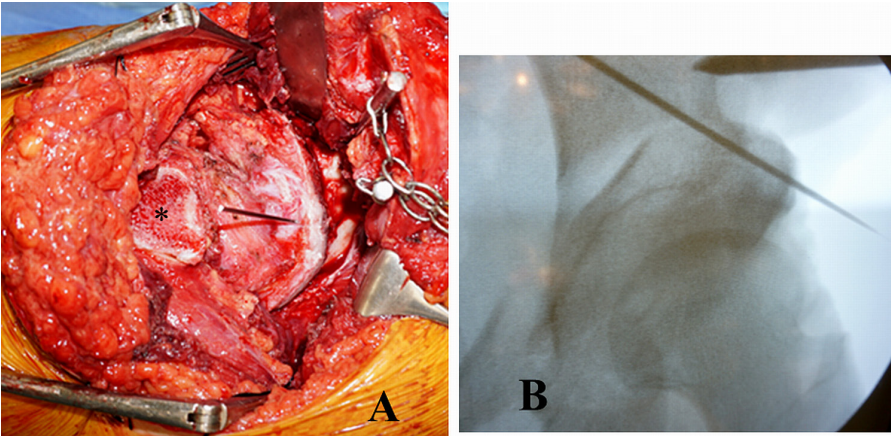
**Fig. 13**  
Completing the osteotomy of the ilium and ischium. The osteotomy line is marked by the arrows.



**Fig. 14**  
The acetabular fragment (black arrow) is retracted with two sharp retractors. The bone is then trimmed. The asterisk indicates the greater trochanter.

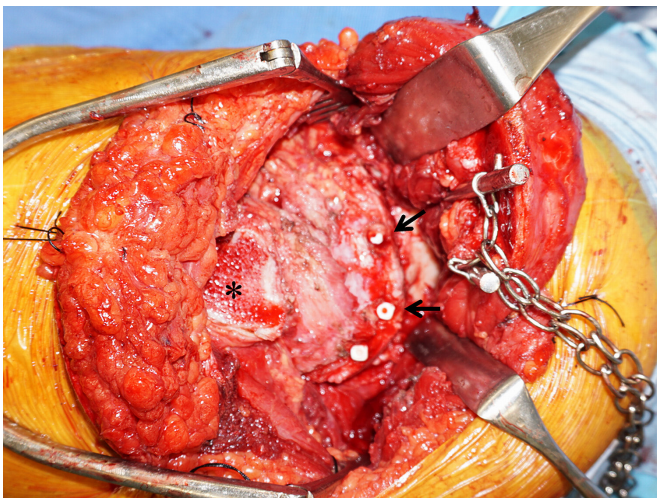


**Fig. 15**  
**Fig. 15-A** Bone model showing the osteotomy line of the acetabular fragment. **Fig. 15-B** The acetabular fragment is rotated only laterally to prevent femoroacetabular impingement. The arrow defines the direction of rotation.



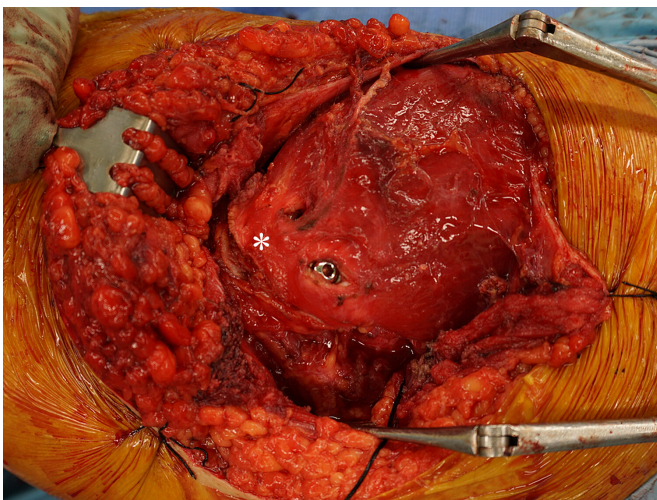
**Fig. 16**

**Fig. 16-A** The acetabular fragment is fixed with a Kirschner wire. The asterisk indicates the greater trochanter. **Fig. 16-B** Anteroposterior fluoroscopic image confirming that the coverage of the femoral head is optimal—i.e., the same as in the preoperative plan. The source should be horizontal.



**Fig. 17**

The acetabular fragment is fixed by three poly-L-lactic acid screws (arrows). The asterisk indicates the greater trochanter.



**Fig. 18**

The greater trochanter (asterisk) is fixed with two AO screws.