

Contents lists available at [ScienceDirect](http://www.sciencedirect.com)

International Journal of Surgery Case Reports

journal homepage: www.casereports.com

Mesh expansion as the cause of bulging after abdominal wall hernia repair

E.B. Deerenberg (MD)^{a,*}, J. Verhelst (MD)^a, S.E.R. Hovius (MD, PhD)^b, J.F. Lange (MD, PhD)^a^a Department of Surgery, Erasmus University Medical Center Rotterdam, The Netherlands^b Department of Plastic and Reconstructive Surgery, Erasmus University Medical Center Rotterdam, The Netherlands

ARTICLE INFO

Article history:

Received 7 August 2016

Received in revised form

20 September 2016

Accepted 28 September 2016

Available online 30 September 2016

Keywords:

Abdominal wall reconstruction

Bulging

Recurrence

Mesh

Case report

ABSTRACT

BACKGROUND: Recurrence is the most important complication of abdominal wall reconstruction. It is possible the repair itself is intact, but bulging or expansion of mesh causes recurrent swelling's of the abdominal wall.

CASE SUMMARY: In this report, we present bulging of a polyester mesh due to central pore expansion.

DISCUSSION: Repetitive stress and variations in intra-abdominal pressure can change tensile strength and stretches mesh materials.

CONCLUSION: A swelling after abdominal wall repair can be caused by bulging of the mesh. A progressive bulging might be the result of failure of the mesh implant due to elongation. Mesh characteristics should be considered when choosing a feasible and suitable mesh for abdominal wall reconstruction. Clinical distinction between recurrent hernia and mesh bulging is difficult but therapeutically irrelevant in symptomatic patients.

© 2016 The Author(s). Published by Elsevier Ltd on behalf of IJS Publishing Group Ltd. This is an open access article under the CC BY-NC-ND license (<http://creativecommons.org/licenses/by-nc-nd/4.0/>).

1. Introduction

Recurrence is the most important complication of abdominal wall reconstruction. In order to reduce recurrence rates meshes are used as reinforcement of augmentation or bridging of large abdominal wall defects. Numerous meshes are available worldwide, differing in material, pore size, weight, tensile strength, elasticity and biocompatibility. These characteristics influence the risk of failure of repair. Swelling or bulge in the area of previous abdominal wall reconstruction is suggestive for recurrence, although not obligatory to be so [1,2]. It is possible that the repair is still intact and bulging of the mesh causes swelling. Bulging can be the result of an insufficient surgical technique. The problem is more frequently seen after repair of large defects [1], especially when mesh are used to bridge the defects [1,3] and more frequent after laparoscopic repair [2–4]. In this article we present the phenomenon of symptomatic bulging due to failure of a polyester mesh.

2. Time-line

2004 necrotizing fasciitis

2005–2008 4-staged repair of abdominal wall with polyester mesh

2012 symptomatic bulging of repair due to enlargement of the mesh. Excision part of mesh.

2015 recurrent symptomatic bulging of the mesh. Excision polyester mesh and replacement by polypropylene mesh

3. Case

A 43-year-old male was referred to the outpatient clinic with severe bulging of the complete right hemi abdomen. One year before he developed necrotizing fasciitis, extending from the right knee to the right thoracic wall resulted in a resection of the right abdominal wall. The patient was left with multiple scars from the right upper leg to the right thorax consisting mainly skin grafts. The abdominal wall consisted of skin grafts and peritoneum. The patient experienced reduced quality of life and discomfort. A four-staged repair over three years was performed in order to reconstruct the abdominal wall. Finally in 2008, the defect was closed in with two (sutured together) collagen-coated polyester meshes of 20*30 cm (Parietex Composite®, Covidien, France). A coated mesh was implanted since contact with the visceral organs was inevitable with the loss of abdominal wall and bridging position of the mesh.

* Corresponding author at: ErasmusMC, Department of Surgery, Room H-822k, PO Box 2040, 3000 CA Rotterdam, The Netherlands.

E-mail addresses: e.deerenberg@erasmusmc.nl (E.B. Deerenberg), j.verhelst@erasmusmc.nl (J. Verhelst), s.e.r.hovius@erasmusmc.nl (S.E.R. Hovius), j.lange@erasmusmc.nl (J.F. Lange).

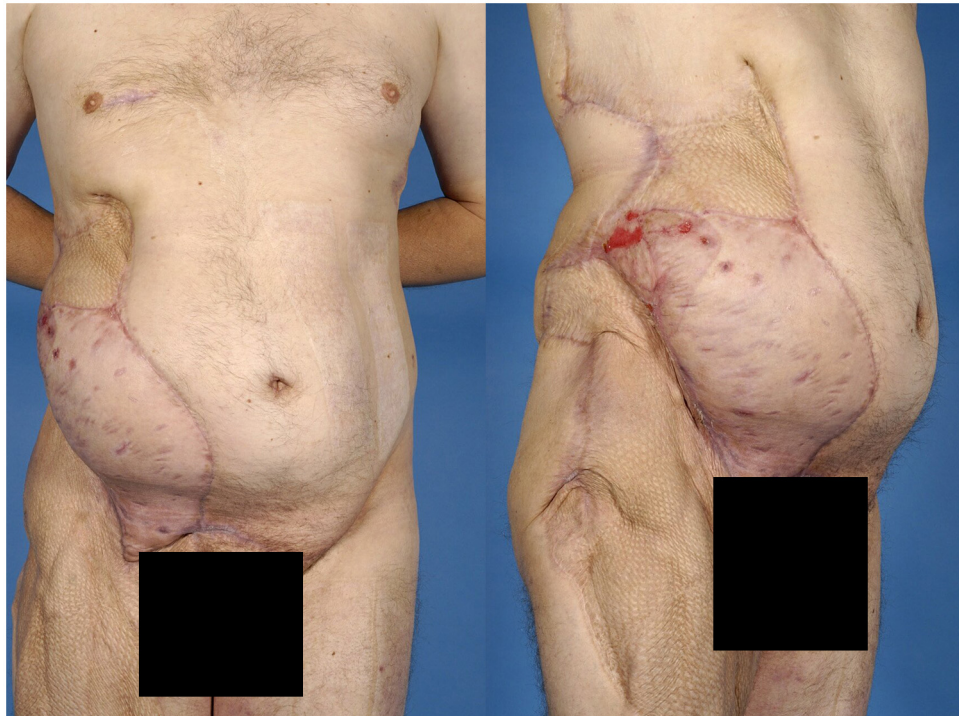


Fig. 1. Abdominal wall after four-staged repair with Parietex Composite® mesh and latissimus dorsi flap (2008).

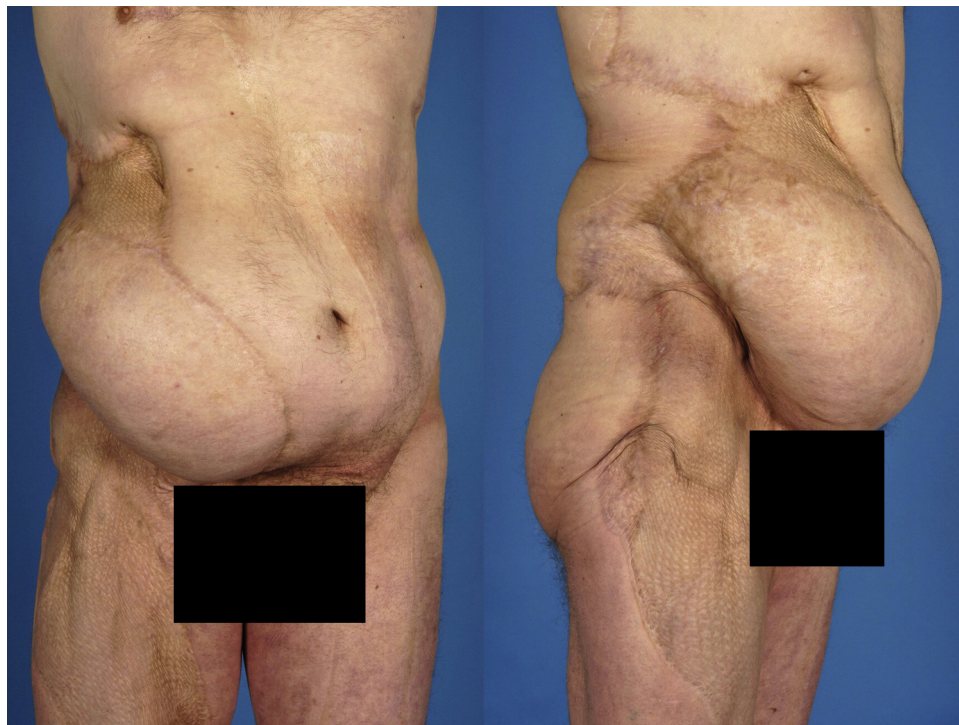

Fig. 2. Increased bulging of the abdominal wall four years after reconstruction (2012).

The soft tissue defect was repaired at the sides of the hernia with skin obtained by using multiple tissue expanders. The soft tissue defect was covered with a free vascularized latissimus dorsi flap with large full thickness skin graft (Fig. 1). Four years after the final repair the patient returned to the outpatient department with progressive swelling of the right lower abdomen (Fig. 2). He suffered from abdominal pain and protrusion that interfered with his work.

A CT-scan was performed, showing an intact repair, but enlargement of the mesh (Fig. 3). A surgical procedure was planned to repair the bulging abdominal wall. During surgery the bulging was found to be caused by expansion of an intact mesh. The elongation was caused by a striking central pore expansion from 1.5 to 2.5 mm (Fig. 4). Surgical excision of the central part of the mesh was performed to tighten the mesh and reduce the bulging. 30

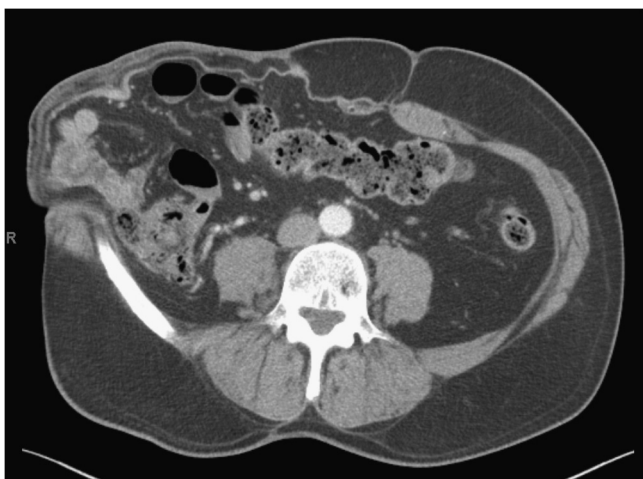

Fig. 3. CT-scan of bulging mesh four years after reconstruction (2012).




Fig. 4. Pore size of explanted polyester mesh compared to original mesh (2102). (A) Pore size (1.5 mm) of original mesh (Parietex Composite®, Covidien, France). (B) Increased pore size (2.5 mm) of explanted mesh (Parietex Composite®, Covidien, France).

months later the patient developed swelling of the right abdominal wall again. The patient was planned for repair. During the procedure the mesh was still in tact but there was ongoing expansion of the mesh. The mesh has been removed and replaced by a 20*30 polypropylene collagen-coated mesh (Parietene Composite®, Covidien, France) in bridging position. A heavy-weight propylproylene mesh was implanted to provide the maximum tensile strength to prevent failure of the repair [5]. Follow-up of over 1 year did not show any bulging.

4. Discussion

In this case symptomatic bulging at the hernia repair site was caused by elongations of the mesh due to pore enlargement. Each mesh used for hernia repair has certain features that determine the mechanical properties. During normal daily activities, mesh material is exposed to stress subsequent to changes in intra-abdominal pressure. The intra-abdominal pressure can raise up to 100 mmHg during coughing and can reach 250 mmHg during vomiting or jumping [6,7]. When abdominal wall defects are repaired using a bridging technique the material has to withstand the tensile stress at the borders.

Normal daily activities require a tensile strength of 16 N/cm and strenuous activities a maximum tensile strength 42–47 N/cm [5,8]. Medium-weight and heavy-weight meshes made of polyester,

polypropylene or (expanded) polytetrafluoroethylene (ePTFE) provide the maximum tensile strength to prevent failure of the repair [5]. In our patient polyester mesh was a valid choice for the first repair with regard to the tensile strength. The elasticity of a mesh should correspond to the elasticity of the abdominal wall to prevent foreign body sensation or discomfort of stiffness. Biomechanical studies have shown low stretch properties of meshes, only up to 3.5% during normal daily activities due to the very large diameter of the filaments [5]. However, other biomechanical studies show that repetitive stress can change the tensile strength and stretches mesh materials [9]. These studies did not test the polyester meshes, but in our case, elongation of polyester filaments is clearly demonstrated.

Bulging is an important adverse effect after abdominal wall repair. Incidences of bulging vary from 1.6% to 17.4% [2–4]. Clinical distinction between recurrence and bulging of mesh is difficult [1–3]. Differentiation is therapeutically irrelevant in symptomatic patients, because for both conditions surgical repair is indicated. Asymptomatic patients however do not require repair in the case of mesh bulging, except for cosmetic reasons. Radiologic imaging can be used to establish the right diagnosis. The use of CT-scans to distinguish between bulging or recurrence can be challenging because polypropylene meshes are visible lines with densities similar to adjacent muscle and can better be identified with ultrasound [10–12]. When performing surgical repair for symptomatic bulging it is often not necessary to remove the implanted mesh when incorporation is sufficient. With open approach the mesh can be partly excised to tighten the repair or the mesh can be removed and replaced. In this case however, bulging was an ongoing process, that finally resulted in mesh explantation and placement of a new mesh. In asymptomatic patients a watchful waiting approach seems justified [2].

5. Conclusion

A swelling after abdominal wall repair can be caused by bulging of the mesh. A progressive bulging might be the result of failure of the mesh implant due to elongation. The distinction between a recurrence and bulging of the mesh remains difficult even with radiological examinations but is therapeutically irrelevant in symptomatic patients.

Conflicts of interest

All authors declare no conflict of interest.

Sources of funding

None.

Ethical approval

Not applicable.

Informed consent

Written informed consent to publish the medical history and photographs of the patient was obtained.

Contribution of authors

All authors have made substantial contributions to all of the following: (1) the conception and design of the study, or acquisition of data, or analysis and interpretation of data, (2) drafting the article or revising it critically for important intellectual content, (3) final approval of the version to be submitted.

Contributions Deerenberg and Verhelst: study design, collection of mesh samples, measurements of mesh, collection of photographs, writing the paper and approving final submission.

Contributions Hovius and Lange: study design, performing several operations on patient, follow-up through the period of the case report, assistance in writing the paper and approving final submission.

Guarantor

Not applicable.

References

- [1] J. Heisterkamp, P.T. den Hoed, J. Kluin, W.F. Weidema, C.J. van Steensel, Long-term results after modified Gallie technique for incisional hernia repair: results in 19 patients, *Hernia* 9 (2005) 12–15.
- [2] E.J. Schoenmaeckers, E.B. Wassenaar, J.T. Raymakers, S. Rakic, Bulging of the mesh after laparoscopic repair of ventral and incisional hernias, *JLS* 14 (2010) 541–546.
- [3] K. Mitura, M. Skolimowska-Rzewuska, K. Garnysz, Outcomes of bridging versus mesh augmentation in laparoscopic repair of small and medium midline ventral hernias, *Surg. Endosc.* (2016), <http://dx.doi.org/10.1007/s00464-016-4984-9>.
- [4] A. Kurmann, E. Visth, D. Candinas, G. Beldi, Long-term follow-up of open and laparoscopic repair of large incisional hernias, *World J. Surg.* 35 (2011) 297–301.
- [5] C.R. Deeken, M.S. Abdo, M.M. Frisella, B.D. Matthews, Physicomechanical evaluation of polypropylene, polyester, and polytetrafluoroethylene meshes for inguinal hernia repair, *J. Am. Coll. Surg.* 212 (2011) 68–79.
- [6] W.S. Cobb, J.M. Burns, K.W. Kercher, B.D. Matthews, H. James Norton, B. Todd Heniford, Normal intraabdominal pressure in healthy adults, *J. Surg. Res.* 129 (2005) 231–235.
- [7] A. Iqbal, M. Haider, R.J. Stadlhuber, A. Karu, S. Corkill, C.J. Filipi, A study of intragastric and intravesicular pressure changes during rest, coughing, weight lifting, retching, and vomiting, *Surg. Endosc.* 22 (2008) 2571–2575.
- [8] U. Klinge, B. Klosterhalfen, J. Conze, W. Limberg, B. Obolenski, A.P. Ottinger, Modified mesh for hernia repair that is adapted to the physiology of the abdominal wall, *Eur. J. Surg.* 164 (1998) 951–960.
- [9] B.J. Eliason, M.M. Frisella, B.D. Matthews, C.R. Deeken, Effect of repetitive loading on the mechanical properties of synthetic hernia repair materials, *J. Am. Coll. Surg.* 213 (2011) 430–435.
- [10] K. Gossios, A. Zikou, P. Vazakas, G. Passas, A. Glantzouni, G. Glantzounis, Value of CT after laparoscopic repair of postsurgical ventral hernia, *Abdom. Imaging* 28 (2003) 99–102.
- [11] J.A. Parra, S. Revuelta, T. Gallego, J. Bueno, J.I. Berrio, M.C. Farinas, Prosthetic mesh used for inguinal and ventral hernia repair: normal appearance and complications in ultrasound and CT, *Br. J. Radiol.* 77 (2004) 261–265.
- [12] E.J. Schoenmaeckers, S.B. van der Valk, H.W. van den Hout, J.F. Raymakers, S. Rakic, Computed tomographic measurements of mesh shrinkage after laparoscopic ventral incisional hernia repair with an expanded polytetrafluoroethylene mesh, *Surg. Endosc.* 23 (2009) 1620–1623.

Open Access

This article is published Open Access at sciendoirect.com. It is distributed under the [IJSCR Supplemental terms and conditions](#), which permits unrestricted non commercial use, distribution, and reproduction in any medium, provided the original authors and source are credited.