

# Subarachnoid Pleural Fistula Due to Gunshot Wound

## Ateşli Silah Yaralanması Sonrası Subaraknoid Plevral Fistül

Birdal GULLUPINAR,<sup>1</sup> Hakan TOPACOGLU<sup>2</sup>

<sup>1</sup>Department of Emergency Medicine, Toros Training and Research Hospital, Mersin;

<sup>2</sup>Department of Emergency Medicine, Istanbul Training and Research Hospital, Istanbul

### SUMMARY

Subarachnoid pleural fistula (SPF) is an extremely rare complication that occurs after dural space and vertebral columns injuries. SPF is divided into two diagnoses based on the absence or presence of pneumocephalus and pneumorrhachis. While pneumocephalus is defined as the presence of air the cranial cavity, if there is air in the spinal canal, this is defined as pneumorrhachis. In general, the association of SPF with pneumocephalus and pneumorrhachis is rare but can occur after blunt trauma. In our patient, pneumorrhachis and pneumocephalus with SBF developed after the patient suffered a gunshot wound. This paper reports an SPF case accompanied by pneumorrhachis and pneumocephalus, which occurred after thoracic spine injury due to a gunshot wound.

**Key words:** Gunshot; pneumocephalus, pneumorrhachis; subarachnoid pleural fistula.

### ÖZET

Subaraknoid plevral fistül (SPF) son derece nadir bir komplikasyondur. Dural aralık ve vertebral kolonların hasarı sonrası oluşur. SPF pnö-mosefali ve pnömorachis yokluğu ve varlığı şeklinde iki gruba ayrılır. Pnö-mosefali, kraniyal kavite içerisinde hava bulunması olarak tanımlanırken spinal kanala hava girmesine ise pnömorachis denir. Genelde pnö-mosefali ve pnömorachis ile SPF birlikteliği nadirdir ve künt travma sonrası gelişir. Ancak bizim hastamızda pnö-mosefali ve pnö-morachis ile SPF birlikteliği ateşli silah yaralanması sonrası gelişmiştir. Bu yazıda, ateşli silah yaralanması sonrası torakal omurga yaralanmasının neden olduğu pnömorachis ve pnö-mosefali bulunan SPF olgusu sunuldu.

**Anahtar sözcükler:** Ateşli silah yaralanması; pnö-mosefali; subaraknoid plevral fistül.

### Introduction

Subarachnoid pleural fistula (SPF) is an extremely rare complication that occurs after injury of dural space and vertebral columns.<sup>[1]</sup> In SPF, both pneumocephalus and pneumorrhachis may be seen. Pneumocephalus is defined as the presence of air in cranial cavity<sup>[2]</sup> and is most commonly caused by trauma. It has been reported that the incidence of the pneumocephalus due to trauma is 5.6%.<sup>[3]</sup> A rare condition in which air enters the spinal canal after trauma is called pneumorrhachis. Occurrence of pneumorrhachis is frequently asymptomatic and does not require any specific treatment because air is reabsorbed spontaneously without leaving any neurological sequelae.<sup>[4]</sup> This paper reports an SPF case accompanied by

pneumorrhachis and pneumocephalus, which occurred after thoracic spine injury due to a gunshot wound.

### Case Report

A 20-year-old male patient with a gunshot wound was brought to the emergency room by air ambulance. His medical history was normal. In the emergency department, he had a poor general condition: he was unconscious, non-oriented, and non-cooperative. Glasgow Coma Scale was evaluated as E1M5Vt. The patient was brought in intubated with bilateral chest tube. His blood pressure was 86/43 mmHg, cardiac pulse 86 beat/min, respiration rate 24 breaths/min, axilla temperature 36.7 °C, and oxygen saturation 96%.

**Submitted:** August 06, 2013 **Accepted:** October 22, 2013 **Published online:** January 07, 2014

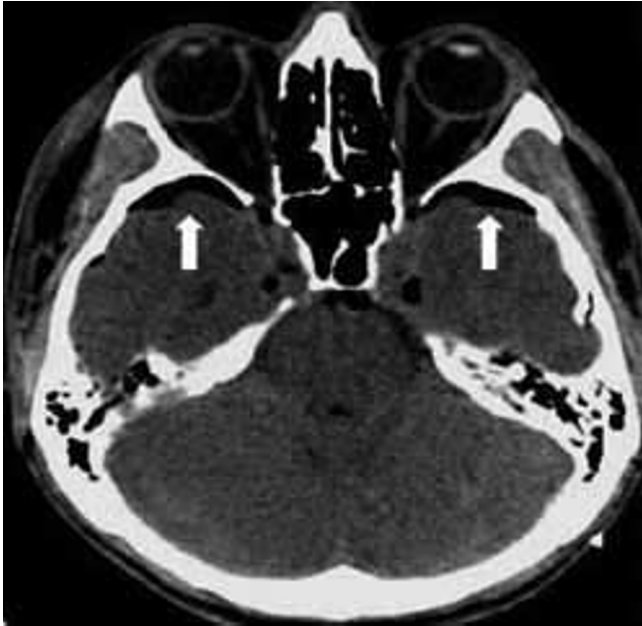
**Correspondence:** Dr. Birdal Gullupinar. Toros Devlet Hastanesi, Acil Servis, Akdeniz, 33330 Mersin, Turkey.

**e-mail:** birdalg@yahoo.com

© 2014 Emergency Medicine Association of Turkey. Production and Hosting by Elsevier B.V. Originally published in [2014] by Kare Publishing. This is an open access article under CC BY-NC-ND license (<http://creativecommons.org/licenses/by-nc-nd/4.0/>)

Turk J Emerg Med 2014;14(2):87-89 doi: 10.5505/1304.7361.2014.93271





**Figure 1.** Bilateral pneumocephalus in brain CT.

While examining the patient's head and neck, it was observed that there was a laceration on the right parietal and frontal area and also a subcutaneous emphysema spanning from the right side of neck to inguinal region. In respiratory system examination, the bullet entry hole on the posterior region of left shoulder and bullet exit hole on anterior of right shoulder were detected. Examination of other systems yielded normal findings.

Computed tomography (CT) of the brain and maxillofacial area exhibited bilateral putamen, cerebellar haemorrhage, and pneumocephalus without any bone fracture (Figure 1). In CT of cervical vertebrae and thorax, a fracture in T2 ver-

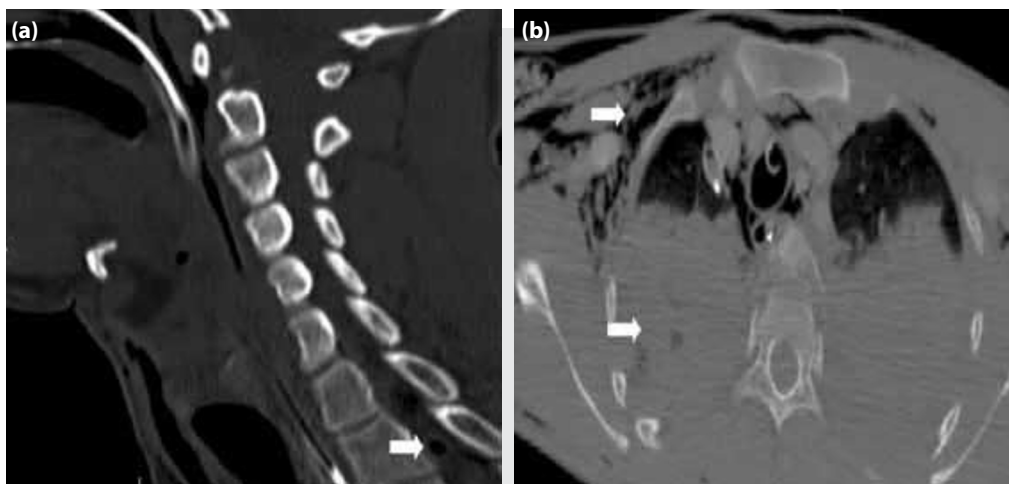
tebra along with pneumorrhachis, haemopneumothorax, and pneumomediastinum were detected (Figure 2a, b). In other tomographic examinations no acute pathologies were observed. The patient was transferred to ICU after consultation with anesthesia and reanimation clinics. The patient died on the seventh day in anesthesia ICU.

## Discussion

SPF can be caused by blunt or penetrating trauma. The main cause of blunt and penetrating traumas are motor vehicle accidents and gunshot injuries.<sup>[5]</sup> SPF is divided into two groups: the first group consists of absence of radiological pneumorrhachis and pneumocephalus, and the second group is defined as the presence of pneumocephalus and pneumorrhachis. The second group is rare and the most common feature of this group is its secondary occurrence after blunt trauma.<sup>[6]</sup> However, in this case, pneumorrhachis and pneumocephalus developed after a gunshot wound not due to a blunt trauma. Pneumocephalus and pneumorrhachis are important radiological findings that may indicate serious pathologies.

Pneumocephalus develops after a trauma if there is a dural membrane tear, leading to contact with air and greater air pressure in this area compared to the cerebrospinal fluid (CSF) pressure. This is rare if no tension pneumothorax is present as the pressure of pleural space is under atmospheric pressure.<sup>[6]</sup> In this case, the patient did not have tension pneumothorax. For this reason, it is thought that high air pressure may also cause secondary pneumocephalus and SPF without tension pneumothorax.

Pressure can change depending on the patient's position. Intratechal pressure at thoracic vertebra level injuries is pro-



**Figure 2.** The fracture of T2 vertebra with pneumorrhachis (a), haemopneumothorax and pneumomediastinum (b).

bably low in supine position and under the state of shock.<sup>[7]</sup> In addition, CSF production decreases about 30% after stimulation of the sympathetic nervous system. In this case, a decrease in CSF production resulting in decrease in CSF pressure can lead to formation of SPF easily as observed in our patient. Wide dural defect due to gunshot wound can lead to the loss of a large amount CSF, a condition that causes CSF pressure to be reduced to zero. In addition, high intrathoracic pressure caused by gunshot shock wave may be higher than that of cerebrospinal fluid pressure. In our case, it is thought that the patient developed pneumocephalus and SPF due to pressure changes at high altitudes during patient transfer to ER by air ambulance.

There is no definitive method in the treatment of SPF. Vertebral column injury, dural and pleural tears are all developed after high-energy trauma mechanisms. This may explain why this condition results in high mortality rates.

### Conclusion

SPF is a rare complication that occurs following an injury to the vertebral column and is usually reported after a blunt trauma. Here we are reporting a case of a victim with pneumorrhachis and pneumocephalus after a gunshot wound, leading to SPF as a secondary defect after trauma. Airborne transfer of patients with vertebral injuries may lead to SPF due to air pressure changes at high elevations; thus caution

must be exercised for the air ambulance transfer of such patients.

### Conflict of Interest

The authors declare that there is no potential conflicts of interest.

### References

1. Liang MK, Moore EE, Williams AM, Marks JL. Traumatic subarachnoid pleural fistula. *J Trauma* 2008;65:1155-61. [CrossRef](#)
2. Kozikowski GP, Cohen SP. Lumbar puncture associated with pneumocephalus: report of a case. *Anesth Analg* 2004;98:524-6. [CrossRef](#)
3. Iwama T, Andoh H, Murase S, Miwa Y, Ohkuma A. Diffuse cerebral air embolism following trauma: striking postmortem CT findings. *Neuroradiology* 1994;36:33-4. [CrossRef](#)
4. Oertel MF, Korinth MC, Reinges MH, Krings T, Terbeck S, Gilsbach JM. Pathogenesis, diagnosis and management of pneumorrhachis. *Eur Spine J* 2006;15 Suppl 5:636-43. [CrossRef](#)
5. Kairinos N, Nicol A, Navsaria P. Pneumocephalus following gunshot injury to the thoracic vertebral column: a case report. *Ulus Travma Acil Cerrahi Derg* 2009;15:614-6.
6. Cole JD. Assessment. In: Illis LS, editor. *Spinal cord dysfunction*. Chapter 9. Oxford University Press; 1988. p. 216-31.
7. Kuczkowski KM. Post-dural puncture headache, intracranial air and obstetric anesthesia. *Anaesthesist* 2003;52:798-800.