



## Single-incision laparoscopic surgery to treat hepatopancreatobiliary cancer: A technical review

Shu-Hung Chuang, Shih-Chang Chuang

**Specialty type:** Surgery

**Provenance and peer review:**

Invited article; Externally peer reviewed.

**Peer-review model:** Single blind

**Peer-review report's scientific quality classification**

Grade A (Excellent): 0

Grade B (Very good): B, B

Grade C (Good): 0

Grade D (Fair): 0

Grade E (Poor): 0

**P-Reviewer:** A JD, China; Hiep LT, Viet Nam

**Received:** January 17, 2022

**Peer-review started:** January 17, 2022

**First decision:** March 9, 2022

**Revised:** March 20, 2022

**Accepted:** June 16, 2022

**Article in press:** June 16, 2022

**Published online:** July 21, 2022



**Shu-Hung Chuang, Shih-Chang Chuang**, Division of General and Digestive Surgery, Department of Surgery, Kaohsiung Medical University Hospital, Kaohsiung Medical University, Kaohsiung 80708, Taiwan

**Shu-Hung Chuang, Shih-Chang Chuang**, School of Medicine, College of Medicine, Kaohsiung Medical University, Kaohsiung 80708, Taiwan

**Corresponding author:** Shih-Chang Chuang, MD, PhD, Associate Professor, Director, Surgeon, Surgical Oncologist, Division of General and Digestive Surgery, Department of Surgery, Kaohsiung Medical University Hospital, Kaohsiung Medical University, No. 100 Shih-Chuan 1st Road, Sanmin District, Kaohsiung 80708, Taiwan. [chuangsc@cc.kmu.edu.tw](mailto:chuangsc@cc.kmu.edu.tw)

### Abstract

Single-incision laparoscopic surgery (SILS), or laparoendoscopic single-site surgery, was launched to minimize incisional traumatic effects in the 1990s. Minor SILS, such as cholecystectomies, have been gaining in popularity over the past few decades. Its application in complicated hepatopancreatobiliary (HPB) surgeries, however, has made slow progress due to instrumental and technical limitations, costs, and safety concerns. While minimally invasive abdominal surgery is pushing the boundaries, advanced laparoscopic HPB surgeries have been shown to be comparable to open operations in terms of patient and oncologic safety, including hepatectomies, distal pancreatectomies (DP), and pancreaticoduodenectomies (PD). In contrast, advanced SILS for HPB malignancy has only been reported in a few small case series. Most of the procedures involved minor liver resections and DP; major hepatectomies were rarely described. Single-incision laparoscopic PD has not yet been reported. We herein review the published SILS for HPB cancer in the literature and our three-year experience focusing on the technical aspects.

**Key Words:** Hepatectomy; Hepatopancreatobiliary cancer; Laparoendoscopic single-site surgery; Pancreatectomy; Pancreaticoduodenectomy; Single-incision laparoscopic surgery

©The Author(s) 2022. Published by Baishideng Publishing Group Inc. All rights reserved.

**Core Tip:** Single-incision laparoscopic surgery (SILS), or laparoendoscopic single-site surgery, has been introduced to minimize incisional traumatic effects over the past few decades. As minor SILS, such as cholecystectomies, have been gaining in popularity, major SILS for complicated hepatopancreatobiliary (HPB) surgeries have made slow progress due to instrumental and technical limitations, costs, and safety concerns. We herein review the published SILS for HPB cancer in the literature and our three-year experience focusing on the technical aspects.

**Citation:** Chuang SH, Chuang SC. Single-incision laparoscopic surgery to treat hepatopancreatobiliary cancer: A technical review. *World J Gastroenterol* 2022; 28(27): 3359-3369

**URL:** <https://www.wjgnet.com/1007-9327/full/v28/i27/3359.htm>

**DOI:** <https://dx.doi.org/10.3748/wjg.v28.i27.3359>

## INTRODUCTION

Single-incision laparoscopic surgery (SILS), also known as laparoendoscopic single-site surgery, is an advanced minimally invasive procedure that leaves a single small incision after surgery. Since it was introduced in the 1990s, numerous studies regarding SILS for minor procedures have been published, such as for cholecystectomy[1]. In contrast, its application in advanced hepatopancreatobiliary (HPB) surgeries is rarely reported[2-8].

By minimizing the incision number, SILS has the potential advantages of less pain, fewer wound complications, faster recovery, and favorable cosmesis. Nevertheless, the existing literature regarding minor SILS fails to reach a conclusion. For example, single-incision laparoscopic cholecystectomies (SILC), the most published SILS to date, have been shown to be superior in marginal benefits such as less pain and shorter hospital stays, while incisional hernia and bile duct injury are considerable drawbacks[9-11]. Nevertheless, it is always necessary to remove a sizable specimen during advanced HPB surgeries. One of the small incisions in standard multi-incision laparoscopic surgeries (MILS) has to be enlarged to fit the specimen size as well as the only incision in SILS. Since incisional hernia has become a minor issue, patient and oncologic safety has attracted more concern in advanced single-incision laparoscopic HPB surgeries. MILS has been shown to be comparable to open operations for HPB malignancy, including hepatectomies, distal pancreatectomies (DP), and pancreaticoduodenectomies (PD), in recent years[12-24]. The fact that only a few case series of SILS for HPB cancer have been reported reflects the limitations of surgical techniques, instrumental technology, and adequate training. Although our previous study showed that practicing minor SILS helps to achieve competence in this technique for complicated diseases[25], there is still a long way to go. In this review, we conducted an updated literature search for SILS to treat malignant HPB diseases that were reported in English. Studies involving robotic technology were excluded. Meanwhile, a summary of our three-year experience focusing on the technical aspects was described.

## SINGLE-INCISION LAPAROSCOPIC HEPATECTOMY (SILH) FOR MALIGNANCY

### Literature review

Eight original studies[26-33] and 20 case reports[34-47] were identified with a cutoff value of 10 malignant cases. The outdated reports of sequential studies from the same groups were excluded. Nearly all the case reports involved minor liver resections [partial hepatectomies, monosegmentectomies, and left lateral sectionectomies (LLS)]. Three of the eight original articles described major hepatectomies (resection of over two segments), including nine right hemihepatectomies (RHs), 34 left hemihepatectomies, and seven right posterior sectionectomies (RPSs)[27,29,32] (Table 1). Most procedures were performed for malignant diseases. Five nonrandomized comparative studies between SILH and multi-incision laparoscopic hepatectomies (MILHs) were conducted[26-28,30,32]. Hyun *et al* [26] reported a shorter postoperative hospital stay and comparable pathologic features for minor SILH compared with minor MILH; long-term survival outcomes were absent. Mittermair *et al*[27] showed less blood loss, a lower number of patients with blood loss > 25 mL, and more blood transfusions in the major SILH group; no local tumor recurrence occurred during a median follow-up of 61 mo. Tsai *et al* [28] reported a shorter operative time and shorter postoperative hospital stays in the SILH group for LLS but not partial hepatectomies of segment 5-6; the 1-, 3-, and 5-year overall and recurrence-free survival rates for hepatocellular carcinoma were similar in both the SILH and MILH groups. Wang *et al* [30] showed shorter postoperative hospital stays for patients without cirrhosis undergoing LLS in the SILH group; the 1-year recurrence-free survival rates for hepatocellular carcinoma were similar in both the SILH and MILH groups. Han *et al*[32] reported a shorter operative time, less blood loss, and earlier

**Table 1 English original researches of single-incision laparoscopic hepatectomies for malignancy retrieved online till December 2021**

Ref.	Journal (year of publication)	SILH	Control group	RH	LH	RAS	RPS	LLS + MR
Hyun <i>et al</i> [26]	<i>J Gastrointest Surg</i> (2021)	15	MILH	0	0	0	0	15
Mittermair <i>et al</i> [27]	<i>J Clin Med</i> (2021)	34	MILH	4	6	0	7	17
Tsai <i>et al</i> [28]	<i>Surg Endosc</i> (2020)	54	MILH	0	0	0	0	54
Saad <i>et al</i> [29]	<i>ANZ J Surg</i> (2020)	54	No	0	11	0	0	43
Wang <i>et al</i> [30]	<i>Int J Surg</i> (2020)	33	MILH	0	0	0	0	33
Pan <i>et al</i> [31]	<i>Surg Laparosc Endosc Percutan Tech</i> (2019)	37	No	0	0	0	0	37
Han <i>et al</i> [32]	<i>World J Gastroenterol</i> (2018)	155	MILH	5	17	0	0	133
Weiss <i>et al</i> [33]	<i>J Hepatobiliary Pancreat Sci</i> (2015)	21	No	0	0	0	0	21
Our study	Under submission	31	No	3	2	3	3	20

SILH: Single-incision laparoscopic hepatectomies; MILH: Multi-incision laparoscopic hepatectomies; RH: Right hemihepatectomies; LH: Left hemihepatectomies; RAS: Right anterior sectionectomies; RPS: Right posterior sectionectomies; LLS: Left lateral sectionectomies; MR: Minor resections including monosegmentectomies and partial hepatectomies.

enteral feeding in the SILH group; the safety resection margins were similar in both the SILH and MILH groups. However, long-term survival outcomes were not presented.

In summary, SILH was superior to MILH in terms of shorter postoperative hospital stays in three comparative studies of minor liver resections[26,28,30]. For major hepatectomies, the two related studies came to a different conclusion. While Mittermair C *et al*[27] declared more substantial blood loss requiring transfusion in SILH, Han *et al*[32] reported a shorter operative time, less blood loss, and earlier enteral feeding for the single port technique.

### **Our experience and technical review**

While SILC[25] and single-incision laparoscopic common bile duct exploration (SILCBD)[48] have become our standard of care for cholelithiasis over the past decade, we have developed more advanced SILS for malignant HPB diseases since 2016. The principles of standard MILS and surgical oncology were strictly followed to maintain a high standard of patient safety and prognosis. From July 2018 to July 2021, 31 SILH procedures were performed by the first author to treat malignant diseases (Table 1). Eleven (35.5%) major liver resections involved three RHs, two left hemohepatectomies (LHs), three right anterior sectionectomies (RASs), and three RPSs. The others were 20 (64.5%) minor resections. An additional port was needed in five (16.1%) procedures, and no open conversion occurred. There was one case of surgery-related 90-d mortality due to pulmonary infection.

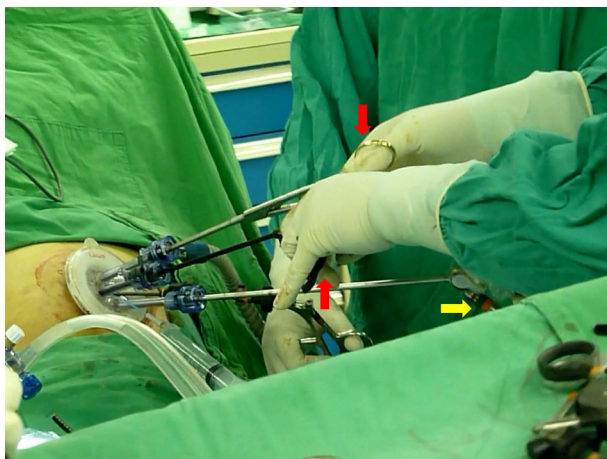
### **Patient position**

During formal hepatic surgery, the patient was placed in a reverse Trendelenburg position with arms abducted and legs split. The surgeon stood between the patient's legs to facilitate hepatic hilar management. The assistant held the laparoscope at the patient's left/right side (between the left/right limbs) during right/Left hepatic resections. For LLS, the operative table could be tilted toward the patient's right side. In contrast, it should be tilted toward the patient's left side during RPS. Lateral decubitus positions were not favored because of impaired access to the hepatic hilum.

### **Port and instrument**

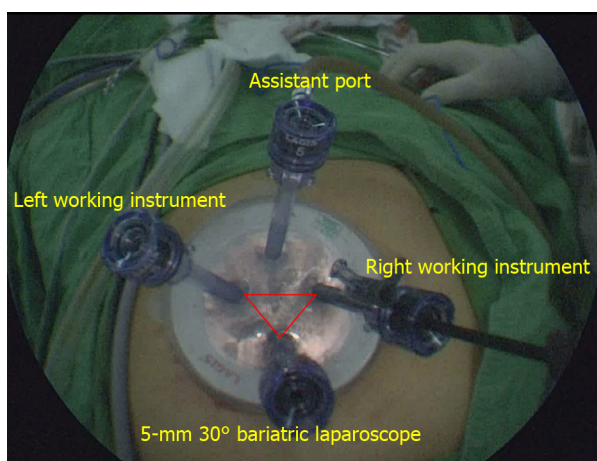
By using conventional laparoscopic ports and straight instruments through a 1.5-2.5 cm skin incision and multiple nearby punctures on the deep fascia, the costs can be reduced to a minimum. This single-incision multipuncture approach is only suitable for short-duration procedures such as SILC[25], SILCBDE[48], and minor SILH because of its inherent problem of air leakage. Otherwise, a 3-6 cm single skin and deep fascia incision with a homemade (surgical glove) or commercial multichannel port is recommended for major liver resections to remove a sizable specimen at the end of surgery.

We recommended 30° rigid laparoscopes and conventional straight instruments, as the latter could be manipulated more intuitively than curved or articulated instruments. A 5-mm 30° bariatric laparoscope can effectively prevent "sword fighting" between the light cable of the laparoscope and the instrument handles (Figure 1). The port configuration was arranged in a reverse triangular pattern (Figure 2). The 30° laparoscope passed through the lower port and the fulcrum to the upper part of the operative field to provide an overlooking view, and the two working instruments reached the lower part of the



DOI: 10.3748/wjg.v28.i27.3359 Copyright ©The Author(s) 2022.

**Figure 1** The 5-mm 30° bariatric laparoscope effectively prevented “sword fighting” between the light cable (yellow arrow) of the laparoscope and the instrument handles (red arrows) in single-incision laparoscopic surgery.



DOI: 10.3748/wjg.v28.i27.3359 Copyright ©The Author(s) 2022.

**Figure 2** The port configuration was arranged in a reverse triangular pattern on a commercial multichannel port in a single-incision laparoscopic surgery. The upper port served as an assistant port for additional traction or suction/irrigation.

operative field to perform the procedure. This configuration decreased collisions between the laparoscope and the working instruments. Finally, a fourth port could be used to perform traction or suction.

### **Abdominal incision**

Considering that upper abdominal incisions induce more pain, we avoided making incisions above the umbilical level. A praumbilical incision with downward extension is good for performing single-incision laparoscopic LH or RH. Otherwise, a transverse incision at the same level of the umbilicus is suitable to perform single-incision laparoscopic RAS or RPS. The incision should be tailored to the specimen size for its removal.

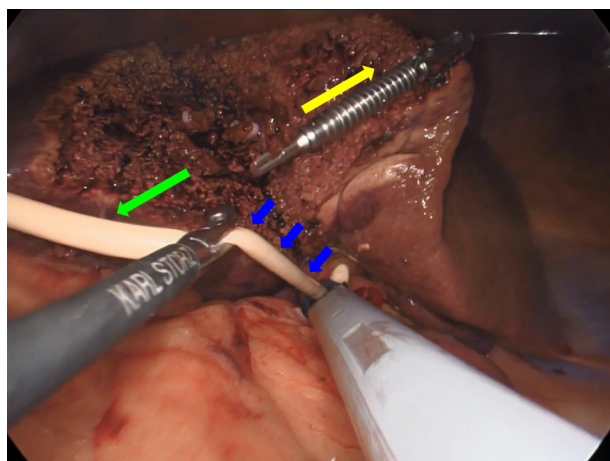
### **Hepatic inflow control**

For temporary hepatic inflow control (Pringle maneuver), we favored the use of a 14-French Foley catheter (Figure 3), which was introduced by Huang *et al*[49] in 2018. During selective inflow control for major SILH, such as the extra Glissonian approach or individual dissection, a laparoscopic right angle dissector or a goldfinger retractor is useful. As the working instruments were kept aligned with the laparoscope in SILH, it was difficult to see the distal ends of the instruments. Laparoscopic working instruments with curved or flexible ends were easier to manipulate under limited vision.

### **Parenchymal transection**

To avoid interinstrumental collisions, auxiliary traction devices substituted for assistant tractions. We preferred EndoGrab™ (Virtual Ports Ltd., Hod Hasharon, Israel), while gravity would provide counter-





DOI: 10.3748/wjg.v28.i27.3359 Copyright ©The Author(s) 2022.

**Figure 3** The hepatoduodenal ligament was encircled by a 14-French Foley catheter (blue arrows) for temporary hepatic inflow control (Pringle maneuver) in a single-incision laparoscopic right posterior sectionectomy. An EndoGrab™ (Virtual Ports Ltd., Hod Hasharon, Israel) provided traction in the direction of the yellow arrow, while gravity created countertraction (green arrow).

traction in some instances (Figure 3). The transection line should be kept aligned with the laparoscopic view at all times.

### **Single-incision laparoscopic suturing technique**

Suturing is the last line of defense in patient safety for not only open but also laparoscopic surgeries. It can be applied in various difficult situations to stop bleeding or biliary leakage. While performing single-incision laparoscopic suturing technique (SILST), forward-backward, vertical, and rotational movements are frequently used rather than transverse movements. The curved tip of a Maryland dissector helps to form a loop made by two instruments nearly parallel to each other (Figure 4). In addition, monofilament threads make loops more easily in SILST due to their high elasticity.

## **SINGLE-INCISION LAPAROSCOPIC PANCREATECTOMY FOR MALIGNANCY**

### **Literature review**

While most reported single-incision laparoscopic DP (SILDP) was used to treat benign lesions, only three original studies[50-52] (Table 2) and three case reports[53-55] of SILDP for cancer were identified with a cutoff value of 10 cases. Series containing neoplasms with uncertain behavior were excluded, as well as outdated reports of sequential studies from the same groups. All three original studies were nonrandomized comparative studies. SILDP was compared with multi-incision laparoscopic DP (MILDP) in two studies and the robotic approach in the remaining study. SILDP was associated with a longer operative time, reduced postoperative pain, and lower spleen/splenic vessel preservation rates than MILDP[50,51]. Robotic DP and splenectomies required a longer operating room time than SILDP and splenectomies, but the operative durations were similar[52]. All the patients except one undergoing DP for neoplasms had R0 resections, and six ( $7 \pm 6.6$ ) lymph nodes were noted according to the pathologic reports. However, long-term survival outcomes were not provided.

For PD, one of the most complicated abdominal surgeries, we could not find any report of applying a single-incision laparoscopic technique.

### **Our experience and technical review**

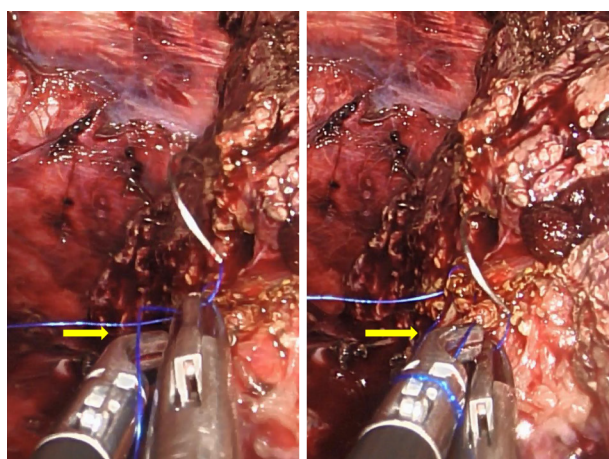
We have no experience in performing SILDP for malignancy. Two patients with benign lesions (serous cystadenoma) underwent this procedure in the last two years. However, we have performed single-incision laparoscopic PD (SILPD) on three patients since May 2020. All procedures were accomplished successfully without conversion to MILS or open operations. No major complications, such as postoperative pancreatic fistula, occurred, and there was no 90-day mortality. The pathology report was distal cholangiocarcinoma in the first patient and pancreatic ductal adenocarcinoma in the other two. Routine D2 Lymph node dissections and intraoperative frozen sections for checking resection margins were carried out for oncologic safety. To the best of our knowledge, this report is the first experience of SILPD in the world and is now under submission.

**Table 2 English original researches of single-incision laparoscopic pancreatectomies for malignancy retrieved online till December 2021**

Ref.	Journal (year of publication)	Procedure	Case number	Control group	Spleen preservation
Park <i>et al</i> [50]	<i>Hepatobiliary Pancreat Sci</i> (2019)	SILDP	26	MILDP	0 <sup>1</sup>
Ağcaoğlu <i>et al</i> [51]	<i>Sisli Etfal Hastan Tip Bul</i> (2019)	SILDP	10	MILDP	1
Ryan <i>et al</i> [52]	<i>JSLS</i> (2015)	SILDPS	16	RDPS	N/A

<sup>1</sup>Splenic vessel preservation.

SILDP: Single-incision laparoscopic distal pancreatectomies; MILDP: Multi-incision laparoscopic distal pancreatectomies; SILDPS: Single-incision laparoscopic distal pancreatectomies and splenectomies; RDPS: Robotic distal pancreatectomies and splenectomies; N/A: Not applicable.



DOI: 10.3748/wjg.v28.i27.3359 Copyright ©The Author(s) 2022.

**Figure 4** The curved tip of a Maryland dissector (yellow arrow) helped to form a loop made by two instruments nearly parallel to each other in a single-incision laparoscopic surgery. A monofilament thread was used in this case.

### Patient position

During a single-incision laparoscopic pancreatectomy, the patient was placed in a reverse Trendelenburg position with the surgeon standing between their legs. The operative table could be tilted toward the patient's right side for SILDP. The assistant held the laparoscope at the patient's left side (between the left limbs) during the resection phase and hepaticojejunostomy during SILPD. In contrast, the assistant held the laparoscope at the patient's right side (between the right limbs) during SILDP and pancreaticojejunostomy/gastrojejunostomy in SILPD.

### Port and instrument

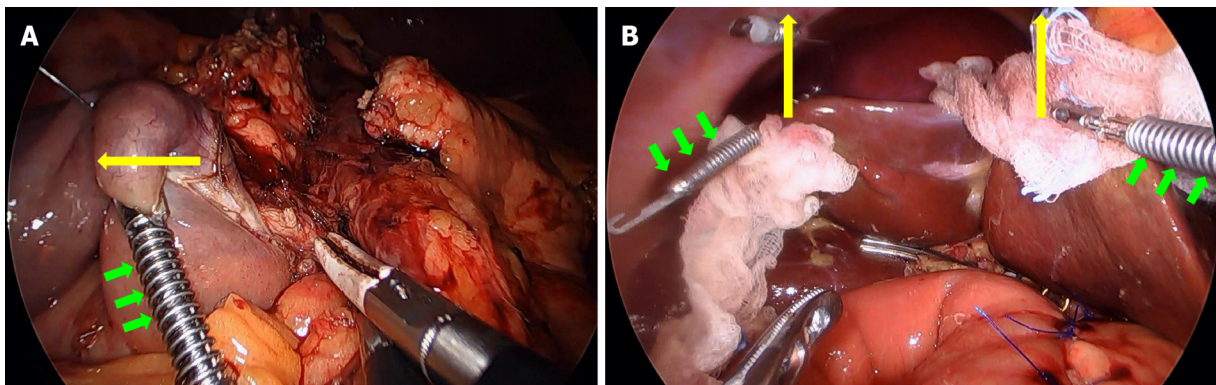
Major pancreatic and hepatic resections shared the same port configuration and instrument selection. Sometimes the surgeon had to cross the instruments to achieve an adequate approaching angle (the angle between the two working instruments) or solve a handedness problem, such as suturing a left target with a right-handed instrument.

### Abdominal incision

In order to achieve less pain and better cosmesis, a several centimeter praumbilical incision with downward extension is good for performing a SILDP or a SILPD. The incision should be enlarged to facilitate specimen removal in a retrieval bag at the end of surgery if necessary.

### Auxiliary traction

EndoGrab™ (Virtual Ports Ltd., Hod Hasharon, Israel) could be applied on the duodenum to be resected during the uncinate process dissection in a SILPD (Figure 5A). It was very useful for liver retraction during SILDP or SILPD (Figure 5B).



DOI: 10.3748/wjg.v28.i27.3359 Copyright ©The Author(s) 2022.

**Figure 5** EndoGrab™ (Virtual Ports Ltd., Hod Hasharon, Israel) provided auxiliary traction during single-incision laparoscopic pancreatectomies. A: EndoGrab™ (green arrows) was applied on the duodenal 3<sup>rd</sup> portion to provide lateral traction (yellow arrow) during the uncinata process dissection in a single-incision laparoscopic pancreaticoduodenectomy (SILPD); B: Two EndoGrabs™ (green arrows) facilitated upward traction (yellow arrows) of the liver edges during the reconstruction phase in a SILPD. Two pieces of gauze served as cushions to minimize the traumatic effect of EndoGrabs™ (green arrows) on the liver.

### SILST

Unlike hepatectomies, suturing constituted a major component in pancreatic resections, such as hemostasis (Video 1), closure of the pancreatic stump in a DP and creation of the three anastomoses (pancreaticojejunostomy, hepaticojejunostomy, and gastrojejunostomy) in a PD. During critical duct-to-mucosa pancreaticojejunostomy, we recommend interrupted suturing for the inner layer to prevent anastomotic stricture caused by a “purse-string effect”. Holding the interrupted stitches with metallic clips before tying them helped to gain adequate space for the anastomosis. In our experience, up to three metallic clips could be used simultaneously during anastomosis without confusing the surgeon (Figure 6). While performing SILST, all the principles of suturing in open surgery and MILS should be followed on the basis of high quality. Otherwise, additional port(s) should be utilized to minimize anastomotic leakage.

### Step-by-step procedures in SILPD

While the laparoscopic view was unchanged during SILPD, the procedural steps were standardized to shorten the operative time as well as the learning curve. These steps include division of the gastrocolic ligament, release of the hepatic flexure of the transverse colon, Kocher maneuver (Station 13 Lymph nodes harvest), division of Treitz’s ligament, pulling of the proximal jejunum to the patient’s right side, creation of the tunnel under the pancreatic neck, division of the proximal jejunum and its mesentery, division of the lesser omentum and distal stomach (Station 5 and 6 Lymph node harvest), division of the pancreatic neck, dissection of the uncinata process (Station 14 Lymph nodes harvest), Station 8 and 12 Lymph node harvest, division of the common hepatic duct, removal of the gallbladder from the liver bed, specimen extraction, pancreaticojejunostomy, hepaticojejunostomy, gastrojejunostomy, and peritoneal irrigation with drainage.

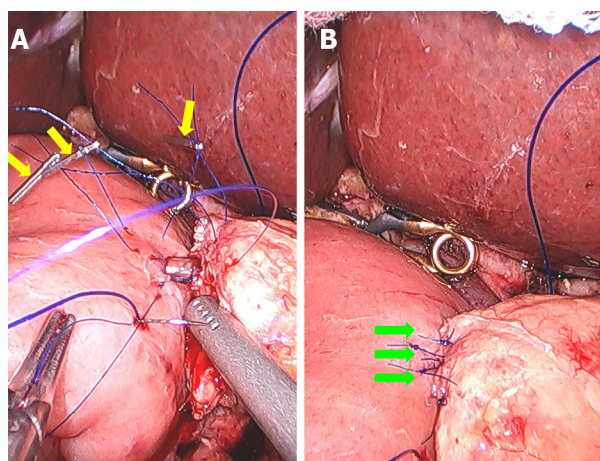
## SINGLE-INCISION LAPAROSCOPIC BILE DUCT RESECTION (SILBDR) FOR MALIGNANCY

### Literature review

We only found one case report of SILBDR in the literature[56]. Two patients with Bismuth–Corlette type I perihilar cholangiocarcinoma underwent the procedure, including hepatoduodenal ligament lymphadenectomy, successfully with good recovery. The resection margins of the proximal and distal bile ducts were free from tumor invasion, but long-term follow-up was pending. The authors concluded that SILBDR can be optional in strictly selected patients with Bismuth–Corlette type I perihilar cholangiocarcinoma.

As perihilar cholangiocarcinoma is relatively rare to diagnose in an early stage, more advanced procedures, such as hemihepatectomies, caudate lobectomies, or PD, are usually performed in addition to bile duct resections for a better prognosis. The feasibility of SILS for resecting advanced-stage perihilar cholangiocarcinoma, an extremely complicated, demanding, and time-consuming procedure, should be considered with caution.





DOI: 10.3748/wjg.v28.i27.3359 Copyright ©The Author(s) 2022.

**Figure 6** Single-incision laparoscopic suturing technique was applied to a pancreatoduodenectomy. A: Three metallic clips (yellow arrows) were used at the same time during the inner duct-to-mucosa anastomosis of the pancreatoduodenectomy (PJ) in a single-incision laparoscopic pancreaticoduodenectomy; B: Completed inner duct-to-mucosa anastomosis (green arrows) of the PJ.

## CONCLUSION

Minor SILH, such as LLS, monosegmentectomies, and partial liver resections, are feasible and safe to treat selected patients with cancer by experienced laparoscopic surgeons. Although the evidence level is low, minor SILH seems to be superior to minor MILH in terms of shorter postoperative hospital stay. The oncologic outcome is comparable for both procedures. Large-scale randomized controlled clinical trials are necessary to address this issue.

Major SILH might be feasible for highly selected patients by experienced laparoscopic surgeons in high-volume centers. The current evidence is limited and fails to determine its position compared with major MILH. Surgical skill refinement and technology advancement are anticipated to overcome this demanding procedure.

Although technically feasible, SILDP has been shown to be associated with longer operative time and lower spleen/splenic vessel preservation rates. Strict patient selection is mandatory for the possible accompanying splenectomy. Well-designed randomized controlled studies are needed to compare this procedure with MILDP. Robotic technology may have a positive effect on minimally invasive DP.

SILPD is just in its infancy, and this is also true for SILBDR. While developing these techniques, patient and oncologic safety should be prioritized. A low threshold to convert the procedures should always be kept in mind.

## ACKNOWLEDGEMENTS

We gratefully acknowledge the work of Dr. Hsu JW in assisting with the surgical procedures and the data collection.

## FOOTNOTES

**Author contributions:** Chuang SH drafted the manuscript; Chuang SC revised the manuscript; Both authors have read and approve the final manuscript.

**Conflict-of-interest statement:** The authors report no conflict of interest.

**Open-Access:** This article is an open-access article that was selected by an in-house editor and fully peer-reviewed by external reviewers. It is distributed in accordance with the Creative Commons Attribution NonCommercial (CC BY-NC 4.0) license, which permits others to distribute, remix, adapt, build upon this work non-commercially, and license their derivative works on different terms, provided the original work is properly cited and the use is non-commercial. See: <https://creativecommons.org/licenses/by-nc/4.0/>

**Country/Territory of origin:** Taiwan

**ORCID number:** Shu-Hung Chuang 0000-0002-2007-0415; Shih-Chang Chuang 0000-0003-1481-1632.



S-Editor: Yan JP

L-Editor: A

P-Editor: Yan JP

## REFERENCES

- Morales-Conde S, Peeters A, Meyer YM, Antoniou SA, Del Agua IA, Arezzo A, Arolfo S, Yehuda AB, Boni L, Cassinotti E, Dapri G, Yang T, Fransen S, Forgione A, Hajibandeh S, Mazzola M, Migliore M, Mittermair C, Mittermair D, Morandeira-Rivas A, Moreno-Sanz C, Morlacchi A, Nizri E, Nuijts M, Raakow J, Sánchez-Margallo FM, Sánchez-Margallo JA, Szold A, Weiss H, Weiss M, Zorron R, Bouvy ND. European association for endoscopic surgery (EAES) consensus statement on single-incision endoscopic surgery. *Surg Endosc* 2019; **33**: 996-1019 [PMID: 30771069 DOI: 10.1007/s00464-019-06693-2]
- Machairas N, Papaconstantinou D, Gaitanidis A, Hasemaki N, Paspala A, Stamopoulos P, Kykalos S, Sotiropoulos GC. Is Single-Incision Laparoscopic Liver Surgery Safe and Efficient for the Treatment of Malignant Hepatic Tumors? *J Gastrointest Cancer* 2020; **51**: 425-432 [PMID: 31388921 DOI: 10.1007/s12029-019-00285-y]
- Wang YB, Xia J, Zhang JY, Gong JP, Wang XM. Effectiveness and safety of single-port versus multi-port laparoscopic surgery for treating liver diseases: a meta-analysis. *Surg Endosc* 2017; **31**: 1524-1537 [PMID: 27553801 DOI: 10.1007/s00464-016-5199-9]
- Karabicak I, Karabulut K. Single port laparoscopic liver surgery: A minireview. *World J Gastrointest Endosc* 2016; **8**: 444-450 [PMID: 27358670 DOI: 10.4253/wjge.v8.i12.444]
- Benzing C, Krenzien F, Atanasov G, Seehofer D, Sucher R, Zorron R, Pratschke J, Schmelzle M. Single incision laparoscopic liver resection (SILL) - a systematic review. *GMS Interdiscip Plast Reconstr Surg DGPW* 2015; **4**: Doc17 [PMID: 26734538 DOI: 10.3205/iprs000076]
- Ban D, Kudo A, Irie T, Ochiai T, Aihara A, Matsumura S, Tanaka S, Tanabe M. Advances in reduced port laparoscopic liver resection. *Asian J Endosc Surg* 2015; **8**: 11-15 [PMID: 25510567 DOI: 10.1111/ases.12164]
- Chang SK, Lee KY. Therapeutic advances: single incision laparoscopic hepatopancreatobiliary surgery. *World J Gastroenterol* 2014; **20**: 14329-14337 [PMID: 25339820 DOI: 10.3748/wjg.v20.i39.14329]
- Gkegkes ID, Iavazzo C. Single incision laparoscopic hepatectomy: A systematic review. *J Minim Access Surg* 2014; **10**: 107-112 [PMID: 25013325 DOI: 10.4103/0972-9941.134872]
- Yao D, Wu S, Tian Y, Fan Y, Kong J, Li Y. Transumbilical single-incision laparoscopic distal pancreatectomy: primary experience and review of the English literature. *World J Surg* 2014; **38**: 1196-1204 [PMID: 24357245 DOI: 10.1007/s00268-013-2404-z]
- Chatzizacharias NA, Dajani K, Koong JK, Jah A. The Role of the Single Incision Laparoscopic Approach in Liver and Pancreatic Resectional Surgery. *Minim Invasive Surg* 2016; **2016**: 1454026 [PMID: 27891251 DOI: 10.1155/2016/1454026]
- Chuang SH, Lin CS. Single-incision laparoscopic surgery for biliary tract disease. *World J Gastroenterol* 2016; **22**: 736-747 [PMID: 26811621 DOI: 10.3748/wjg.v22.i2.736]
- Hildebrand N, Verkoulen K, Dewulf M, Heise D, Ulmer F, Coolsen M. Short-term outcomes of laparoscopic versus open hepatectomy in the elderly patient: systematic review and meta-analysis. *HPB (Oxford)* 2021; **23**: 984-993 [PMID: 33632653 DOI: 10.1016/j.hpb.2021.01.016]
- Machairas N, Kostakis ID, Schizas D, Kykalos S, Nikiteas N, Sotiropoulos GC. Meta-analysis of laparoscopic versus open liver resection for intrahepatic cholangiocarcinoma. *Updates Surg* 2021; **73**: 59-68 [PMID: 33219937 DOI: 10.1007/s13304-020-00930-3]
- Cipriani F, Ratti F, Fiorentini G, Reineke R, Aldrighetti L. Systematic review of perioperative and oncologic outcomes of minimally-invasive surgery for hilar cholangiocarcinoma. *Updates Surg* 2021; **73**: 359-377 [PMID: 33615423 DOI: 10.1007/s13304-021-01006-6]
- Lyu Y, Cheng Y, Wang B, Zhao S, Chen L. Assessment of laparoscopic versus open distal pancreatectomy: a systematic review and meta-analysis. *Minim Invasive Ther Allied Technol* 2022; **31**: 350-358 [PMID: 32903097 DOI: 10.1080/13645706.2020.1812664]
- Gavrilidis P, Roberts KJ, Sutcliffe RP. Laparoscopic versus open distal pancreatectomy for pancreatic adenocarcinoma: a systematic review and meta-analysis. *Acta Chir Belg* 2018; **118**: 278-286 [PMID: 29996721 DOI: 10.1080/00015458.2018.1492212]
- van Hilst J, Korrel M, de Rooij T, Lof S, Busch OR, Groot Koerkamp B, Kooby DA, van Dieren S, Abu Hilal M, Besselink MG; DIPLOMA study group. Oncologic outcomes of minimally invasive versus open distal pancreatectomy for pancreatic ductal adenocarcinoma: A systematic review and meta-analysis. *Eur J Surg Oncol* 2019; **45**: 719-727 [PMID: 30579652 DOI: 10.1016/j.ejso.2018.12.003]
- Yang DJ, Xiong JJ, Lu HM, Wei Y, Zhang L, Lu S, Hu WM. The oncological safety in minimally invasive versus open distal pancreatectomy for pancreatic ductal adenocarcinoma: a systematic review and meta-analysis. *Sci Rep* 2019; **9**: 1159 [PMID: 30718559 DOI: 10.1038/s41598-018-37617-0]
- Nickel F, Haney CM, Kowalewski KF, Probst P, Limen EF, Kalkum E, Diener MK, Strobel O, Müller-Stich BP, Hackert T. Laparoscopic Versus Open Pancreaticoduodenectomy: A Systematic Review and Meta-analysis of Randomized Controlled Trials. *Ann Surg* 2020; **271**: 54-66 [PMID: 30973388 DOI: 10.1097/SLA.0000000000003309]
- Wang M, Li D, Chen R, Huang X, Li J, Liu Y, Liu J, Cheng W, Chen X, Zhao W, Tan Z, Huang H, Zhu F, Qin T, Ma J, Yu G, Zhou B, Zheng S, Tang Y, Han W, Meng L, Ke J, Feng F, Chen B, Yin X, Chen W, Ma H, Xu J, Lin R, Dong Y, Yu Y, Zhang H, Qin R; Minimally Invasive Treatment Group in the Pancreatic Disease Branch of China's International Exchange and Promotion Association for Medicine and Healthcare (MITG-P-CPAM). Laparoscopic versus open

- pancreatoduodenectomy for pancreatic or periampullary tumours: a multicentre, open-label, randomised controlled trial. *Lancet Gastroenterol Hepatol* 2021; **6**: 438-447 [PMID: 33915091 DOI: 10.1016/S2468-1253(21)00054-6]
- 21 **Katsuki R**, Jo T, Yasunaga H, Kumazawa R, Uda K. Outcomes of laparoscopic versus open pancreatoduodenectomy: A nationwide retrospective cohort study. *Surgery* 2021; **169**: 1427-1433 [PMID: 33487433 DOI: 10.1016/j.surg.2020.12.018]
  - 22 **Yin Z**, Jian Z, Hou B, Jin H. Surgical and Oncological Outcomes of Laparoscopic Versus Open Pancreaticoduodenectomy in Patients With Pancreatic Duct Adenocarcinoma. *Pancreas* 2019; **48**: 861-867 [PMID: 31306305 DOI: 10.1097/MPA.0000000000001363]
  - 23 **Jiang YL**, Zhang RC, Zhou YC. Comparison of overall survival and perioperative outcomes of laparoscopic pancreaticoduodenectomy and open pancreaticoduodenectomy for pancreatic ductal adenocarcinoma: a systematic review and meta-analysis. *BMC Cancer* 2019; **19**: 781 [PMID: 31391085 DOI: 10.1186/s12885-019-6001-x]
  - 24 **Peng L**, Zhou Z, Cao Z, Wu W, Xiao W, Cao J. Long-Term Oncological Outcomes in Laparoscopic Versus Open Pancreaticoduodenectomy for Pancreatic Cancer: A Systematic Review and Meta-Analysis. *J Laparoendosc Adv Surg Tech A* 2019; **29**: 759-769 [PMID: 30835156 DOI: 10.1089/lap.2018.0683]
  - 25 **Chuang SH**, Yang WJ, Chang CM, Lin CS, Yeh MC. Is routine single-incision laparoscopic cholecystectomy feasible? *Am J Surg* 2015; **210**: 315-321 [PMID: 25916613 DOI: 10.1016/j.amjsurg.2014.12.032]
  - 26 **Hyun IG**, Choi Y, Han HS, Yoon YS, Cho JY, Kim KH, Han S. Feasibility of Solo Single-Incision Laparoscopic Surgery in Non-anatomical Minor Liver Resection: a Propensity Score-Matched Analysis. *J Gastrointest Surg* 2021; **25**: 681-687 [PMID: 32157607 DOI: 10.1007/s11605-020-04527-4]
  - 27 **Mittermair C**, Weiss M, Schirnhöfer J, Brunner E, Fischer K, Obrist C, de Cillia M, Kemmetinger V, Gollegger E, Hell T, Weiss H. The Shift from Multiport to Single Port Increases the Amount of Bleeding in Laparoscopic Major Hepatectomy. *J Clin Med* 2021; **10** [PMID: 33498169 DOI: 10.3390/jcm10030374]
  - 28 **Tsai KY**, Chen HA, Wang WY, Huang MT. Long-term and short-term surgical outcomes of single-incision laparoscopic hepatectomy on anterolateral liver segments. *Surg Endosc* 2020; **34**: 2969-2979 [PMID: 31482356 DOI: 10.1007/s00464-019-07080-7]
  - 29 **Saad MR**, Choi Y, Han HS, Yoon YS, Cho JY, Lee JS, Lee BR. Solo single-incision laparoscopic liver resection: a cohort series. *ANZ J Surg* 2020; **90**: 1108-1111 [PMID: 32378778 DOI: 10.1111/ans.15941]
  - 30 **Wang JC**, Pan Y, Chen J, Hu D, Tuoheti Y, Zhou Z, Xu L, Chen M, Zhang Y. Single versus multiple port laparoscopic left lateral sectionectomy for hepatocellular carcinoma: A retrospective comparative study. *Int J Surg* 2020; **77**: 15-21 [PMID: 32179178 DOI: 10.1016/j.ijssu.2020.03.003]
  - 31 **Pan Y**, Chen J, Xu L, Zhou Z, Chen M, Zhang Y. Single-Port Laparoscopic Hepatectomy for Liver Tumor: Operative Steps (With Video). *Surg Laparosc Endosc Percutan Tech* 2019; **29**: e98-e101 [PMID: 31567784 DOI: 10.1097/SLE.0000000000000724]
  - 32 **Han JH**, You YK, Choi HJ, Hong TH, Kim DG. Clinical advantages of single port laparoscopic hepatectomy. *World J Gastroenterol* 2018; **24**: 379-386 [PMID: 29391760 DOI: 10.3748/wjg.v24.i3.379]
  - 33 **Weiss M**, Mittermair C, Brunner E, Schirnhöfer J, Obrist C, Pimpl K, Hell T, Weiss H. Inline radiofrequency pre-coagulation simplifies single-incision laparoscopic minor liver resection. *J Hepatobiliary Pancreat Sci* 2015; **22**: 831-836 [PMID: 26510122 DOI: 10.1002/jhbp.295]
  - 34 **Tayar C**, Subar D, Salloum C, Malek A, Laurent A, Azoulay D. Single incision laparoscopic hepatectomy: Advances in laparoscopic liver surgery. *J Minim Access Surg* 2014; **10**: 14-17 [PMID: 24501503 DOI: 10.4103/0972-9941.124454]
  - 35 **Pan M**, Jiang Z, Cheng Y, Xu X, Zhang Z, Zhou C, He G, Xu T, Liu H, Gao Y. Single-incision laparoscopic hepatectomy for benign and malignant hepatopathy: initial experience in 8 Chinese patients. *Surg Innov* 2012; **19**: 446-451 [PMID: 22474017 DOI: 10.1177/1553350612438412]
  - 36 **Toyama Y**, Yoshida S, Okui N, Kitamura H, Yanagisawa S, Yanaga K. Transumbilical single-incision laparoscopic hepatectomy using pre-coagulation and clipless technique in a patient with combined hepatocellular-cholangiocarcinoma: a case report. *Surg Laparosc Endosc Percutan Tech* 2013; **23**: e194-e199 [PMID: 24105295 DOI: 10.1097/SLE.0b013e31828b8602]
  - 37 **Camps Lasa J**, Cugat Andorrà E, Herrero Fonollosa E, García Domingo MI, Sánchez Martínez R, Vargas Pierola H, Rodríguez Campos A. Single-port laparoscopic approach of the left liver: initial experience. *Cir Esp* 2014; **92**: 589-594 [PMID: 24999088 DOI: 10.1016/j.ciresp.2014.05.009]
  - 38 **Kim G**, Lau AC, Chang SK. Single-incision laparoscopic hepatic resection in patients with previous hepatic resections: a mini case series. *Asian J Endosc Surg* 2014; **7**: 63-66 [PMID: 24450347 DOI: 10.1111/ases.12072]
  - 39 **Karabacak I**, Karabulut K, Yuruker S, Kesicioglu T, Ozen N. Single-Port Laparoscopic Liver Resection: Largest Turkish Experience. *Indian J Surg* 2017; **79**: 111-115 [PMID: 28442836 DOI: 10.1007/s12262-015-1435-0]
  - 40 **Inoue Y**, Asakuma M, Hirokawa F, Hayashi M, Shimizu T, Uchiyama K. Single port access for laparoscopic lateral segmentectomy. *Wideochir Inne Tech Maloinwazyjne* 2017; **12**: 357-365 [PMID: 29362650 DOI: 10.5114/wiitm.2017.70260]
  - 41 **Tzanis D**, Lainas P, Tranchart H, Pourcher G, Devaquet N, Perlemuter G, Naveau S, Dagher I. Atypical as well as anatomical liver resections are feasible by laparoendoscopic single-site surgery. *Int J Surg Case Rep* 2014; **5**: 580-583 [PMID: 25108073 DOI: 10.1016/j.ijscr.2013.11.009]
  - 42 **Struecker B**, Haber P, Öllinger R, Bahra M, Pascher A, Pratschke J, Schmelzle M. Comparison of Single-Port Versus Standard Multiport Left Lateral Liver Sectionectomy. *Surg Innov* 2018; **25**: 136-141 [PMID: 29303066 DOI: 10.1177/1553350617752010]
  - 43 **Belli G**, Fantini C, D'Agostino A, Cioffi L, Russo G, Belli A, Limongelli P. Laparoendoscopic single site liver resection for recurrent hepatocellular carcinoma in cirrhosis: first technical note. *Surg Laparosc Endosc Percutan Tech* 2011; **21**: e166-e168 [PMID: 21857451 DOI: 10.1097/SLE.0b013e3182207d3a]
  - 44 **Wu S**, Yu XP, Tian Y, Siwo EA, Li Y, Yu H, Yao D, Lv C. Transumbilical single-incision laparoscopic resection of focal hepatic lesions. *JSLS* 2014; **18** [PMID: 25392646 DOI: 10.4293/JSLS.2014.00397]
  - 45 **Dapri G**, Dimarco L, Cadière GB, Donckier V. Initial experience in single-incision transumbilical laparoscopic liver resection: indications, potential benefits, and limitations. *HPB Surg* 2012; **2012**: 921973 [PMID: 23082044 DOI: 10.1007/s12089-012-9219-7]

- 10.1155/2012/921973]
- 46 **Rosok BI**, Edwin B. Single-Incision Laparoscopic Liver Resection for Colorectal Metastasis through Stoma Site at Time of Reversal of Diversion Ileostomy: A Case Report. *Minim Invasive Surg* 2011; **2011**: 502176 [PMID: [22091359](#) DOI: [10.1155/2011/502176](#)]
  - 47 **Cantos-Pallares M**, Mir-Labrador J, Rafael Redondo-Cano C, Nuñez-Ronda R, Artigues-Sanchez de Rojas E, Fabra-Ramis R. Single-port Laparoscopic Liver Resection in Patients with Previous Abdominal Surgeries: Is it a Feasible Approach? *J Coll Physicians Surg Pak* 2022; **32**: 96-98 [PMID: [34983156](#) DOI: [10.29271/jcpsp.2022.01.96](#)]
  - 48 **Chuang SH**, Chen PH, Chang CM, Tsai YF, Lin CS. Single-incision laparoscopic common bile duct exploration with conventional instruments: an innovative technique and a comparative study. *J Gastrointest Surg* 2014; **18**: 737-743 [PMID: [24347312](#) DOI: [10.1007/s11605-013-2420-1](#)]
  - 49 **Huang JW**, Su WL, Wang SN. Alternative Laparoscopic Intracorporeal Pringle Maneuver by Huang's Loop. *World J Surg* 2018; **42**: 3312-3315 [PMID: [29589115](#) DOI: [10.1007/s00268-018-4584-z](#)]
  - 50 **Park P**, Han HJ, Song TJ, Choi SB, Kim WB, Yoo YD, Kim DS, Cha JH. Single-port versus conventional laparoscopic distal pancreatectomy: a propensity score matched analysis and a learning curve of single-port approach. *J Hepatobiliary Pancreat Sci* 2019; **26**: 401-409 [PMID: [31211913](#) DOI: [10.1002/jhbp.646](#)]
  - 51 **Ağcaoglu O**, Aksakal N, Azamat İF, Doğan S, Mercan S, Barbaros U. Comparison of Clinical Outcomes of Single-Incision Versus Conventional Multiport Laparoscopic Distal Pancreatectomy: A Single Institution Experience. *Sisli Etfal Hastan Tip Bul* 2019; **53**: 114-119 [PMID: [32377068](#) DOI: [10.14744/SEMB.2019.37880](#)]
  - 52 **Ryan CE**, Ross SB, Sukhramwala PB, Sadowitz BD, Wood TW, Rosemurgy AS. Distal pancreatectomy and splenectomy: a robotic or LESS approach. *JSLs* 2015; **19**: e2014.00246 [PMID: [25848192](#) DOI: [10.4293/JSLs.2014.00246](#)]
  - 53 **Kuroki T**, Kitasato A, Adachi T, Soyama A, Takatsuki M, Eguchi S. Single-incision laparoscopic distal pancreatectomy: our initial experience. *Hepatogastroenterology* 2014; **61**: 212-214 [PMID: [24895823](#) DOI: [10.1002/hep.24089](#)]
  - 54 **Misawa T**, Ito R, Futagawa Y, Fujiwara Y, Kitamura H, Tsutsui N, Shiba H, Wakiyama S, Ishida Y, Yanaga K. Single-incision laparoscopic distal pancreatectomy with or without splenic preservation: how we do it. *Asian J Endosc Surg* 2012; **5**: 195-199 [PMID: [23095300](#) DOI: [10.1111/j.1758-5910.2012.00155.x](#)]
  - 55 **Haugvik SP**, Rosok BI, Waage A, Mathisen O, Edwin B. Single-incision versus conventional laparoscopic distal pancreatectomy: a single-institution case-control study. *Langenbecks Arch Surg* 2013; **398**: 1091-1096 [PMID: [24177746](#) DOI: [10.1007/s00423-013-1133-y](#)]
  - 56 **Yu H**, Wu SD, Tian Y, Su Y, Li YN. Single-incision laparoscopic resection of Bismuth I hilar cholangiocarcinoma. *Surg Innov* 2013; **20**: 209-213 [PMID: [22393076](#) DOI: [10.1177/1553350612438414](#)]



Published by **Baishideng Publishing Group Inc**  
7041 Koll Center Parkway, Suite 160, Pleasanton, CA 94566, USA

**Telephone:** +1-925-3991568

**E-mail:** [bpgoffice@wjgnet.com](mailto:bpgoffice@wjgnet.com)

**Help Desk:** <https://www.f6publishing.com/helpdesk>

<https://www.wjgnet.com>

