

Received: 2017.09.24  
Accepted: 2017.10.24  
Published: 2018.02.02

e-ISSN 1941-5923  
© Am J Case Rep, 2018; 19: 123-127  
DOI: 10.12659/AJCR.907268

# A Patient with Left Bundle Branch Block and Persistent Atrial Fibrillation Treated with Cardiac Catheter Ablation and Pharmacologic Cardiac Resynchronization Therapy without the Use of an Implantable Cardiac Device

Authors' Contribution:  
Study Design A  
Data Collection B  
Statistical Analysis C  
Data Interpretation D  
Manuscript Preparation E  
Literature Search F  
Funds Collection G

ABCDE **Hideyuki Hasebe**

Division of Arrhythmology, Shizuoka Saiseikai General Hospital, Shizuoka City, Shizuoka, Japan





**Corresponding Author:** Hideyuki Hasebe, e-mail: [h153478@siz.saiseikai.or.jp](mailto:h153478@siz.saiseikai.or.jp)  
**Conflict of interest:** None declared

**Patient:** Male, 68  
**Final Diagnosis:** Heart failure  
**Symptoms:** Short of breath  
**Medication:** —  
**Clinical Procedure:** Catheter ablation of AF  
**Specialty:** Cardiology

**Objective:** Rare co-existence of disease or pathology  
**Background:** Left bundle branch block (LBBB) is associated with atrial fibrillation (AF) and systolic heart failure, which can be treated with cardiac resynchronization therapy (CRT) that includes an implantable cardiac device (ICD). However, in some patients, LBBB may vary with heart rate, and during episodes of AF in LBBB, aberrant ventricular conduction, or wide QRS complex tachycardia (Ashman beats) can occur. This report is a case of LBBB treated with pharmacologic CRT, without the use of an ICD.  
**Case Report:** A 68-year-old man presented with persistent AF and systolic heart failure. Serial electrocardiograms (ECGs) showed AF and mixed narrow (116 ms) and wide (152 ms) QRS duration of LBBB. Echocardiography showed a left ventricular ejection fraction (LVEF) of 30%. Catheter ablation for AF resulted in the restoration of sinus rhythm. The patient was treated with step-wise decreasing doses of amiodarone, from 200 mg to 75 mg daily, and step-wise increasing doses of bisoprolol, from 3.75 mg to 5.0 mg daily, which effectively slowed heart rate, inhibited aberrant cardiac conduction due to LBBB, reduced the symptoms of heart failure, and improved LVEF to 60%, despite persistent sinus bradycardia and the inability of the heart rate to increase during activity (chronotropic incompetence).  
**Conclusions:** This report of a case of AF associated with LBBB shows that pharmacologic CRT can restore sinus rhythm following catheter ablation and can reduce heart rate and treat heart failure without the use of an ICD.

**MeSH Keywords:** Atrial Fibrillation • Cardiac Resynchronization Therapy • Heart Failure

**Full-text PDF:** <https://www.amjcaserep.com/abstract/index/idArt/907268>

 1614  —  2  10



## Background

Prolongation of the QRS duration due to left bundle branch block (LBBB) is an important predisposing factor for systolic heart failure and atrial fibrillation (AF) [1]. Cardiac resynchronization therapy (CRT) that includes the use of an implantable cardiac device (ICD) can provide clinical benefit for patients with LBBB [2]. Intraventricular conduction disorders, such as LBBB, are usually stable and remain unchanged, irrespective of heart rate. However, in some patients, LBBB may vary with heart rate, and during episodes of AF, aberrant ventricular conduction, or wide QRS complex tachycardia, known as Ashman beats, can occur [3].

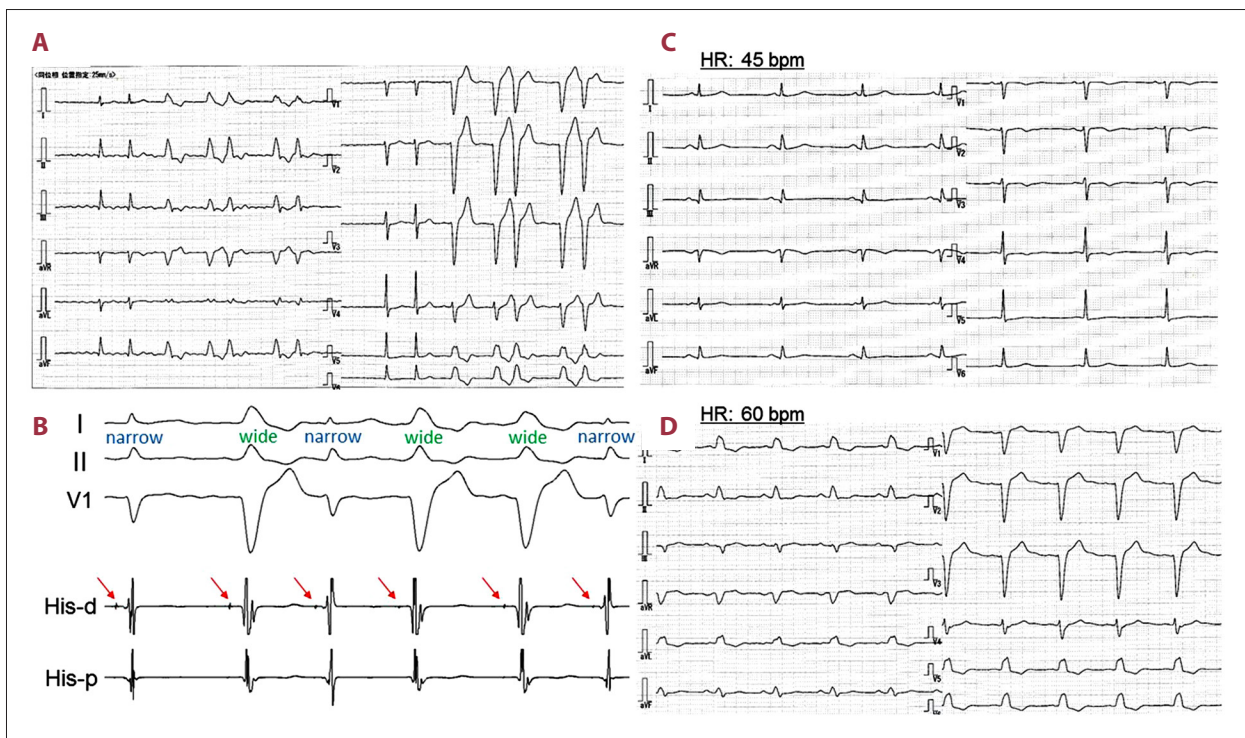
This report is of a case of heart failure due to persistent AF and aberrant cardiac conduction due to LBBB, with the restoration of sinus rhythm following cardiac catheter ablation. Pharmacologic CRT with amiodarone and bisoprolol restored sinus rhythm, reduced heart rate, and treated heart failure without the use of an ICD. Left ventricular (LV) systolic function and heart failure symptoms improved with time, despite persistent sinus bradycardia and the inability of the heart rate to increase during activity (chronotropic incompetence).

## Case Report

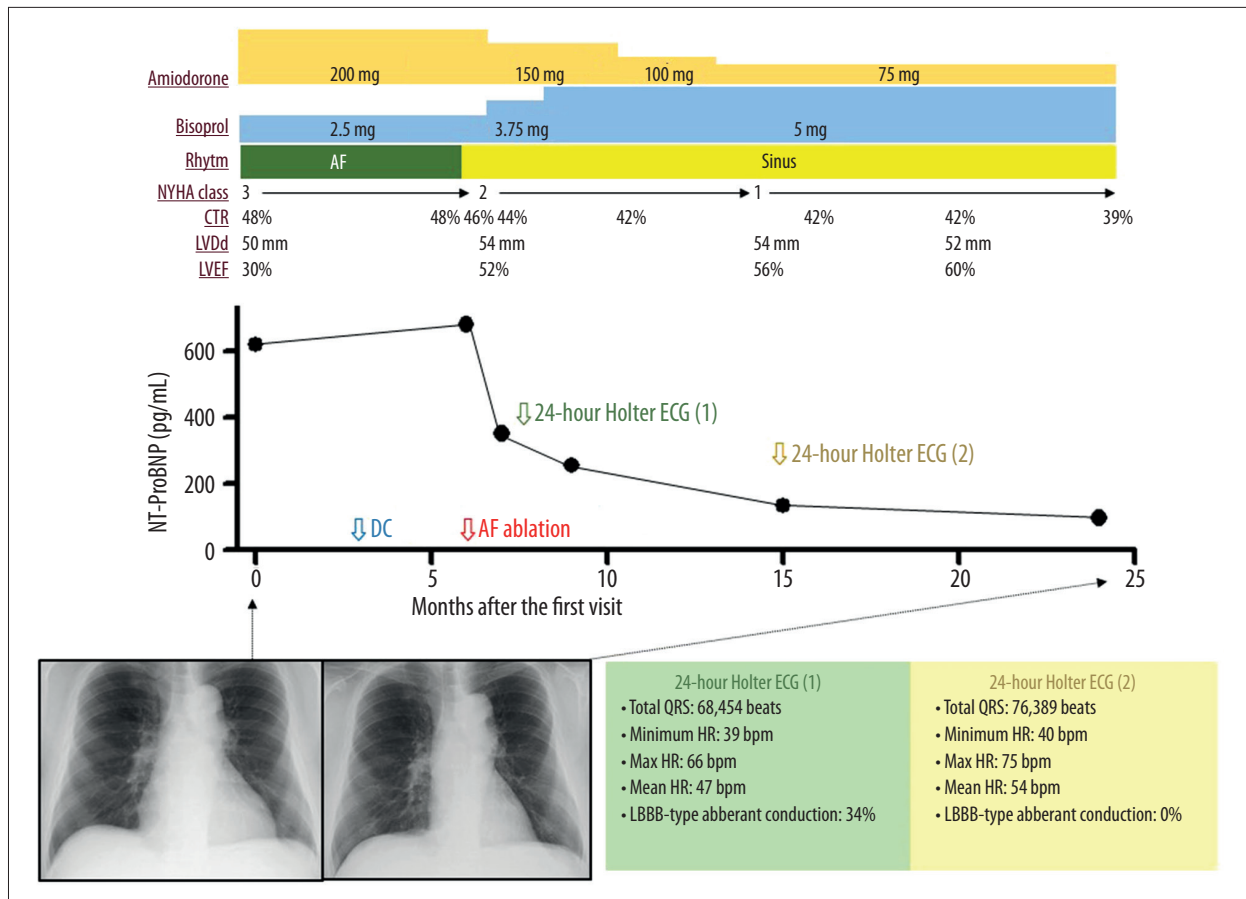
A 68-year-old man with persistent atrial fibrillation (AF) was referred to our hospital with symptoms of heart failure with the severity of the New York Heart Association (NYHA) class III. On hospital admission, the estimated duration of AF was several years, with the patient's ventricular rate being well controlled, between 60–90 (beats per minute (bpm) at rest, on treatment with the beta-blocker, bisoprolol, 2.5 mg daily.

Serial electrocardiograms (ECGs) showed AF and a mixture of narrow (116 ms) and wide (152 ms) QRS complexes, consistent with left bundle branch block (LBBB). The frequency of narrow and wide QRS complexes was comparable, and short runs of wide QRS complexes were seen (Figure 1A).

A chest X-ray showed a cardiothoracic ratio (CTR) of 48%. Echocardiography showed diffuse impairment of left ventricular (LV) systolic motion, a left ventricular ejection fraction (LVEF) of 30%, and atrial dilatation, with a left atrial diameter of 44 mm. Dyssynchrony of the LV systolic motion was observed at the same time as the appearance of LBBB wide QRS complexes. Electrophysiological studies showed that both



**Figure 1.** Twelve-lead electrocardiograms (ECGs) before (A) and after (C, D) catheter ablation, and intracardiac ECG during atrial fibrillation (AF) (B). (A) Twelve-lead electrocardiogram (ECG) shows narrow and wide QRS complexes with left bundle branch block (LBBB) morphology were observed during atrial fibrillation (AF). The frequency of narrow and wide QRS complex morphology was almost comparable. (B) Intracardiac ECG during AF shows both narrow and wide QRS complexes preceded by His potentials (indicated by red arrows). (C) Twelve-lead ECG during sinus rhythm at a rate of 45 bpm shows no wide QRS complexes. (D) Twelve-lead ECG during sinus rhythm at a rate of 60 bpm shows wide QRS complexes with LBBB morphology.



**Figure 2.** Clinical course of the patient. AF – atrial fibrillation; CTR – cardiothoracic ratio; DC – direct-current cardioversion; HR – heart rate; LBBB – left bundle branch block; LVDd – left ventricular diastolic diameter; LVEF – left ventricular ejection fraction; NT-ProBNP – N-terminal pro-brain natriuretic peptide; NYHA – New York Heart Association.

narrow and wide QRS complexes were preceded by His potentials (Figure 1B), indicating that the wide QRS complexes were LBBB aberrant forms of cardiac conduction.

Initially, pharmacologic treatment with 3.75 mg bisoprolol daily and 200 mg amiodarone daily was not effective for AF cardioversion and did not inhibit LBBB aberrant cardiac conduction. Sinus rhythm was temporarily restored by cardioversion with 200 mg of amiodarone. During sinus rhythm, no LBBB aberrant cardiac conduction changes were observed. However, the initial pharmacologic rhythm control regimen failed to maintain sinus rhythm.

Therefore, cardiac catheter ablation, including left atrial pulmonary vein isolation and creation of linear lesions along the left atrial roof, was performed. At the time of writing this case report, sinus rhythm has been maintained since cardiac catheter ablation. Following this procedure, serial ECGs taken at monthly intervals showed mainly narrow QRS complexes, but with occasional wide QRS complexes, consistent with LBBB (Figure 1C, 1D). The dose of bisoprolol was increased from 3.75

to 5 mg daily in an attempt to inhibit aberrant conduction by decreasing the sinus rate. The dose of amiodarone was decreased, in a step-wise manner, from 200 mg to 75 mg daily, but with consideration of the risk of the side effects of amiodarone. Details of the pharmacologic drug dosing regimens are shown in Figure 2.

At two months following cardiac catheter ablation for AF, the dose of amiodarone was 150 mg daily, and the dose of bisoprolol was 3.75 mg daily. Twenty-four hour Holter ECG monitoring showed mean, maximum, and minimum heart rates of 47 bpm, 66 bpm, and 39 bpm, respectively, and the prevalence of LBBB aberrant cardiac conduction was 34%, indicating the presence of chronotropic incompetence, or inability of the heart rate to increase during physical activity, and disturbed conductivity of the left bundle branch. Following cardiac catheter ablation for AF, cardiac parameter changes, including a decrease in NYHA class, CTR, and LV diastolic diameter, and an increase in LVEF were observed with time.

At nine months following cardiac catheter ablation for AF, the dose of amiodarone was 75 mg daily, and the dose of bisoprolol was 5 mg daily. Twenty-four hour Holter ECG monitoring showed mean, maximum, and minimum heart rates of 54 bpm, 75 bpm, and 40 bpm, respectively, and the prevalence of LBBB aberrant cardiac conduction was 0%, indicating improvement in chronotropic incompetence and left bundle branch cardiac conductivity.

At 18 months following cardiac catheter ablation for AF, treadmill exercise ECG showed that the peak heart rate was 93 bpm, whereas the age-predicted peak heart rate was 151 bpm. No LBBB aberrant cardiac conduction abnormalities were observed, even at peak exercise levels. Details of the clinical course and changes in clinical parameters are summarized in Figure 2.

## Discussion

Changes in the length of the QRS cycle on electrocardiogram (ECG) during atrial fibrillation (AF) can occasionally induce physiologically aberrant ventricular cardiac conduction, known as Ashman phenomenon [3]. Ashman beats are more commonly associated with right bundle branch block (RBBB), but can also be associated with left bundle branch block (LBBB). In this case report, a cardiac conduction abnormality consistent with LBBB was diagnosed, even after a relatively long coupling interval, indicating that the aberrant cardiac conduction was not physiological, but pathological.

LBBB may cause deterioration in cardiac function via modification of electrical activation within the left ventricle (LV). The QRS duration is a marker of intraventricular conduction delay, and QRS prolongation is associated with adverse clinical outcome in patients with heart failure [4]. In the present case, the LBBB QRS duration was 152 ms, and an apparent LV systolic dyssynchronous motion was observed at the time of appearance of LBBB on ECG, indicating that this conduction abnormality had a large negative effect on LV systolic function. Therefore, the inhibition of LBBB conduction by restoration of sinus rhythm and the pharmacologic reduction in heart rate resulted in improved LV systolic function.

AF exerts detrimental effects on cardiac function and hemodynamic status by several mechanisms, including loss of the atrial contribution to ventricular filling, increase in mean atrial pressure, tachycardia-mediated systolic dysfunction in cases of poor control of heart rate, reduced duration of passive diastolic filling, and an irregular sequence of RR intervals. Therefore, in this case, in addition to inhibiting LBBB cardiac conduction, restoration of sinus rhythm was also assumed to contribute to the improvement in cardiac function with pharmacologic cardiac resynchronization therapy (CRT). Although, it is difficult to

comment on the degree of contribution of these two factors, inhibition of LBBB and restoration of sinus rhythm, the association of tachycardia-mediated systolic dysfunction seemed to a minimal contributor to impaired cardiac function, because the ventricular rate, or heart rate, was well controlled before cardiac catheter ablation for AF.

Pharmacologic treatment with bisoprolol and amiodarone inhibited aberrant conduction by decreasing sinus rate. However, in this patient, chronotropic incompetence was present, even after restoration of sinus rhythm. A potential causal relationship between beta-blocker therapy and chronotropic incompetence has been previously reported [5,6]. However, it is difficult to determine whether the chronotropic incompetence seen in this case was attributable to the bisoprolol and amiodarone therapy. Several previously published studies have reported that the presence of chronotropic incompetence is associated with increased cardiovascular mortality and lower exercise capacity in patients with heart failure [5,7,8]. However, even with chronotropic incompetence, 24-hour Holter ECG monitoring at nine months following cardiac catheter ablation for AF showed increased peak heart rate when compared with that at two months following cardiac catheter ablation. One of the possible reasons for this improvement in chronotropic incompetence was the increased exercise capacity of the patient due to improvement in cardiac function.

Furthermore, in this case, despite the increased heart rate, the prevalence of LBBB aberrant cardiac conduction was 0%, which also indicated an improvement in left bundle branch conduction. Karaca et al. reported that reduction in QRS duration was seen in responders to CRT, indicating that cardiac conductive remodeling is associated with functional and structural remodeling [9]. Also, a previously published case report described the effective treatment of LBBB following CRT [10]. These findings indicate the importance of optimal medical therapy before the use of an implantable cardiac device (ICD) for CRT. The optimal medical or pharmacologic therapy for heart failure can improve conduction disturbance in CRT candidates by reversal of cardiac functional and structural remodeling. It is important to note that the maximum possible dose of beta-blocker should be administered because the dose-dependent reduction of LBBB seen in this case could occur in patients with sinus rhythm as well as patients with AF.

In this reported case, the improvement in cardiac function and reduction in the LBBB cardiac conduction abnormality might have had synergistic effects. A further possible reason for the improvement in cardiac conduction in LBBB was the reduced dose of amiodarone. Bepridil, which has less effect on the cardiac conduction system compared with amiodarone, might have been a more favorable treatment option in this case. However, bepridil was not given to this patient,

because of the possibility of inducing excessive QT prolongation, leading to potentially fatal ventricular arrhythmia in patients with heart failure. The trade-off between the restoration of sinus rhythm with the inhibition of LBBB and chronotropic incompetence had a favorable result on the cardiac function and heart failure status in this patient.

## References:

1. Cho GY, Kim HK, Kim YJ et al: Electrical and mechanical dyssynchrony for prediction of cardiac events in patients with systolic heart failure. *Heart*, 2010; 96: 1029–32
2. Prinzen FW, Vernooij K, Auricchio A: Cardiac resynchronization therapy. State-of-the-art of current applications, guidelines, ongoing trials, and areas of controversy. *Circulation*, 2013; 128: 2407–18
3. Single V, Singh B, Singh Y, Manjunath CN: Ashman phenomenon; A physiological aberration. *BMJ Case Rep*, 2013; 2013: pii: bcr2013009660
4. Birnie D, Ha A, Higginson L et al: Impact of QRS morphology and duration on outcomes after cardiac resynchronization therapy. Results from the resynchronization-defibrillation for ambulatory heart failure trial (RAFT). *Circ Heart Fail*, 2013; 6: 1190–98
5. Witte KKA, Cleland JGF, Clark AL: Chronic heart failure, chronotropic incompetence, and the effects of beta blockade. *Heart*, 2006; 92: 481–86
6. Dobre D, Zannad F, Keteyian SJ et al: Association between resting heart rate, chronotropic index, and long-term outcomes in patients with heart failure receiving  $\beta$ -blocker therapy: Data from the HF-ACTION trial. *Eur Heart J*, 2013; 34: 2271–80
7. Hirsh BJ, Mignatti A, Garan R et al: Effect of  $\beta$ -blocker cessation on chronotropic incompetence and exercise tolerance in patients with advanced heart failure. *Circ Heart Fail*, 2012; 5: 560–65
8. Magri D, Corra U, Lenarda AD et al: Cardiovascular mortality and chronotropic incompetence in systolic heart failure: The importance of a reappraisal of current cut-off criteria. *Eur J Heart Fail*, 2014; 16: 201–9
9. Karaca O, Cakal B, Omaygenc MO et al: Native electrocardiographic QRS duration after cardiac resynchronization therapy: The impact on clinical outcomes and prognosis. *J Card Fail*, 2016; 22: 772–80
10. Dizon J, Horn E, Neglia J et al: Loss of left bundle branch block following biventricular pacing therapy for heart failure: Evidence for electrical remodeling? *J Interv Card Electrophysiol*, 2004; 10: 47–50

## Conclusions

This report has described a patient with LBBB and persistent AF treated with cardiac catheter ablation to restore sinus rhythm, and pharmacologic CRT, with bisoprolol and amiodarone. Sinus rhythm, cardiac function, and cardiac resynchronization were achieved without the use of an implantable device.

## Conflict of interest

None.