

# A Rare Case of Solitary Osteochondroma of Right Hip with Unusual Clinical Presentation

Sai Kumar Reddy Mukkamalla<sup>1</sup>, Damagatla Sreekanth<sup>1</sup>, G Gnanendra Reddy<sup>1</sup>, H Umanath Rao<sup>1</sup>, P Siva Rama Krishna<sup>1</sup>

## Learning Point of the Article:

Excision of osteochondroma of hip improves the functional ability. Halts the malignant transformation and improves life expectancy of the patient.

## Abstract

**Introduction:** Osteochondroma is the most common primary benign tumor and developmental osseous anomaly resulting in exophytic overgrowth on the surface of bone lined by hyaline cartilage cap. In morphological view, they are sessile or pedunculated forms most commonly occurring in hip, scapula, humerus, and rarely, clavicle. X-ray, MRI angiogram are useful to know the bony, vascular pathology and histopathological investigation is the gold standard investigation to confirm the diagnosis.

**Case Report:** A 30-year-old male patient presented to our department with pain and swelling over the right gluteal region followed by difficulty in walking in the past 3 months. On clinical and radiological examination, we observed the findings suggestive of osteochondroma, the patient was planned for excisional biopsy, and the material sent to histopathological examination which confirmed as osteochondroma.

**Conclusion:** Early diagnosis and excision of tumor prevent functional disability and malignant transformation and improve the life expectancy.

**Keywords:** Osteochondroma, sessile, pedunculated histopathological examination, malignant transformation.

## Introduction

Osteochondroma is considered as developmental lesion rather than true neoplasm and constitutes 36% to 41% of all tumors, may occur on any bone performed in cartilage but is usually found in metaphysis of long bone near physis. It is a cartilage-covered osseous projection that protrudes from the surface of the bone. Most patients with this disorder have mutation in one of two genes EXT1 and EXT2. Most characteristic feature of lesion is cortical and cancellous components continuously with parental bone [1].

## Case Report

A 30-year-old male patient was admitted in our hospital with pain and swelling over the right gluteal region followed by difficulty in walking, inability to sit on hard surface. The main complaints started 3 months back with swelling insidious in onset, gradually progressive followed by pain. There is no history of fall, trauma, weight loss, and appetite present. On local examination, a diffuse swelling with irregular margins, hard in consistency present on the right gluteal region extending into posteromedial aspect of proximal thigh (Fig. 1). No regional lymphadenopathy.

There are no distal neurovascular deficits present. X-ray of pelvis

Access this article online

Website:  
www.jocr.co.in

DOI:  
<https://doi.org/10.13107/jocr.2023.v13.i11.4032>

## Author's Photo Gallery



Dr. Sai Kumar Reddy Mukkamalla



Dr. Damagatla Sreekanth



Dr. G Gnanendra Reddy



Dr. H Umanath Rao



Dr. P Siva Rama Krishna

<sup>1</sup>Department of Orthopaedics, Viswabharathi Medical College, Kurnool, Andhra Pradesh, India.

### Address of Correspondence:

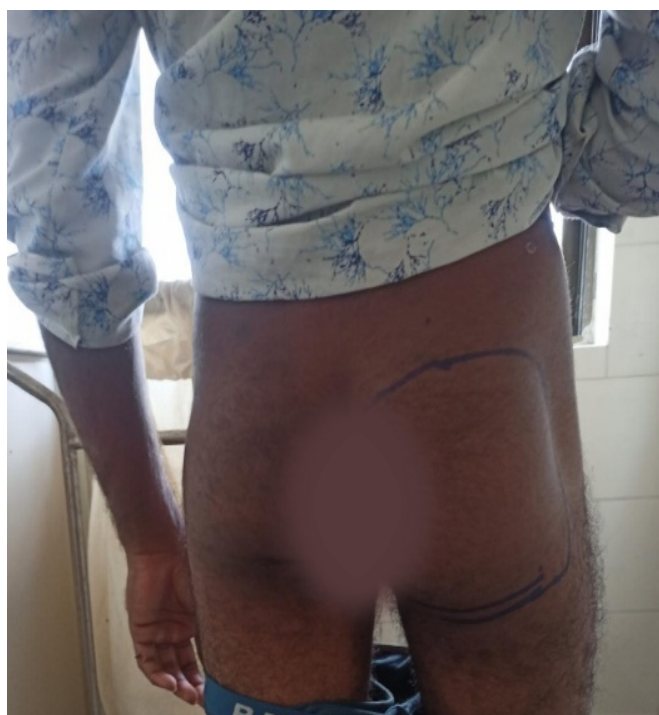Dr. Damagatla Sreekanth,  
Department of Orthopaedics, Viswabharathi Medical College, Kurnool, Andhra Pradesh, India.  
E-mail: kuttisreekanth@gmail.com

Submitted: 30/08/2023; Review: 13/09/2023; Accepted: October 2023; Published: November 2023

DOI: <https://doi.org/10.13107/jocr.2023.v13.i11.4032>

This is an open access journal, and articles are distributed under the terms of the Creative Commons Attribution-NonCommercial-ShareAlike 4.0 License <https://creativecommons.org/licenses/by-nc-sa/4.0/>, which allows others to remix, tweak, and build upon the work non-commercially, as long as appropriate credit is given and the new creations are licensed under the identical terms





**Figure 1:** Clinical photograph.

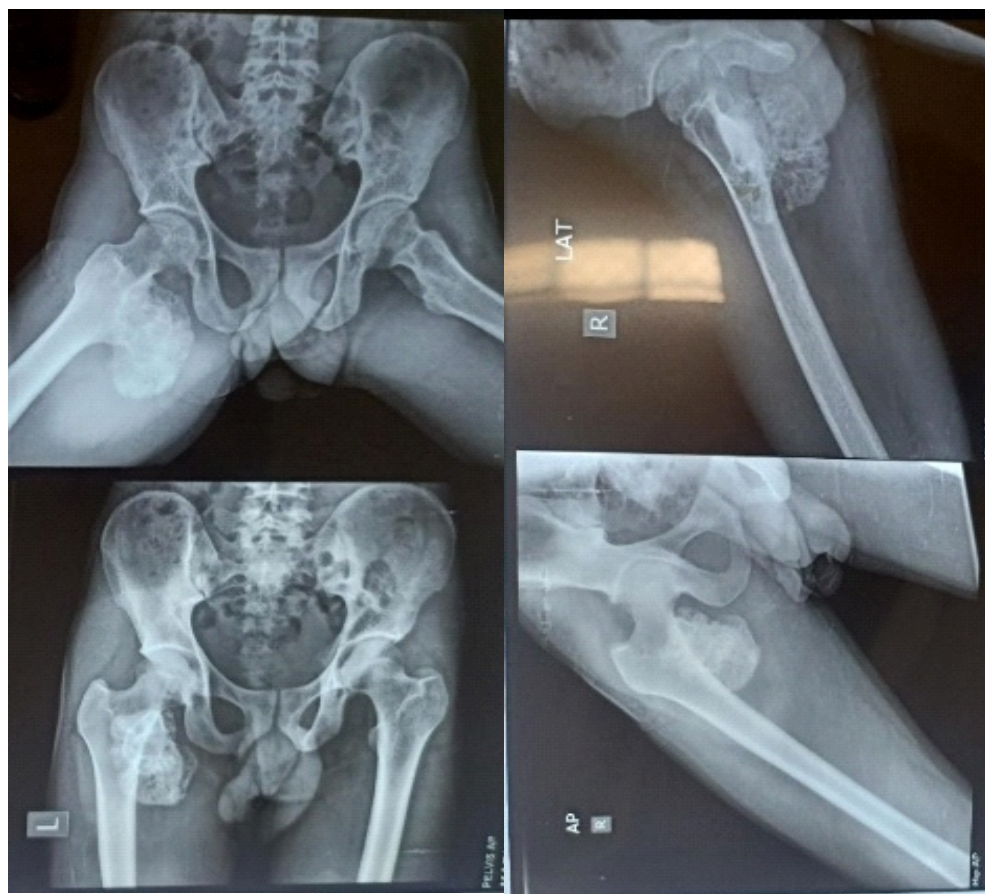
including both hip joints showing cauliflower growth communicating from lesser trochanter of the right femur with corticomedullary continuity has been noticed (Fig. 2). Further, magnetic resonance imaging (MRI) showed hypointense areas in the lesion raised concern for the presence of necrotic tissue. It shows a low signal on T1, in homogenous high signal on T2 with a peripheral hypointense rim, and edematous infiltration of bone marrow (Fig. 3). Preliminary blood investigations were done and planned for excisional biopsy through posterior approach (Fig. 4). Histopathology tissue has zoned architecture, the superficial part is constructed of well-differentiated chondrocyte, and the cartilaginous depth of tissue is replaced by regular osteoblasts suggestive of osteochondroma.

The occurrence of osteochondroma in hip lesion is very rare. Post-operative was uneventful. In postoperative X-ray, complete removal of the lesion was confirmed and patient was mobilized after surgery (Fig. 4). The patient regained near-normal life with no disability and has been in followup without recurrence till date.

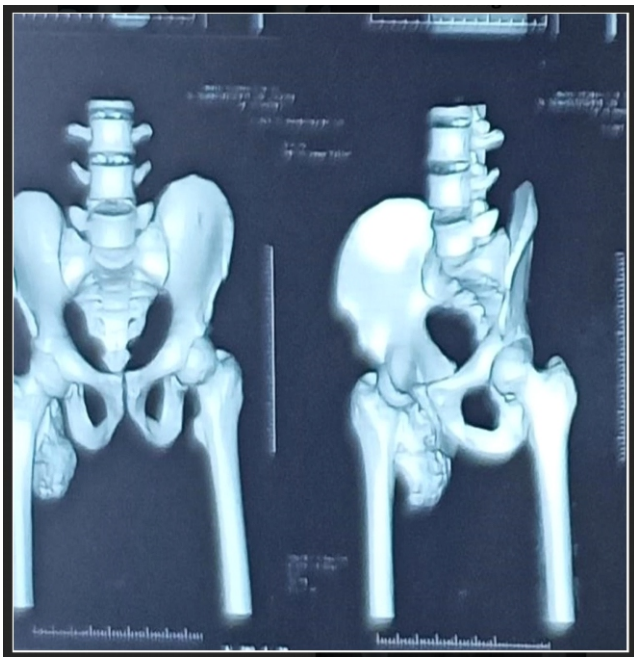
### Discussion

According to the World Health Organization classification,

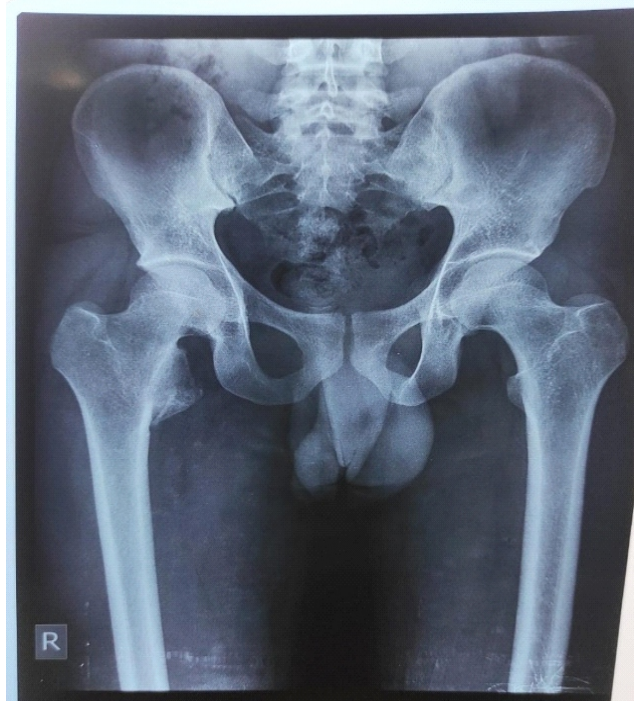osteochondroma is defined as cartilage-capped bony projection extending from metaphysis diagnosed as solitary lesion as a part of hereditary multiple osteochondromas involving the hip in 30–90% of patients [1,2]. Sessile and pedunculated are usually symptomless. Cartilage-capped lesions have variable thickness ranging from 0.2 to 1.5 cm traditionally used as a marker for malignant transformation and cutoff of 1 cm to 1.5 cm for excision of osteochondromas for concern of malignant transformation [3]. The continuity of the cortex and medulla of the lesion with that of native bone is pathognomonic feature [4]. MRI is useful to know the amount of lesion, soft-tissue involvement, and depth of cartilaginous cap [5]. Histologically, malignant chondrosarcomas are



**Figure 2:** Pre-operative X-ray.

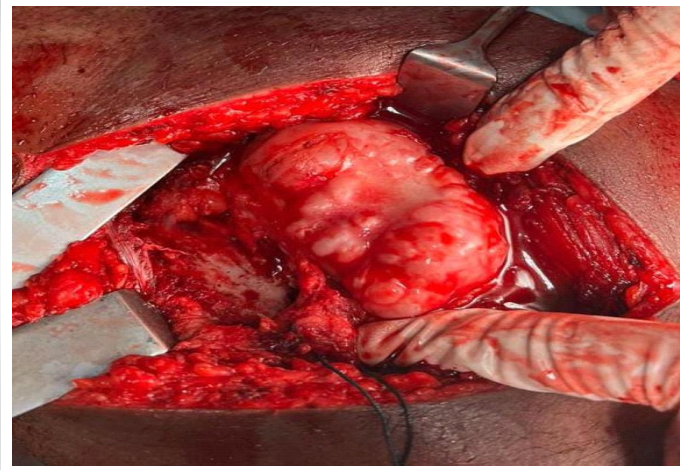


**Figure 3:** Magnetic resonance imaging right femur: Large lobulated soft-tissue mass arising from posteromedial aspect of right proximal femur (7.7\*5.7\*6.9 cm).



**Figure 5:** Post-operative X-ray.

differentiated by hypercellularity, plump nuclei, permeative pattern, and entrapment of bony trabeculae [6]. Complications include nerve, vascular involvement, aneurysmal formation and secondary osteoarthritis, functional disability, and malignant



**Figure 4:** Excised tumor.

transformation [7]. Biopsy is the gold standard investigation for confirmation of diagnosis and treatment of osteochondromas should be aimed to remove growth, thereby relieving mechanical block [8]. Treatment should consist of the complete lesion removal including cartilage and perichondrium covering it [9]. Inadequacy of removal can lead to recurrence of lesion [10].

### Conclusion

Osteochondroma appears in the first and third decades of life, with equal predilection to both males and females with presentation of complaints such as pain and restriction of motion causing disability. Radiological investigations are of more importance and biopsy is the gold standard investigation for the conformation of diagnosis. For patients with painful swelling and restricted joint movement with or without neurovascular deficit, extra periosteal bony excision remains the mainstay of the treatment to prevent malignant transformation.

### Clinical Message

Early diagnosis and excision of osteochondroma can prevent neurovascular complications, malignant transformation, metastasis and functional disability.

**Declaration of patient consent:** The authors certify that they have obtained all appropriate patient consent forms. In the form, the patient has given the consent for his/ her images and other clinical information to be reported in the journal. The patient understands that his/ her names and initials will not be published and due efforts will be made to conceal their identity, but anonymity cannot be guaranteed.

**Conflict of interest:** Nil **Source of support:** None

## References

1. Canella P, Gardin F, Borriani S. Exostosis: Development, evolution and relationship to malignant degeneration. *Ital J Orthop Traumatol* 1981;7:293-8.
2. Porter DE, Benson MK, Hosney GA. The hip in hereditary multiple exostoses. *J Bone Joint Surg Br* 2001;83:988-95.
3. Kitsoulis P, Galani V, Stefanaki K, Paraskevas G, Karatzias G, Agnantis NJ, et al. Osteochondromas: Review of the clinical, radiological and pathological features. *In Vivo* 2008;22:633-46.
4. Haaga JR, Dogra VS, Frosting M, Gilkeson RC, Sundaram M. A case report of osteochondroma with unusual clinical and imaging presentation. *Adv Biomed Res* 2009;2:2134-5.
5. Douis H, Saifuddin A. The imaging of cartilaginous bone tumours. I. Benign lesions. *Skeletal Radiol* 2012;41:1195-212.
6. Paik NJ, Han TR, Lim SJ. Multiple peripheral nerve compressions related to malignantly transformed hereditary multiple exostoses. *Muscle Nerve* 2000;23:1290-4.
7. Feeley BT, Kelly BT. Arthroscopic management of an intraarticular osteochondroma of the hip. *Orthop Rev (Pavia)* 2009;1:e2.
8. Mehta M, White LM, Knapp T, Kandel RA, Wunder JS, Bell RS. MR imaging of symptomatic osteochondromas with pathological correlation. *Skeletal Radiol* 1998;27:427-33.
9. Singh R, Jain M, Siwach R, Rohilla S, Sen R, Kaur K. Large para-articular osteochondroma of the knee joint: A case report. *Acta Orthop Traumatol Turc* 2012;46:139-43.
10. Al Qarni AD. Femoral neck osteochondroma in an athlete: A case report and literature review. *Saudi J Sports* 2014;14:158-60.

**Conflict of Interest:** Nil  
**Source of Support:** Nil

**Consent:** The authors confirm that informed consent was obtained from the patient for publication of this case report

## How to Cite this Article

Mukkamalla SKR, Sreekanth D, Reddy GG, Rao HU, Krishna PSR. A Rare Case of Solitary Osteochondroma of Right Hip with Unusual Clinical Presentation. *Journal of Orthopaedic Case Reports* 2023 November;13(11): 129-132.