

Experience in treating a case of the cardiac rupture during transcatheter aortic valve implantation procedure

Wei-Min Zhang¹, Jian-Mao Hong¹, Fan He¹, Guo-Sheng Fu², Fei-Cheng Yu²

¹Department of Cardiovascular Surgery, Sir Run Run Shaw Hospital, Zhejiang University, Hangzhou, Zhejiang 310016, China;

²Department of Cardiology, Sir Run Run Shaw Hospital, Zhejiang University, Hangzhou, Zhejiang 310016, China.

To the Editor: A 70-year-old male patient underwent transcatheter aortic valve implantation (TAVI) for severe aortic stenosis. Echocardiography showed that the peak velocity in aortic valve was 4.33 m/s, with a peak pressure gradient of 75 mmHg and a mean pressure gradient of 38 mmHg. The end-systolic dimension and end-diastolic dimension of left ventricle was 31.7 and 50.0 mm, respectively. The internal diameter of aortic annular was 30.7 mm, and the diameter of aortic sinus was 37.3 mm. The area of valve was 0.87 cm². The computerized tomography indicated a bicuspid aortic valve of 27.3 mm diameter according to 85.6 mm perimeter of aortic annulus, or an aortic valve of 27.4 mm diameter according to 569 mm² valve orifice area. A 26 mm Venus-A valve (Venus Medtech, Hangzhou, China) was implanted.

When we used a 20Fr balloon to dilate the aortic valve, the patient's systolic blood pressure dropped to 70 mmHg in 5 min. The transesophageal echocardiography (TEE) showed a rapidly increasing pericardial effusion. A single-chamber central venous catheter was inserted immediately into the pericardial cavity through the left fourth intercostal space. Five hundred milliliter bright red bloody hemopericardium was drawn out quickly and infused back into the body through the left femoral artery. The patient's blood pressure recovered after the intervention, but the pericardial effusion was not improved as monitored by TEE. We decided to send the artificial valve to the predetermined location and released it immediately under fluoroscopy. Simultaneously, the bloody hemopericardium was continuously pumped back into the patient's femoral artery. Slight perivalvular leak was detected by the fluoroscopy and TEE.

Because we observed that the hemopericardium was with bright red blood rather than blue-black color, there was a high possibility of the left ventricle rupture. Indeed, the Color Flow Doppler imaging clearly showed that a bundle

of blood from the left ventricle ejected to the pericardial cavity [Figure 1A]. We then performed an urgent thoracotomy through the median sternal incision. On the left ventricular surface, we found a 1 cm gap, which was 8 mm away from the left anterior descending branch and parallel with the ventricular septum. Blood ejected to the outside of the left ventricle from the gap with every heartbeat [Figure 1B]. We used two interrupted horizontal mattress sutures with 2-0 Prolene on two felts to close the cleft. There was no myocardial infarction, no stroke, no incision infection, or conduction block post-operatively. The patient was discharged 9 days later.

Some cardiologists suggest that the TAVI procedure can be extremely simplified by finishing the procedure unilaterally in the catheter lab without cardiac surgeons' assistance. However, the case in this study strongly suggests that to ensure patients' safety, the TAVI procedure must be performed by an integrated heart team including both physicians and surgeons in the hybrid theater with cardiopulmonary bypass instruments standing by.^[1] The TAVI procedure calls for physicians' experience in interventional technique, as well as surgeons' knowledge of cardiac anatomy and quick response to severe surgical complications. Furthermore, anesthetists and perfusionists are better coordinated by the dual effort of physicians and cardiac surgeons, adding an extra layer of comprehensive safety for patients. The combination of internal and surgical technology has become essentially required in training programs for cardiac surgeons in some Chinese heart centers.

The disinfection and draping of TAVI should be carried out according to the surgical requirements before the surgery. To minimize the time of disinfection, patient's chest should be fully exposed for urgent thoracotomy if needed. We recommend that at least one cardiac surgeon should participate in the operation.

Access this article online

Quick Response Code:



Website:

www.cmj.org

DOI:

10.1097/CM9.0000000000001098

Correspondence to: Dr. Wei-Min Zhang, Department of Cardiovascular Surgery, Sir Run Run Shaw Hospital, Zhejiang University, Hangzhou, Zhejiang 310016, China
E-Mail: zwm660@zju.edu.cn

Copyright © 2020 The Chinese Medical Association, produced by Wolters Kluwer, Inc. under the CC-BY-NC-ND license. This is an open access article distributed under the terms of the Creative Commons Attribution-Non Commercial-No Derivatives License 4.0 (CCBY-NC-ND), where it is permissible to download and share the work provided it is properly cited. The work cannot be changed in any way or used commercially without permission from the journal.

Chinese Medical Journal 2020;133(20)

Received: 09-05-2020 Edited by: Li-Shao Guo

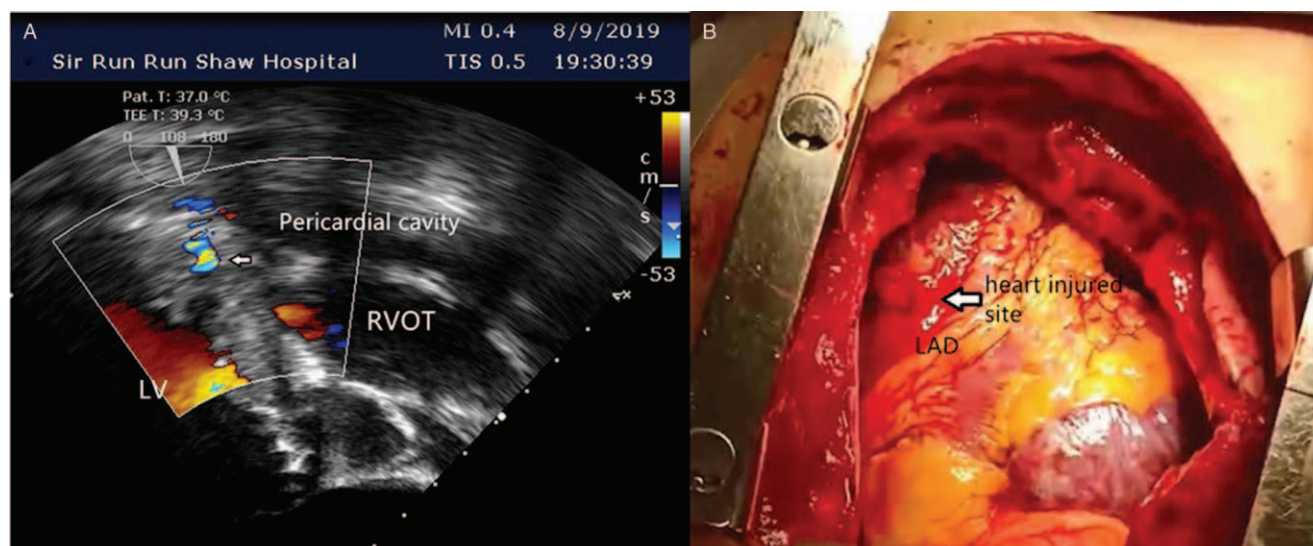


Figure 1: (A) The Color Flow Doppler imaging showed a bundle of blood from the left ventricle ejected to the pericardial cavity. (B) On the left ventricular surface, we found a 1 cm gap, which was 8 mm away from the left anterior descending branch (LAD) and parallel with the ventricular septum. Blood ejected to outside of the left ventricle from the gap with every heartbeat. LV: Left ventricle; RVOT: Right ventricular outflow tract.

Main complications of TAVI include A-V block, stroke, perivalvular leaking, and cardiac rupture, which are the most life-threatening.^[2] High quality performance in each step of the TAVI procedure is the key to prevent heart rupture. Early diagnosis and in-time treatment of the heart rupture can substantially reduce the mortality and disability. Calcified aortic annulus, fragile and scarred myocardium due to likely co-existence of ischemic heart disease with previous infarcts can be the predisposing factors for the development of tamponade during TAVI. Common causes of cardiac tear include the damage of the left ventricle by the stiff guide wire, and the rupture of the aortic annular during the valve dilation by the balloon.^[2,3] The most frequently heart injured site is the anterior wall of the left ventricle about 2 cm left lateral to the left anterior descending artery distribution.^[4] A strong sign of heart rupture is massive continuous pericardial effusion detected by TEE. Consequently, both blood pressure and pulse pressure drop. Therefore, TEE and blood pressure monitoring are critical for diagnosis of cardiac rupture. While reviewing the video recorded TAVI procedure, we found that the stiff guide wire caused the cardiac rupture in our case. When we were dilating the aortic valve with the balloon, the pump flow of the heart did not reduce as expected due to rapid heart pacing. Moreover, the dilated balloon slipped to the left ventricle transiently, which pushed the stiff guide wire to cut the myocardium. Finally, the stiff guide wire broke the left ventricle along the interventricular septum. Stiff wire provides excellent support for the delivery of the valve and is an important component of TAVI procedure. But it also has the potential to cause significant trauma to the left ventricle myocardium. The operators sometimes may focus exclusively on the area of valve dilation or valve deployment. This might briefly divert the attention from the stiff wire in the left ventricle that could migrate and cause the catastrophe. Hence, great caution is necessary during the introduction of the stiff wire in the left ventricle.^[5] From anatomic and pathophysiological points of view, it would be reasonable

to be concerned when a patient has a small cavity and a hypercontractile thin ventricle, where the aorto-mitral angle is narrow. Thereby, for elderly female patients with these risk factors, more attention is needed to be paid to prevent cardiac rupture.^[4]

To rescue patients from potential heart rupture during TAVI procedure, pericardiocentesis should be performed quickly to release the cardiac tamponade.^[5] A three-way plug valve and a transfusion tube can be used to connect the pericardial drainage tube and the femoral artery sheath. Thus, the blood in the pericardium can be pumped out and infused back to the body through the femoral artery immediately and readily. Surgical intervention should be performed as early as possible.^[2,5] It is worth noting that long-time poor perfusion will cause multiple organs failure, including the heart, the brain, and the kidney. In addition, cautions should be taken to avoid a secondary coronary artery injury during the repair of the heart rupture.

Declaration of patient consent

The authors certify that they have obtained all appropriate patient consent forms. In the form, the patient has given his consent for his images and other clinical information to be reported in the article. The patient understands that his name and initials will not be published and due efforts will be made to conceal the identity of the patient, although anonymity cannot be guaranteed.

Conflicts of interest

None.

References

1. Holmes DR Jr, Mack MJ. Writing Committee. Transcatheter valve therapy: a professional society overview from the American College of Cardiology Foundation and the Society of Thoracic Surgeons. *Ann Thorac Surg* 2011;92:380-389. doi: 10.1016/j.athoracsurg.2011.05.067.

2. Eggebrecht H, Vaquerizo B, Moris C, Bossone E, Lämmer J, Czerny M, *et al*. Incidence and outcomes of emergent cardiac surgery during transfemoral transcatheter aortic valve implantation (TAVI): insights from the European Registry on Emergent Cardiac Surgery during TAVI (EuRECS-TAVI). *Eur Heart J* 2018;39:676–684. doi: 10.1093/eurheartj/ehx713.
3. Borz B, Durand E, Godin M, Tron C, Canville A, Litzler PY, *et al*. Incidence, predictors and impact of bleeding after transcatheter aortic valve implantation using the balloon-expandable Edwards prosthesis. *Heart* 2013;99:860–865. doi: 10.1136/heartjnl-2012-303095.
4. Owais T, El Garhy M, Fuchs J, Disha K, Elkaffas S, Breuer M, *et al*. Pathophysiological factors associated with left ventricular perforation in transcatheter aortic valve implantation by transfemoral approach. *J Heart Valve Dis* 2017;26:430–436.
5. Rezq A, Basavarajaiah S, Latib A, Takagi K, Hasegawa T, Figini F, *et al*. Incidence, management, and outcomes of cardiac tamponade during transcatheter aortic valve implantation: a single-center study. *JACC Cardiovasc Interv* 2012;5:1264–1272. doi: 10.1016/j.jcin.2012.08.012.

How to cite this article: Zhang WM, Hong JM, He F, Fu GS, Yu FC. Experience in treating a case of the cardiac rupture during transcatheter aortic valve implantation procedure. *Chin Med J* 2020;133:2518–2520. doi: 10.1097/CM9.0000000000001098