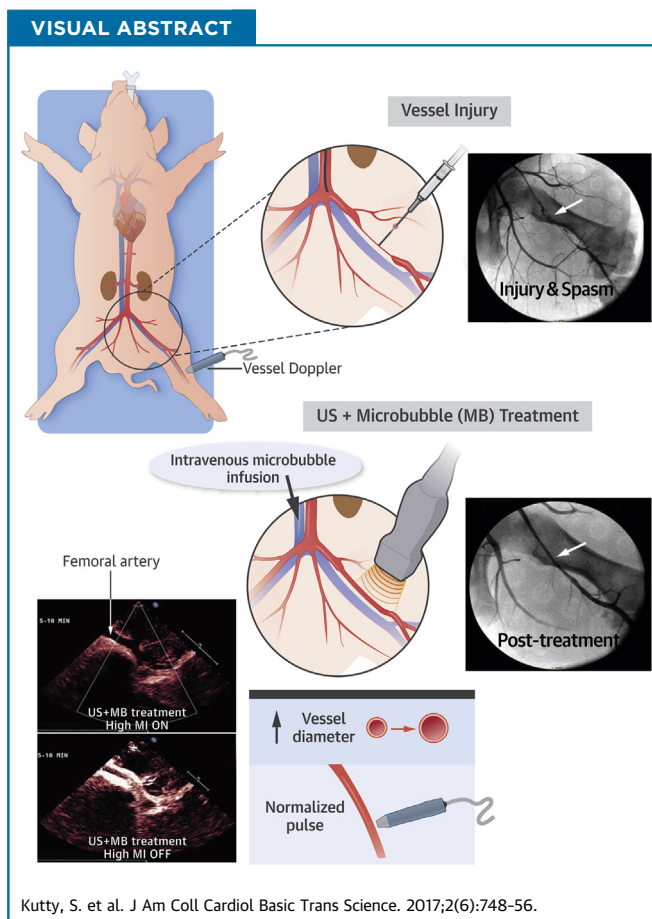


PRECLINICAL RESEARCH

Ultrasound-Induced Microbubble Cavitation for the Treatment of Catheterization-Induced Vasospasm



Shelby Kutty, MD, PhD, MHCM,^a Na Liu, MD, PhD,^{a,b} Jia Zhou, MD, PhD,^{a,c} Yunbin Xiao, MD, PhD,^a Juefei Wu, MD, PhD,^d David A. Danford, MD,^a John Lof, MS,^d Feng Xie, MD,^d Thomas R. Porter, MD^d



HIGHLIGHTS

- In a porcine model, we investigated the therapeutic effectiveness of microbubble enhanced sonothrombolysis for treatment of catheter-induced vasospasm and vascular injury, a common complication after femoral arterial catheterization, particularly in children.
- Our results show that microbubble cavitation mediated by brief application of diagnostic high mechanical index impulses is an effective noninvasive method for relieving catheter-induced vasospasm.
- This approach could have potential as an effective treatment for reversal of pulse loss after peripheral arterial injury and vasospasm.

From the ^aDivision of Pediatric Cardiology, University of Nebraska College of Medicine/Children's Hospital & Medical Center/Creighton University, Omaha, Nebraska; ^bDepartment of Cardiology and Cardiac Catheterization Lab, Second Xiangya Hospital, Central South University, Changsha, China; ^cDepartment of Ultrasonography, the First Affiliated Hospital of University of South China, Hengyang, China; and the ^dDepartment of Internal Medicine, Section of Cardiology, University of Nebraska Medical Center, Omaha, Nebraska. Dr. Kutty is supported by the American Heart Association and the National Institute of Child Health and Development. Dr. Porter is supported by the Theodore F Hubbard Foundation. Funding sources were not involved in data collection, data analysis, or manuscript drafting. All other authors have reported that they have no relationships relevant to the

SUMMARY

Inertial cavitation inducing ultrasound-mediated microbubble treatments can produce resolution of vasospasm and restoration of distal arterial flow after peripheral artery injury. Resolution of catheter-induced vasospasm is likely to be nitric oxide-mediated because improvements in stenosis diameter and downstream blood flow were blunted following pretreatment with L-NAME. The potential for clinical applicability of this therapy is significant because: 1) microbubbles can be delivered systemically into the site of injury enabling relatively high local concentration; 2) targeted transcutaneous ultrasound delivery is achievable due to the proximity of vessels; and 3) microbubbles and diagnostic ultrasound system used are commercially available. (J Am Coll Cardiol Basic Trans Science 2017;2:748-56) © 2017 The Authors. Published by Elsevier on behalf of the American College of Cardiology Foundation. This is an open access article under the CC BY-NC-ND license (<http://creativecommons.org/licenses/by-nc-nd/4.0/>).

ABBREVIATIONS AND ACRONYMS

CIV = catheter-induced vasospasm
CC = cardiac catheterization
L-NAME = N (ω)-nitro-L-arginine methyl ester
MB = microbubble
MI = mechanical index
NO = nitric oxide
UMC = ultrasound-induced microbubble cavitation
US = ultrasound

Arterial vasospasm is a commonly observed complication of cardiac catheterization (CC). Other sequelae of CC-related vascular injury include thrombus formation and post-thrombotic syndrome with either transient or complete loss of arterial pulses in the femoral and distal arteries. Infants and children with heart disease often undergo multiple CC procedures, and are at higher risk for catheter-induced vasospasm (CIV) and thrombosis. Moreover, infants have an increased incidence of thromboembolism (1). Up to 20% of thrombotic events occur in the femoral vessels (1-4) and are associated with larger arterial access points (5-7) and longer procedure times. These factors may be compounded by small body size, polycythemia, and low cardiac output in sick infants (6,8). CIV and loss of femoral pulse after CC contributes to prolonged hospital stay, increased need for medical and/or surgical interventions, and difficulty with future vascular access. Despite technological improvements such as the use of indwelling arterial sheaths for a shorter duration (9), smaller balloon/catheter profiles (10,11), and systemic heparinization (12), complications of CC-related vascular injury continue to occur.

Ultrasound (US) has been investigated as an adjunct to pharmacologic thrombolysis, as well as an independent treatment for vascular thrombosis (13-16). Guided high mechanical index (MI) impulses from a diagnostic US system during intravenous microbubble (MB) infusion have the potential to dissolve intravascular thrombi (termed sonothrombolysis) without

the need for fibrinolytic therapy. We have previously studied the feasibility of treating deeply located acute intravascular thrombi with US and intravenous MBs (17-19). The spasm reversal properties of US + systemic MB therapy have not been previously investigated, but diagnostic US-induced MB cavitation has been shown to enhance endothelial nitric oxide (NO) release (20,21). Our principal hypothesis was that US and MB therapy might have an immediate effect on reversing pulse loss following CIV by promoting NO-mediated resolution of spasm. We sought to investigate the: 1) safety and feasibility; and 2) therapeutic effectiveness of MB-enhanced sonothrombolysis for treatment of CIV. A porcine model was chosen based on our previous work which demonstrated safety of intravenous MB and transcutaneous US in this model.

METHODS

PORCINE MODELS OF CIV. The study was approved by the Institutional Animal Care and Use Committee of the University of Nebraska Medical Center and was in compliance with the standards in the Guide for the Care and Use of Laboratory Animals. Models of CIV were created in pigs: in a unilateral femoral artery, or bilateral femoral arteries separated at 1-week time intervals. Before the procedure, each pig was fasted overnight and pre-anesthetized with an intramuscular mixture of Telazol (4.4 mg/kg; tiletamine HCl and zolazepam HCl, Fort Dodge Animal Health, Fort

contents of this paper to disclose. All institutional and national guidelines for the care and use of laboratory animals were followed and approved by the appropriate institutional committees. Drs. Kutty and Liu contributed equally to this work. All authors attest they are in compliance with human studies committees and animal welfare regulations of the authors' institutions and Food and Drug Administration guidelines, including patient consent where appropriate. For more information, visit the *JACC: Basic to Translational Science* [author instructions page](#).

Manuscript received May 5, 2017; revised manuscript received July 18, 2017, accepted July 20, 2017.

Dodge, Iowa), ketamine (2.2 mg/kg; Bioniche Teoranta, Inverin, Co. Galway, Ireland), and xylazine (2.2 mg/kg; Lloyd Laboratories, Shenandoah, Iowa). Intramuscular atropine (0.05 mg/kg) was used to dry oral-tracheal secretions and prevent bradycardia during intubation. After placement of a venous line in the ear, the pig was intubated and isoflurane inhalation anesthesia (induction at 4%, maintenance at 1.0% to 1.8%) was administered. The animal was placed on a ventilator at a volume of 11 ml/kg of air at 15 breaths per minute.

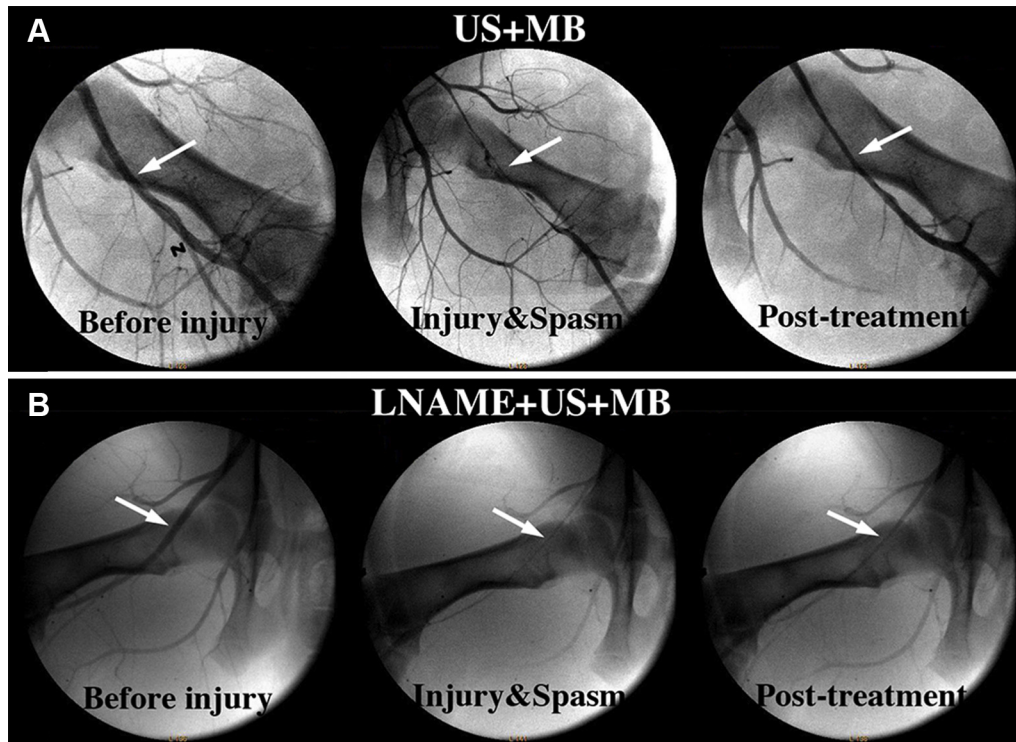
Before creation of CIV, baseline 2-dimensional (2-D) and color Doppler imaging of the femoral artery was obtained with a 5-MHz transducer (S5-1, Philips Healthcare, Andover, Massachusetts). 2-D and pulsed Doppler examination of the distal ipsilateral popliteal artery (4V1c transducer, Siemens) was continuously recorded. Angiography of bilateral ilio-femoral-popliteal vessels was obtained with 5 ml to 10 ml of iodinated contrast (iohexol or iopamidol) injected through a 6-F pigtail catheter introduced via carotid cut-down and positioned at the iliac bifurcation. CIV was induced by percutaneous punctures of the femoral artery with an 18-gauge needle 2 cm to 3 cm below the inguinal ligament. The artery was injured 3 to 5 times for induction of spasm. A 0.025-inch straight guidewire was introduced into the artery after each access and moved within the vessel 3 to 4 times to enhance creation of spasm, simulating clinical arterial trauma. CIV was defined as >50% reduction in the circumferential size of the vessel on angiography and >50% reduction in distal popliteal artery velocity by pulsed Doppler for 5 min. At this point, the animals were randomized to 1 of 4 groups (see the following text). The angiographic lumen size of the femoral artery from the proximal to distal aspect of the segment of spasm, and the Doppler maximal velocity (V_{max}) and velocity time integral (VTI) in the popliteal artery were measured before and after randomized treatments.

MICROBUBBLE AND DIAGNOSTIC ULTRASOUND SETTINGS. Commercially available MB, Definity (Lantheus Medical Imaging, North Billerica, Massachusetts), which have a diameter of 1.1 to 3.0 μm , and concentration of 1.5 to 3.0 $\times 10^{10}/\text{ml}$ once activated was used for the study. The MB infusion was prepared by diluting 2 ml activated Definity in 100 ml of 0.9% saline. A modified diagnostic US system (iE33, Philips Healthcare) and diagnostic transducer (S5-1, Philips Healthcare) were used. The US system had low MI contrast sensitive imaging pulse sequences (Power Modulation) that was applied in between high MI impulses to assist in MB detection. Group 1 consisted of controls that received no treatment, and group 2 consisted of treatment with transcutaneous US alone.

Treatment in group 3 consisted of transcutaneous US and MB. In group 3, brief high MI impulses (1.1 MI; 20 μs pulse duration; 1.6 MHz; S5-1; Philips Healthcare) were guided to allow replenishment of MB at the region of interest with a typical off time of 2 s to 3 s between the high MI applications. In group 4, pigs were administered N (ω)-nitro-L-arginine methyl ester (L-NAME), 20 mg/kg, intravenously 5 min before arterial injury to determine what effects L-NAME alone had on CIV, and then determine what effect it had on US-induced MB cavitation. In groups 3 and 4, ketorolac trimethamine (60 mg intravenously) and methylprednisolone sodium succinate (Solu-medrol, 40 mg intravenously) were administered prior to inhibit any pulmonary macrophage responses to MB. During treatment (groups 2, 3, and 4), brief high MI impulses of 1.2 MI (5 s on, 5 s off) were delivered to the site of arterial injury. MBs (in groups 3 and 4 only) were administered as an infusion (3 ml to 4 ml/min, over 15 min) with simultaneous application of US. All US treatment times were 15 min. After post-treatment measurements, the animals were either sacrificed after treatment of unilateral CIV, or recovered from anesthesia, transferred to housing and brought back to the laboratory after 1 week for contralateral femoral artery injury and randomized CIV treatment before sacrifice. At completion of protocol while under general anesthesia, the animal was euthanized by an intravenous dose of pharmaceutical grade potassium chloride (60 to 120 mEq) or Beuthanasia (1 ml of solution per 4.5 kg of body weight). Euthanasia was determined to be complete when the animal had no recordable pulse or spontaneous respiration and there was no blood pressure for more than 5 min.

ANGIOGRAPHIC AND DOPPLER MEASUREMENTS. Angiograms were uploaded to computer workstation, and a digital measurement tool (Philips DICOM Viewer, R 30-SP03, Philips Medical System, Best, the Netherlands) was used to measure diameter of the femoral artery at the mid aspect and at the proximal and distal ends of the narrowed segment after analyzing frame-by-frame cine images. Particular care was taken to ensure that the measurements were taken from exactly the same vessel segment using the anatomic landmarks identified during angiography. Three measurements were taken at each site and averaged to obtain the final average dimension of the CIV segment. The percentage stenosis was calculated as: (baseline dimension – most narrow post injury dimension)/baseline dimension $\times 100$. This was compared to the post-treatment value calculated as: (baseline dimension – most narrow post-treatment dimension)/baseline dimension $\times 100$. The peak velocity (V_{max}) and VTI of popliteal artery were

FIGURE 1 Changes in Femoral Angiographic Lumen Size



(A, B) The angiographic lumen size of the femoral artery (white arrows) (from the site of injury to the popliteal artery) was measured before and after randomized treatments. The degree of CIV was similar in the pigs pre-treated with L-NAME (B). CIV = catheter-induced vasospasm; L-NAME = N (ω)-nitro-L-arginine methyl ester; MB = microbubble; US = ultrasound.

measured using tools in the Acuson Sequoia C512 system (Siemens Medical Solutions USA, Inc., Mountain View, California). The Doppler data were measured from 3 cardiac cycles and averaged.

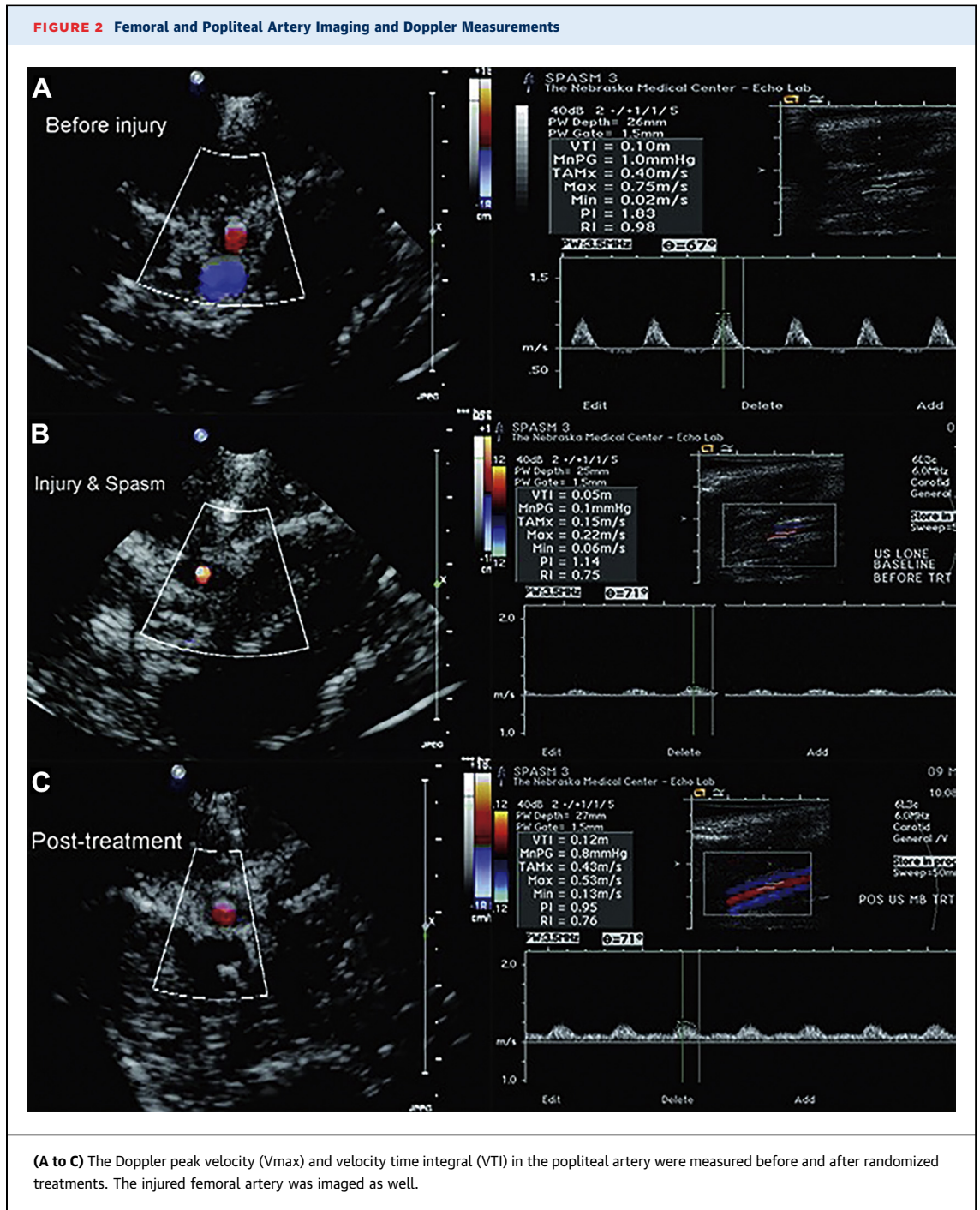
SAFETY AND FEASIBILITY ASSESSMENTS. Safety of US and MB treatments was evaluated by continuously monitoring heart rate, oxygen saturation, arterial blood pressure, and 12-lead electrocardiograms before and after treatment.

STATISTICAL ANALYSIS. Mean \pm SD were determined for continuous variables. Because some, but not all animals were subjects of more than 1 experiment, a hierarchical cluster analysis (22) was undertaken to determine the contribution to outcome associated with the identity of the experimental animal relative to the contribution of the treatment. The levels of the hierarchy were: 1) animal; 2) treatment type; and 3) pre- or post-treatment status. Variance partition coefficients were calculated at each hierarchical level for the 3 outcomes of interest: 1) angiographic stenosis percentage; 2) popliteal Vmax; and 3) popliteal VTI. Student's *t*-test was used

to compare heart rate, oxygen saturation, and arterial blood pressure before and after randomized treatments. The multilevel hierarchical model results were evaluated, and only when there was minimal animal identity effect, and when there were clear contributions of both treatment type and pre- versus post-treatment status, was Student's *t*-testing undertaken to compare the outcome before and after treatment. A *p* value <0.05 was considered significant. Statistical analysis was performed using commercially available software (Minitab version 16.1, Minitab Inc.) and Microsoft Excel (Microsoft Inc., Redmond, Washington).

RESULTS

A total of 24 randomized CIV treatments were performed in 16 pigs. Eight pigs had unilateral (in either femoral artery) creation and treatment of CIV, and 8 pigs had CIV creation and treatments in bilateral femoral arteries separated by 1 week. Animal weight at the time of procedure was 50.4 ± 12.3 kg. **Figure 1** shows an example of angiographic lumen size of the

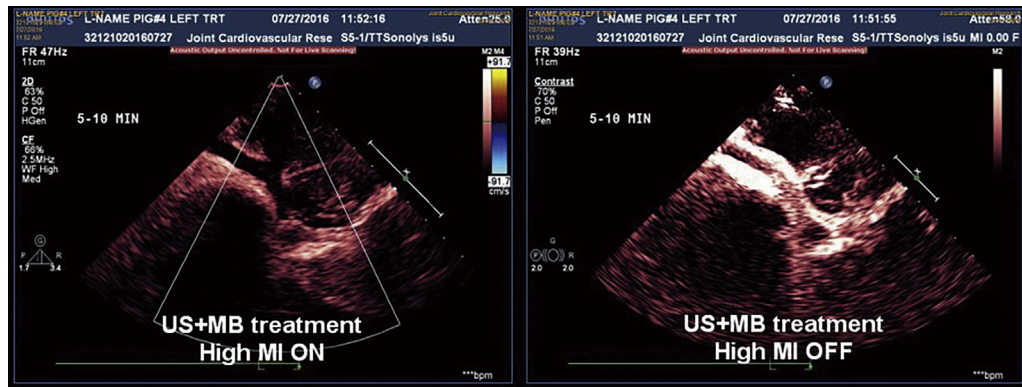


femoral artery at baseline, with creation of CIV, and after randomized US and MB treatment (in the presence and absence of L-NAME). **Figure 2** shows the changes in a cross-section of the femoral lumen, and the popliteal Doppler at baseline, immediately after injury, and after diagnostic US + MB treatment. **Figure 3** shows 2-D US image of the femoral artery

obtained during treatment with and without application of high MI impulses.

Table 1 summarizes the hemodynamic measurements in all animals before and immediately after randomized treatments. There were no statistically significant differences in these parameters among the groups with any of the randomized therapies.

FIGURE 3 Femoral Artery Imaging During US+MB Treatment



Images of the femoral artery (from the site of injury to the popliteal artery) during microbubble treatment, with and without application of high mechanical index impulses. Abbreviations as in Figure 1.

The 3-level regression analysis of outcomes relative to animal, treatment type, and pre- versus post-treatment status is summarized in Table 2. The model for angiographic stenosis percentage was strong, and revealed effects attributable to both type of treatment and pre- versus post-treatment status, but negligible effects attributable to the animal. Although significant differences were observed before and after treatment, the models for popliteal Vmax and VTI were weaker. Further analysis focused on angiographic outcome with the various treatments; these are shown in Table 3. Significant treatment effects were demonstrated with US alone and with US + MB, but not in the L-NAME and control groups. In the US + MB treated group, the popliteal

artery Vmax and VTI before and after treatment were 0.14 ± 0.08 m/s and 0.35 ± 0.27 m/s ($p = 0.02$), and 0.03 ± 0.02 m and 0.08 ± 0.05 m ($p = 0.01$), respectively. The respective measurements in the L-NAME pre-treated group were 0.16 ± 0.09 m/s and 0.18 ± 0.10 m/s ($p = 0.73$) and 0.03 ± 0.01 m and 0.02 ± 0.01 m ($p = 0.71$). Changes in Vmax and VTI before and after treatment were significant for the diagnostic US + MB treated pigs ($p < 0.05$).

Typically, L-NAME-induced systemic vascular effects are fully developed by 5 min to 10 min in anaesthetized, acutely prepared animals. Femoral angiographic diameters and Doppler flow parameters

TABLE 1 Summary of Hemodynamic Data in all Animals Before and After Treatment

	Before Treatment	After Treatment	p Value
First experiment			
HR	103 ± 4	98 ± 4	0.18
SBP (mm Hg)	94 ± 8	105 ± 8	0.56
DBP (mm Hg)	63 ± 5	79 ± 10	0.59
SpO2 (%)	100 ± 0	99 ± 0.6	0.36
Second experiment			
HR	104 ± 2	101 ± 5	0.15
SBP (mm Hg)	96 ± 9	106 ± 6	0.44
DBP (mm Hg)	72 ± 8	80 ± 9	0.64
SpO2 (%)	100 ± 0	97 ± 0.4	0.42

Values are mean ± SD.
 DBP = diastolic blood pressure; HR = heart rate; SBP = systolic blood pressure.

TABLE 2 Three-Level Regression Analysis of Outcomes Relative to Animal, Treatment Type, and Pre- Versus Post-Treatment Status

	VPC	p Value	Model R ² (%)
Angiography stenosis			
Pre- vs. post-treatment	0.826	<0.001	54.8
Treatment type	0.171	0.003	
Animal specific	0.003	0.66	
Popliteal VTI			
Pre- vs. post-treatment	0.700	0.011	15.7
Treatment type	0.014	0.71	
Animal specific	0.285	0.10	
Popliteal Vmax			
Pre- vs. post-treatment	0.619	0.021	10.7
Treatment type	0.073	0.42	
Animal specific	0.308	0.10	

Vmax = maximum velocity; VPC = variance partition coefficient; VTI = velocity time integral.

TABLE 3 Changes in Femoral Artery Stenosis Diameter by Angiography in the 4 Groups

Angiographic Stenosis (%)	Before Treatment	After Treatment	p Value
Controls (n = 4)	78 ± 10	71 ± 5	0.33
US alone (n = 6)	76 ± 12	50 ± 9	0.03
US + MB (n = 10)	80 ± 7	53 ± 10	0.0002
L-NAME + US + MB (n = 4)	80 ± 7	72 ± 11	0.23

Values are mean ± SD.
L-NAME = N (ω)-nitro-L-arginine methyl ester; MB = microbubble;
US = ultrasound.

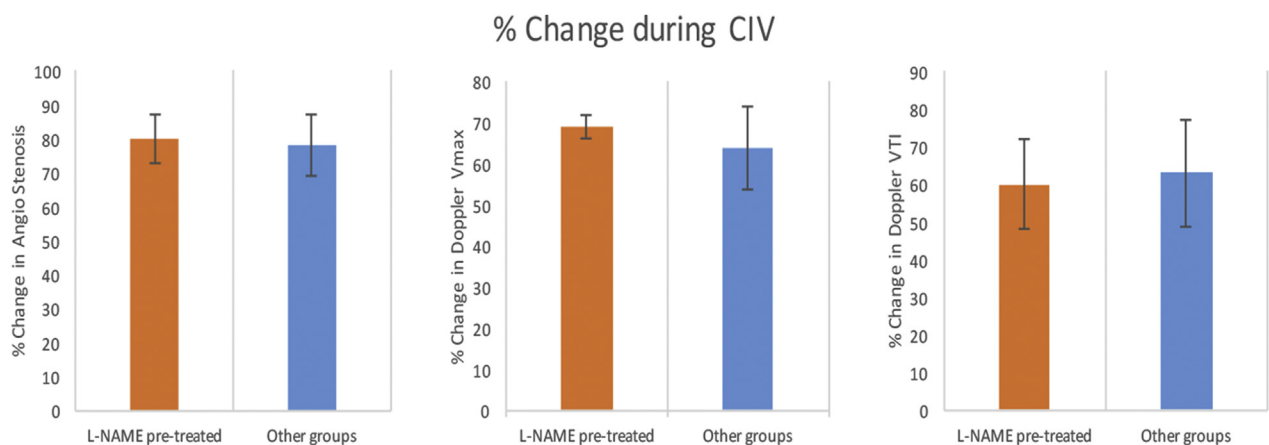
before and after the needle injury (before randomized treatment) in the L-NAME pre-treated groups were not different than the three groups that were not pre-treated with L-NAME (Figure 4), indicating no direct effect of L-NAME alone on vessel diameters or flow changes.

DISCUSSION

Although there have been considerable improvements in equipment and skills, vascular injury and CIV continue to complicate catheterization procedures (5,23). These complications include arterial spasm, thrombus formation, and post-thrombotic syndrome with loss of arterial pulse, often resulting in prolonged hospital stay, need for further

intervention, and difficulty with future vascular access. In this study, we show the feasibility of achieving reduction in CIV using a 15-min treatment with diagnostic US and intravenous MB. An image-guided approach was used by ensuring the presence of MB in the region of CIV when the high-MI US impulses are applied. Significant improvements were noted in the angiographic measurements of femoral lumen size before and after treatment. Post-treatment angiography also served as a monitor of distal small vessel occlusion from potential thrombus dislodgement; none of the animals developed signs suggestive of distal vessel occlusion.

It has been shown that NO contributes to vessel dilation by inhibiting vascular smooth muscle constriction (24). Belcik *et al.* (25) have shown in a peripheral artery disease model that MB cavitation augments diagnostic US-mediated hyperemia and can acutely reverse tissue ischemia. Both NO production and endothelial NO synthase phosphorylation increased incrementally with MB cavitation induced by guided diagnostic high-MI impulses (25). This improvement in microvascular perfusion during acute ischemia has been shown with non-imaging low-frequency transducers as well. Others have shown enhanced myocardial tissue perfusion in the setting of coronary occlusion with US- and MB-mediated cavitation resulting from NO-mediated enhancement of coronary artery collateral flow (26).

FIGURE 4 Angiographic and Doppler Changes in L-NAME Group Versus Other Groups

Changes in angiographic diameters and Doppler flow parameters before and after needle injury (pre-treatment) in the L-NAME group pigs versus the other groups not pre-treated with L-NAME (combined for the sake of comparison). Note the percentage change in angiographic diameter, VTI, and Vmax is not different between the groups. Abbreviations as in Figures 1 and 2.

Furthermore, transcutaneous low-frequency US energy alone has been shown to have vasodilatory effects mediated by an NO-dependent mechanism (27). Resolution of CIV with US and MB therapy in our model is also likely to be NO-mediated because the improvement in stenosis diameter and downstream popliteal blood flow was blunted after pre-treatment with L-NAME, an inhibitor of nitric oxide synthase (28–30), before injury and treatment.

The potential for clinical applicability of this therapy in the setting of peripheral interventions is significant because: 1) MBs can be delivered systemically into the site of arterial injury and CIV enabling a relatively high local MB concentration; 2) targeted delivery of transcutaneous US to the site is achievable due to the proximity of femoral vessels; and 3) the contrast MB (Definity) and diagnostic US system used in the present study are commercially available and used widely. Therefore, further progress with this application could have significant potential as a safe, effective, and noninvasive treatment for catheterization related peripheral arterial injury, CIV, and pulse loss. US- and MB-mediated methods to stimulate local vasodilation could be explored to treat the vasospasm that accompanies other pathophysiologic processes such as intracranial hemorrhage (21).

The findings of the current study differ from those of Roos *et al.* (16) who found coronary vasoconstriction induced by transthoracic high-MI impulses during an MB infusion in patients with acute ST-segment elevation myocardial infarction (16). These high-MI impulses were nearly identical to the ones delivered in the current study. Additional animal studies were performed in the study by Roos *et al.* (16) where, in a porcine model of coronary injury, diagnostic US-induced MB cavitation resulted in coronary vasodilation following injury alone, but that this vasodilation was reversed when concomitant arterial thrombus was present. In this study, it was also observed that in the absence of prior balloon injury, the intermittent high-MI longer pulse durations actually increased coronary artery diameter. This is in concordance with Belcik *et al.* (25) who showed increases in vessel diameter when US with intermittent high-MI pulses was used in nonischemic mice. After balloon injury of the proximal left anterior descending coronary artery in our pig experiments, there was an even greater improvement in vessel diameter (19% increase) at

the injury site in response to US. Only in the presence of thrombus did intermittent high-MI US resulted in a reduction in vessel diameter distal to the injury site (25). We speculate that cavitation of arterial thrombus may induce platelet-mediated vasoconstriction through thromboxane or serotonin release, and counter the beneficial effects observed because of NO release. Further study is needed to determine what effect any concomitant arterial thrombus present during CIV would have on our study results.

STUDY LIMITATIONS. Angiographic assessment of vessel stenosis was the primary outcome variable examined in the present study. Angiographic assessment, however, does not have adequate resolution to appreciate small changes in lumen reduction following vascular interventions, which is a potential limitation of the study. Although there were significant improvements in VTI and Vmax with the US + MB treated group, it was unclear on the basis of the repeated measurements in the same animal what effect this had on the results. We do not believe it was related to any effect of the previous interventions performed at least 7 days earlier, since the Definity MB half-life is in minutes. However, a prolonged NO effect from the previous treatment cannot totally be ruled out based on the statistical analysis (31).

CONCLUSIONS

Our results indicate that a brief application of diagnostic high MI impulses during a commercially available MB infusion may be an effective noninvasive method of treating catheter-induced vasospasm. This approach could have significant potential as a safe, effective, and noninvasive treatment for CIV in infants and children.

ACKNOWLEDGMENTS The authors thank Elizabeth Stolze, Lucas Drvol, and Gretchen Fry of the Joint Cardiovascular Research Laboratory of the University of Nebraska Medical Center for their expert technical assistance.

ADDRESS FOR CORRESPONDENCE: Dr. Shelby Kutty, Division of Pediatric Cardiology, University of Nebraska Medical Center, 982265 Nebraska Medical Center, Omaha, Nebraska 68198-2265. E-mail: skutty@unmc.edu.

PERSPECTIVES

COMPETENCY IN MEDICAL KNOWLEDGE

Specific diagnostic US-mediated microbubble cavitation settings can be utilized to reverse vasospasm and improve tissue perfusion in porcine models of peripheral arterial spasm, which may be related to locally increased nitric oxide release. The methodology should next be examined for treatments in humans, and if successful could have therapeutic potential in the management of peripheral arterial injury and vasospasm.

TRANSLATIONAL OUTLOOK Diagnostic US-mediated microbubble cavitation could be a targeted method of locally augmenting endothelial responses in clinical situations where it may be beneficial to reverse vasoconstrictive states. Mechanistically, the role of specific chemical mediators needs to be further studied, as well as the cavitation events that optimize vasodilation and improved flow.

REFERENCES

- Saxena A, Gupta R, Kumar RK, Kothari SS, Wasir HS. Predictors of arterial thrombosis after diagnostic cardiac catheterization in infants and children randomized to two heparin dosages. *Cathet Cardiovasc Diagn* 1997;41:400-3.
- Rothman A. Arterial complications of interventional cardiac catheterization in patients with congenital heart disease. *Circulation* 1990;82:1868-71.
- Burrows PE, Benson LN, Williams WG, et al. Iliofemoral arterial complications of balloon angioplasty for systemic obstructions in infants and children. *Circulation* 1990;82:1697-704.
- Balaguru D, Dilawar M, Ruff P, Radtke WA. Early and late results of thrombolytic therapy using tissue-type plasminogen activator to restore arterial pulse after cardiac catheterization in infants and small children. *Am J Cardiol* 2003;91:908-10.
- Vitiello R, McCrindle BW, Nykanen D, Freedom RM, Benson LN. Complications associated with pediatric cardiac catheterization. *J Am Coll Cardiol* 1998;32:1433-40.
- Bouhoutsos J, Morris T. Femoral artery complications after diagnostic procedures. *Br Med J* 1973;3:396-9.
- Hanslik A, Thom K, Haumer M, et al. Incidence and diagnosis of thrombosis in children with short-term central venous lines of the upper venous system. *Pediatrics* 2008;122:1284-91.
- Smith C, Green RM. Pediatric vascular injuries. *Surgery* 1981;90:20-31.
- Neches WH, Mullins CE, Williams RL, Vargo TA, McNamara DG. Percutaneous sheath cardiac catheterization. *Am J Cardiol* 1972;30:378-84.
- Beekman RH, Rocchini AP, Andes A. Balloon valvuloplasty for critical aortic stenosis in the newborn: influence of new catheter technology. *J Am Coll Cardiol* 1991;17:1172-6.
- Mullins CE, Nihill MR, Vick GW 3rd, et al. Double balloon technique for dilation of valvular or vessel stenosis in congenital and acquired heart disease. *J Am Coll Cardiol* 1987;10:107-14.
- Girod DA, Hurwitz RA. Heparinization for prevention of thrombosis following pediatric percutaneous arterial catheterization. *Pediatr Cardiol* 1982;3:175-80.
- Tachibana K, Tachibana S. Albumin microbubble echo-contrast material as an enhancer for ultrasound accelerated thrombolysis. *Circulation* 1995;92:1148-50.
- Porter TR, LeVeen RF, Fox R, Kricsfeld A, Xie F. Thrombolytic enhancement with perfluorocarbonexposed sonicated dextrose albumin microbubbles. *Am Heart J* 1996;132:964-8.
- Xie F, Tsutsui JM, Lof J, et al. Effectiveness of lipid microbubbles and ultrasound in de clotting thrombosis. *Ultrasound Med Biol* 2005;31:979-85.
- Roos ST, Juffermans LJM, van Royen N, et al. Unexpected High Incidence of Coronary Vasoconstriction in the Reduction of Microvascular Injury Using Sonolysis (ROMIUS) Trial. *Ultrasound Med Biol* 2016;42:1919-28.
- Kutty S, Xie F, Gao S, et al. Sonothrombolysis of intra-catheter aged venous thrombi using microbubble enhancement and guided three-dimensional ultrasound pulses. *J Am Soc Echocardiogr* 2010;23:1001-6.
- Kutty S, Wu J, Hammel J M, et al. Microbubble mediated thrombus dissolution with diagnostic ultrasound for the treatment of chronic venous thrombi. *PLoS ONE* 2012;7:e51453.
- Kutty S, Wu J, Hammel J M, et al. Prevention of arteriovenous shunt occlusion using microbubble and ultrasound mediated thromboprophylaxis. *J Am Heart Assoc* 2014;3:e000689.
- Porter TR, Kricsfeld D, Lof J, Everbach EC, Xie F. Effectiveness of transcranial and trans-thoracic ultrasound and microbubbles in dissolving intravascular thrombi. *J Ultrasound Med* 2001;20:1313-25.
- Xie F, Lof J, Everbach C, et al. Treatment of acute intravascular thrombi with diagnostic ultrasound and intravenous microbubbles. *J Am Coll Cardiol Img* 2009;2:511-8.
- Pearl DL. Making the most of clustered data in laboratory animal research using multi-level models. *ILAR J* 2014;55(3):486-92.
- Bennett D, Marcus R, Stokes M. Incidents and complications during pediatric cardiac catheterization. *Paediatr Anaesth* 2005;15:1083-8.
- Palmer RMJ, Ferrige AG, Moncada S. Nitric oxide accounts for the biological activity of endothelium-derived relaxing factor. *Nature* 1987;327:524-6.
- Belcik JT, Mott BH, Xie A, et al. Augmentation of limb perfusion and reversal of tissue ischemia produced by ultrasound-mediated microbubble cavitation. *Circ Cardiovasc Imaging* 2015;8: pii: e002979.
- Siegel RJ, Suchkova VN, Miyamoto T, et al. Ultrasound energy improves myocardial perfusion in the presence of coronary occlusion. *J Am Coll Cardiol* 2004;44:1454-8.
- Iida K, Luo H, Hagsawa K, et al. Noninvasive low-frequency ultrasound energy causes vasodilation in humans. *J Am Coll Cardiol* 2006;48:532-7.
- Suchkova VN, Baggs RB, Sahni SK, Francis CW. Ultrasound improves tissue perfusion in ischemic tissue through a nitric oxide dependent mechanism. *Thromb Haemost* 2002;88:865-70.
- Yang HT, Ren J, Laughlin MH, Terjung RL. Prior exercise training produces NO-dependent increases in collateral blood flow after acute arterial occlusion. *Am J Physiol Heart Circ Physiol* 2002;282:H301-10.
- Rawls SM, Tallarida RJ, Gray AM, Geller EB, Adler MW. L-NAME, a nitric oxide synthase inhibitor, and WIN 55212-2, a cannabinoid agonist, interact to evoke synergistic hypothermia. *J Pharmacol Exp Ther* 2004;308:780-6.
- Belcik JT, Davidson BP, Xie A, et al. Augmentation of muscle blood flow by ultrasound cavitation is mediated by ATP and purinergic signaling. *Circulation* 2017;135:1240-52.

KEY WORDS catheter-induced vasospasm, microbubble, N (ω)-nitro-L-arginine methyl ester, ultrasound, velocity time integral