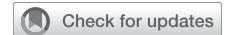

Neotracheal reconstruction with autologous forearm free flap for long-segment tracheal reconstruction: A case report



Arushi P. Mahajan, BS,^a Rebecca W. Gao, MD,^b Samuel A. Schechtman, MD,^c Ross Blank, MD,^c Steven B. Chinn, MD,^b and Elliot Wakeam, MD,^d Ann Arbor, Mich, and Toronto, Ontario, Canada

From the ^aUniversity of Michigan Medical School, Ann Arbor, Mich; Departments of ^bOtolaryngology and ^cAnesthesiology, University of Michigan, Ann Arbor, Mich; and ^dDivision of Thoracic Surgery, Toronto General Hospital, Toronto, Ontario, Canada.

Disclosures: The authors reported no conflicts of interest.

The *Journal* policy requires editors and reviewers to disclose conflicts of interest and to decline handling or reviewing manuscripts for which they may have a conflict of interest. The editors and reviewers of this article have no conflicts of interest.

Received for publication May 24, 2022; revisions received Sept 21, 2022; accepted for publication Oct 3, 2022; available ahead of print Oct 12, 2022.

Address for reprints: Elliot Wakeam, MD, 200 Elizabeth St, Toronto, Ontario, 9N-955, Canada; (E-mail: Elliot.wakeam2@unh.ca or ewakeam@med.umich.edu).

JTCVS Techniques 2022;16:169-71

2666-2507

Copyright © 2022 Published by Elsevier Inc. on behalf of The American Association for Thoracic Surgery. This is an open access article under the CC BY-NC-ND license (<http://creativecommons.org/licenses/by-nc-nd/4.0/>). <https://doi.org/10.1016/j.jtc.2022.10.005>

Long-segment tracheal reconstructions have remained a complex surgical challenge. Scientists have investigated the roles of synthetic prostheses, tissue-engineering scaffolds, allografting, and allograft transplantation—yet an effective method remains elusive.¹⁻⁴

Surgical treatment for primary tracheal cancer has been described via a radial forearm free flap with a splint. Previous research demonstrated that external stabilization with a splinted aortic graft and a slow absorbable matrix helped maintain patency and integrity.⁵ We report a case of long-segment tracheal reconstruction with an autologous composite graft composed of a radial forearm free flap and an external splint (Figure 1).

CASE PRESENTATION/METHODS

We present a case of a 64-year-old male patient with a history of concurrent T1N0 squamous cell carcinomas of the right true vocal fold and epiglottis treated with definitive radiation who underwent tracheal resection and reconstruction. Two years later, he developed 2 distinct endotracheal lesions that were poorly differentiated, p-16–positive squamous cell carcinomas (Figure 2). After seeking multiple expert opinions from several institutions, the patient elected for surgical resection with possible reconstruction over concurrent carboplatin/paclitaxel with irradiation, knowing the significant associated risks with this aggressive intervention. Bronchoscopy measurements demonstrated 2.4 cm of normal tissue from cricoid to the superior aspect of the first lesion and 2.2 cm of normal tissue from the inferior aspect of the most distal lesion to the carina. The total tracheal length was 10.1 cm with 5.5 cm involved by tumor.

Surgical Exposure

The head and neck microvascular reconstruction team and thoracic team performed suprahyoid and infrahyoid releases with a near-total tracheal resection with pericardial releases via a sternotomy. This was required for appropriate access to the carina, given the location of the final distal

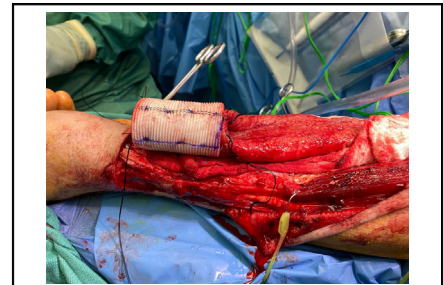


Image of the radial microvascular free flap and an external splint with vascular pedicle.

CENTRAL MESSAGE

An autologous composite graft composed of a microvascular free flap and an external splint may be suitable for long segment tracheal reconstructions.

anastomosis. The total resected trachea was 6.5 cm. Cross-field ventilation was maintained via a sterile armored endotracheal tube inserted directly into the distal trachea at the level of the transection. A 1-cm gap remained even when the anastomosis was brought together under significant tension, and so the intraoperative decision-making confirmed proceeding with the composite graft reconstruction.

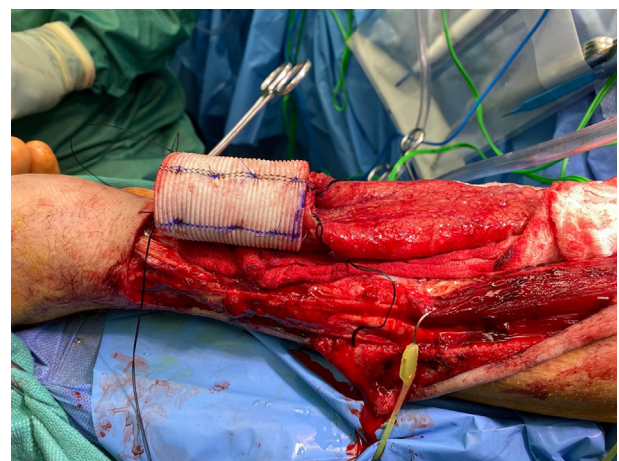


FIGURE 1. Radial microvascular free flap and an external splint with vascular pedicle.

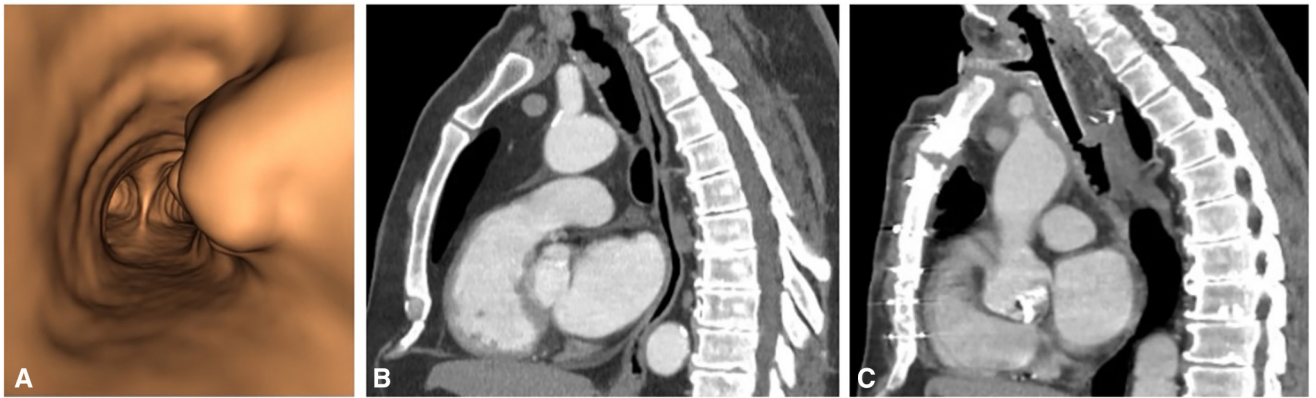


FIGURE 2. A, Three-dimensional imaging reconstruction of endotracheal tumor. B, Preoperative computed tomography imaging of the chest, sagittal view. Lobulated soft tissue at the anterior part of the proximal trachea at T1–T2 vertebral levels with an additional right lateral nodule at T2–T3. C, Post-operative computed tomography imaging of the chest, sagittal view, at 6 months. T-tube in place.

Creating the Interposition Graft

The radial forearm flap was created using a 10- × 7-cm template with 6 cm of proximal adipo-fascial margins (Figure 1). The radial forearm flap was folded in on itself to create a tube, which was then sutured to a 10- × 6-cm, 0.5-mm Synthes graft (Johnson & Johnson). The bio-absorbable Synthes graft was bent over a 50-mL syringe to ensure at least a 3-cm diameter and served as a stent to prevent the collapse and stenosis of the transposed tissue. A 30-mm Hemashield aortic graft (Maquet Cardiovascular, LLC) was draped over the outside of the graft to create the composite product, which was then inserted into the body cavity. The radial artery anastomosis was performed to the left internal mammary artery, and the radial vena comitans was anastomosed to the left external jugular vein (Figure 3).

The endotracheal tube was removed to allow completion of the distal anastomosis and then moved to the proximal end of the graft to allow ongoing cross-field ventilation. Each anastomosis was created with 2 corner sutures of 3-0 VICRYL on the membranocartilaginous junction as stay sutures with a running 4-0 polydioxanone on the back wall. Once the back wall had been parachuted, the corners were tied, and interrupted 3-0

polydioxanone were used for the cartilage anteriorly. Pedicled thymic and pericardial fat pads were placed to separate the aorta and innominate artery from the graft. A 16-French T-tube was placed, and the patient was reintubated with a nasotracheal tube placed in the proximal limb of the T-tube.

Final pathology demonstrated moderately differentiated squamous cell carcinoma with 2 primary lesions, the largest of which measured 1.6 cm. The specimen demonstrated negative final margins, and negative lymph nodes.

The patient was transferred to the intensive care unit. He underwent twice-daily bronchoscopy for secretion clearance for the first 4 days. On the fourth postoperative day, the nasotracheal tube was removed. Three weeks later, the patient was discharged with a T-tube. Tracheoscopy performed at 2 months demonstrated a well-healing graft that was partially mucosalized. At his 6-month visit, the T-tube was planned for removal since the graft had healed well, and his reconstructed airway was deemed appropriate for decannulation. However, tumor recurrence was noted on this assessment, and the decision was made to maintain an artificial airway, given the anticipated necessity of frequent future instrumentation and laser treatment. Ultimately the patient’s tube was replaced with a custom

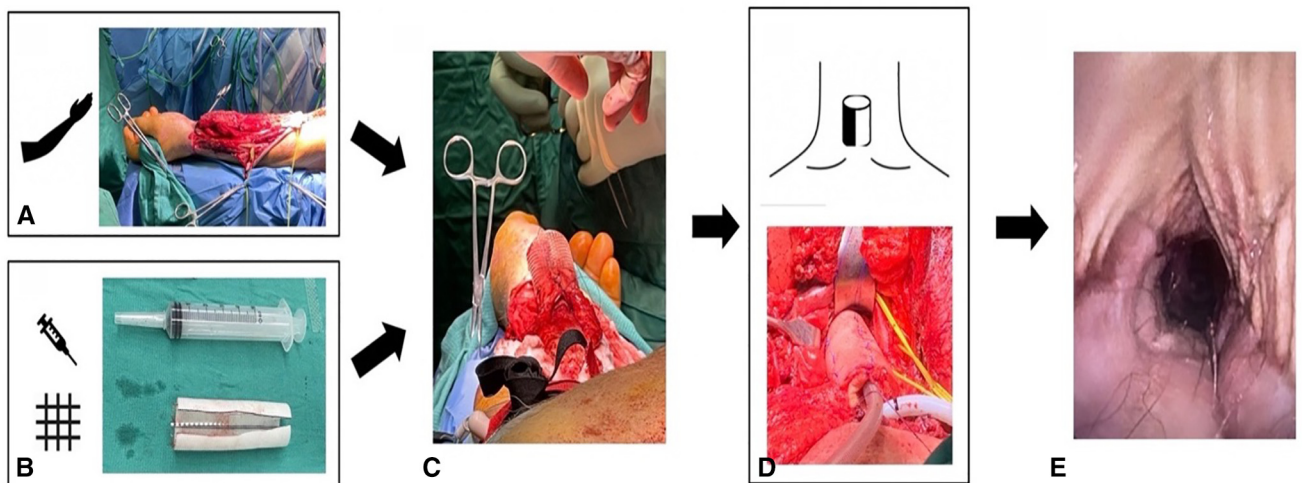


FIGURE 3. Workflow illustration. A, Radial forearm microvascular free flap. B, Large Toomey syringe to act as a mold and the Synthes 0.5-mm graft from DePuy Synthes. C, Wrapping and securing the radial forearm free flap over the splint. D, Insertion of the composite graft into the long-segment tracheal defect. E, Image via bronchoscopy of patient’s tracheal reconstruction 15 months’ postoperation.

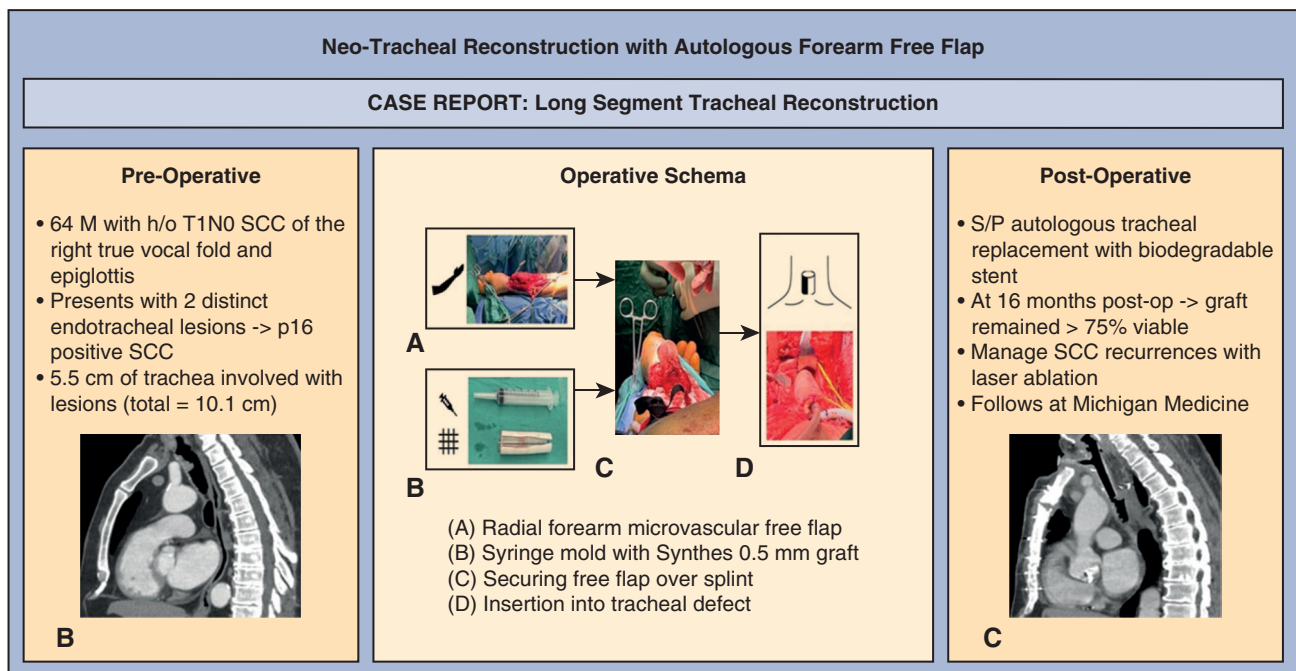


FIGURE 4. Visual abstract of the preoperative, operative, and postoperative schema. SCC, Squamous cell carcinoma; S/P, status post.

tracheostomy tube due to diffuse recurrence in the lower airway while on palliative systemic therapy. At 16 months postoperatively, his composite graft remained over 75% viable. There was appreciable subglottic collapse suprastomally but good distal patency of the reconstruction. The new airway squamous cell carcinoma recurrences have been managed with laser ablation every 3 to 4 months (Figure 4).

Per our institution, institutional review board approval is not required for a case report. Informed consent was not obtained from the patient, as any patient identifiers were removed.

DISCUSSION

Long-segment tracheal reconstructions remain a technically complex surgical challenge. A functional tracheal substitute needs to be both rigid to create a patent lumen but also be flexible and elastic to function as an airway.⁴ Furthermore, it needs to be able to withstand adjuvant radiation treatment if required.

A systematic review by Grillo and Mathisen² compared tracheal replacement modalities and highlighted that patients do not need a maintained ciliated epithelium if they can produce a sufficient cough for secretion clearance. This finding paved the way for the potential viability of composite grafts. Autologous flaps supported by synthetic, biocompatible material can mimic the native tracheal cartilaginous shape.¹

We thus present an example of an autologous tracheal replacement with a biodegradable stent as a possible

treatment modality for a patient with squamous cell carcinoma previously considered inoperable. While there are significant limitations in this surgery and outcomes for this case, given the patient's disease recurrence, our reconstruction method demonstrates a degree of success.

CONCLUSIONS

An autologous composite graft composed of a microvascular free flap and an external splint may be suitable for long-segment tracheal reconstructions.

References

1. Etienne H, Fabre D, Gomez Caro A, Kolb F, Mussot S, Mercier O, et al. Tracheal replacement. *Eur Respir J*. 2018;51:1702211. <https://doi.org/10.1183/13993003.02211-2017>
2. Grillo HC, Mathisen DJ. Primary tracheal tumors: treatment and results. *Ann Thorac Surg*. 1990;49:69-77. [https://doi.org/10.1016/0003-4975\(90\)90358-d](https://doi.org/10.1016/0003-4975(90)90358-d)
3. Grillo HC. Tracheal replacement: a critical review. *Ann Thorac Surg*. 2002;73:1995-2004. [https://doi.org/10.1016/s0003-4975\(02\)03564-6](https://doi.org/10.1016/s0003-4975(02)03564-6)
4. Maciejewski A, Szymczyk C, Póltorak S, Grajek M. Tracheal reconstruction with the use of radial forearm free flap combined with biodegradable mesh suspension. *Ann Thorac Surg*. 2009;87:608-10. <https://doi.org/10.1016/j.athoracsur.2008.06.062>
5. Yu P, Clayman GL, Walsh GL. Human tracheal reconstruction with a composite radial forearm free flap and prosthesis. *Ann Thorac Surg*. 2006;81:714-6. <https://doi.org/10.1016/j.athoracsur.2004.12.009>