

Keratinocyte dissociation (desmolysis/acantholysis) in ameloblastoma

Sachin C. Sarode,¹ Gargi S. Sarode,¹ Praveen Birur,² Yaser A. Alhazmi,³ Shankargouda Patil³

¹Department of Oral Pathology and Microbiology, Dr. D.Y. Patil Dental College and Hospital, Dr. D.Y. Patil Vidyapeeth, Sant-Tukaram Nagar, Pimpri, Pune, MH, India; ²Department of Oral Medicine and Radiology, KLE's Institute of Dental Sciences, Bangalore, India; ³Department of Maxillofacial Surgery and Diagnostic Sciences, Division of Oral Pathology, College of Dentistry, Jazan University, Jazan, Saudi Arabia

Abstract

Ameloblastoma is the only odontogenic tumor that displays diversified histomorphological features with subtypes like follicular, plexiform, acanthomatous, granular cell, clear cell, desmoplastic etc. In this paper we presented an extremely unusual presentation of ameloblastoma, which is characterized by desmolysis or acantholysis of stellate reticulum-like cells caused due to keratinocyte dissociation. A 35-year-old male patient presented with a painless hard 3×3 cm swelling in the mandibular right posterior region in the past 4-5 months. Radiographic examination revealed a multi-locular radiolucent lesion in the body of mandible with resorption of the roots. Histopathological examination revealed ameloblastic follicles with central cells showing keratinocyte dissociation leading to desmolysis/acantholysis. Desmolytic cells were seen as an isolated entity in the follicular space with round to polygonal shaped morphology. Future retrospective studies on archival samples of ameloblastoma are recommended to relook into identification of such rare phenomenon. This will help in better understanding of the incidence rate and biological behavior of this rare variant of ameloblastoma.

Introduction

Ameloblastoma is one of the most common benign odontogenic neoplasms of epithelial origin. It is considered as locally aggressive and often managed with the sur-

gical excision.¹ Based on the clinico-pathological features, there are four main subtypes of ameloblastoma; conventional, unicystic, extraosseous or peripheral and metastasizing ameloblastoma.² It is the only odontogenic tumor that displays diversified histomorphological features and hence, has many histopathological subtypes like follicular, plexiform, acanthomatous, granular cell, clear cell, desmoplastic *etc.*³ Combination of the above histopathological features could be present in the form of hybrid ameloblastoma.⁴ Some rare variants reported in the literature are hemangiopericytoma⁵ and papilliferous keratameloblastoma.⁶ For most of the histopathological subtypes of ameloblastoma, clinical and radiological features are usually similar in nature, which includes mandibular posterior location, painless expansion of cortical plates and multi-locular radiographic appearance.¹ However, desmoplastic ameloblastoma is an exception to this finding as it most commonly occurs in the maxillary anterior region and shows mixed radio-opaque and radio-lucent appearance.⁷

In the present paper we reported an extremely unusual presentation of ameloblastoma, which is characterized by desmolysis or acantholysis of central stellate reticulum like cells.

Case Report

A 35-year-old male patient visited to the outpatient department with chief complaint of painless hard swelling in the mandibular right posterior region since 4-5 months. There was no history of trauma or any discharge from the lesion. The medical and dental history was unremarkable. The swelling was gradually increasing in size to reach the present size of 3×3 cm. Radiographic examination revealed a multi-locular radiolucent lesion extending from distal surface of right mandibular first molar to retro-molar region (Figure 1). Radiolucency extended up to the lower border of the mandible. Each locules were well-demarcated with the radio-opaque septas. Root resorptions were present in the first, second and third molar. Based on the clinico-pathological observations a diagnosis of ameloblastoma and differential diagnosis of odontogenic keratocyst and central giant cell granuloma was made. Aspiration of the lesion does not yield any material thus ruling out cystic and vascular lesions. Intra-oral incisional biopsy was performed by creating small window on buccal aspect of the body of the mandible.

Histopathological examination of spec-

Correspondence: Sachin C. Sarode, Department of Oral Pathology and Microbiology, Dr. D.Y. Patil Dental College and Hospital, Dr. D.Y. Patil Vidyapeeth, Sant-Tukaram Nagar, Pimpri, Pune 411018, India. E-mail: drsachinsarode@gmail.com

Key words: Ameloblastoma; odontogenic tumor; jaw tumor; desmolysis; acantholysis.

Conflict of interest: the authors declare no potential conflict of interests.

Received for publication: 18 April 2020.

Revision received: 26 April 2020.

Accepted for publication: 18 May 2020.

This work is licensed under a Creative Commons Attribution NonCommercial 4.0 License (CC BY-NC 4.0).

©Copyright: the Author(s), 2020

Licensee PAGEPress, Italy

Clinics and Practice 2020; 10:1255

doi:10.4081/cp.2020.1255

imen revealed large ameloblastomatous follicular spaces with peripheral columnar/cuboidal cells and central stellate reticulum like cells. At few places central stellate reticulum like cell displayed squamoid morphology suggesting acanthomatous change. In most of the areas, central cells were separated from each other due to keratinocyte dissociation leading to desmolysis/acantholysis (Figure 2A and C). Desmolytic cells were seen as an isolated entity in the follicular space with round to polygonal shaped morphology (Figure 2B and D). The ameloblastic follicles were also characterized by numerous clear spaces caused due to acantholysis. This appearance was seen throughout the section. Intriguingly, we also observed dense bundle of collagen fibers with hyalinization in the stroma tissue (Figure 2D). However, absence of kite or animal like configurations of the ameloblastomatous epithelium ruled out the possibility of desmoplastic ameloblastoma.⁷ The final diagnosis of follicular ameloblastoma (desmolytic or acantholytic variant) was made and patient was posted for the surgical excision but we lost the follow up with the patient.

Discussion and Conclusions

Ameloblastoma is known for the histomorphological diversity that leads to various histopathological subtypes.² These subtypes mainly show metaplastic changes in the morphological pattern of central cells

leading to acanthomatous (squamous metaplasia), granular cell, clear cell, basal cell, *etc.*⁸ Sometimes the stromal changes can also produce different subtype of ameloblastomas, which includes desmoplastic and hemangioameloblastoma.^{4,5} In the present case, keratinocyte dissociation (desmolysis or acantholysis) was present in the central stellate reticulum like cells, which is first of its kind presentation in the literature.

Distinction of ameloblastoma into a particular histopathological type is of paramount importance as it determines the aggressive behavior as well as guides the management.⁹ In this regard, desmoplastic ameloblastoma and granular cell ameloblastoma were considered as the most aggressive subtypes due to their high rate of recurrence.^{10,11} In the present case, we reported an extensive desmolysis or acantholysis of the central stellate shaped cells of ameloblastic follicles and hence labeled this entity as a desmolytic/acantholytic ameloblastoma. As it is first of its kind reported in the literature, it is very difficult to comment on the biological behavior of this unique subtype of ameloblastoma. Hence, future prospective studies are recommended to better understand the biological behavior.

The present case was present at the mandibular posterior region with painless swelling and expansion of the cortical plates. Radiographic examination revealed multi-locular lesion with resorption of the mandibular molar roots. All these features are very characteristics of ameloblastoma except desmoplastic ameloblastoma, which mainly occurs at maxillary anterior region with mixed radiolucent and radiopaque appearance.¹¹ Based on the present case, which is first of its kind, it will be premature to comment on the uniqueness of the clinical and radiological feature.

It is very difficult to comment on the exact reason for such unique histomorphological appearance. Acantholysis and desmolysis of epithelial cells is the characteristic features seen in the pemphigus and pemphigus-like lesions where the destruction of desmosomal junction takes place due to formation of auto-antibodies against the desmoglein 1 and 3, which are the cell adhesion molecules found in desmosomes.¹² Since ameloblastic follicles are epithelial in origin and also possesses desmosomal junctions, the possibility of breakdown of desmosomal junctions in a stellate reticulum like cells by similar or any other unknown mechanism cannot be underestimated. Hence, future studies are warranted in this direction to authenticate the proposed hypothesis.

Artifact related desmolysis or acanthol-

ysis of the skin or oral epithelium is rarely seen histopathological phenomenon. Tissues fixed in a diluted formalin concentration, saline or water produced prominent acantholysis of the superficial epithelium

with attachment of basal cell layer to the underlying basement membrane. Histopathologically, this artifact looks exactly similar to the pemphigus and Darier's disease.¹³ In the present case, possibility of fix-

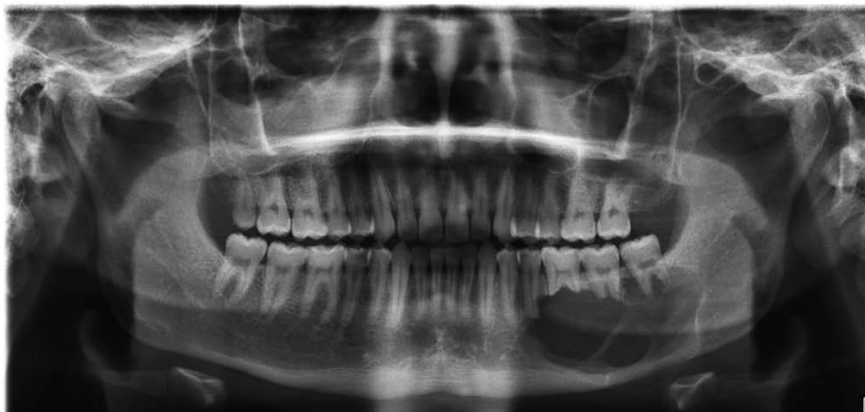

Figure 1. Panoramic radiograph showing multi-locular lesion in the mandibular posterior region.

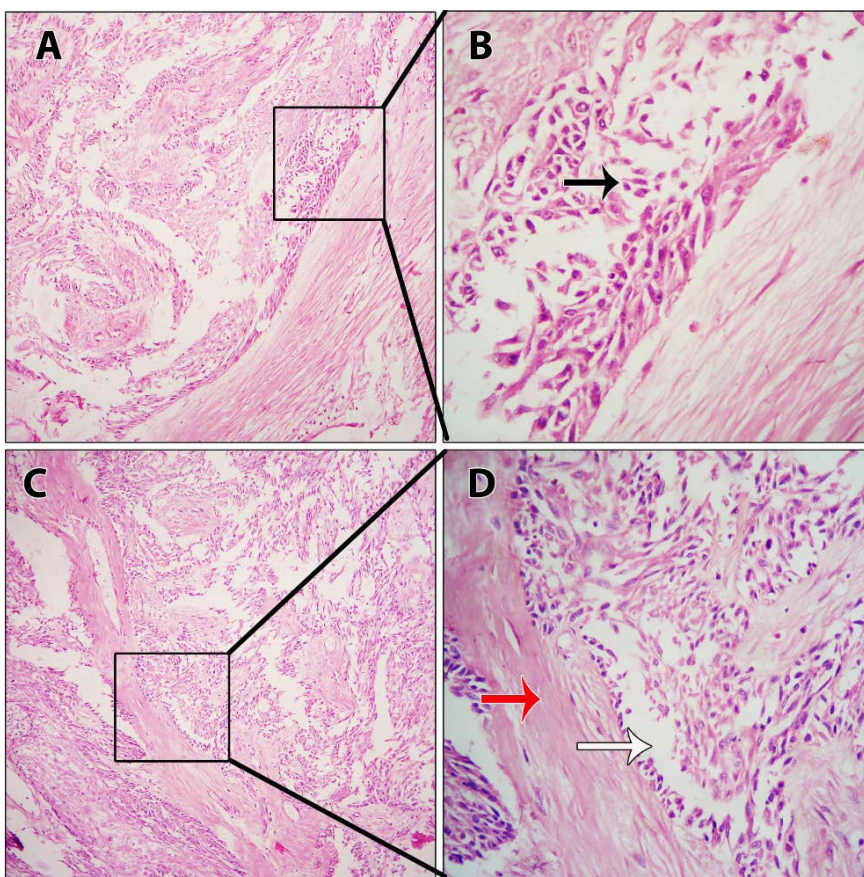


Figure 2. Photomicrograph showing microscopic features of acantholytic/desmolytic ameloblastoma. Scanner view (40×) shows ameloblastomatous proliferation of odontogenic epithelium with numerous clear spaces (A and C). High power magnification (400×) displays numerous acantholytic cells (black arrow) and clear spaces (white arrow) in the ameloblastic follicle and desmoplasia (red arrow) in the stroma (B and D). (Hematoxylin and eosin stain).

ation artifact in acantholytic or desmolytic appearance of central cell of the follicle is quite possible. But, biopsy specimen was received and fixed in 10% neutral buffered formalin and hence it rules out possibility of fixation artifact. Moreover, other stromal tissue elements such as fibroblasts, collagen bundles, blood vessels, *etc.* were devoid of any artifact related changes.

Histopathological diagnosis of ameloblastoma is very straightforward due to its typical and pathognomonic features. Hence, there could be a possibility of overlooking this unique finding during routine diagnosis of ameloblastoma by the pathologists. This could be one of the reasons why it was not reported previously. Hence, retrospective studies on the archival samples are warranted to understand the incidence, demographics and clinico-pathological features of this rare phenomenon. This will help in labeling this unique phenomenon as distinguished histopathological subtype of ameloblastoma.

In conclusion, we reported a very unique histopathological presentation of follicular ameloblastoma in the form of desmolysis/acantholysis. Future retrospective studies on archival samples are recommended to identify such presentation in ameloblastoma. This will help in better understanding of the true incidence and bio-

logical behavior of this rare variant of ameloblastoma.

References

1. Reichart PA, Philipsen HP, Sciubba JJ. The new classification of Head and Neck Tumours (WHO)--any changes?. *Oral Oncol* 2006;42:757-8.
2. Wright JM, Vered M. Update from the 4th edition of the World Health Organization classification of head and neck tumours: odontogenic and maxillofacial bone tumors. *Head Neck Pathol* 2017;11:68-77.
3. Effiom OA, Ogundana OM, Akinshipo AO, Akintoye SO. Ameloblastoma: current etiopathological concepts and management. *Oral Dis* 2018;24:307-16.
4. Philipsen HP, Reichart PA, Takata T. Desmoplastic ameloblastoma (including "hybrid" lesion of ameloblastoma). Biological profile based on 100 cases from the literature and own files. *Oral Oncol* 2001;37:455-60.
5. Sarode GS, Sarode SC, Vaidya K. Intraluminal plexiform hemangioameloblastomatous proliferation in unicystic ameloblastoma: an unusual case report. *Indian J Dent Res* 2013;24: 390-2.
6. Altini M, Slabbert HD, Johnston T. Papilliferous keratoameloblastoma. *J Oral Pathol Med* 1991;20:46-8.
7. Sun ZJ, Wu YR, Cheng N, et al. Desmoplastic ameloblastoma - A review. *Oral Oncol* 2009;45:752-9.
8. Effiom OA, Ogundana OM, Akinshipo AO, Akintoye SO. Ameloblastoma: current etiopathological concepts and management. *Oral Dis* 2018;24:307-16.
9. McClary AC, West RB, McClary AC, et al. Ameloblastoma: a clinical review and trends in management. *Eur Arch Otorhinolaryngol* 2016;273:1649-61.
10. Pinheiro JJ, Freitas VM, Moretti AI, et al. Local invasiveness of ameloblastoma. Role played by matrix metalloproteinases and proliferative activity. *Histopathology* 2004;45:65-72.
11. Anand R, Sarode GS, Sarode SC, et al. Clinicopathological characteristics of desmoplastic ameloblastoma: A systematic review. *J Investig Clin Dent* 2018;9: 10.1111/jicd.12282.
12. Kasperkiewicz M, Ellebrecht CT, Takahashi H, et al. Pemphigus. *Nat Rev Dis Primers* 2017;3:17026.
13. Chatterjee S. Artefacts in histopathology. *J Oral Maxillofac Pathol* 2014;18: S111-6.