

# Serum midkine is a more sensitive predictor for hepatocellular carcinoma than Dickkopf-1 and alpha-L-fucosidase in cirrhotic HCV patients

Ayman F. El-Shayeb, MD<sup>a,b</sup>, Nihal M. El-Habachi, MD<sup>b,c</sup>, Amal R. Mansour, MD<sup>c,d</sup>,  
Mariam S. Zaghloul, MD<sup>e,\*</sup>

## Abstract

Alpha fetoprotein (AFP) level is the gold standard diagnostic tool for detection and monitoring hepatocellular carcinoma (HCC) but with low sensitivity. Thus, the identification of alternative or combined serum markers of HCC is highly needed. Therefore, the aim of this work was to verify the value of serum midkine (MDK), Dickkopf-related protein 1 (DKK1), and alpha-L-fucosidase (AFU) in detection of HCC.

We recruited 244 subjects to the present study; 89 with liver cirrhosis, 86 cirrhotic hepatitis C virus (HCV) induced HCC, and 69 apparently healthy volunteers as controls. Serum AFP, MDK, DKK1, and AFU were measured by ELISA.

Patients with HCC showed significantly higher serum MDK, DKK1, and AFU levels compared with those patients with liver cirrhosis and healthy controls ( $X^2 = 179.56, 153.94, \text{ and } 90.07$  respectively) ( $P < .001$  in all). In HCC cases, neither of MDK, DKK1, or AFU was correlated with tumor number. On the other hand, only serum DKK1 was significantly higher in lesions  $>5$  cm, those with portal vein thrombosis and advanced HCC stage. Receiver operator characteristic (ROC) curve analysis showed that serum MDK levels discriminated between cirrhosis and HCC at a sensitivity of 100%, a specificity of 90% at cut-off value of  $>5.1$  ng/mL.

Although our results showed that serum MDK, DKK-1, and AFU are increased in HCC cases only MDK may be considered as the most promising serological marker for the prediction of the development of HCC in cirrhotic HCV patients.

**Abbreviations:** AFP = alpha fetoprotein, AFU = alpha-L-fucosidase, DKK1 = Dickkopf-related protein 1, HCC = hepatocellular carcinoma, IQR = interquartile range, MDK = midkine, ROC = receiver operator characteristic, WNT/B = wingless related integration site.

**Keywords:** alpha-L-fucosidase, biological markers of hepatocellular carcinoma, chronic hepatitis C, Dickkopf-related protein 1, hepatocellular carcinoma, liver cirrhosis, midkine, serum midkine

## Key Points

- No single biomarker was found to have optimal performance for diagnosis of HCC.
- Serum MDK, DKK-1, and AFU are increased in HCC cases and they could complement each other and improve the early diagnostic rate.

- MDK alone may be considered as the most promising serological marker for the prediction of the development of HCC in cirrhotic HCV patients.

Editor: Chun Gao.

**Ethics approval and consent to participate:** All patients and healthy controls who participated in the present study signed an informed consent form. The study protocol was approved by the Ethics Committee of the Faculty of Medicine, Alexandria University, Egypt and is in accordance with the Helsinki Declaration of 1975.

**Availability of data and materials:** The data that support the findings of this study are available from [Alexandria clinical research center (ACRC)] but restrictions apply to the availability of these data, which were used under license for the current study, and so are not publicly available. Data are however available from the authors upon reasonable request and with permission of [ACRC].

This study was supported by a research grant from the Science and Technology Development Fund (STDF), Egypt (Grant No. 5215) to Professor Dr. Nihal ELHabachi. The authors have no conflicts of interest to disclose.

The datasets generated during and/or analyzed during the current study are available from the corresponding author on reasonable request.

<sup>a</sup>Department of Tropical Medicine, <sup>b</sup>Alexandria Clinical Research Center, <sup>c</sup>Department of Physiology, <sup>d</sup>Department of Clinical Pathology, Faculty of Medicine, Alexandria University, Alexandria, <sup>e</sup>Hepatology, Gastroenterology and Infectious Diseases Department, Faculty of Medicine, Kafrelsheikh University, Kafrelsheikh, Egypt.

\*Correspondence: Mariam S. Zaghloul, Hepatology, Gastroenterology and Infectious Diseases Department, Faculty of Medicine, ElGeish street, 33565, Kafrelsheikh University, Kafrelsheikh, Egypt (e-mail: mariam\_zaghloul@med.kfs.edu.eg)

Copyright © 2021 the Author(s). Published by Wolters Kluwer Health, Inc.

This is an open access article distributed under the terms of the Creative Commons Attribution-Non Commercial License 4.0 (CCBY-NC), where it is permissible to download, share, remix, transform, and buildup the work provided it is properly cited. The work cannot be used commercially without permission from the journal.

**How to cite this article:** El-Shayeb AF, El-Habachi NM, Mansour AR, Zaghloul MS. Serum midkine is a more sensitive predictor for hepatocellular carcinoma than Dickkopf-1 and alpha-L-fucosidase in cirrhotic HCV patients. *Medicine* 2021;100:17(e25112).

Received: 15 October 2020 / Received in final form: 16 February 2021 / Accepted: 18 February 2021

<http://dx.doi.org/10.1097/MD.00000000000025112>

## 1. Introduction

Hepatocellular carcinoma (HCC) is the fourth most common cancer and third leading cause of cancer death worldwide.<sup>[1]</sup> It has been recognized that liver cirrhosis is the most common risk factor for the development of HCC as about 80% of HCC develop in cirrhotic liver.<sup>[2]</sup>

Egypt has high prevalence of hepatitis C virus (HCV) antibody of about 10.0%, and active viraemia HCV RNA of 7.0% according to the last Egyptian Demographic Health Survey.<sup>[3]</sup> Hence the remarkable high incidence of HCV related HCC in Egypt as demonstrated in several center studies.<sup>[4,5]</sup>

The diagnosis of HCC patients is difficult particularly in the early disease development hence alphafetoprotein (AFP) which is widely used as a diagnostic biomarker has a suboptimal performance.<sup>[6]</sup>

Midkine (MDK) is a heparin-binding secreted growth factor protein of a highly regulated gene family which has a pivotal role in cell growth and angiogenesis.<sup>[7]</sup> Over expression of MDK was observed in various human malignancies including HCC at both mRNA and protein level.<sup>[8]</sup>

Wingless related integration site (WNT/B catenin pathway) plays an important role in cellular homeostasis<sup>[9]</sup> and interruption of which may result in developmental abnormalities and diseases particularly cancers.<sup>[10]</sup> Secreted WNT antagonists play a role in regulation of WNT/ B catenin, of these antagonists are the Dickkopf (DKK) proteins' family.<sup>[11]</sup>

DKK-1 block the interaction between the secreted WNT ligands and the low-density lipoprotein receptor related protein 5/6 resulting in B catenin degradation.<sup>[12]</sup> The oncogenic role of DKK-1 as well as its prognostic value in cancer outcome was highlighted by several studies.<sup>[13]</sup>

Serum alpha-L-fucosidase (AFU) is one of the liposomal enzymes that is widely present in tissues and body fluid. AFU is engaged in the breakdown of fucose containing glycoconjugates.<sup>[14]</sup> Several studies have revealed increases serum levels of AFU in patients with HCC.<sup>[15]</sup>

Therefore, the combined use of these promising biomarkers would aid early accurate diagnosis. Our study aimed to verify the value of serum MDK, DKK1, and AFU in detection of HCC development in cirrhotic HCV patients.

## 2. Patients and methods

This observational cross-sectional study was performed in 175 patients; 89 patients were cirrhotic HCV patients without HCC (group I) and 86 cirrhotic HCV patients with HCC (group II). Besides, 69 apparently healthy volunteers were included as a control group (group III), who were presenting to the outpatient clinic or the inpatient ward of the main University hospital between March 2016 and February 2017. Figure 1.

**Inclusion criteria:** Inclusion of patients with these criteria; HCV positive proven by PCR, age: 18 to 65 years, any sex, possibility of continuous communication during the study period. Ultrasound (US) (for all patients) and Triphasic CT examination was performed for those with US proven hepatic focal lesion to define HCC patients.

**Exclusion criteria:** Patients with these conditions were excluded from the study: Chronic diseases, for example, chronic hepatitis B virus (HBV) infection, diabetes, renal failure, and patients with other malignancies. Patients who fail to sign the informed consent were excluded.

All patients and controls were subjected to proper and detailed history taking and thorough clinical examination. After

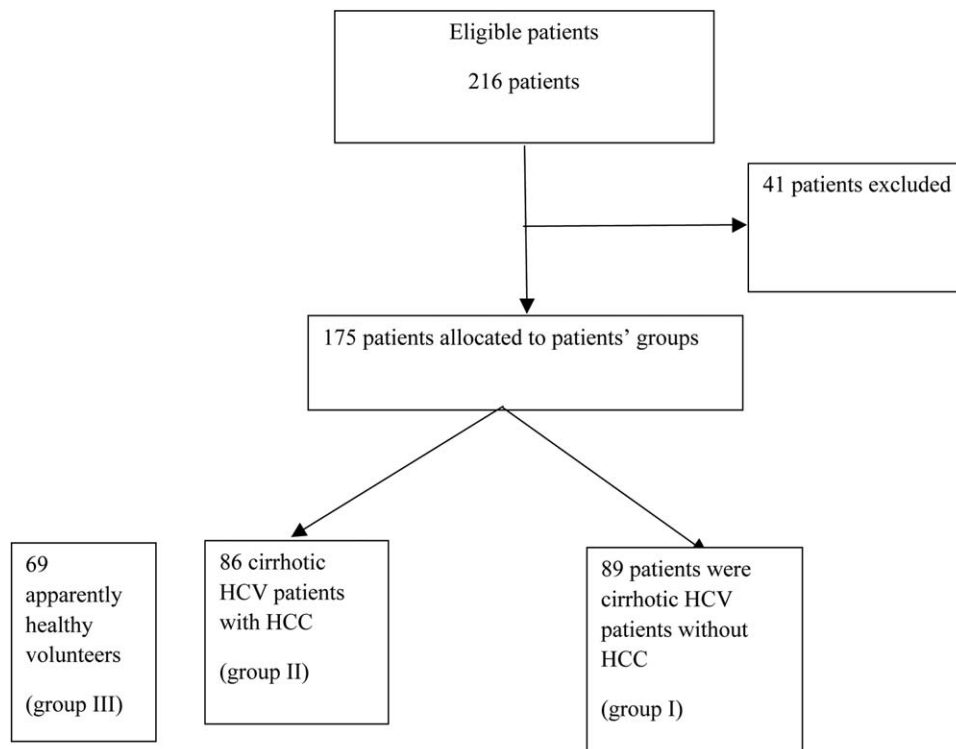


Figure 1. Flow chart of patients.

overnight fasting, blood sampling of 10 mL and the sample was derived into 2 halves; 5 mL for routine laboratory investigation<sup>[16]</sup>; CBC, liver function tests (AST, ALT, total bilirubin, total protein and albumin, prothrombin time and activity, and AFP) and renal function tests, viral markers for hepatitis B (HBs Ag) and hepatitis C (anti-HCV) by ELISA, and PCR for HCV-RNA.<sup>[17]</sup>

The other 5 mL were centrifuged, and separate aliquots of serum were frozen at -80°C for the time of analysis of serum Midkine by a commercially available enzyme-linked immunosorbent assay kit (Human Midkine PicoKine ELISA Kit [Boster Biological Technology, Pleasanton CA, Catalog # EK1235]), serum DKK1 by using a commercially available enzyme-linked immunosorbent assay kit (Human DKK-1 PicoKine ELISA Kit [Boster Biological Technology, Pleasanton CA, Catalog # EK0867]), and serum AFU by a commercially available enzyme-linked immunosorbent assay kit (Human Tissue alpha-L-fucosidase, ELISA Kit [EIAab www.eiaab.com, Catalog No: E0807h]).

**2.1. Ethical approval**

All patients and healthy controls who participated in the present study signed an informed consent form. The study protocol was approved by the Ethics Committee of the Faculty of Medicine and is in accordance with the Helsinki Declaration of 1975.

**2.2. Statistical methods**

Differences between groups were analyzed with the unpaired *t* test or the Mann-Whitney *U* test, where appropriate. Results were expressed as median and interquartile range (IQR) and were analyzed by using the Independent-samples Kruskal-Wallis test. To assess the accuracy of the diagnostic tests, the matched data sets (chronic liver diseases patients and HCC patients) regarding

AFP, MDK, DKK1, and AFU were analyzed by using receiver operator characteristic (ROC) curve analysis. All statistical procedures were performed using SPSS software, version 20 for Windows (IBM Corp. Released 2011. IBM SPSS Statistics for Windows, Version 20.0. Armonk, NY: IBM Corp.).

**3. Results**

The clinical and demographic data of the 3 studied groups are shown in Table 1. The mean age of HCC patients was significantly higher than those with liver cirrhosis and controls (*P* = .00 and .01 respectively). In addition, patients with HCC had statistically significant lower platelet count than those with liver cirrhosis and controls (*P* < .001 in both).

**3.1. Serum AFP, MDK, DKK1, and AFU**

Serum AFP was significantly higher in group II than in groups I and III (*Z* = -6.41 and -8.81 respectively) (*P* = .00 and .00 respectively). Also, serum AFP was significantly higher in group I than in group III (*Z* = -5.77) (*P* = .00) Table 2.

Serum MDK was significantly higher in group II than in groups I and III (*Z* = 10.38, 10.58) (*P* = .00) and in group I than in group III (*Z* = 3.12 and *P* = .00).

Also, DKK-1 was significantly higher in HCC cases compared with cirrhotic and controls (*Z* = 9.66, 10.55) (*P* = .00). Moreover, it was significantly higher in cirrhotic patients than controls (*Z* = 9.20) (*P* = .00) Table 2.

As regards AFU, it was significantly higher in group II than in groups I and III (*Z* = 2.75, 8.99) (*P* = .00) and in group I than in group III (*Z* = 7.15 and *P* = .00) Table 2.

In group II (HCC patients), multiple lesions were found in 53 patients and 33 patients presented with single focal lesion. Early HCC cases were 41 (BCLC A+B) while late HCC cases were 45 (BCLC C+D). Portal vein thrombosis was present in 12 patients

**Table 1**  
The clinical and demographic data of the 3 studied groups.

Variable	Group I liver cirrhosis (n=89)	Group II HCC (n=86)	Group III healthy (n=69)	<i>P</i> <sup>*</sup>	Significance between groups
Age, y	52 (47-60)	59 (55-62)	50 (46-55)	<.001	I-II/I-III
ALT, U/L	39 (27-54.5)	42.5 (25-74.5)	26 (24-45)	.002	I-III/I-III
AST, U/L	59 (42-83)	68.5 (45.75-92)	24 (19-54)	.003	I-III/I-III
Albumin, g/dL	2.7 (2.1-3.2)	2.7 (2.1-3.3)	3.8 (3.5-5)	<.001	I-II/I-III
Total bilirubin, mg/dL	1.7 (1.1-2.4)	1.5 (1-3.4)	1 (0.5-1.2)	.035	I-II/I-III
Platelet count (×10 <sup>9</sup> L <sup>-1</sup> )	111.5 (71-143)	76 (55-124)	180 (152-250)	<.001	I-II/I-III/I-III
Child class (A/B/C)	21/41/27	26/32/28			
BCLC classification (A/B/C/D)		7/34/12/33			

Data are given as median (IQR). Reference intervals are given in parentheses. HCC=hepatocellular carcinoma.  
\* Significant at *P* ≤ .05.

**Table 2**  
Serum AFP, MDK, DKK1, and AFU in the 3 studied groups.

Variable	Group I liver cirrhosis (n=89)	Group II HCC (n=86)	Group III healthy (n=69)	<i>χ</i> <sup>2</sup>	<i>P</i> <sup>*</sup>	Significance between groups
AFP, ng/mL Median (IQR)	8.8 (2.9-30)	108.3 (11.75-516.67)	2.6 (0.8-5.3)	98.5	.00*	All
MDK, ng/mL Median (IQR)	1.96 (1.08-2.8)	12.23 (9.38-21.44)	1.1 (1.09-2.77)	153.94	.00*	All
DKK1, ng/mL	1.82 (1.46-3.42)	7.58 (3.42-20.68)	0.72 (0.48-0.88)	179.56	.00*	All
AFU, U/L Median (IQR)	0.38 (0.25-1.35)	0.67 (0.37-1.87)	0.23 (0.21-0.26)	90.07	.00*	All

Data are given as median (IQR). Reference intervals are given in parentheses. AFP=alpha fetoprotein, AFU=alpha-L-fucosidase, DKK1=Dickkopf-related protein 1, HCC=hepatocellular carcinoma, MDK=midkine  
\* Significant at *P* ≤ .05.

**Table 3**  
Sensitivity, specificity, PPV, NPV, and accuracy of the studied parameters for prediction of HCC.

	AUC	CI 95%	Cutoff	Sensitivity	Specificity	PPV	NPV	Accuracy
AFP, ng/mL	0.83	0.73–0.89	10	78%	45%	61.5%	71.2%	65.14%
Midkine, ng/mL	0.95	0.95–0.99	5.1	100%	90%	89%	100%	94%
DKK-1, ng/mL	0.92	0.93–0.97	2.3	89%	80%	80.2%	88.6%	84%
AFU, U/L	0.62	0.69–0.81	0.37	74%	50%	58.33%	65.67%	61.1%

AFP = alpha fetoprotein, AFU = alpha-L-fucosidase, AUC = area under the curve, CI = confidence interval, DKK1 = Dickkopf-related protein 1, HCC = hepatocellular carcinoma, NPV = negative predictive value, PPV = positive predictive value.

and absent in 74 patients. Lesions >5 cm were observed in 36 patients while 50 patients had lesions <5 cm.

Serum MDK was higher in patients with multiple focal lesions, lesions >5 cm and those with portal vein thrombosis (median = 14.43, 12.88, and 16.44 respectively) than in single focal lesion, lesions <5 cm and those without portal vein thrombosis (median = 10.41, 12.18, and 12.1 respectively) but was statistically insignificant ( $Z = 1.00, 0.71, \text{ and } 1.89$ ) ( $P = .31, .47, \text{ and } .06$  respectively).

Furthermore, lesions >5 cm have significantly higher levels of DKK-1 than those <5 cm ( $Z = 3.88$  and  $P = .00$ ). Also, those with portal vein thrombosis have higher levels of DKK-1 than those without it ( $Z = 4.99$  and  $P = .00$ ). DKK-1 levels were significantly higher in advanced HCC stage than in early ones ( $Z = 2.64$  and  $P = .00$ ).

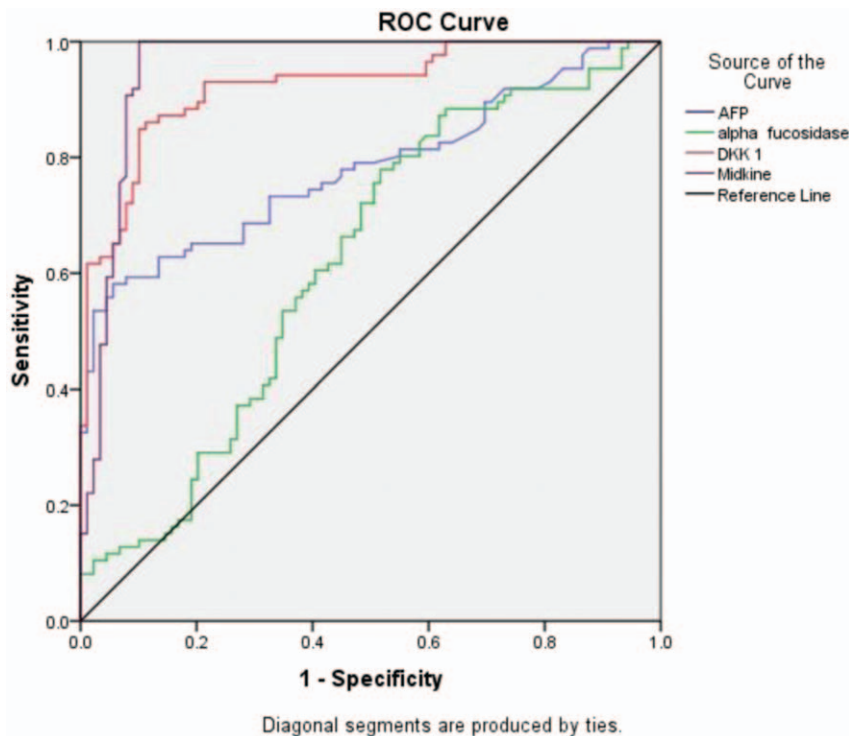
Although serum DKK-1 levels were higher in those with multiple focal lesions than in patients with single lesion but that was statistically insignificant (median 9.37 and 5.98 respectively) ( $Z = 1.86, P = .06$ ).

Regarding AFU, it was observed that serum AFU doesn't have any association with tumor number, size, severity, or portal vein thrombosis.

ROC curve analysis reveals that serum MDK and DKK1 at cut off 5.1 and 2.3 ng/mL respectively showed better performance than AFP at a cut off  $\geq 10$  and AFU at a cut off  $0.37 \mu\text{L}$  in differentiation between HCC patients and those with liver cirrhosis. (Table 3, Fig. 2).

Using 10 ng/mL as a diagnostic cut-off value for AFP, it was positive in 78% of (67/86) HCC patients and negative in 22% (19/86) of them. While in those HCC patients with negative AFP, serum AFU was positive in 15/19 (79%), serum DKK1 was positive in 16/19 (84.2%), and serum MDK was positive in 19/19 (100%).

A logistic regression analysis was performed to ascertain the effects of serum MDK, DKK1, and AFU on the like hood that cirrhotic HCV patients would have HCC. The logistic regression model was statistically significant  $X^2 = 137.45$  and  $P = .000$ . Among the 3 variables tested, only serum MDK and DKK1



**Figure 2.** Receiver-operator characteristics (ROC) curve analyses showing the diagnostic potential of serum AFP, AFU, DKK1, and MDK to detect HCC occurrence. AFP = alpha fetoprotein, AFU = alpha-L-fucosidase, DKK1 = Dickkopf-related protein 1, HCC = hepatocellular carcinoma, MDK = midkine.

significantly predicted HCC development in cirrhotic HCV patients ( $P = .00$  and  $.017$  respectively).

#### 4. Discussion

Serum biomarkers are reliable potential tools for screening and diagnosis of HCC. Meanwhile, no single biomarker was found to have optimal performance for diagnosis of HCC. Therefore, combination of several biomarkers have been shown to complement each other and improve the early diagnostic rate.<sup>[18]</sup>

Evidence that MDK has a significant role in cancer process such as proliferation, anti-apoptosis, and angiogenesis has been documented in many solid tumors, including HCCs.<sup>[19]</sup>

In this study, serum MDK was significantly elevated in patients with HCC compared with those with cirrhosis ( $P < .001$ ).

In addition, ROC curves showed a higher classification power of MDK (93.54% of HCC patients) to detect HCC patients at a cutoff value of 5.1 ng/mL with respect to AFP at a cutoff value of 10 ng/mL (36% of HCC patients). This indicates that serum MDK could be a useful marker with a lower false-positive rate in diagnosing and differentiating HCC from liver cirrhosis.

Our results were in agreement with Zhu et al,<sup>[20]</sup> who showed that serum MDK may serve as a novel diagnostic tumor marker for the detection of HCC, particularly for those with negative AFP and/or at an early stage. However, most of the HCC patients in their study are HBV-related. Similar findings were reported by Hung et al<sup>[21]</sup> and Shaheen et al.<sup>[22]</sup>

MDK was significantly elevated in HCC tissue as well as serum in Zhu et al<sup>[20]</sup> study with AUC of 0.91% and 95% confidence interval (CI) 0.89–0.93 similar to ours 0.95% and 95% CI of 0.92–0.98. In Zhu study,<sup>[20]</sup> 13.2% of patients with liver cirrhosis had elevated serum MDK (false positive) versus 10.11% in our study.

In Shaheen et al,<sup>[22]</sup> serum MDK was higher in HCC patients than in those with liver cirrhosis and controls. Also, out of 40 HCC patients 15 have AFP  $< 20$ , in those 15 patients MDK was higher than cut off 0.387 ng/mL in 14/15. Furthermore, MDK was positive (above the cut off value of in 19/19 cases of HCC with negative AFP) (100%).

A large-scale multicenter study was performed with patients affected by liver diseases including HCC, chronic hepatitis B virus (HBV), or liver cirrhosis to assess whether DKK1 could serve as an alternative biomarker to alpha-fetoprotein (AFP) for HCC diagnosis.<sup>[23]</sup>

Our study revealed significant higher serum DKK-1 levels in HCC patients compared with healthy controls. This was in accordance with previous studies done by Kim et al<sup>[24]</sup> and Bakr et al.<sup>[25]</sup> In addition, several studies reported high expression of DKK-1 in hepatocellular carcinoma.<sup>[26]</sup>

We found a significant elevation of serum DKK-1 levels in cases with lesions  $> 5$  cm compared with smaller one ( $< 5$  cm). This finding was in accordance with Bakr et al<sup>[25]</sup> and Dala et al<sup>[27]</sup> this also was similar in late stage disease and in those with portal vein thrombosis.

Dala et al<sup>[27]</sup> showed that DKK-1 at a cut off value of 1.122 ng/mL had a sensitivity of 80%, specificity of 77.1% with an area under curve of 0.810 and  $P$  value of  $< .001$  while our cut off was 2.3 ng/mL that showed sensitivity of 89%, specificity of 80% with an area under curve of 0.92 and  $P$  value of  $< .001$ .

However, patients with multiple HCC lesions showed no significant difference of DKK-1 levels compared with single lesions. These results were in agreement with previous studies

that showed positive correlation between serum DKK-1 and tumor size  $\geq 5$  cm.<sup>[23,28]</sup>

We have noticed significant increased serum DKK-1 levels in patients with BCLC (C–D) than BCLC (A–B) stages. Similar results were reported by Kim et al,<sup>[24]</sup> and Bakr et al.<sup>[25]</sup>

Moreover, in 31 cases of HCC who have normal AFP, DKK-1 was higher above the cut off value in 28 cases. This also in accordance with Bakr et al<sup>[25]</sup> who reported elevated DKK-1 in all cases with normal AFP. This finding was similar to results of Tao et al<sup>[29]</sup> and Gomceli et al.<sup>[30]</sup>

Also, Mohamed et al,<sup>[31]</sup> in Egyptian patients with HCC found that 17/40 have normal AFP but DKK-1 was above the cut off value. Also, in their study at cut off value of 400 ng/mL AFP (sensitivity 28% and specificity 100%) while ours 100% specificity was associated with 30% sensitivity.

Alpha-L-fucosidase enzyme has been proposed as a marker of HCC.<sup>[32–35]</sup> The results of our study confirm the work of the previously mentioned studies of an increased serum activity of alpha-L-fucosidase enzyme in patients with HCC. The reason for the increase of alpha-L-fucosidase is still unknown. One possible explanation is an increased synthesis of proteins by tumor with a consequent increase in fucose turnover.<sup>[36]</sup>

Our results revealed that AFU was also higher in those with liver cirrhosis than healthy controls which is consistent with the studies that suggested that elevated AFU was not directly derived from tumors.<sup>[37]</sup> El-Houseini et al<sup>[37]</sup> reported that AFU could be used as a diagnostic biomarker of HCC 6 months before detection by ultrasound.

Our study included 60/86 (Child B+C) of HCC cases, high levels of cytokines in advanced cirrhotic disease process could upregulate AFU levels.<sup>[38]</sup>

In AFP negative HCC patients, serum AFU was positive in 15 patients (79%). Similar finding was reported by Wang et al,<sup>[39]</sup> who showed that 17 patients with HCC with negative AFP have higher AFU but the difference between our study and Wang is their cut off value for AFP is  $> 400$  ng/mL while ours was 10 ng/mL.

Our study revealed that AFU sensitivity and specificity were 60.5% and 57.3% for HCC diagnosis which is lower than AFP (64% and 82%). These findings were in accordance with Bukofzer et al,<sup>[32]</sup> who reported less sensitivity and specificity of AFU than AFP. While Zhang et al<sup>[40]</sup> showed the sensitivity of AFU was 72.4% and the specificity was 63.8%.

Alpha-L-fucosidase enzyme showed no relation with the size of the tumor. This finding came in agreement with Takahashi et al<sup>[41]</sup> who found no relationship between alpha-L-fucosidase enzyme activity and tumor size.

This study had its potential limitations. First, the small number of patients, and this was owing to the pilot nature of the study to discover the efficacy of these markers together. Also, our patient cohort did not include hepatocellular carcinoma secondary to other etiologies than HCV. So, larger multicenter studies investigating these markers would help to define the cut off levels and recommend their use as an alternative biomarker for HCC. On the other hand, this was the first study to combine these 3 promising biomarkers.

#### 5. Conclusions

Although our results showed that serum MDK, DKK-1, and AFU are increased in HCC cases only MDK may be considered as the most promising serological marker for the prediction of the development of HCC in cirrhotic HCV patients.

## Acknowledgments

The authors would thank all the nursing staff and laboratory technicians who helped in this work.

## Author contributions

**Conceptualization:** Ayman El-Shayeb.

**Data curation:** Mariam Salah Zaghoul.

**Formal analysis:** Mariam Salah Zaghoul.

**Funding acquisition:** Nihal El-Habachi.

**Investigation:** Amal Mansour.

**Methodology:** Amal Mansour.

**Project administration:** Ayman El-Shayeb, Nihal El-Habachi.

**Software:** Mariam Salah Zaghoul.

**Supervision:** Ayman El-Shayeb.

**Validation:** Mariam Salah Zaghoul.

**Visualization:** Mariam Salah Zaghoul.

**Writing – original draft:** Mariam Salah Zaghoul.

**Writing – review & editing:** Ayman El-Shayeb, Nihal El-Habachi, Amal Mansour.

## References

- Herszenyi L, Tulassay Z. Epidemiology of gastrointestinal and liver tumors. *Eur Rev Med Pharmacol Sci* 2010;14:249–58.
- Shaker MK, Abdella HM, Khalifa MO, et al. Epidemiological characteristics of hepatocellular carcinoma in Egypt: a retrospective analysis of 1313 cases. *Liver Int* 2013;33:1601–6.
- Gomaa A, Allam N, Elsharkway A, et al. Hepatitis C infection in Egypt: prevalence, impact and management strategies. *Hepat Med* 2017;9:17–25.
- Abd-El salam S, Elwan N, Soliman H, et al. Epidemiology of liver cancer in Nile delta over a decade: a single-center study. *South Asian J Cancer* 2018;7:24–6.
- Ziada DH, El Sadany S, Soliman H, et al. Prevalence of hepatocellular carcinoma in chronic hepatitis C patients in Mid Delta, Egypt: a single center study. *J Egypt Natl Canc Inst* 2016;28:257–62.
- Farinati F, Marino D, De Giorgio M, et al. Diagnostic and prognostic role of alpha-fetoprotein in hepatocellular carcinoma: both or neither? *Am J Gastroenterol* 2006;101:524–32.
- Muramatsu T. Midkine and pleiotrophin: two related proteins involved in development, survival, inflammation and tumorigenesis. *J Biochem* 2002;132:359–71.
- Ruan M, Ji T, Wu Z, et al. Evaluation of expression of midkine in oral squamous cell carcinoma and its correlation with tumour angiogenesis. *Int J Oral Maxillofac Surg* 2007;36:159–64.
- Anastas JN, Moon RT. WNT signalling pathways as therapeutic targets in cancer. *Nat Rev Cancer* 2013;13:11–26.
- Clevers H, Nusse R. Wnt/beta-catenin signaling and disease. *Cell* 2012;149:1192–205.
- Niehrs C. Function and biological roles of the Dickkopf family of Wnt modulators. *Oncogene* 2006;25:7469–81.
- Zorn AM. Wnt signalling: antagonistic Dickkopfs. *Curr Biol* 2001;11:R592–5.
- Hall CL, Kang S, MacDougald OA, et al. Role of Wnts in prostate cancer bone metastases. *J Cell Biochem* 2006;97:661–72.
- Johnson SW, Alhadeff JA. Mammalian alpha-L-fucosidases. *Comp Biochem Physiol B* 1991;99:479–88.
- Zhao YJ, Ju Q, Li GC. Tumor markers for hepatocellular carcinoma. *Mol Clin Oncol* 2013;1:593–8.
- Burtis CA, Ashwood ER. *Tietz Fundamentals of Clinical Chemistry*. WB Saunders: Philadelphia, PA; 1996.
- Eddleston ALWF. Viral hepatitis, scientific basis and clinical management. *Gut* 1994;35:1679.
- Tsuchiya N, Sawada Y, Endo I, et al. Biomarkers for the early diagnosis of hepatocellular carcinoma. *World J Gastroenterol* 2015;21:10573–83.
- Choudhuri R, Zhang H-T, Donnini S, et al. An angiogenic role for the neurokines midkine and pleiotrophin in tumorigenesis. *Cancer Res* 1997;57:1814–9.
- Zhu W-W, Guo J-J, Guo L, et al. Evaluation of midkine as a diagnostic serum biomarker in hepatocellular carcinoma. *Clin Cancer Res* 2013;19:3944–54.
- Hung Y-J, Lin ZH, Cheng T-I, et al. Serum midkine as a prognostic biomarker for patients with hepatocellular carcinoma. *Am J Clin Pathol* 2011;136:594–603.
- Shaheen KY, Abdel-Mageed AI, Safwat E, et al. The value of serum midkine level in diagnosis of hepatocellular carcinoma. *Int J Hepatol* 2015;2015:146389.
- Shen Q, Fan J, Yang X-R, et al. Serum DKK1 as a protein biomarker for the diagnosis of hepatocellular carcinoma: a large-scale, multicentre study. *Lancet Oncol* 2012;13:817–26.
- Kim SU, Park JH, Kim H-S, et al. Serum Dickkopf-1 as a biomarker for the diagnosis of hepatocellular carcinoma. *Yonsei Med J* 2015;56:1296–306.
- Bakr HG, Elfarargy OM, Elnaggar AM. Clinical significance of serum Dickkopf-1 (Dkk-1) as a diagnostic marker for hepatocellular carcinoma. *Int J Sci Res* 2016;5.
- Yu B, Yang X, Xu Y, et al. Elevated expression of DKK1 is associated with cytoplasmic/nuclear  $\beta$ -catenin accumulation and poor prognosis in hepatocellular carcinomas. *J Hepatol* 2009;50:948–57.
- Dala A, Badr M, Habib M, et al. Diagnostic value of serum Dickkopf-1 as a predictor of hepatocellular carcinoma in patients with liver cirrhosis. *Menoufia Med J* 2019;32:359–62.
- Tung EKK, Mak CKM, Fatima S, et al. Clinicopathological and prognostic significance of serum and tissue Dickkopf-1 levels in human hepatocellular carcinoma. *Liver Int* 2011;31:1494–504.
- Tao Y-M, Liu Z, Liu H-L. Dickkopf-1 (DKK1) promotes invasion and metastasis of hepatocellular carcinoma. *Dig Liver Dis* 2013;45:251–7.
- Gomceli I, Bostanci EB, Ozer I, et al. A novel screening biomarker in gastric cancer: serum Dickkopf-1. *Hepatogastroenterology* 2012;59:1661–4.
- Mohamed FZ, Barakat LAA, Radwan NH, Khedr MMM. Comparative study between DKK-1 and AFP for diagnosing of hepatocellular carcinoma among egyptian patients. *Eur J Pharma Med Res* 2016;3:8.
- Bukofzer S, Stass P, Kew M, et al. Alpha-L-fucosidase as a serum marker of hepatocellular carcinoma in southern african blacks. *Br J Cancer* 1989;59:417–20.
- Giardina MG, Matarazzo M, Morante R, et al. Serum  $\alpha$ -L-fucosidase activity and early detection of hepatocellular carcinoma. *Cancer* 1998;83:2468–74.
- Ishizuka H, Nakayama T, Matsuoka S, et al. Prediction of the development of hepatocellular carcinoma in patients with liver cirrhosis by the serial determinations of serum alpha-L-fucosidase activity. *Intern Med* 1999;38:927–31.
- Tangkijvanich P, Tosukhowong P, Bunyongyod P, et al. Alpha-L-fucosidase as a serum marker of hepatocellular carcinoma in Thailand. *Southeast Asian J Trop Med Public Health* 1999;30:110–4.
- Deugnier Y, David V, Brissot P, et al. Serum  $\alpha$ -L-fucosidase: a new marker for the diagnosis of primary hepatic carcinoma? *Hepatology* 1984;4:889–92.
- El-Houseini ME, El-Sherbiny M, Awad M, et al. Serum alpha-L-fucosidase enzyme activity as a marker for hepatocellular carcinoma: comparison with AFP using ROC analysis. *J Egypt Natl Cancer Inst* 2001;13:227–83.
- Leonardi GC, Candido S, Cervello M, et al. The tumor microenvironment in hepatocellular carcinoma. *Int J Oncol* 2012;40:1733–47.
- Wang C-C, Iyer SG, Low JK, et al. Perioperative factors affecting long-term outcomes of 473 consecutive patients undergoing hepatectomy for hepatocellular carcinoma. *Ann Surg Oncol* 2009;16:1832–42.
- Zhang S-Y, Lin B-D, Li B-R. Evaluation of the diagnostic value of alpha-L-fucosidase, alpha-fetoprotein and thymidine kinase 1 with ROC and logistic regression for hepatocellular carcinoma. *FEBS Open Bio* 2015;5:240–4.
- Takahashi H, Saibara T, Iwamura S, et al. Serum  $\alpha$ -L-fucosidase activity and tumor size in hepatocellular carcinoma. *Hepatology* 1994;19:1414–7.