

# Intercalated low doses of antimonials for disseminated cutaneous leishmaniasis caused by *Leishmania guyanensis*: A successful approach in Amazonas, Brazil



Aline Grasielli Monçale Campos, MD,<sup>a</sup> Louise Makarem Oliveira, MS,<sup>b</sup> Laísa Ezaguy de Hollanda, MS,<sup>b</sup> Valeska Albuquerque Francesconi do Valle, MD,<sup>a</sup> and Fábio Francesconi do Valle, MD<sup>a</sup>  
Amazonas, Brazil

**Key words:** antimonial; cutaneous leishmaniasis; *Leishmania guyanensis*; low doses; therapy-refractory.

## INTRODUCTION

*Leishmania guyanensis* is the prevailing protozoa responsible for leishmaniasis in the Amazon ecoregion, which encompasses Brazil, Venezuela, Colombia, Peru, Bolivia, Suriname, Ecuador, and British and French Guiana.<sup>1</sup> This species can cause localized, diffuse, or disseminated cutaneous leishmaniasis (CL).<sup>2,3</sup> The lattermost, characterized by the presence of 10 lesions or more in different body parts, is seldom observed. This variant involves lymphatic dissemination, and it is usually associated with other *Leishmania* species, such as *Leishmania braziliensis*, which represents a therapeutic challenge.<sup>3</sup> There are few studies on the treatment of leishmaniasis caused by *L guyanensis*, which leads to poor evidence, fleeting protocols, and a success rate of 50% to 60%. This fact becomes more worrisome when we consider the health of travelers, for the Amazon is one of the main destinations for ecotourism worldwide, and leishmaniasis is one of the dermatoses most frequently associated with tropical countries.<sup>4,5</sup>

## CASE REPORT

In January 2015, a 56-year-old man suffering from therapy-refractory leishmaniasis was referred to our department. He had several cutaneous ulcers with raised borders (Fig 1). Before that date, in November 2014, he had been medicated for 20 days with 15 mg/kg/d of N-methyl glucamine (Glucantime), due to a positive smear of his lesions.

### Abbreviation used:

CL:	cutaneous leishmaniasis
Sb(V):	pentavalent antimonial
Sb(III):	trivalent antimonial

Consequently, we reintroduced the medication—at the same dose—for 30 days.

He returned in March 2015, reporting musculoskeletal pain and asthenia with ulcerated lesions on his trunk. The direct smear test result was still positive, confirming the disease's activity. We hospitalized the patient and administered liposomal amphotericin B for 7 days (7 mg/kg). The clinical manifestations improved; nonetheless, he still presented lesions on his thorax. We performed a biopsy and a polymerase chain reaction test. Although the histopathologic examination of hematoxylin-eosin-stained tissue found a lymphohistiocytic inflammatory infiltrate and *Leishmania* amastigotes within macrophages (Fig 2), the polymerase chain reaction showed *L guyanensis* as the infecting protozoa.

On April 14, we discharged the patient from the hospital and initiated intramuscular pentamidine, considering both the disease's activity and the infecting species. He received 300 mg every 72 hours for 9 days. On January 6, 2016, the disease progressed into the disseminated form, with 12 active lesions (Fig 3) and a positive skin smear. Hence, we introduced Glucantime (5 mg/kg/d). This approach consisted of cycles during which we medicated the

From the Tropical Medicine Foundation Dr. Heitor Vieira Dourado, Department of Dermatology<sup>a</sup> and the Federal University of Amazonas, Academic Medical Center.<sup>b</sup>

Funding sources: None.

Conflicts of interest: None disclosed.

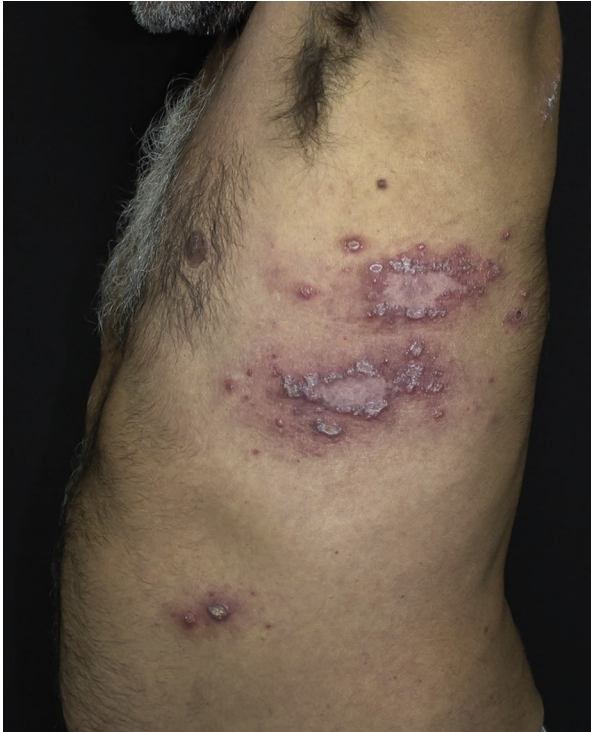Correspondence to: Aline Grasielli Monçale Campos, MD, Pedro Teixeira Av, 725 Manaus, AM, 69040-000. E-mail: [alinemoncale@gmail.com](mailto:alinemoncale@gmail.com).

JAAD Case Reports 2018;4:1045-8.

2352-5126

© 2018 by the American Academy of Dermatology, Inc. Published by Elsevier, Inc. This is an open access article under the CC BY-NC-ND license (<http://creativecommons.org/licenses/by-nc-nd/4.0/>).

<https://doi.org/10.1016/j.jdc.2018.07.014>



**Fig 1.** Multiple erythematous papules and ulcers with raised, erythematous borders located at the left lateral chest of a 56-year-old man.

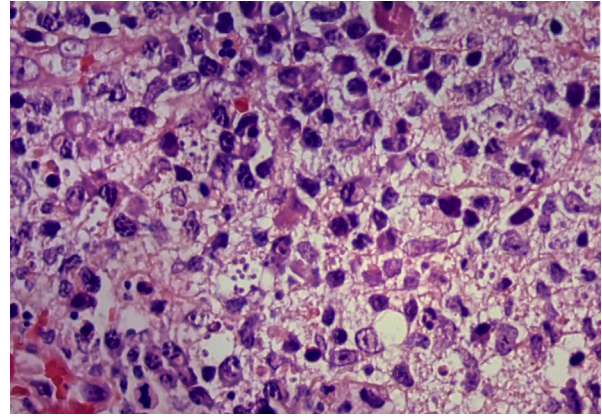
patient with a daily ampoule—405 mg of pentavalent antimonial [Sb(V)]—for 10 days and then interrupted the medication for 7 days. After 3 cycles, we did not observe active lesions. In February, the patient returned with fewer remising patches (Fig 4). In April, he displayed noteworthy improvement, presenting hyperchromic patches on his chest and upper limbs. After 1 year, there was no sign of disease.

## DISCUSSION

We presented the case of a patient with therapy-refractory disseminated CL caused by *L guyanensis* and successfully treated with intercalated low doses of Glucantime (5 mg/kg/d).

Pentamidine is the first-line medication in countries in which *L guyanensis* prevails, and since 2017, this medication has been considered the best option for treating CL caused by *L guyanensis* in Brazil. However, no randomized trial has demonstrated its therapeutic superiority to antimonials, which remain the gold standard for disseminated CL.<sup>6</sup>

Moreover, the Amazon is a convergence area for various *Leishmania*, and although the species respond differently to each medication, antimonials are usually effective. Therefore, we initiated our treatment with Glucantime.



**Fig 2.** Histopathologic examination shows several *Leishmania* amastigotes within macrophages. No special stains were performed. (Hematoxylin-eosin stain; original magnification:  $\times 100$ .)

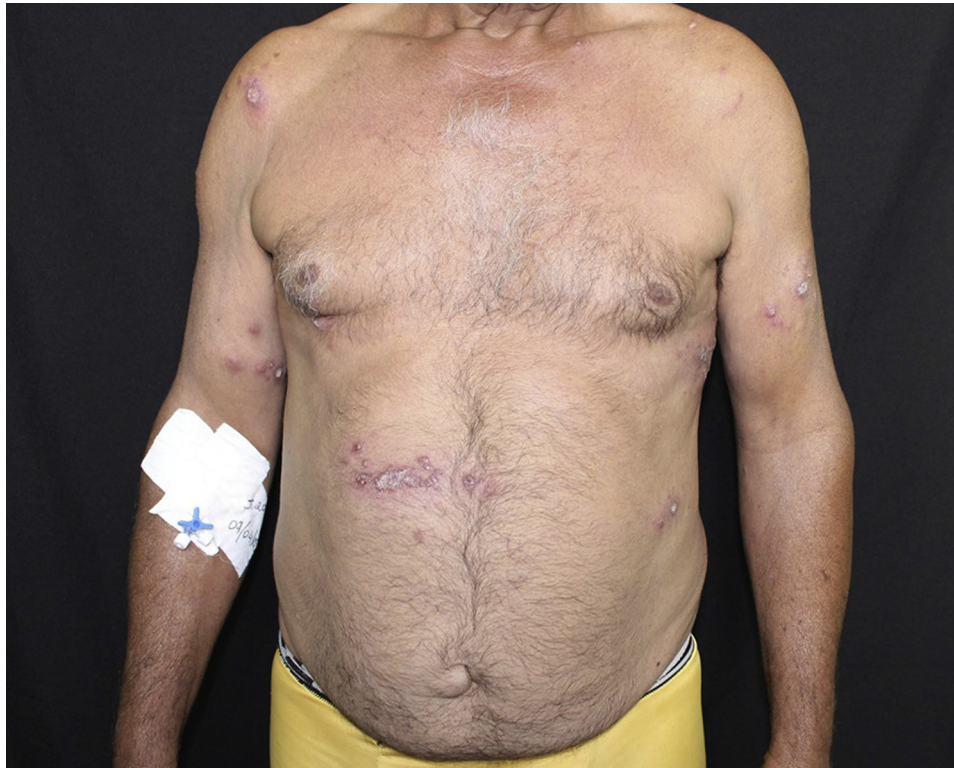Localized CL treatment consists of the parenteral daily administration of an antimonial for 20 days, at doses of 10 to 20 mg/kg/d. It can be reintroduced after 20 days, at the same dose, but for 30 days. If there is no remission, the physician can try second-line drugs, such as pentamidine and amphotericin B.

Because our initial therapy failed and after the definition of the infectious species, we initiated the treatment with pentamidine. Later, we introduced liposomal amphotericin B and once again did not obtain remission. The lesions only responded to a novel treatment schedule, based on intercalated cycles of Glucantime.

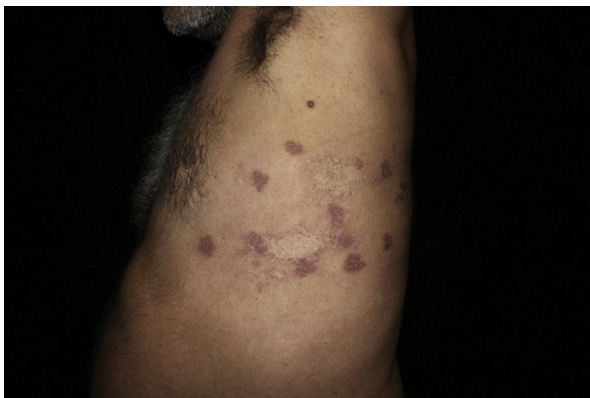The absence of commercial return for neglected diseases, such as leishmaniasis, has resulted in scarce funding from both public sector agencies and the pharmaceutical industry.<sup>7</sup> Thus, the development of therapies has been meager. Accordingly, strategies based on improving treatment schedules have been more satisfactory than the use of potential new chemical entities.

The exact structure and mechanism of the actions of antimonials are not fully understood. Nonetheless, 2 main theories justify its antileishmanial activity. Whereas 1 theory defends that Sb(V) has an intrinsic role, the other advocates that the pentavalent form is a prodrug, which needs to be reduced to Sb(III) so it can exert its activity.<sup>8,9</sup>

More than 80% of the Sb(V) is excreted through urine in 6 to 8 hours. Approximately 5% to 10% of the remaining medication is reduced to trivalent antimonial [Sb(III)], which remains in the organism for 24 to 72 hours.<sup>9</sup> Some state that this form has a third space concentration, which would delay its clearance for more than 30 days after its administration.<sup>9</sup> The toxicity of antimonials is greatly related to their trivalent presentation and the administered doses.<sup>10</sup>



**Fig 3.** Novel skin lesions show disease activity. Erythematous papules and plaques on the upper limbs and the abdomen.



**Fig 4.** Hyperchromic patches with an atrophic hypochromic center on the chest. Fewer and remising skin lesions after 3 intercalated low-dose cycles of Glucantime.

Sb(III) accumulates until a plateau is reached. After 10 days without medication, however, the serum rates of antimonials are minor.<sup>9</sup> Hence, waiting 20 days to reintroduce the drug in case of disease activity is a questionable approach.

Although some diseases respond to plateaus of medication, others react to peaks of therapy. Leishmaniasis, often treated as the second, may

belong in the first group. By intercalating 10 days of Glucantime (5 mg/kg/d) with 7 days without medication, we did not allow the serum rates to decrease to an insignificant level, obtaining efficacy without the same toxicity. Therefore, we diminished the adverse effects and elevated adherence to treatment. Our patient had no complaints during the low-dosage cycles.

This is the first case report, to our knowledge, to show that low doses of Glucantime succeeded in treating therapy-refractory disseminated CL caused by *L guyanensis*. We believe that randomized trials should be conducted to evaluate low, intermittent doses, leading to fewer adverse effects fewer expenses, without jeopardizing the leishmanicidal activity of antimonials.

#### REFERENCES

1. Fagundes-Silva G, Romero G, Cupolillo E, et al. *Leishmania (Viannia) naiffi*: rare enough to be neglected? *Memórias do Instituto Oswaldo Cruz* 2015;110(6):797-800.
2. Fernandes A, Pedroso R, Venazzi E, et al. American cutaneous leishmaniasis with unusual clinical presentation and response to treatment. *Rev Inst Med Trop Sao Paulo*. 2016;58.
3. Vries H, Reedijk S, Schallig H. Cutaneous leishmaniasis: recent developments in diagnosis and management. *Am J Clin Dermatol*. 2015;16(2):99-109.

4. Berens-Riha N, Fleischmann E, Pralong F, et al. Cutaneous leishmaniasis (*Leishmania tropica*) in a German tourist after travel to Greece. *J Travel Med.* 2009;16(3):220-222.
5. Bricaire F, Danis M, Gentilini M. Dermatoses associated with travel to tropical countries: a prospective study of the diagnosis and management of 269 patients presenting to a tropical disease unit. *Clin Infect Dis.* 1995;20:542-548.
6. Mitropoulos P, Konidas P, Durkin-Konidas M. New world cutaneous leishmaniasis: updated review of current and future diagnosis and treatment. *J Am Acad Dermatol.* 2010;63:309-322.
7. Yamey G, Torreele E. The world's most neglected diseases [editorial]. *Br Med J.* 2002;325:176-177.
8. Haldar AK, Sen P, Roy S. Use of antimony in the treatment of leishmaniasis: current status and future directions. *Mol Biol Int.* 2011;571242.
9. Frézard F, Demicheli C, Ribeiro R. Pentavalent antimonials: new perspectives for old drugs. *Molecules.* 2009;14(12):2317-2336.
10. Oliveira LF, Schubach AO, Martins MM, et al. Systematic review of the adverse effects of cutaneous leishmaniasis treatment in the New World. *Acta Tropica.* 2011;118:87-96.