



After cochlear implantation: Complications related to flap around implants

Feifei Qin^{1,2}, Wen Li^{1,3}, Jianxin Qiu*, Li Zhang², Mei Zhong²

Department of Otorhinolaryngology, The First Affiliated Hospital of Anhui Medical University, China

Received 11 October 2016; revised 5 December 2016; accepted 5 December 2016

Abstract

Objective: To report complications related to flap around implants after cochlear implantation, possible causes of such complications and treatments.

Methods and material: We performed a retrospective analysis of children in whom complications related to flap around implants occurred after undergoing cochlear implantation in our department from 2005 to 2016.

Results: Complications among 1500 cochlear implantation (CI) recipients by the same surgeon included hematoma (n = 20) and seroma around implants (n = 15), of which most (n = 10) recovered in 2 weeks after effective drainage, utility of antibiotics and pressure dressing, but 5 developed flap necrosis and had to undergo contralateral re-implantation. Four patients developed abscess around implants, of whom 2 recovered after 2 weeks of drainage, gentamicin irrigation and use of antibiotics, but 2 patients ended up with flap necrosis and had to receive contralateral reimplantation.

Conclusions: Immediate drainage, pressure dressing and antibiotics can be used to effectively control seroma around implants. For seroma lasting for more than two weeks without improvement, surgical drainage may be need.

Copyright © 2016, PLA General Hospital Department of Otolaryngology Head and Neck Surgery. Production and hosting by Elsevier (Singapore) Pte Ltd. This is an open access article under the CC BY-NC-ND license (<http://creativecommons.org/licenses/by-nc-nd/4.0/>).

Keywords: Cochlear implant; Complications; Flap-related problem

1. Introduction

Nowadays, cochlear implantation is a relatively safe and effective surgery for the treatment of severe and profound sensorineural hearing loss with low rate of postoperative complications (Ajallouyea et al., 2011; Hou et al., 2010). As more and more deaf patients receive this surgery, postoperative

complications have also been paid close attention to. At present, complications after CI are generally grouped as minor and major complications (Filipo et al., 2010). Minor complications refer to those that can be managed conservatively, including transient facial palsy, subperiosteal hematoma, infections not requiring surgical intervention, tinnitus, pain, facial tic, etc. These can usually be relieved by switching off electrodes. Major complications, however, are those that necessitate surgical intervention or threaten patient life, including meningitis, tinnitus, pain, facial tic, CSF otorrhea, complications that cannot be treated with ipsilateral reimplantation (flap necrosis, serious infection with tympanic membrane perforation and cholesteatoma), etc. These cannot be relieved by switching off electrodes. In the current study, we performed a retrospective analysis on complications in 1500 CI recipients by one surgeon in our department in recent years, many of which related to the

* Corresponding author.

E-mail addresses: 568616657@qq.com (F. Qin), 812104084@qq.com (W. Li), qiujianxin@ahmu.edu.cn (J. Qiu), 1159365361@qq.com (L. Zhang), 784563402@qq.com (M. Zhong).

Peer review under responsibility of PLA General Hospital Department of Otolaryngology Head and Neck Surgery.

¹ These authors equally contributed to the work.

² Studying in Anhui Medical University.

³ Co-author, Department of Otorhinolaryngology, Suzhou Municipal Hospital.

flap over the implant, to investigate causes and preventive and therapeutic measures.

2. Subjects and methods

2.1. Clinical data

Data were collected from 1500 CI recipients at the Department of Otolaryngology, the First Affiliated Hospital of Anhui Medical University, treated between May 2005 and May 2016, including 871 males and 629 females, aging from 6 months to 52 years (mean = 5.32 years). Implantation was in right ear in 1225 recipients and in left ear in the rest of recipients. The surgery was performed by one surgeon. Implant was switched on at one month after surgery with good test results in all recipients.

2.2. Implanted devices

Implanted devices included Nucleus 24M Cranked Electrode (n = 585) and Straight Electrode (n = 5) made in Australia, Advanced Bionics 90K Cochlear made in USA (n = 286), Med-EL 40+ made in Austria (n = 101) and Nurotron CS-10A made in China (n = 20).

2.3. Surgical techniques

Under general anesthesia, a small reverse “S” post-aural incision or a linear incision was made. After elevating temporal occipital periosteum, a 0.5 cm deep bone groove was made for the implant about 3 cm from the ear. Following mastoidectomy and exposure of the short crus of incus and incudal recess, the facial nerve recess 1 mm below was opened and the stapedius and round window niche exposed. A 1 mm fenestration was completed about 1.5 mm above and anterior to the round window niche. Entrance to the scala tympani was evidenced by leak of clear perilymph. While the fenestration was temporarily covered with a gelatin sponge, the surgical field was irrigated and the receiver placed in the bone groove and secured with temporalis fascia. The gelatin sponge was removed and electrodes carefully implanted under a microscope. After sealing electrodes with small pieces of muscle grafts, the surgical cavity was irrigated with antibiotics and the incision was closed in sutured layers followed by pressure dressing.

3. Complications and management

There were a total of 42 cases (42/1000) of infection-related complications in this group, including 37 cases of minor and 6 cases of major complications (see Table 1).

3.1. Wound infection

Infection is a Gordian knot for every surgeon. Cochlear implantation surgery is no exception. In 1 child, surgical incision was red and swollen one week after surgery, with

Table 1
Complications, management and outcomes.

Type of complication	No.	Management	Results
Wound infection	1	Wound debridement and suture	Recovered
Seroma around implants	15	Symptomatic treatment	10 Recovered 5 Drained
Subperiosteal hematoma	20	Pressure dressings and antibiotics	Recovered
Flap necrosis	2	1 Transposition of flap	1 Recovered
Implant extrusion		1 Monitoring	1 Monitoring
Wound abscess	4	2 Antibiotics	Recovered
		2 Wound debridement and suture	

small papules on skin surface but no purulent secretion. The child had an obvious allergic constitution. After two weeks of pressure dressing and intravenous dexamethasone and ceftriaxone sodium, the child's condition improved and the child was doing well at the 2-year follow-up.

3.2. Hematoma

In our series, the incidence rate of hematoma was the highest among complications related to flap around implants, occurring usually 1–2 days after operation. A small hematoma was often managed via local pressure dressing, antibiotics and symptomatic treatments. For more difficult hematoma, drainage was performed in addition to the above management. Generally, local conditions improved within half a month.

3.3. Abscess

Fever developed 1 month after operation in 3 patients, and after 5 years in 1 patient. Redness, swelling and tenderness were present around the implant, accompanied with local fluctuation. Purulent fluid was drained through puncture, followed by irrigation with gentamycin of three times, systemic antibiotics, pressure dressing and symptomatic treatments for 4 weeks. The abscess resolved in 2 patients, but required surgical debridement and contralateral re-implantation in the other 2 patients.

3.4. Seroma

Local swelling around implants was seen in 15 patients for years after operation, fortunately without pain but still uncomfortable and itchy with some decline in sound clarity through the device. The swelling was soft, with fluctuation to palpation but no local redness. Yellowish fluid was drained and was shown to be serous fluid with no pus cells by lab testing. Culture showed no bacteria growth. After drainage as well as pressure dressing and antibiotics for 2 weeks, local condition improved in 10 patients but not in the rest 5, for whom the skin over the implant eventually ruptured, showing local granulation and necrosis, with implant extrusion. Antibiotics, pressure dressing and symptomatic treatment failed in these patients. Surgical debridement and transposition flaps repair was performed in 2 patients initially. Surgical

management was needed again several months later in these 2 patients, due to skin flap necrosis and implants extrusion. Their implants were removed and they received contralateral implantation. Implants were taken out directly in the other 3 patients, followed by contralateral implantation.

3.5. Flap necrosis

Flap necrosis occurred in 2 patients. One was ischemic necrosis caused by the less than ideal incision design, while the other seemed to be caused by malnutrition and anemia.

4. Discussion

Cochlear implantation has made great progress in the past 20 years. With the improvement of surgical equipment and techniques, postoperative complications have somewhat declined, but they remain a Gordian knot for surgeons. The most common complications of cochlear implantation are: flap necrosis, infection, rupture and resultant device explantation (Trinidad et al., 2008). In our study, the rate of complications related to flap around implants was 3.7%, while rates of complications reported in the literature range from 0.06% to 10% (Raghuandhan et al., 2014; Ajallouyeen et al., 2011; Cunningham et al., 2004; Rubinstein et al., 1999; Hopfenspirger et al., 2007; Cohen and Hoffman, 1991; Kempf et al., 1999).

Fluid retention around implants often include hematoma and seroma (Catli et al., 2015). The incidence rate of fluid retention around implants in our series was 3.5%. Early hematoma around implants was a minor postoperative complication, generally caused by abnormal clotting mechanisms, inadequate intraoperative hemostasis, etc. It can lead to fibrosis or infection around implants, and even flap necrosis. The rates of such complications reported in the literature range from 0.4% to 3.7% (Bhatia et al., 2004; Weise et al., 2005; Migirov et al., 2009).

In our data, seroma around implants occurred in 1–2 years after cochlear implantation, characterized by eminentia around implants and obvious local fluctuation (Fig. 1). The drained fluid was yellow and serous in nature, with no pus or bacteria growth. These children had normal white blood cell counts and no fever, infection or other symptoms. It was highly possible that the seroma was associated with reaction to the silica gel that came with the implant. Seroma was clearly around silica gel in one child. The metal parts were not involved. The mechanisms leading to seroma formation remain unclear. Some believe that chronic inflammation may change the reaction to silicone rubber by the immune system and result in delayed allergy reactions (Kunda et al., 2006). Therein, after local pressure dressing, antibiotics, anti-allergic and symptomatic treatments, there was no seroma recurrence among the 15 children with minor symptoms. In the other 5 children with large seroma, the condition failed to improve despite repeated puncture drainages over a period of more than 2 weeks, complicated by flap infection and necrosis later.

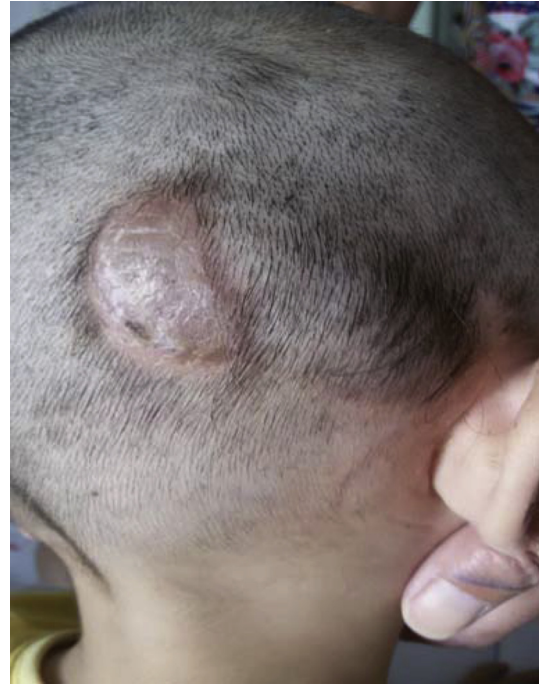

Fig. 1. Yellowish fluid was drained from the swelling and tested as serous in nature.

Finally, their implants were removed and contralateral implantation was performed. We consider infection in these cases as probably resulting from repeated puncture and drainage operations.

In the last 5 children, the local scalp flaps showed shrinkage and necrosis after repeated continuous pressure dressing. CT scan in 1 child (Fig. 2) showed a soft tissue density shadow between the implant and bone groove with no obvious lacuna. Surgical exploration revealed a large amount of edematous

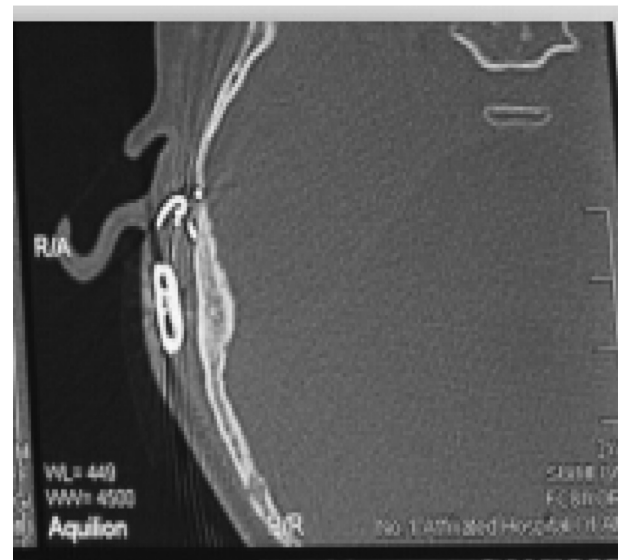


Fig. 2. A soft tissue density shadow can be seen between the implant and bone groove on this CT scan.

granulation tissue around the implant, which had been lifted out of the nearly disappeared bone groove and surrounded by dead space. The dead space was filled blood and/or exudate, which had not been absorbed and probably contributed to the formation of edematous granulation tissue and implant extrusion. The CT scan, however, did not show signs of otitis media. We infer that there is no correlation between seroma and middle ear involvement. In 2 cases, granulation tissue around the implant was removed during surgical exploration, followed by transposed scalp flap repair and other treatments deemed appropriate, which resulted in some improvement. However, skin necrosis and implant extrusion occurred within half year and the original implants were taken out. The patients recovered well after contralateral cochlear implantation.

In four recipients, local abscess developed with redness, swelling, elevated local temperature and tenderness, complicated by fever and elevated white blood cell counts. The drainage was purulent. Two children responded well to local irrigation with gentamicin, pressure dressing and large doses of intravenous antibiotics for two weeks, with implant preservation and no recurrence in ten years. This may have been caused by bacterial infection introduced during the operation. In the other 2 children, local condition improved after debridement, but both received contralateral re-implantation.

Early postoperative implant extrusion occurred in 2 cases, with a small amount of secretion. One occurred soon after surgery (Fig. 3), perhaps because of an incision that was too long and extended to the auricle, disrupting blood supply from the post-auricular artery, which caused ischemia, flap infection and necrosis. The patient recovered after transposition skin flap repair. Another case was a one-year old child with anemia and malnutrition. Two months after operation, a small area of necrosis appeared in the flap over the implant. Perhaps, the thin scalp and high surface tension led to ischemic necrosis of the flap. Following active antibiotics, nutrition and other

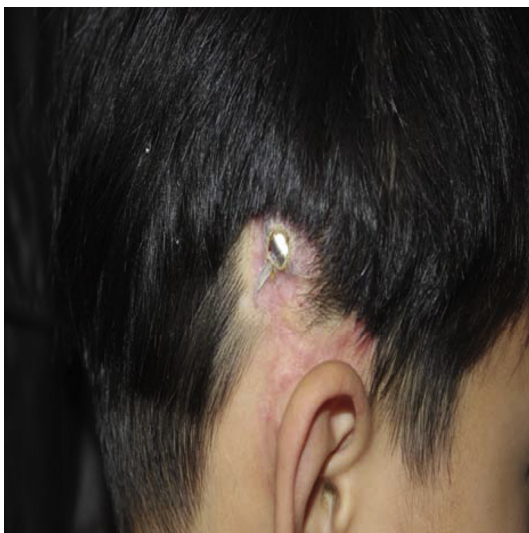

Fig. 3. Early ischemic necrosis of the flap caused by ill-planned incision.

symptomatic treatments, the necrotic defect gradually healed, although child is still being closely monitored.

In conclusion, patients can generally recover from post-operative seroma around the implant, following early drainage and pressure dressing, especially if the lesion responds well to the first 2 to 3 drainage treatments. For seroma lasting for more than two weeks, edematous granulation will likely develop, making spontaneous fluid absorption difficult. Repeated continuous pressure dressing may leave the local scalp flap susceptible to shrinkage and necrosis, which may make implant removal inevitable. The causes of seroma around implants remain to be further investigated, which is the goal of our future studies.

Acknowledgements

We would like to thank the hospital records section for their untiring effort in providing us access to the hospital database.

References

- Ajallouyeen, M., Amirjalari, S., Yousefi, J., et al., 2011 Dec. A report of surgical complications in a series of 262 consecutive pediatric cochlear implantations in Iran. *Iran. J. Pediatr.* 21 (4), 455–60.x.
- Bhatia, K., Gibbin, K.P., Nikolopoulos, T.P., et al., 2004. Surgical complications and their management in a series of 300 consecutive pediatric cochlear implantations. *Otol. Neurotol.* 25, 730–739.
- Catli, T., Olgun, Y., Celik, C., Olgun, L., et al., 2015 Jan 20. Swelling around the implant body: a late complication of cochlear implantation. How to deal? *Cochlear Implants Int.* 16 (1), 47–50. <http://dx.doi.org/10.1179/1754762814Y.0000000084> (Epub 2014 Jun 20).
- Cohen, H., Hoffman, R., 1991. Complications of cochlear implant surgery in adults and children. *Ann. Otol. Rhinol. Laryngol.* 100, 708–711.
- Cunningham 3rd, D., Slattery 3rd, W.H., Luxford, W.M., 2004. Postoperative infection in cochlear implant patients. *Otolaryngol. Head Neck Surg.* 131, 109–114.
- Filipo, R., D'Elia, C., Covelli, E., et al., 2010. Haematoma after cochlear implantation: management of a minor complication. *Acta Otolaryngol.* 13 (1), 108–113.
- Hopfenspirger, M.T., Levine, S.C., Rimell, F.L., 2007. Infectious complications in pediatric cochlear implants. *Laryngoscope* 117, 1825–1829.
- Hou, J.H., Zhao, S.P., Ning, F., et al., 2010 Jun. Postoperative complications in patients with cochlear implants and impacts of nursing intervention. *Acta Otolaryngol.* 130 (6), 687–695.
- Kempf, H., Johann, K., Lenarz, T., 1999. Complications in pediatric cochlear implant surgery. *Eur. Arch. Otorhinolaryngol.* 256, 128–132.
- Kunda, L.D., Stidham, K.R., Inserra, M.M., et al., 2006. Silicone allergy: a new cause for cochlear implant extrusion and its management. *Otol. Neurotol.* 27, 1078–1082.
- Migirov, L., Dagan, E., Kronenberg, J., 2009 Jul. Surgical and medical complications in different cochlear implant devices. *Acta Otolaryngol.* 129 (7), 741–744.
- Raghuandhan, S., Kameswaran, M., Anand Kumar, R.S., et al., 2014 Jan. A study of complications and morbidity profile in cochlear implantation: the MERF experience. *Indian J. Otolaryngol. Head Neck Surg.* 66 (Suppl. 1), 161–168.
- Rubenstein, J.T., Gantz, B.J., Parkinson, W.S., et al., 1999. Management of cochlear implant infections. *Am. J. Otol.* 20, 46–49.
- Trinidad, A., Rowlands, G., Obholzer, R., et al., 2008 Sep. Late skin flap failure following cochlear implantation. *Cochlear Implants Int.* 9 (3), 167–175.
- Weise, J.B., Muller-Deile, J., Brademann, G., et al., 2005. Impact to the head increases cochlear implant reimplantation rate in children. *Auris Nasus Larynx* 32, 339–343.