



Received: 2014.01.21
Accepted: 2014.02.17
Published: 2014.08.27

Authors' Contribution:

- A** Study Design
- B** Data Collection
- C** Statistical Analysis
- D** Data Interpretation
- E** Manuscript Preparation
- F** Literature Search
- G** Funds Collection

Iatrogenic Hemobilia in 10-Year-Old Boy

Urszula Zaleska-Dorobisz^{1ABCEFG}, Mateusz Łasecki^{1BCDEF}, Cyprian Olchowy^{1BCDEF},
Wojciech Ugorski^{1DEF}, Jerzy Garcarek^{1BCD}, Dariusz Patkowski^{2ABCD}, Jacek Kurcz^{1CDE}

¹ Department of Radiology, Wrocław University of Medicine, Wrocław, Poland
² Department of Pediatric Surgery, Wrocław University of Medicine, Wrocław, Poland

Author's address: Mateusz Łasecki, Department of Radiology, Wrocław University of Medicine, Wrocław, Poland,
e-mail: m.c.lasecki@wp.pl

Background:

Hemobilia in children is a rare phenomenon which has been described mostly in the context of traumas. The descriptions of massive hemobilia in children after liver biopsy are a rarity in the scientific literature because there are only a few examples of it. Hemobilia rarely develops spontaneously. Generally, this is a complication after a blunt abdominal trauma or after medical (especially surgical) procedures. Correct diagnosis and treatment of hemobilia are essential, especially in the case of patients with severe – sometimes life-threatening – haemorrhage from biliary ducts. It should be remembered that the symptoms of hemobilia do not necessarily occur immediately after surgery or trauma. In some cases hemobilia occurs after a changeable, asymptomatic period of time.

Case Report:

We would like to present a case of a severe form of hemobilia caused by arterio-biliary fistula which developed incidentally after liver biopsy in a 10-year-old boy with chronic hepatitis B. Symptoms of hemobilia appeared on the seventh day after the diagnostic biopsy when the patient's general condition began to deteriorate. The diagnosis of arterio-biliary fistula was established after angio-CT examination of the liver. A selective embolization of the right hepatic artery was carried out. Hemobilia in children is a rare phenomenon which has been described mostly in the context of traumas. The cases of massive hemobilia in children after liver biopsy are a rarity in the scientific literature because there are only a few examples of it. Hemobilia very rarely develops spontaneously. Generally, this is a complication after a blunt abdominal trauma or after medical (especially surgical) procedures.

Results:

Correct diagnosis and treatment of hemobilia are essential, especially in the case of patients with severe – sometimes life-threatening – haemorrhage from biliary ducts. It should be remembered that the symptoms of hemobilia do not necessarily occur immediately after surgery or trauma. In some cases hemobilia occurs after a changeable, asymptomatic period of time.

Keywords:

Arterio-Biliary Fistula • GI Haemorrhage • Hemobilia

PDF file:

<http://www.polradiol.com/abstract/index/idArt/890410>

Background

Hemobilia is one of the causes of haemorrhage from the upper gastrointestinal tract, which should be considered in differential diagnostics, also in children.

The first clinical description of hemobilia was made by Francis Glisson in 1654 [1]. In medical terminology, the word "haemobilia" was first used by Sandblom in 1948 [2,3].

In comparison to adults, hemobilia in children is a very rare phenomenon, and has been described as a complication of traumatic injuries of the abdomen [4–6]. The second most common cause of hemobilia is iatrogenic injury after diagnostic or surgical procedures performed on the liver or biliary ducts [7–9].

The clinical manifestation of hemobilia consists of three symptoms (sometimes called Sandblom's triad) [2,3], which are: pain in the right epigastric region, hyperbilirubinemia

and haemorrhage from the upper part of the gastrointestinal tract. Although the simultaneous occurrence of all of the three symptoms is infrequent (presented only in 30% of patients with hemobilia), the physician should always carefully look for all of them. Most patients complain of at least one of these symptoms.

Case Report

A 10-year-old boy (case record number 967/05) was admitted to the Paediatric Surgery Department as an emergency case with acute abdominal pain and symptoms of haemorrhage from the gastrointestinal tract. He was diagnosed with chronic hepatitis B when he was 6 months old and was under constant medical care of the Department of Paediatric and Infectious Diseases of the Wrocław Medical University. The development of the child was normal. He was periodically treated with interferon and lamivudine. On admission to the Department of Infectious Diseases, the laboratory investigation revealed deterioration in liver functioning (increased liver enzyme activity: AST 340 U/l, ALT 395 U/l, alkaline phosphatase 160 U/l GGTP 47 U/l,) and changes in the liver tissue, seen in the US examination (a slightly enlarged liver with hyperechogenic parenchyma + reactive lymph nodes in the liver hilum), which were indications for a liver biopsy in order to evaluate grading of the disease. An ultrasound was performed prior to the biopsy procedure in order to determine the topographic relationship between abdominal viscera. A thick-needle biopsy was carried out under general anaesthesia using a 4F needle. The blood test was normal (haemoglobin 13 g/dL, haematocrit 40.2%). On the seventh day after the diagnostic biopsy, the patient's general condition began to deteriorate. He developed an increasing abdominal pain located in the right epigastrium, increasing anaemia, bloody stools and progressing weakness. The boy was moved to the emergency department with suspected haemorrhage from oesophageal varices. The next blood test indicated haemoglobin reduction to 7 g/dl in the peripheral blood, haematocrit decrease to 25.2% and a decreased Fe level in the plasma. There were additional abnormalities in the physical examination that included abdominal tenderness, positive peritoneal signs, weakness and paleness. There was a coffee-ground vomitus. The ultrasound examination revealed fluid in the abdominal cavity, mostly between intestinal loops and in the recess behind the urinary bladder, a moderately enlarged liver with non-homogenous "coarse-grained structure" and irregular echogenic intensity of the liver parenchyma with a normal blood flow spectrum in the portal and hepatic veins.

There was no sign of pathological or dilated blood vessels in the region of the cardia and lesser curvature of the stomach. However, there were some abnormalities within the gallbladder, which was 30% larger than at the initial examination (Figure 1) – examinations were performed in fasted condition. Moreover, there were hyperechogenic, irregular structures within it and its walls were thickened to 0.5–0.6 cm. Because there was an increase in symptoms of haemorrhage from the GI tract (anaemia, vomiting, blood in the stools), gastroscopy was performed. However, the source of haemorrhage was not found and oesophageal varices were excluded. In the next 3 days the patient's general condition got worse gradually. During that time he fainted twice,

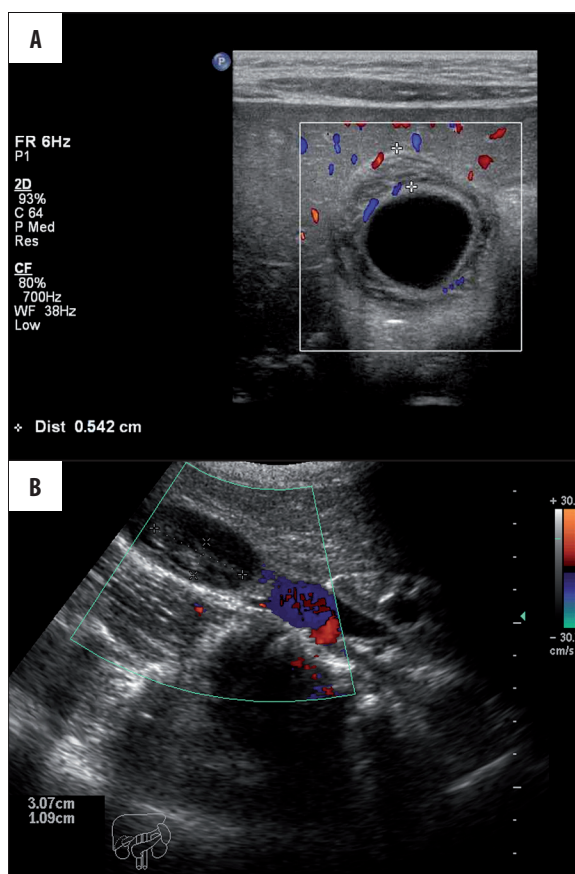


Figure 1. US image (A) demonstrates hyperechogenic, irregular structures in the lumen of the gallbladder (marked between cursors) as well as gallbladder wall thickening (B) to approximately 0.5 cm.

he had numerous bloody stools and progressing anaemia that required a blood substitute (antihemolytic plasma). Additional investigations showed worsening liver function and hyperbilirubinaemia. Increasing liver dimensions, gall bladder volume and dimensions of irregular structures within the gallbladder were observed in the next US examination. Moreover, the volume of fluid around the gallbladder increased. In the Doppler ultrasound examination, which was carried out on the 14th day after liver biopsy, a pathological flow (flash artifact and high diastolic velocity) in the right hepatic artery was found. On the basis of the US examination, as well as physical and laboratory tests of the gallbladder, an injury to and haemorrhage from the biliary ducts were suggested. An angio-CT of the liver was conducted to include or exclude the presence of an arterio-biliary fistula. It revealed liver enlargement, vascular disorders in the 5th and 6th segment and the presence of a haematoma in the gallbladder (Figure 2). The examination did not show extravasation of blood in the liver. Because of the difference between angio-CT and Doppler examination on the 21st day after liver biopsy, celiac arteriography was performed. The examination visualized the celiac trunk with its branches – tortuous spleen and common hepatic arteries. In the late venous phase, the portal vein was seen with an intrahepatic flow. Significant extravasations of the contrast agent with a fistula to one of the branches of the portal vein (HPAVF) were found in the middle of the right hepatic

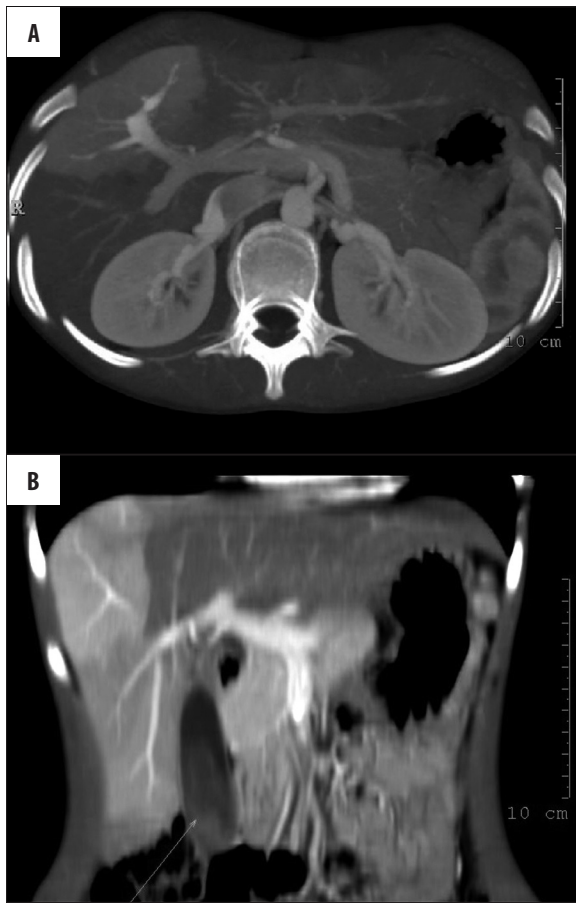

Figure 2. (A) In the late venous phase, the portal vein with intrahepatic flow is seen. Significant extravasation of the contrast agent from the middle portion of the right hepatic artery to one of the branches of the portal vein was found. During the examination the presence of contrast agent in the biliary ducts was observed which confirmed the existence of the arterio-biliary fistula with characteristic peripheral wedge-shaped hepatic parenchymal enhancement. (B) Coronal CT C + MPR reconstruction visualizes transient hepatic parenchymal enhancement (THPE). Triangular hyperattenuating area in hepatic arterial phase (segments VI and VII) with normal appearance of the rest of the liver in the portal phase. The presence of blood/haematoma in the gallbladder was confirmed (arrow).

artery. Contrast agent was also found in the biliary ducts, which confirmed the existence of the arterio-biliary fistula. The embolization of the right hepatic artery was performed using 0.2×0.2 cm fragments of spongostan. Following blood flow arrest, the Gianturco Wallach coil (diameter 0.4 cm, length 3 cm) was placed. A complete occlusion of the damaged branch of the hepatic artery and no blood flow through the fistula were seen in the follow-up arteriography. After the procedure, normal blood flow was observed. The boy was transferred to the Infectious Diseases Department for further specialist treatment after four days (Figures 3 and 4).

Discussion

There was no technical contraindication to liver biopsy in the described case. A puncture was made under sight

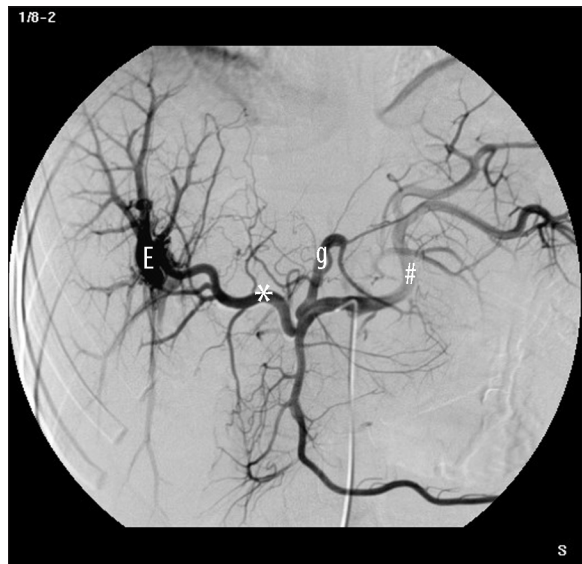

Figure 3. In the middle part of the right hepatic artery, significant extravasations (E) of the contrast agent (with the fistula to one of the branches of the portal vein) were visualised. Note the tortuosity of the common hepatic (*) and splenic (#) arteries. The left gastric artery (g) has a normal appearance.

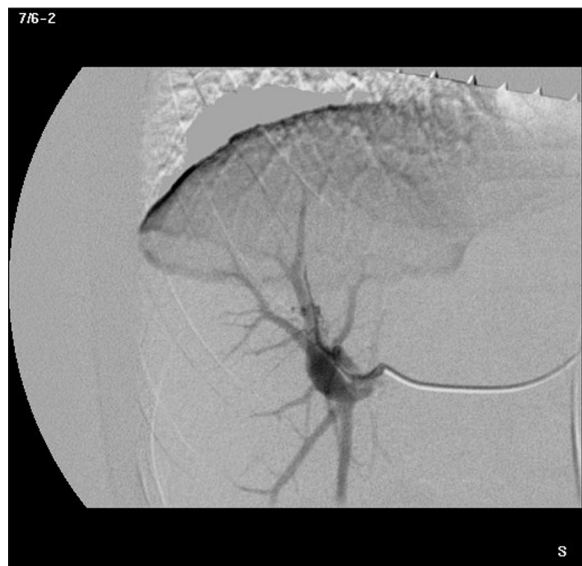

Figure 4. Follow-up arteriography demonstrated a complete occlusion of the damaged branch of the hepatic artery and no blood flow through the fistula.

supervision based on topographic lines and ultrasound data collected beforehand. This algorithm has been successfully used in our hospital for many years, but the complication in the described case shows that it is necessary to conduct liver biopsies in children under US supervision in order to avoid accidental puncture of the gallbladder or biliary ducts. There are other recommended methods that may reduce the frequency of hemobilia, such as laparoscopic biopsy, biopsy via the internal jugular vein or biopsy with embolization of the biliary tract [10–12]. In the described case, the lack of Sandblom’s triad made the diagnosis difficult. Ultrasound is a useful imaging technique whose quality depends on the physician’s experience. The US examination carried

out in the described patient showed a thrombus inside the gallbladder. A lack of pathological blood flow in the veins indicated an incidental puncture of the biliary duct and consequent haemorrhage to gallbladder lumen. Rapidly increasing clinical symptoms that intensified in the second week, dramatic worsening of the patient's condition and a lack of characteristic changes in imaging studies made diagnosis difficult. Moreover, there was no dilatation of the biliary

vessel, which contributed to the diagnostic complexity. If a thrombus is adjacent to the gallbladder wall it can be misinterpreted as a polyp. There was no sign of blood flow inside the thrombus. Clotted blood located in biliary ducts may be misdiagnosed as gallstones. Therefore, the golden standard in the diagnostics of hemobilia is angiography, even though it is not a first-line examination due to a higher rate of adverse effects as compared to US or CT [5,6].

References:

1. Glisson F: Anatomia hepatis, 1654
2. Sandblom P: Haemorrhage into the biliary tract following trauma – "traumatic hemobilia". *Surgery*, 1948; 24: 571–86
3. Sandblom P: Hepatic hemobilia: haemorrhage from the intrahepatic biliary tract, a review. *World J Surg*, 1984; 8(1): 41–50
4. Green MHA, Duell RM, Johnson CD et al: Hemobilia. *Br J Surg*, 2001; 88: 773–86
5. Vargas C: Diagnostic laparoscopy: a 5-year experience in a hepatology training program. *Am J Gastroenterol*, 1995; 90(8): 1258–62
6. Hayashi N: US-guided left-sided biliary drainage: nine-year experience. *Radiology*, 1997; 204(1): 119–22
7. Moehler M: Hemobilia after minilaparoscopic liver biopsy: a rare complication. *Endoscopy*, 2000; 32(9): S60
8. Montalto G, Soresi M, Carroccio A et al: Notarbartolo. Percutaneous Liver Biopsy: A Safe Outpatient Procedure? *Digestion*, 2001; 63: 55–60
9. Rousseau A, Regimbeau JM, Vibert E et al: [Hemobilia after blunt hepatic trauma: a sometimes delayed complication.] *Ann Chir*, 2004; 1: 41–45 [in French]
10. Hidalgo F: Treatment of hemobilia with selective hepatic artery embolization. *J Vasc Interv Radiol*, 1995; 6(5): 793–98
11. Xu ZB: Evaluation of selective hepatic angiography and embolization in patients with massive hemobilia. *Hepatobiliary Pancreat Dis Int*, 2005; 4(2): 254–58
12. Forlee MV: Hemobilia after penetrating and blunt liver injury: treatment with selective hepatic artery embolisation. *Injury*, 2004; 35(1): 23–28