



Case report

Extensive thrombosis with amputation of digit I pedis dextra: A case report in Indonesian adult with type 2 diabetes mellitus

Andrew Adinata Rusli, Soebagijo Adi Soelistijo *

Department of Internal Medicine, Faculty of Medicine, Universitas Airlangga – Dr. Soetomo General Academic Hospital, Surabaya, Indonesia

ARTICLE INFO

Keywords:

Diabetes mellitus
Acute limb infection
Chronic limb ischemia
Thrombectomy

ABSTRACT

Background: Diabetes mellitus (DM) is a risk factor for vascularization disorders, especially in the lower extremity that causes acute limb infection (ALI) and chronic limb ischemia (CLI).

Case presentation: A 41-year-old man has acute limb ischemia, critical limb ischemia, and diabetes mellitus. Investigation results showed vascular disorders in the lower extremity area with necrosis of the digit I pedis dextra. The patient underwent retrograde and antegrade thrombectomy of the right to left femoral artery and amputation of the digit pedis.

Discussion: Thrombectomy is still effective for the management of extensive thrombosis. Amputation of necrotic tissue needs to be conducted immediately to prevent infection.

Conclusion: Vascular disorders in the extremities are an urgent health problem that requires immediate treatment because it prevents damage to the function of the lower extremities.

1. Introduction

Diabetes mellitus (DM) is a serious long-term condition with major impacts on the lives and well-being of individuals, families, and communities around the world. The number of DM patients is estimated at 463 million people globally, and it is estimated that the number will increase by 2030 [1,2]. Diabetes mellitus is a risk factor for venous thrombosis, which several studies have shown that many DM patients have thrombosis and DM increases the risk of thrombosis by 1.4 times [3–5]. Thrombosis will block the flow of blood that supplies nutrients, oxygen, and drugs to the tissues. This disruption in perfusion causes tissue death, making it easier for bacteria to grow and thrive in necrotic tissue. Over time, amputation will be one of the solutions in diabetic patients with foot ulcers [6,7]. Based on the above explanation, we were interested in reporting a case of extensive thrombosis in an Indonesian male with DM who had his toe amputated, in which the report used the Surgical Case Report (SCARE) 2020 guidelines [8].

2. Case presentation

A 41-year-old man with complaints of diarrhea >5 times a day with yellow-brown stools, little pulp, no smell, no mucus, and blood and pain

in the abdomen. The patient also had an injury on his right foot thumb that gradually made the nail black and painful so that he could not walk. The patient had a history of hypertension and type 2 diabetes mellitus (T2DM).

Laboratory results showed some partial abnormalities as follows: HbA1C = 7.2, Albumin = 3.1 mg/dL, Potassium = 2.9 mg/dL Sodium = 126 mg/dL, Chloride = 88 mg/dL, CRP = 17.3 mg/L, uric acid = 8.7 mg/dL, partial prothrombin time (PPT) = 18.9 s, and activated partial thromboplastin time (APTT) = 31.8 s. Blood gas analysis examination of arterial blood pH: 7.51, SaO₂ = 94–100%, PaO₂ = 82 mmHg, PaCO₂ = 34 mmHg, Base excess (BE) = 4.1 mEq/L, Bicarbonate (HCO₃) = 27.1 mEq/L, SpO₂ = 100%. X-ray examination revealed no abnormalities. CT results showed very weak lower extremity vascularization (Fig. 1). The patient was diagnosed with Acute Limb Infection (ALI) in the left lower extremity and Chronic Limb Ischemia (CLI) in the right lower extremity and T2DM.

The patient was treated with a high-calorie, high-protein diet 2100 kcal/day, 1000 cc Wida KN2 infusion every 24 h, Ceftriaxone 1 g intravenous injection, Metamizole 1 g intravenous injection every 8 h, heparin pump 10 IU/kg BW/h, Dorner oral tablet 20 µg every 8 h, Cilostazole 50 mg oral tablet every 8 h, Allopurinol 100 mg oral tablet for treating gout, Lisinopril 5 mg oral tablet for hypertension, Concor 2.5

* Corresponding author at: Department of Internal Medicine, Faculty of Medicine, Universitas Airlangga – Dr. Soetomo General Academic Hospital, Jl. Mayjend Prof. Dr. Moestopo No. 6-8, Airlangga, Gubeng, Surabaya, East Java 60286, Indonesia.

E-mail address: soebagijo1121@gmail.com (S.A. Soelistijo).

<https://doi.org/10.1016/j.ijscr.2022.106853>

Received 5 December 2021; Received in revised form 21 February 2022; Accepted 22 February 2022

Available online 25 February 2022

2210-2612/© 2022 The Authors. Published by Elsevier Ltd on behalf of IJS Publishing Group Ltd. This is an open access article under the CC BY-NC-ND license

(<http://creativecommons.org/licenses/by-nc-nd/4.0/>).

mg oral tablet, Attapulgit 2 oral tablet every 8 h for diarrhea, Omeprazole 20 oral tablet mg every 12 h.

The patient underwent emergency surgery for retrograde and antegrade thrombectomy of the right to left femoral artery [9] that consisted of arteriotomy of the right to the left femoral artery, followed by retrograde thrombectomy on the right to left femoral artery along ± 35 cm with Fogarty number 5, obtained a hard thrombus of ± 8 cm. Moreover, an antegrade thrombectomy was conducted on the right to left femoral artery with a length of ± 20 cm with Fogarty number 3, obtained a thrombus of ± 10 cm. Each thrombectomy was performed 3 times, the flow was present after each thrombectomy, but it weakened again. Subsequently, a lower-extremity amputation procedure (digit I pedis destra) was performed [10]. The condition of the patient's legs before and after the amputation can be seen in Fig. 2.

Examination of the extremities after surgery was found to be warm, dry, red, and no edema. When conducting vascular evaluation in the lower extremity area, no palpable artery pulse was found. Meanwhile, palpable artery pulse was only found in the femoral artery when using Doppler. Moreover, further examinations showed hemoglobin (12.6 g/dL), Hematocrit (38.0%), Leukocytes (12.040/ μ L), Platelets (299,000/ μ L), blood sugar (117 mg/dL), creatinine (3.4 mg/dL), Albumin (2.89 mg/dL), Potassium (3.4 mg/dL), Sodium (135 mg/dL), Chloride (94 mg/dL), PPT (19.0 s), and APTT (54.3 s).

The patient was treated with Ceftriaxone 1 g intravenous injection every 12 h, Metamizole 1 g intravenous injection every 8 h, heparin pump 10 IU/kg BW/h, Dorner tablet 20 μ g every 8 h, Cilostazole 50 mg oral tablet every 12 h, Allopurinol tablet 100 mg orally. Warming right and left extremities and aortobifemoral bypass were also conducted.

3. Discussion

Surgical therapy for thrombotic cases of ALI includes thromboembolectomy with a balloon catheter (Fogarty), bypass surgery, and other adjuncts such as endarterectomy, patch angioplasty, and intraoperative thrombolysis. A combination of these techniques is often required. Surgical revascularization is preferred in patients with compromised limb conditions, suspected bypass infection, symptoms of occlusion lasting more than two weeks, or contraindications to thrombolysis [11]. In surgical intervention, a vertical incision exposes the common femoral artery and its branches. The location of the embolus in the bifurcation of the femoral artery can be detected by distally disappeared proximal femoral pulse. The artery is clamped and opened transversely over the branch. The thrombus is extracted by passing a Fogarty balloon catheter. This procedure is repeated until antegrade bleeding, indicating that the entire clot had been successfully extracted [12].

Medical therapy provided includes antithrombotic drugs which are

classified into two groups, namely antiplatelet and anticoagulant. Antiplatelet inhibits platelet aggregation that will prevent thrombus formation in blood vessels. Antiplatelet drugs include thienopyridine (e.g. ticlopidine, clopidogrel, prasugrel, ticagrelor), aspirin, nonsteroidal anti-inflammatory drugs (e.g. abciximab, roxifiban, eptifibatide, tirofiban), protease-activated receptor 1 (PAR-1) inhibitors (e.g. vorapaxar) [13–15]. Anticoagulants inhibit thrombus formation by inhibiting the hemostatic cascade in the body. This group is divided into four classes, such as vitamin K antagonists, heparin derivatives, direct oral anticoagulant (DOAC)/novel oral anti-coagulant (NOAC) consisting of factor Xa inhibitors, and thrombin inhibitors [13,16]. The mechanism of action of various antithrombotic groups is to inhibit several specific pathways [11].

Antithrombotic therapy is basically given based on the type of thrombosis (arterial or venous) and the organ involved. Factors that should be considered are that the elderly often have lower lean body mass so that the dose should be calculated more carefully based on body weight. Second, the elderly are often accompanied by various comorbidities so that receiving large amounts of drugs will increase the risk of interactions with the antithrombotic drugs given. Therefore, therapy monitoring must be carried out more carefully on the dose, drug effects, or side effects of drugs [17,18].

4. Conclusion

A 41-year-old man has acute limb ischemia, critical limb ischemia, and T2DM. The results of the investigation show vascular disorders in the lower extremity area with necrosis of the digit I pedis destra. The treatment given is endovascular revascularization and medical therapy with heparin pump injection, cilostazol, uric acid control with allopurinol, lisinopril, and concor for hypertension control, attapulgit to treat diarrhea.

Consent

Written informed consent was obtained from the patient for publication of this case report and accompanying images. A copy of the written consent is available for review by the Editor-in-Chief of this journal on request.

Guarantor

Soebagijo Adi Soelistijo.

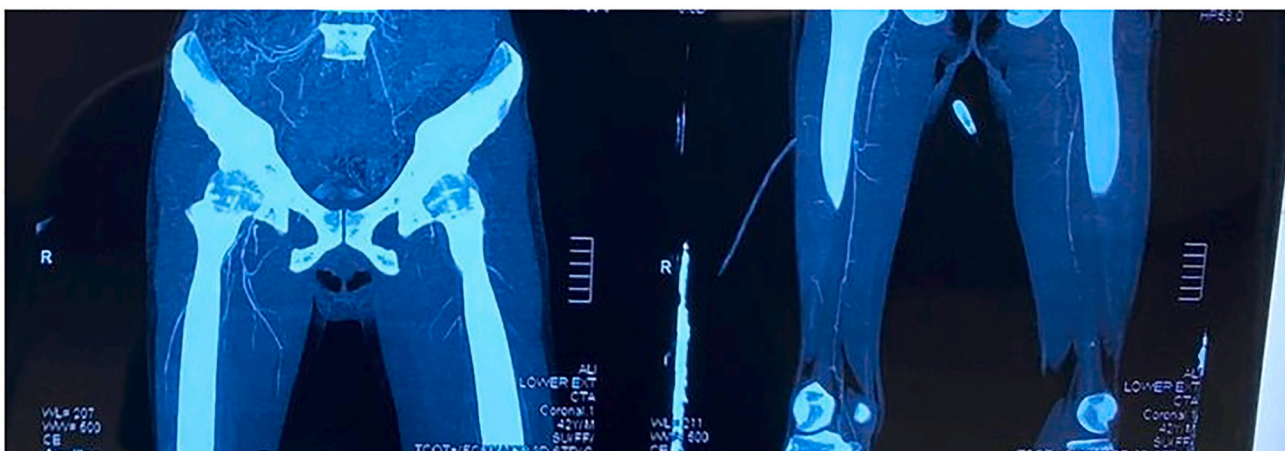


Fig. 1. CT Scan of the artery in the lower extremity.

a



b

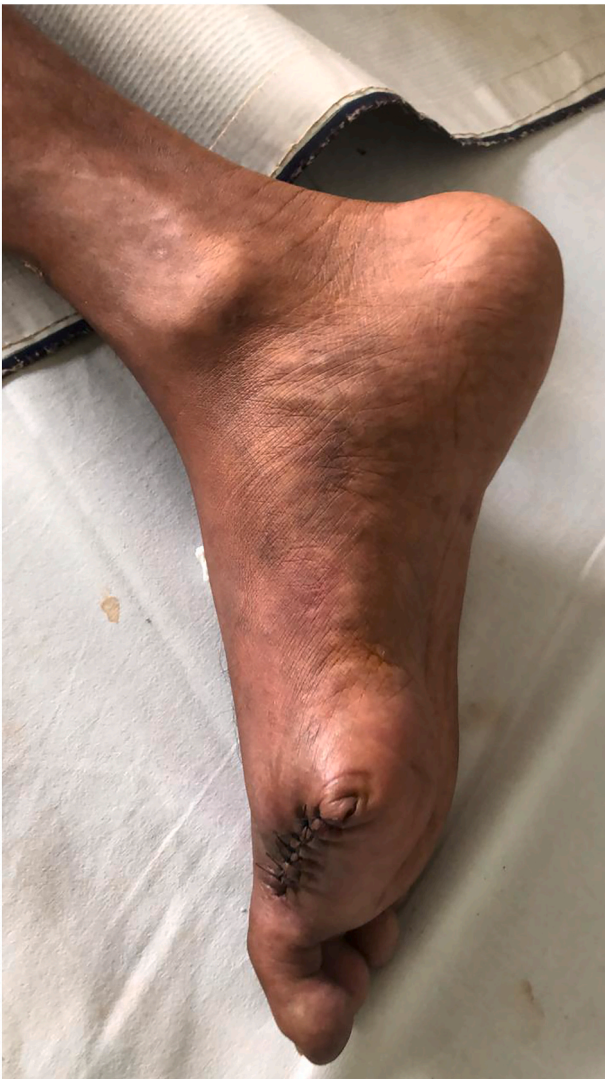

Fig. 2. Comparison of digit I pedis amputation before and after surgery.

Provenance and peer review

Not commissioned, externally peer-reviewed.

Sources of funding

None.

Ethical approval

Not applicable.

Credit authorship contribution statement

All authors contributed toward data analysis, drafting and revising the paper, gave final approval of the version to be published and agree to be accountable for all aspects of the work.

Declaration of competing interest

Andrew Adinata Rusli and Soebagijo Adi Soelistijo declare that they have no conflict of interest.

Acknowledgment

We would like to thank our editor “Fis Citra Ariyanto”.

References

- [1] P. Saeedi, I. Petersohn, P. Salpea, B. Malanda, S. Karuranga, N. Unwin, et al., Global and regional diabetes prevalence estimates for 2019 and projections for 2030 and 2045: Results from the International Diabetes Federation Diabetes Atlas, 9(th) edition, *Diabetes Res. Clin. Pract.* 157 (2019) 107843, <https://doi.org/10.1016/j.diabres.2019.107843>.
- [2] M.A.B. Khan, M.J. Hashim, J.K. King, R.D. Govender, H. Mustafa, Kaabi J. Al, Epidemiology of type 2 diabetes - global burden of disease and forecasted trends, *J. Epidemiol. Glob. Health* 10 (1) (2020) 107–111, <https://doi.org/10.2991/jegh.k.191028.001>.
- [3] J. Yuan, G.M. Xu, Early and late stent thrombosis in patients with versus without diabetes mellitus following percutaneous coronary intervention with drug-eluting stents: a systematic review and meta-analysis, *Am. J. Cardiovasc. Drugs* 18 (6) (2018) 483–492, <https://doi.org/10.1007/s40256-018-0295-y>.
- [4] J.A. Beckman, M.A. Creager, Vascular complications of diabetes, *Circ. Res.* 118 (11) (2016) 1771–1785, <https://doi.org/10.1161/circresaha.115.306884>.
- [5] Y. Mi, S. Yan, Y. Lu, Y. Liang, C. Li, Venous thromboembolism has the same risk factors as atherosclerosis: a PRISMA-compliant systemic review and meta-analysis, *Medicine* 95 (32) (2016), e4495, <https://doi.org/10.1097/md.0000000000004495>.
- [6] N. Vazzana, P. Ranalli, C. Cuccurullo, G. Davì, Diabetes mellitus and thrombosis, *Thromb. Res.* 129 (3) (2012) 371–377, <https://doi.org/10.1016/j.thromres.2011.11.052>.
- [7] N. Pechlivani, R.A. Ajjan, Thrombosis and vascular inflammation in diabetes: mechanisms and potential therapeutic targets, *Front. Cardiovasc. Med.* 5 (2018) 1, <https://doi.org/10.3389/fcvm.2018.00001>.
- [8] R.A. Agha, T. Franchi, C. Sohrabi, G. Mathew, A. Kerwan, The SCARE 2020 guideline: updating consensus Surgical CAse REport (SCARE) guidelines, *Int. J. Surg. (London, England)* 84 (2020) 226–230, <https://doi.org/10.1016/j.ijsu.2020.10.034>.
- [9] S. Cho, S.H. Lee, J.H. Joh, Complete revascularization of acute limb ischemia with distal pedal access, *Vasc. Endovasc. Surg.* 54 (1) (2020) 69–74, <https://doi.org/10.1177/1538574419873177>.
- [10] S.A. Domingos, C.N. França, I. Tuleta, M. Rezende Barbosa, Bachi ALL, L.M. Neves, Self-care in type 2 diabetes patients with urgency lower limb amputation: the influence of sex, marital status and previous amputations 15 (2021) 1083–1090, <https://doi.org/10.2147/ppa.S298537>.
- [11] J. Vojacek, Clinical monitoring of the antithrombotic treatment, *Cor Vasa* 54 (2) (2012) e97–e103, <https://doi.org/10.1016/j.crvasa.2012.01.012>.
- [12] J. Bath, J. Hartwig, V.Y. Dombrovskiy, T.R. Vogel, Trends in management and outcomes of vascular emergencies in the nationwide inpatient sample, *VASA Zeitschrift für Gefasskrankheiten* 49 (2) (2020) 99–105, <https://doi.org/10.1024/0301-1526/a000791>.
- [13] R.D. Acosta, N.S. Abraham, V. Chandrasekhara, K.V. Chathadi, D.S. Early, M. A. Eloubeidi, et al., The management of antithrombotic agents for patients undergoing GI endoscopy, *Gastrointest. Endosc.* 83 (1) (2016) 3–16, <https://doi.org/10.1016/j.gie.2015.09.035>.

- [14] M.P. Bonaca, P.G. Steg, L.J. Feldman, J.F. Canales, J.J. Ferguson, L. Wallentin, et al., Antithrombotics in acute coronary syndromes, *J. Am. Coll. Cardiol.* 54 (11) (2009) 969–984, <https://doi.org/10.1016/j.jacc.2009.03.083>.
- [15] P.G. Chassot, C. Marcucci, A. Delabays, D.R. Spahn, Perioperative antiplatelet therapy, *Am. Fam. Physician* 82 (12) (2010) 1484–1489.
- [16] J.L. Mega, T. Simon, Pharmacology of antithrombotic drugs: an assessment of oral antiplatelet and anticoagulant treatments, *Lancet (London, England)* 386 (9990) (2015) 281–291, [https://doi.org/10.1016/s0140-6736\(15\)60243-4](https://doi.org/10.1016/s0140-6736(15)60243-4).
- [17] G. Siasos, G. Skotsimara, E. Oikonomou, M. Sagris, M. Vasiliki-Chara, E. Bletsas, et al., Antithrombotic treatment in diabetes mellitus: a review of the literature about antiplatelet and anticoagulation strategies used for diabetic patients in primary and secondary prevention, *Curr. Pharm. Des.* 26 (23) (2020) 2780–2788, <https://doi.org/10.2174/1381612826666200417145605>.
- [18] R.A. Ajjan, N. Kietsiriroje, L. Badimon, G. Vilahur, D.A. Gorog, D.J. Angiolillo, et al., Antithrombotic therapy in diabetes: which, when, and for how long? *Eur. Heart J.* 42 (23) (2021) 2235–2259, <https://doi.org/10.1093/eurheartj/ehab128>.