

## Goat's eye integrated with a human cataractous lens: A training model for phacoemulsification

Sabyasachi Sengupta, Praveen Dhanapal<sup>1</sup>,  
Manas Nath<sup>2</sup>, Aravind Haripriya<sup>3</sup>, Rengaraj Venkatesh<sup>4</sup>

A relatively simple and inexpensive technique to train surgeons in phacoemulsification using a goat's eye integrated with a human cataractous nucleus is described. The goat's eye is placed on a bed of cotton within the lumen of a cylindrical container. This is then mounted on a rectangular thermocol so that the limbus is presented at the surgical field. After making a clear corneal entry with a keratome, the trainer makes a 5–5.5 mm continuous curvilinear capsulorhexis in the anterior lens capsule, creates a crater of adequate depth in the cortex and inserts the human nucleus within this crater in the goat's capsular bag. The surgical wound is sutured, and the goat's eye is ready for training. Creating the capsulorhexis with precision and making the crater of adequate depth to snugly accommodate the human nucleus are the most important steps to prevent excessive wobbling of the nucleus while training.

**Key words:** Cataract, goat's eye, phacoemulsification, training, wet lab

Ophthalmic microsurgical training has undergone a paradigm shift from being a master-apprentice teaching method to employing novel methods such as virtual simulators to achieve surgical skill transfer.<sup>[1,2]</sup> Learning phacoemulsification directly on human subjects poses ethical issues and is challenging for both, the trainee and trainer.<sup>[3]</sup>

To overcome these hurdles, both virtual simulators and animal eyes have been described as training models in the past.<sup>[4-7]</sup> An ideal model should closely mimic the surgical field of view and be easily reproducible and cost effective at the same time. This helps residents surmount their initial fear of operating on patients and provides opportunities to address issues such as dexterity, depth perception and handling the microscope and phacoemulsification machines. Though

the virtual simulator is a much more sophisticated tool for surgical training, it is expensive and beyond the budget of most residency programs in the developing world.

It has been proven that phacoemulsification offers significantly better uncorrected visual acuity compared to other techniques such as manual small incision cataract surgery (MSICS) or conventional extracapsular cataract extraction.<sup>[8]</sup> Hence, it is prudent that ophthalmology residents, even in the developing world, gain expertise in performing phacoemulsification. A cost effective animal eye model if prepared adequately, may go a long way in developing high-quality surgeons.

### Technique

The axial length and anterior chamber depth of the adult goat eye are almost similar to the human eye, but the lens thickness is nearly twice that in humans (3.63 mm vs. 7.85 mm) thereby allowing implantation of the human cataractous nucleus into the goat's lens.<sup>[9]</sup> Additionally, the lens matter in the goat's eye is almost entirely composed of the cortex making it easy to emulsify and create a bed for the human nucleus.

The stand for holding the enucleated goat's eye in position is a modified cylindrical container originally used for storing camera film rolls [Fig. 1a]. Cotton rolls are placed in the lumen of the cylindrical container and help in presenting the cornea and limbus at the surgical field [Fig. 1b]. This also prevents the excessive antero-posterior movement of the eyeball. Then, a rectangular piece of thermocol with a central, full thickness circular opening whose diameter corresponds to the diameter of the cylindrical container [Fig. 1b], is used to support and mount the cylindrical container with the goat's eye on to the surgical field [Video 1].

Once the goat's eye is mounted, a 2.8 mm keratome is used to make a clear corneal entry along the long axis of the eyeball [Fig. 2a] followed by a continuous curvilinear capsulorhexis of about 5–5.5 mm in diameter (smaller than the diameter of the human nucleus) initiated with a cystotome and completed with the capsulorhexis forceps [Fig. 2b]. Part of the lens matter is removed using minimal phaco energy and low vacuum settings to create a bed for the human nucleus obtained during MSICS [Fig. 2c]. The surgical wound is then extended horizontally to about 6 mm size and a frozen human nucleus, corresponding to grade 2–3 nuclear sclerosis, is implanted in the cortical bed within the goat's capsular bag [Fig. 2d]. Care is taken not to apply too much pressure over the nucleus as it may crack. The wound is sutured using 3 interrupted 9 "O" nylon sutures, and if required, its integrity is reinforced using commercially available cyanoacrylate glue. The goat eye is now ready to be used by the trainee surgeon. The video presents all the steps described above in a systematic manner.

### Discussion

The first step toward developing surgical competency is a structured surgical education program that helps residents develop the cognitive and psychomotor skills required for ophthalmic surgery.<sup>[10]</sup> A surgical wet lab that allows good training for phacoemulsification is the centerpiece for this.

We describe a technique that exposes a surgical trainee to the essential steps in phacoemulsification. The corneal incision within the clear cornea in a goat's eye feels almost identical to

Video available on: [www.ijjo.in](http://www.ijjo.in)

Access this article online

Quick Response Code:



Website:

[www.ijjo.in](http://www.ijjo.in)

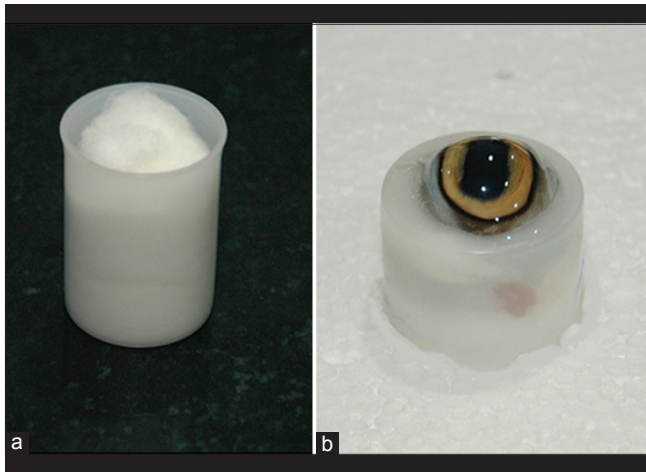
DOI:

10.4103/0301-4738.156937

Vitreoretina Services, <sup>1</sup>Department of Cornea and Refractive Services, <sup>2</sup>Department of Cataract and Refractive Services, <sup>4</sup>Glaucoma Services, Aravind Eye Hospital, Pondicherry, <sup>3</sup>Department of Cataract and Refractive Services, Aravind Eye Hospital, Madurai, India

**Correspondence to:** Dr. Sabyasachi Sengupta, Aravind Eye Hospital, Puducherry - 605 007, India. E-mail: [drsunny1980@gmail.com](mailto:drsunny1980@gmail.com)

**Manuscript received:** 06.06.14; **Revision accepted:** 27.02.15

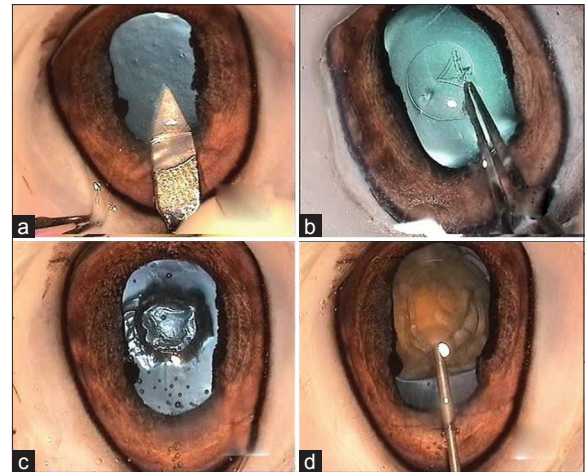


**Figure 1:** The cylindrical container (film roll box) filled with cotton rolls (a) used to hold the goat's eye that is mounted on a rectangular thermocol so that the limbus is presented at the surgical field (b)

a human eye. The capsulorhexis in the goat's eye is difficult to control as the anterior lens capsule is extremely elastic (similar to the pediatric lens capsule). This is a crucial step while preparing the goat's eye for phacoemulsification and hence, it is desirable that the trainer perform this "all important" step meticulously in order to make the phacoemulsification on the human nucleus fruitful. After the trainee is comfortable with steps of phacoemulsification, he/she can also attempt capsulorhexis on the goat's eye with utmost care. While trenching, cracking and emulsifying, one can work on a real cataractous nucleus, which gives the surgeon a near real feel of the actual cataract. While practicing, the trainee surgeon becomes familiar with the audible cues and foot pedal control along with understanding the machine's fluid dynamics.

A similar technique has been described by Kayıkçıoğlu *et al.* using sheep eyes almost a decade ago.<sup>[4]</sup> However, the authors mention that the implanted nucleus tended to move to the periphery of the capsule and behind the iris with fluid turbulence or when pushed with the phacoemulsification tip. These difficulties can be overcome by creating a capsulorhexis of the correct size and with adequate removal of the lens matter from the goat's eye to prevent excessive mobility of the human nucleus during phacoemulsification.

Ram *et al.* described a novel technique for surgical wet lab training on cadaveric human eyes using the Miyake – Apple technique.<sup>[11]</sup> Pandey *et al.*, using a similar technique, have injected Karnovsky solution to accelerate the density of cataract in the human cataractous lens.<sup>[12]</sup> Though the Miyake – Apple technique uses human eyes, it involves sectioning the eyeball at the equator and careful mounting using cyanoacrylate glue and glass slides, thus making it cumbersome and expensive. Additionally, phaco is performed after removing the cornea and iris, thus making it an open – sky technique and precluding understanding of the phacodynamics that require a closed chamber. Ours is a simple technique that does not require such sophisticated equipment as the Miyake – Apple mount and combines the advantages of corneal clarity and good visualization of the goat's eye with the near real feel of the human nucleus within the capsular bag. Due to these limitations, the Miyake – Apple technique has not found



**Figure 2:** A keratome is used to make an entry into the anterior chamber through the clear cornea (a), a capsulorhexis of about 5–5.5 mm is completed using a Utrata's forceps (b), a crater of adequate depth is created within the goat's capsular bag (c) using minimal phaco power and aspiration and after enlarging the surgical wound, a human nucleus is inserted within the crater created in the goat's capsular bag (d)

widespread applications for resident surgical training compared to surgical simulators though it has contributed immensely in research of newer intraocular lens technologies.<sup>[13]</sup>

Goat eyes are easily available and are economical as well. Also, due to the high volume MSICS procedures being performed on a daily basis, there are plenty of human cataractous nuclei of various cataract densities available for use.<sup>[14]</sup> Using this technique to train more than 100 trainees over the past few years, Haripriya *et al.* reported an intraoperative complication rate ranging from 2% to 8% amongst fellows and residents in training.<sup>[15]</sup> This compares favorably with complication rates reported by other authors.<sup>[16–18]</sup> The drawback of our training module, compared to a surgical simulator is that it does not allow automated feedback to the trainee based on their serial performance. However, after meticulous and sequential monitoring, the trainer can provide useful real – time feedback to the trainee and help improve performance. This may potentially help the trainee as much as the feedback provided by a simulator and hence, may be an acceptable tradeoff between training on a cost – prohibitive surgical simulator and the goat's eye model described here, though a head – to – head comparative study is required to confirm this hypothesis.

## Conclusion

Implantation of a human nucleus into the capsular bag of an adequately mounted and prepared goat's eye simulates the surgical environment to a large extent. This economical technique for surgical training may be useful, especially in the developing world, to train budding ophthalmologists in phacoemulsification.

## References

1. Lam CK, Sundaraj K, Sulaiman MN. A systematic review of phacoemulsification cataract surgery in virtual reality simulators. *Medicina (Kaunas)* 2013;49:1-8.
2. Sikder S, Tuwairqi K, Al-Kahtani E, Myers WG, Banerjee P.

- Surgical simulators in cataract surgery training. *Br J Ophthalmol* 2014;98:154-8.
3. Randleman JB, Wolfe JD, Woodward M, Lynn MJ, Cherwek DH, Srivastava SK. The resident surgeon phacoemulsification learning curve. *Arch Ophthalmol* 2007;125:1215-9.
  4. Kayikcioglu O, Egrilmez S, Emre S, Erakgün T. Human cataractous lens nucleus implanted in a sheep eye lens as a model for phacoemulsification training. *J Cataract Refract Surg* 2004;30:555-7.
  5. Hashimoto C, Kurosaka D, Uetsuki Y. Teaching continuous curvilinear capsulorhexis using a postmortem pig eye with simulated cataract (2)(2) *J Cataract Refract Surg* 2001;27:814-6.
  6. Van Vreeswijk H, Pameyer JH. Inducing cataract in postmortem pig eyes for cataract surgery training purposes. *J Cataract Refract Surg* 1998;24:17-8.
  7. Mekada A, Nakajima J, Nakamura J, Hirata H, Kishi T, Kani K. Cataract surgery training using pig eyes filled with chestnuts of various hardness. *J Cataract Refract Surg* 1999;25:622-5.
  8. Venkatesh R, Tan CS, Sengupta S, Ravindran RD, Krishnan KT, Chang DF. Phacoemulsification versus manual small-incision cataract surgery for white cataract. *J Cataract Refract Surg* 2010;36:1849-54.
  9. Ribeiro AP, Silva ML, Rosa JP, Souza SF, Teixeira IA, Laus JL. Ultrasonographic and echobiometric findings in the eyes of Saanen goats of different ages. *Vet Ophthalmol* 2009;12:313-7.
  10. Lee AG, Greenlee E, Oetting TA, Beaver HA, Johnson AT, Boldt HC, *et al.* The Iowa ophthalmology wet laboratory curriculum for teaching and assessing cataract surgical competency. *Ophthalmology* 2007;114:e21-6.
  11. Ram J, Wesendahl TA, Auffarth GU, Apple DJ. Evaluation of *in situ* fracture versus phaco chop techniques. *J Cataract Refract Surg* 1998;24:1464-8.
  12. Pandey SK, Werner L, Vasavada AR, Apple DJ. Induction of cataracts of varying degrees of hardness in human eyes obtained postmortem for cataract surgeon training. *Am J Ophthalmol* 2000;129:557-8.
  13. Pereira FA, Werner L, Milverton EJ, Coroneo MT. Miyake-Apple posterior video analysis/photographic technique. *J Cataract Refract Surg* 2009;35:577-87.
  14. Venkatesh R, Muralikrishnan R, Balent LC, Prakash SK, Prajna NV. Outcomes of high volume cataract surgeries in a developing country. *Br J Ophthalmol* 2005;89:1079-83.
  15. Haripriya A, Chang DF, Reena M, Shekhar M. Complication rates of phacoemulsification and manual small-incision cataract surgery at Aravind Eye Hospital. *J Cataract Refract Surg* 2012;38:1360-9.
  16. Khanna RC, Kaza S, Palamaner Subash Shantha G, Sangwan VS. Comparative outcomes of manual small incision cataract surgery and phacoemulsification performed by ophthalmology trainees in a tertiary eye care hospital in India: A retrospective cohort design. *BMJ Open* 2012;2:e001035.
  17. Bhagat N, Nissirios N, Potdevin L, Chung J, Lama P, Zarbin MA, *et al.* Complications in resident-performed phacoemulsification cataract surgery at New Jersey Medical School. *Br J Ophthalmol* 2007;91:1315-7.
  18. Rogers GM, Oetting TA, Lee AG, Grignon C, Greenlee E, Johnson AT, *et al.* Impact of a structured surgical curriculum on ophthalmic resident cataract surgery complication rates. *J Cataract Refract Surg* 2009;35:1956-60.

**Cite this article as:** Sengupta S, Dhanapal P, Nath M, Haripriya A, Venkatesh R. Goat's eye integrated with a human cataractous lens: A training model for phacoemulsification. *Indian J Ophthalmol* 2015;63:275-7.

**Source of Support:** Nil. **Conflict of Interest:** None declared.