

## Clinical Study

# Comprehensive CT Evaluation in Acute Ischemic Stroke: Impact on Diagnosis and Treatment Decisions

Askell Löve,<sup>1</sup> Roger Siemund,<sup>1</sup> Gunnar Andsberg,<sup>2</sup> Mats Cronqvist,<sup>1</sup> Stig Holtås,<sup>1</sup> and Isabella Björkman-Burtscher<sup>1</sup>

<sup>1</sup>Department of Neuroradiology, Skåne University Hospital, Lund University, Getingevägen 4, 221 85 Lund, Sweden

<sup>2</sup>Department of Neurology and Wallenberg Neuroscience Center, Skåne University Hospital, Lund University, 221 85 Lund, Sweden

Correspondence should be addressed to Askell Löve, askell.love@skane.se

Received 26 November 2010; Revised 12 January 2011; Accepted 19 January 2011

Academic Editor: Chelsea S. Kidwell

Copyright © 2011 Askell Löve et al. This is an open access article distributed under the Creative Commons Attribution License, which permits unrestricted use, distribution, and reproduction in any medium, provided the original work is properly cited.

**Background.** With modern CT imaging a comprehensive overview of cerebral macro- and microcirculation can be obtained within minutes in acute ischemic stroke. This opens for patient stratification and individualized treatment. **Methods.** Four patients with acute ischemic stroke of different aetiologies and/or treatments were chosen for illustration of the comprehensive CT protocol and its value in subsequent treatment decisions. The patients were clinically evaluated according to the NIHSS-scale, examined with the comprehensive CT protocol including both CT angiography and CT perfusion, and followed up by MRI. **Results.** The comprehensive CT examination protocol increased the examination time but did not delay treatment initiation. In some cases CT angiography revealed the cause of stroke while CT perfusion located and graded the perfusion defect with reasonable accuracy, confirmed by follow-up MR-diffusion. In the presented cases findings of the comprehensive CT examination influenced the treatment strategy. **Conclusions.** The comprehensive CT examination is a fast and safe method allowing accurate diagnosis and making way for individualized treatment in acute ischemic stroke.

## 1. Introduction

Current guidelines for treatment of acute stroke by intravenous (IV) thrombolysis with recombinant tissue-type plasminogen activator (rt-PA) [1, 2] are based on several large trials showing favorable results for this treatment within the 3- or 4.5-hour time window [3–9]. The main limitation has been the diminished benefit of IV-thrombolytic treatment beyond the given time frame. However, in these trials, the diagnosis of acute stroke was made clinically with supplementary nonenhanced computer tomography (NECT) examination to exclude intracranial hemorrhage and extensive early ischemic changes, both considered contraindications for thrombolytic treatment. No perfusion measurements or angiographic studies were carried out, which might have allowed treatment individualization and improved treatment results.

Clinical evaluation and NECT examination are still the most important tools in the workup of acute ischemic stroke. With modern brain CT-imaging, a supplementary overview of cerebral macro- and microcirculation can be obtained

in minutes with CT angiography (CTA) and CT perfusion, providing valuable information before or during treatment initiation.

The aim of this study was to illustrate a comprehensive three-step CT imaging protocol for acute stroke consisting of NECT to exclude hemorrhage and other contraindications for IV-thrombolysis, contrast enhanced dynamic CT-perfusion scan (CTP) to evaluate the existence and grade of perfusion deficit, and finally a contrast enhanced CT-angiography (CTA) of the cervical and intracranial arteries to locate and grade possible arterial occlusions. We describe the comprehensive radiological examination and evaluation and discuss the time aspect and present clinical cases emphasizing and discussing the impact of the method on treatment individualization.

## 2. Methods and Material

Four patients with acute ischemic stroke of different aetiologies or different treatments were chosen for illustration

TABLE 1: Overview of starting times of relevant events and NIHSS scores for the four different cases.

Event	Case 1	Case 2	Case 3	Case 4
Onset of symptoms	0	0	0	0+
Arrival at the stroke center	14 min	38 min	38 min	4 h 0 min
NIHSS evaluation	<b>14</b>	<b>9</b>	<b>14</b>	<b>11</b>
CT-head	43 min	56 min	54 min	4 h 25 min
CT-perfusion	47 min	63 min	64 min	4 h 41 min
CT-angiography	51 min	66 min	68 min	4 h 53 min
IV-thrombolysis	65 min	80 min	—	—
Thrombectomy/IA-thrombolysis	210 min	—	—	6 h 30 min
NIHSS evaluation at discharge	<b>1</b>	<b>6</b>	<b>0</b>	<b>1</b>

of the comprehensive CT protocol and for demonstrating the impact of the information obtained on treatment decisions.

When the first medical personnel arrived at the scene of a suspected acute stroke they immediately notified the stroke center. In this way the patients entered the stroke fast-track service before physically arriving at the hospital, giving the hospital stroke team, consisting of personnel from the emergency department, a neurologist and the radiology department personnel, time to prepare and coordinate their actions. The neurological deficit was quantified using the National Institutes of Health Stroke Scale (NIHSS) [10] and the patients were immediately transferred to the radiology department where they entered the three-step comprehensive CT examination performed using a Brilliance 64-slice CT (Philips Medical Systems, Best, The Netherlands).

Firstly a spiral whole-brain NECT was performed with  $16 \times 1.0$  mm primary slices (120 kV, 355 mAs, CTDI 57 mGy = 2.2 mSv) reconstructed to axial and coronal MPR with 5 and 3 mm slice thickness, respectively, to rule out intracranial hemorrhage and early imaging findings of ischemia, both representing contraindications for intravenous thrombolysis.

If no contraindications for IV thrombolysis were established, dynamic contrast-enhanced CTP was performed with injection of 70 mL Iomeprol 400 mgI/mL (Iomeron, Bracco SA, Milano, Italy) followed by 40 mL saline injected at 5 mL/sec. A total of 34 sequential acquisitions were performed with a scan interval of 1.5 seconds covering a 4 cm-thick section of the brain (80 kV, 170 mAs, CTDI 5.9 mGy/scan  $\times$  34 scans = 200 mGy = 1.7 mSv). Each acquisition consisted of eight adjacent 5 mm slices covering 4 cm of brain extending upwards from a level 2 cm above the entrance of the sella. Brain perfusion analysis was performed using the brain perfusion package of the Extended Brilliance Workspace (Philips Medical Systems, Best, The Netherlands). For the arterial input and venous output functions the A2 segment of the anterior cerebral artery and the posterior superior sagittal sinus were used respectively, avoiding occluded arteries or other major abnormalities [11]. Cerebral blood volume (CBV), cerebral blood flow (CBF), and mean transit time (MTT) were calculated and displayed by the software. The software package provided an automated color coded CTP-viability map. The penumbra (tissue at risk) was

defined as a region where MTT was prolonged by more than 50% when compared to the contralateral hemisphere [12] and was indicated by green color. The infarct core was defined as a region within the penumbra where CBV measured lower than 2 mL/100 g and was indicated by red color (Figure 1).

Finally a contrast-enhanced CTA of the cervical and intracranial arteries was performed with  $64 \times 1.0$  mm primary slices (120 kV, 225 mAs, CTDI 943 mGy = 4.6 mSv) in one continuous run after the administration of 100 mL Iomeprol 400 mgI/mL followed by 40 mL saline injected at 5 mL/sec. The CTA scan was started by automated monitoring of the contrast enhancement in the descending aorta. Reconstructions were created with 3 mm-slice thickness in the axial, sagittal and coronal planes in addition to maximum intensity projections (MIP) and three-dimensional images in selected cases.

The effective dose for each examination was estimated from the dose length product (DLP) by the equation  $E$  [mSv] =  $DLP \times f$ . The conversion factor ( $f$ ) used for NECT and CTP was 0.0021 and 0.0049 for CTA [13]. All stated dose values are the typical dose values of our standard protocols. Slight individual dose variation occurs due to different scan lengths and the use of dose modulation.

The imaging information was reviewed directly at the workstation during the examination and immediate treatment decisions were made by a joint effort of the neurologist and the neuroradiologist. For intravenous thrombolysis 0.9 mg/kg alteplase (Actilyse) was administered by IV-infusion over 60 minutes (maximum 90 mg). Patients selected for neurointerventional treatment underwent digital subtraction angiography (DSA) followed by intraarterial (IA) thrombolysis and/or mechanical thrombectomy. Time of important events was accurately logged throughout the whole process, from onset of symptoms to treatment initiation (Table 1).

For followup the patients underwent a magnetic resonance imaging (MRI) examination within 48 hours from symptom onset. The examinations, performed on a Philips Intera (Philips Medical Systems, Best, The Netherlands) or Siemens Allegra (Siemens Medical, Munich, Germany) 3 Tesla scanners, included T1, T2, FLAIR, diffusion weighted imaging (DWI), and in selected cases MR perfusion (MRP) and time-of-flight MR-angiography (MRA).

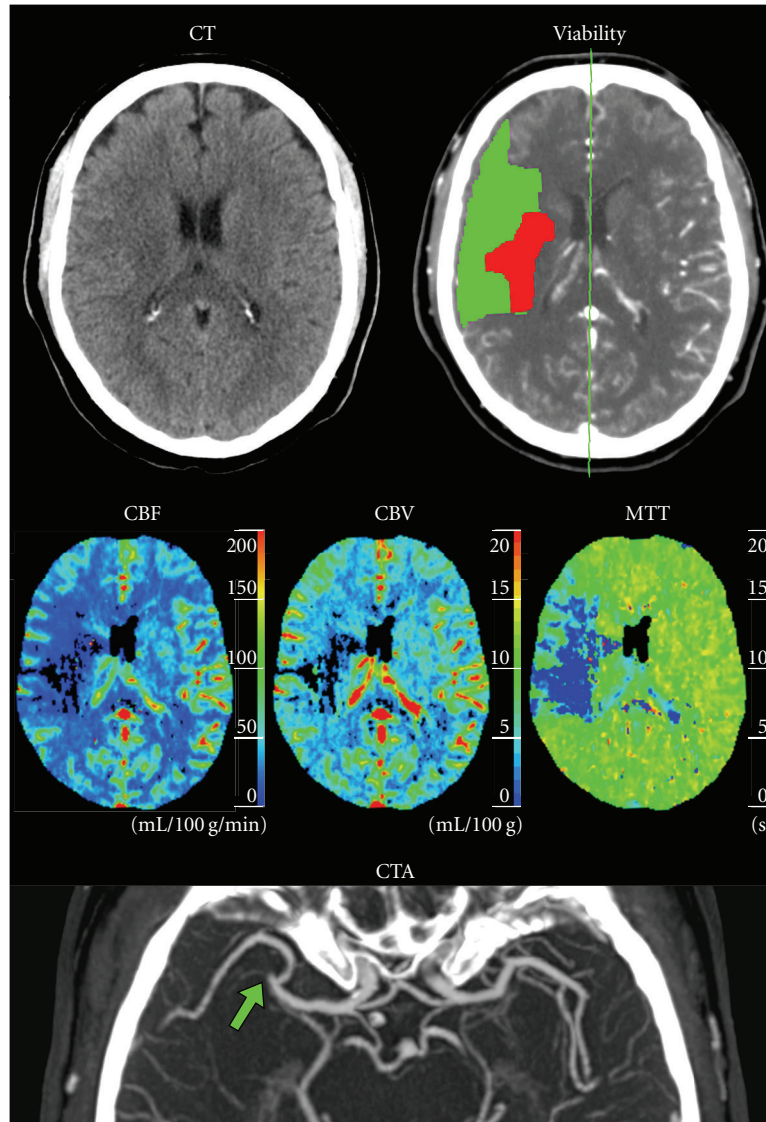


FIGURE 1: Case 1: 66-year-old male with left-sided stroke symptoms and a normal NECT. Initial comprehensive examination shows reduction of both CBF and CBV in the right hemisphere and an increase in MTT caused by a right-sided M2-segment MCA occlusion (arrow) seen on the CTA. The CTP viability map shows a small area of advanced perfusion defect (red) in the right hemisphere surrounded by a relatively large penumbra (green).

### 3. Results

**3.1. Case 1: CTP Results Change Treatment Strategy.** 66-year old male with hypertension and controlled hypercholesterolemia presented with acute onset of left-sided weakness and difficulty speaking. On physical examination he was fully-oriented but had dysarthria, rightward gaze preference, left sided hemiparesis involving the face, and left sensory deficits. The NIHSS score was 14 (Table 1). NECT was normal, but CTP showed a small area of advanced perfusion deficit with a relatively large surrounding area of potentially salvageable ischemic brain tissue (penumbra) in the arterial territory of the right insular artery. This was confirmed by the visualization of an M2 segment occlusion of the right middle cerebral artery (MCA) on

CTA (Figure 1). IV thrombolysis was initially given but since the treatment did not lead to any significant change in symptoms the CT examination was repeated. The new NECT showed early signs of infarction in the right basal ganglia. CTP showed unchanged ischemic core size but marked enlargement of the surrounding penumbra (Figure 2). Based on the findings of penumbra progression despite treatment with IV-thrombolysis, implicating worsening prognosis, the patient underwent DSA which showed an embolic occlusion of the right insular artery. After unsuccessful attempt at thrombectomy, local IA thrombolysis was started leading to complete dissolution of the embolus within 5 hours from the onset of symptoms (Figure 3). Right after the neurointervention the patient scored 12 on NIHSS, and the next day the NIHSS score was down to 4 with only

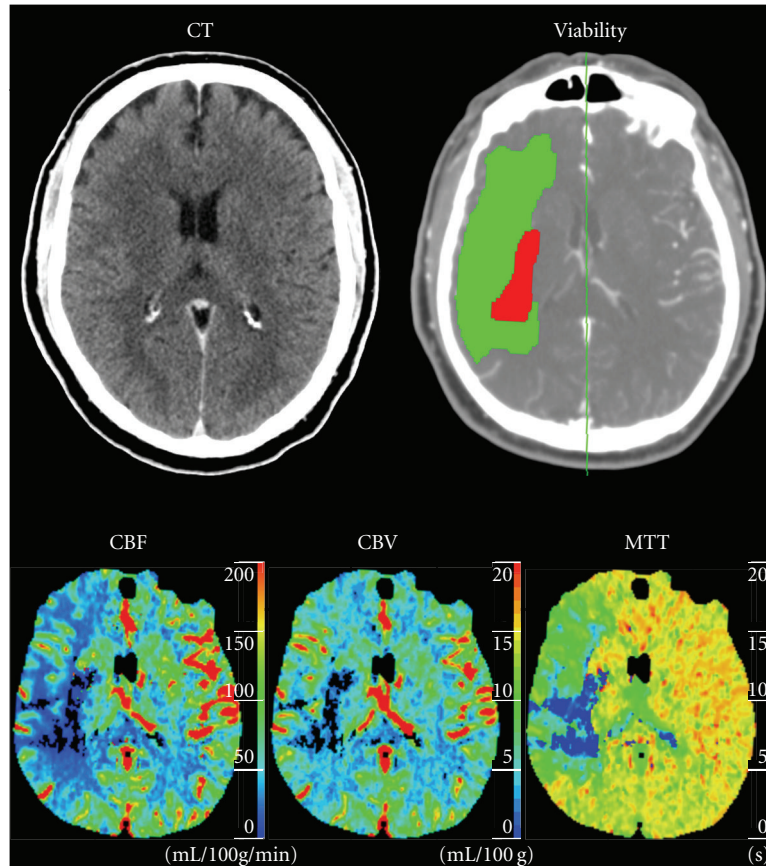


FIGURE 2: Case 1: Repeated NECT and CTP examinations 90 minutes after IV-thrombolysis without clinical improvement. The NECT is still normal and the CTP shows unchanged ischemic core but moderate enlargement of the penumbra. Based on this information the patient underwent intraarterial thrombolysis.

slight remaining left-sided weakness. Follow-up MRI showed diffusion abnormality in the right putamen corresponding to the CT-perfusion defined ischemic core, but normal perfusion in the CT-defined penumbra region (Figure 4). One week after initial presentation the NIHSS score was 1 and the patient was discharged with only minor strength reduction in the left arm and a partial central facial paresis.

**3.2. Case 2: Fragmented Cardiogenic Embolism.** 65-year-old male with controlled hypertension and paroxysmal atrial fibrillation who presented with acute onset of left-sided weakness and difficulty speaking the day after electrical defibrillation. On physical examination he was fully oriented but had general left-sided hemiparesis, facial weakness, mild dysarthria and hemi-inattention (neglect) to more than one sensory modality and scored 9 on NIHSS (Table 1). NECT was normal, but CTP showed multiple small areas of reduced perfusion (penumbra) in the right hemisphere with a small area of advanced ischemic core anterior to the Sylvian fissure (Figure 5). CTA showed no definitive arterial occlusion. After treatment with IV-thrombolysis the NIHSS score was down to 5 with only slight remaining left-sided weakness and minor sensory loss. Follow-up MRI showed diffusion

abnormality in the right frontal lobe immediately anterior to the Sylvian fissure confirming the CT-perfusion defined infarct, but showed no additional diffusion- or perfusion abnormalities (Figure 6). The patient was transferred to a rehabilitation center.

**3.3. Case 3: Lacunar Stroke with Spontaneous Recovery.** 49-year-old male with uncontrolled hypertension presented with acute onset of right-sided weakness and difficulty speaking. On physical examination he was fully oriented but had dysarthria and right-sided hemiplegia including facial nerve palsy but no sensory deficits. The NIHSS score was 14 (Table 1). NECT and CTA were normal, but the CTP showed a small perfusion defect in the left corona radiata that was initially missed (Figure 7). Just before planned administration of IV-thrombolysis the patient's symptoms spontaneously and completely resolved and the treatment was cancelled. Shortly thereafter the patient experienced transient relapse of the initial symptoms lasting about 5 minutes, again with complete recovery. Follow-up MRI confirmed an acute lacunar infarction in the left corona radiata matching the subtle CTP perfusion deficit (Figure 8). On the third day the patient was discharged with no persisting neurological deficit.

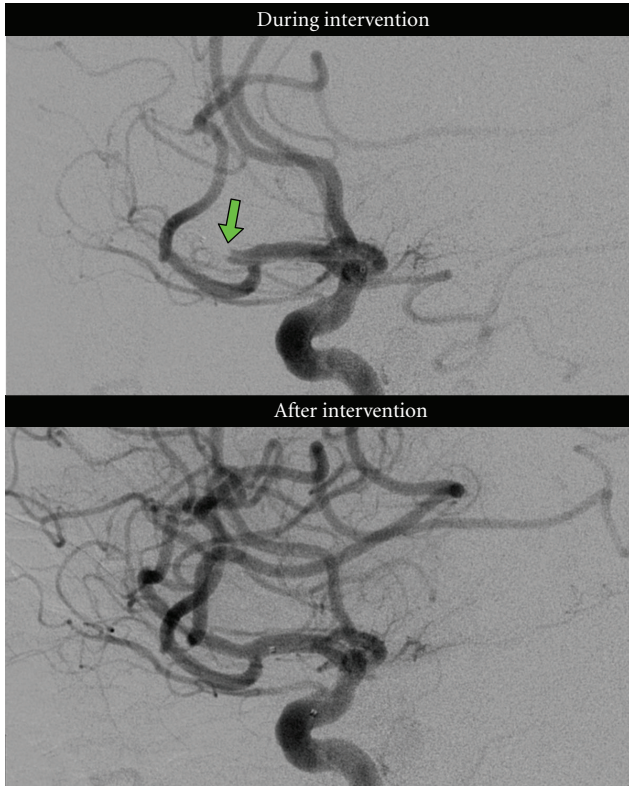


FIGURE 3: Case 1: DSA images from the right anterior cerebral circulation. The microcatheter is seen in an occluded M2-segment of the right MCA (arrow) during the intervention. The IA-thrombolysis results in complete recanalization of the occluded segment.

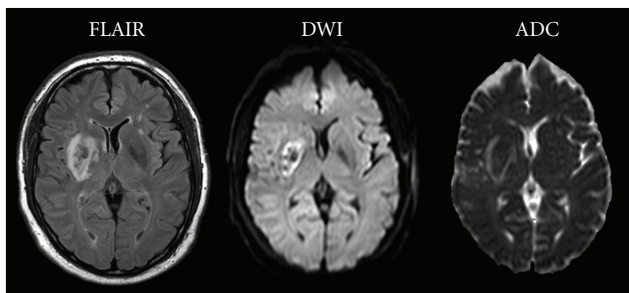


FIGURE 4: Case 1: follow-up MRI with FLAIR, DWI and ADC showing an established infarction in the right basal ganglia region, with minor hemorrhagic transformation, corresponding well to the previously defined CTP ischemic core.

**3.4. Case 4: Fluctuating Symptoms and Unknown Time of Onset.** 27-year-old woman using oral contraceptives and with prior history of migraine and benign childhood epilepsy woke up with fluctuating left-sided weakness. Prior to admission she experienced 5 episodes of weakness each lasting 5–10 minutes and followed by near-complete recovery. NECT, CTA, and CT venography (CTV) performed at a local hospital were judged normal. In retrospect a dense media sign was

seen on the NECT and an occlusion of the right MCA M2-segment on the CTA. The patient was referred to the stroke center and upon arrival she was fully oriented but physical examination revealed left sided hemiplegia and facial nerve palsy. The current symptom episode had persisted for over 1 hour without any recovery, unlike the previous attacks. Her NIHSS score was 11 (Table 1). Repeated NECT was normal but CTP showed a large volume of ischemic brain tissue in the right basal ganglia and frontal lobe, without evidence of advanced perfusion deficit. CTA showed unchanged occlusion of a right MCA M2-segment (Figure 9). An acute MRI examination with DWI showed two small right sided ischemic lesions within the CTP-defined ischemic area (Figure 10). Since the duration of symptoms was more than 4.5 hours, it was decided to perform IA-thrombolysis. DSA confirmed the M2-occlusion which was completely recanalized by local IA-thrombolysis within 6 hours from onset of persistent neurological symptoms (Figure 11). The intervention was performed with the patient awake. During the treatment a partial revascularization was established and the patient instantly became capable of moving her previously paretic left extremities. Intraarterial thrombolysis was then stopped despite a remaining thrombus because of the risk that further lysis would increase the risk of secondary hemorrhage. The patient complained of increasing headache and a follow-up NECT demonstrated a small hemorrhagic transformation in the right basal ganglia region measuring  $10 \times 12$  mm (Figure 12). She was left with persisting partial facial paresis resulting in a NIHSS score of 3. Follow-up MRI including MR-angiography showed slight enlargement of the two known diffusion abnormalities located in the right basal ganglia and centrum semiovale with complete revascularization of the right MCA (Figure 12). No progress of the hemorrhagic component was noted. One week after initial presentation the NIHSS score was 1 and the patient was transferred back to the local hospital.

## 4. Discussion

**4.1. The Comprehensive Acute Examination.** According to current guidelines all patients with suspected acute ischemic stroke receive the same treatment within the given time frame, regardless of imaging findings which potentially might be used to individualize treatment.

A negative comprehensive CT examination does not exclude patients with clinically suspected acute ischemic stroke from receiving IV thrombolysis because symptomatic small vessel occlusions (Case 3) can be difficult to detect both on CTA and CTP. On the contrary a positive comprehensive CT examination can be valuable when choosing the optimal treatment. When a large vessel occlusion is identified on CTA (Cases 1 and 4) an evaluation of the collateral circulation in the affected territory with CTP can be useful to identify patients with perfusion mismatch suggesting tissue at risk that might be salvaged. These patients should be considered for IV-thrombolysis but the treatment can be converted to IA thrombolysis (bridging) for more aggressive approach if needed, potentially increasing the chance of a good outcome

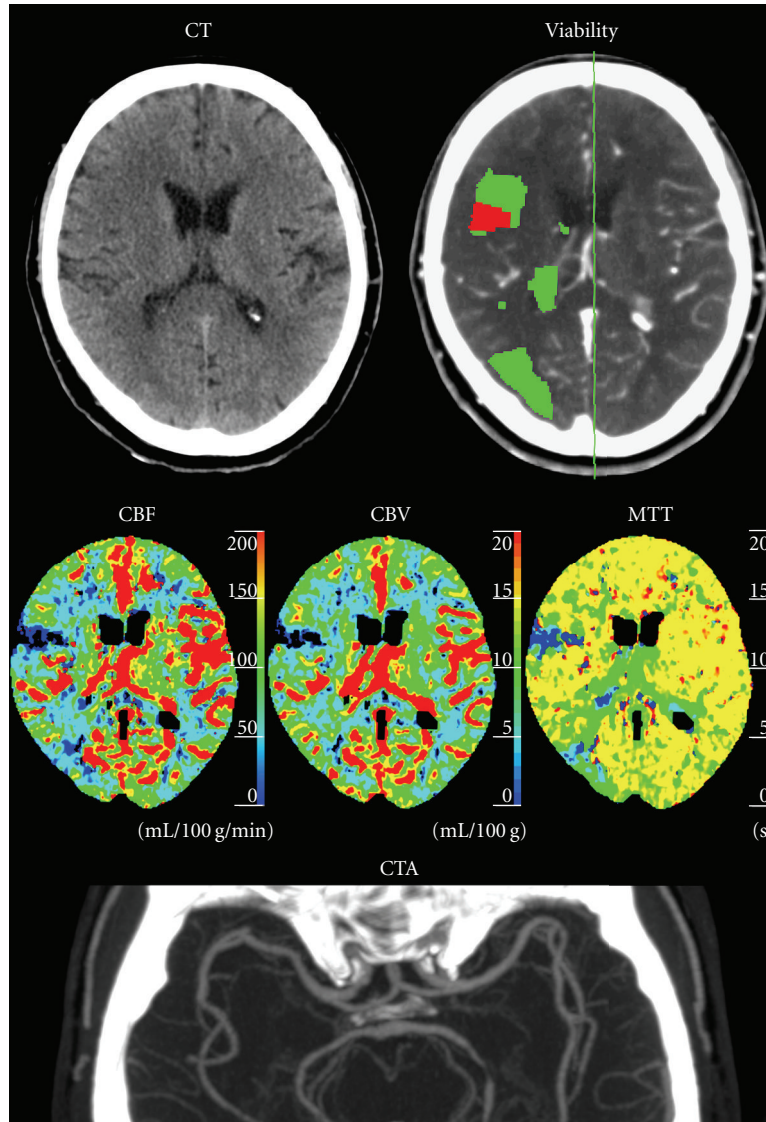


FIGURE 5: Case 2: 65-year-old male left-sided stroke symptoms and a normal NECT. The CTP viability map shows multiple perfusion defects (green) and a small area of advanced perfusion deficit (red) in the right hemisphere consistent with fragmented cardiogenic embolism. The CTA showed no major arterial occlusion obviating neurointervention.

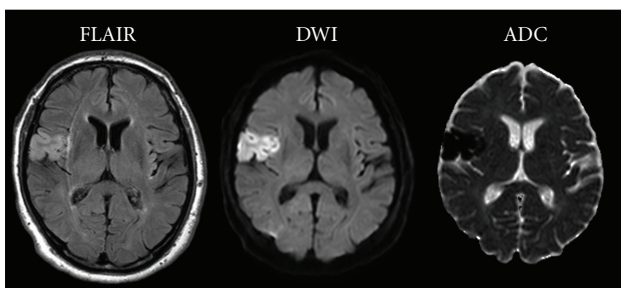


FIGURE 6: Case 2: follow-up MRI with FLAIR, DWI, and ADC showing an established infarction in the right frontal lobe matching the CTP-delineated ischemic core.

as in case 1 [14–16]. Results from meta-analysis have shown a recanalization rate for IV-thrombolysis of about 46%, while

IA-thrombolysis and mechanic thrombectomy have recanalization rates of about 63% and 84%, respectively, [17].

Moreover the information from the CTP might introduce some flexibility to the currently fixed therapeutic time window and increase safety when the time of onset is unknown (Case 4).

Recently the time frame for treatment with IV thrombolysis was extended from 3 hours after symptom onset [3–7] to 4.5 hours [8, 9], while the time frame for IA thrombolysis remains 6 hours after symptom onset [18, 19].

In some instances the CTP can reveal the underlying pathological process as in case 2 where the patient had multiple small ischemic regions in both the anterior and posterior circulation consistent with fragmented cardiac emboli without major vessel occlusion, excluding treatment with thrombectomy or IA thrombolysis.

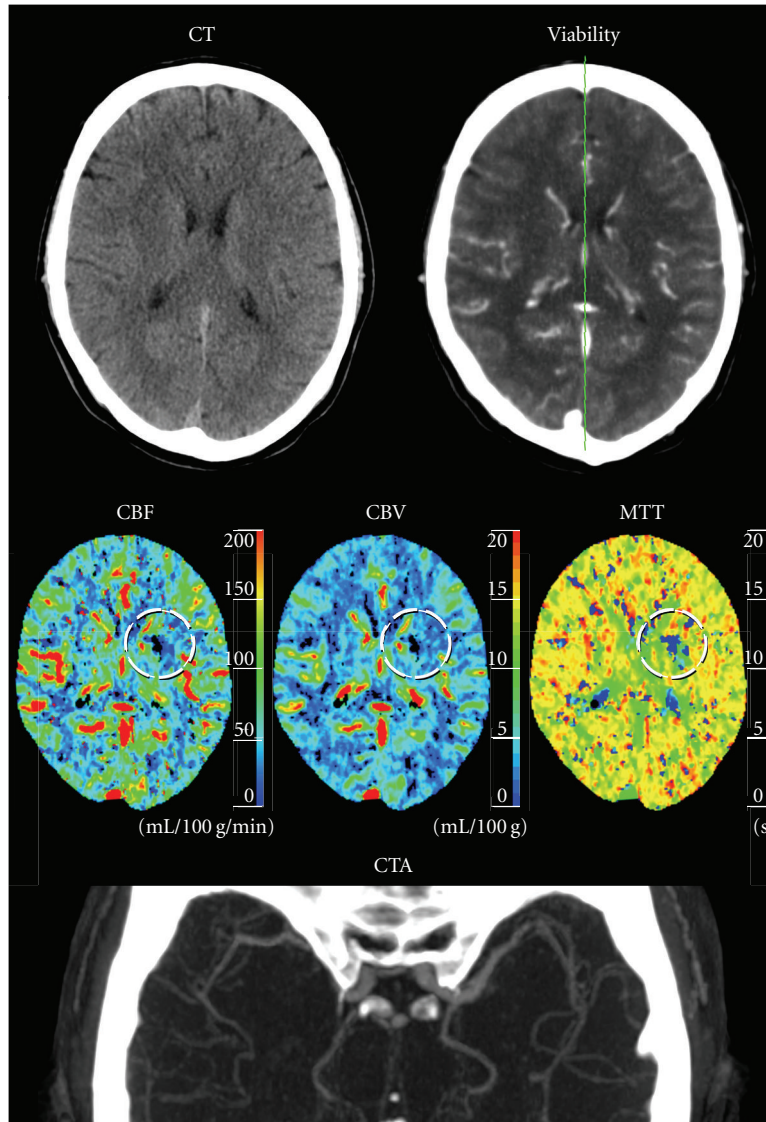


FIGURE 7: Case 3: 49-year-old male with right sided stroke symptoms and a normal NECT. The CTP source images show a small perfusion deficit in the left corona radiata with a marked decrease of both CBF and CBV (circle) that was initially missed by both the radiologist and the automated viability map software. CTA was normal.

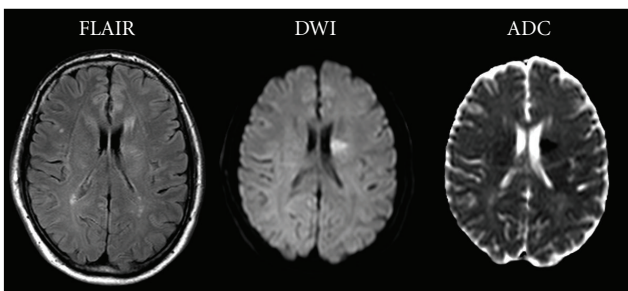


FIGURE 8: Case 3: Follow-up MRI with FLAIR, DWI and ADC showing a small lacunar infarction in the right corona radiata that is also seen retrospectively on the CTP maps (Figure 7).

Still studies on the clinical application of CTP results are lacking so even though the comprehensive CT examination

is promising in many ways the impact of the method on the clinical outcome is yet unknown.

4.2. MRI versus CT in Acute Ischemic Stroke. DWI/MRP is currently the gold standard for infarct evaluation in acute ischemic stroke because of the superiority of DWI in assessing tissue viability [20, 21], despite some disadvantages and pitfalls [22]. CTP provides useful information about the existence and grade of perfusion deficit providing equivalent information to the combined MR DWI, ADC, and MRP sequences [23]. Furthermore it has been shown that CTP can distinguish salvageable penumbra from nonsalvageable ischemic core with good correlation with follow-up DWI [12, 23, 24]. CTA provides information about the location of large arterial occlusion and is helpful in deciding on a therapeutic approach with IV or IA thrombolysis, and/or thrombectomy.

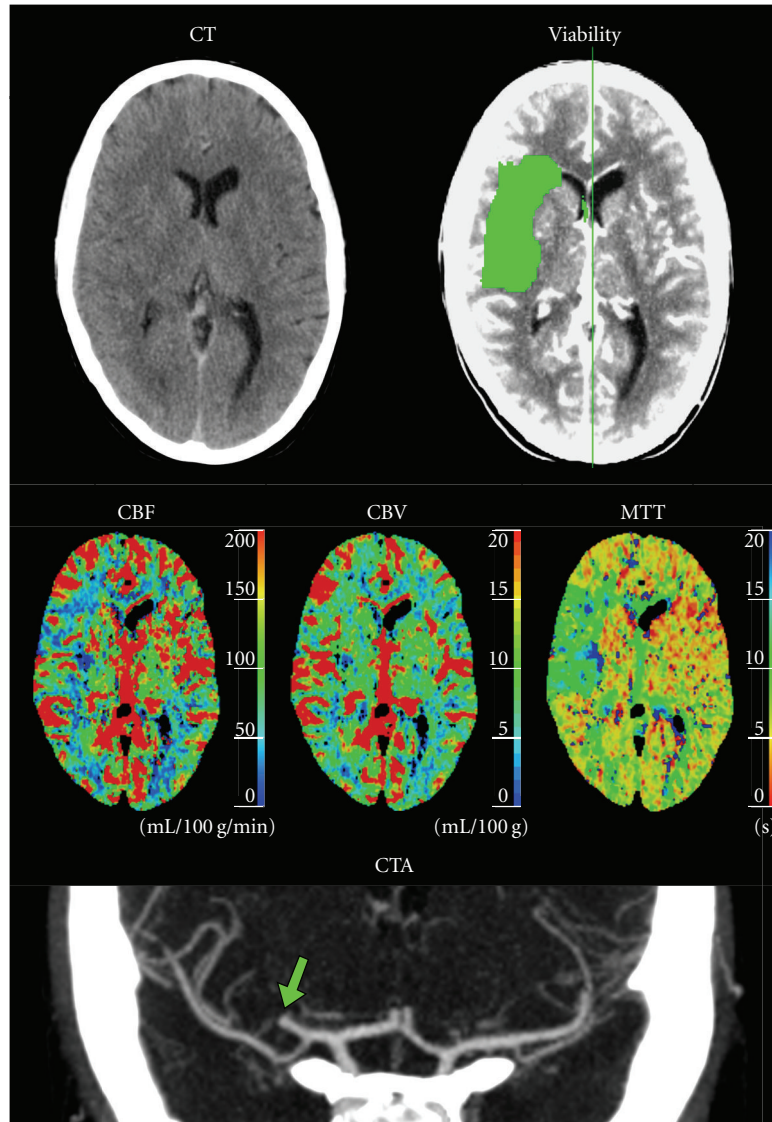


FIGURE 9: Case 4: 27-year-old woman with left-sided stroke symptoms of unknown onset and a normal NECT. The CTP viability map showed no ischemic core but a relatively large penumbra (green) in the right basal ganglia caused by a M2-segment MCA occlusion (arrow) seen on the CTA.

Using perfusion data to assess tissue viability as in CTP is inherently inaccurate because the result of disturbed perfusion is both tissue- and time-dependent. The color coded infarct core (red) and surrounding penumbra (green) in CTP-viability maps is therefore merely a rough estimate on the current status of a dynamic process [11]. Part of the CTP infarct core might prove to be viable tissue if the blood flow is quickly restored and part of the penumbra may become infarcted later in the process.

Nevertheless, CTP has over the last years gained acceptance as an alternative examination to DWI/MRP in the acute phase of ischemic stroke, mostly because of technical and practical advantages. It offers faster examination time and more effective workflow since it can be done in continuity with the standard NECT examination. It has been estimated that approximately 1.9 million neurons are lost every minute following the occlusion of a major cerebral artery [25].

Fast radiological diagnosis is essential for early treatment initiation. If everything runs smoothly the complete radiological examination described in this paper takes less than 10 minutes including a preliminary evaluation, which is in agreement with other authors [23], and it does not delay treatment initiation because the two are carried out as parallel processes.

Additionally CTP is more robust than MRP because it offers quantitative measurement of perfusion with higher spatial resolution and a linear relationship between contrast concentration and attenuation [26]. This together with shorter examination time, greater availability, and lower cost makes CTP an attractive method in the acute setting in cases where IA thrombolysis is a possible treatment option.

Until recently a major disadvantage of CTP has been the limited coverage of the examination whereas DWI covers the whole brain. Common CTP techniques offer only 4–8 cm



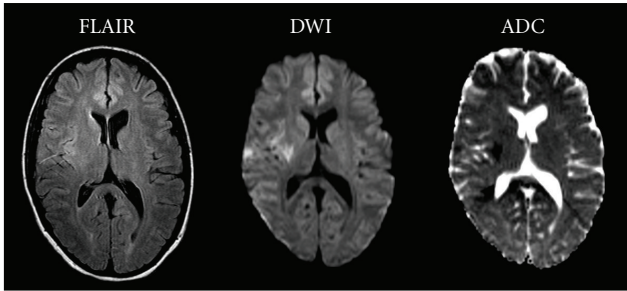


FIGURE 10: Case 4: acute MRI with FLAIR, DWI and ADC showing an established infarction in the right basal ganglia that was not detected by the CTP examination.

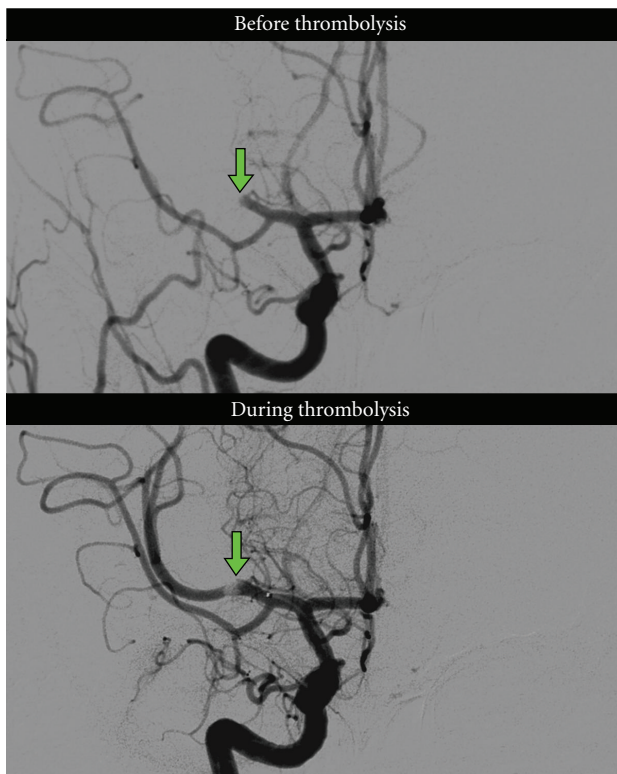


FIGURE 11: Case 4: DSA images from the right anterior cerebral circulation before recanalization showed an occluded right MCA M2-segment. During IA-thrombolysis partial revascularization was achieved with a remaining clot.

coverage, with the risk of small peripheral ischemic lesions being missed. This problem has now been overcome with the availability of 320 slice MDCT with 16 cm coverage [27]. Extended CTP coverage and increased sampling frequency linearly increases the radiation dose. The estimated effective dose equivalent of the comprehensive acute stroke protocol described in this paper amounts to 8.5 mSv (2.2 + 1.7 + 4.6) which is in agreement with other studies [28] and reasonable considering the added value for treatment individualization in this serious acute disease. Only 20% of the total effective dose in the comprehensive protocol can be attributed to the CTP examination.

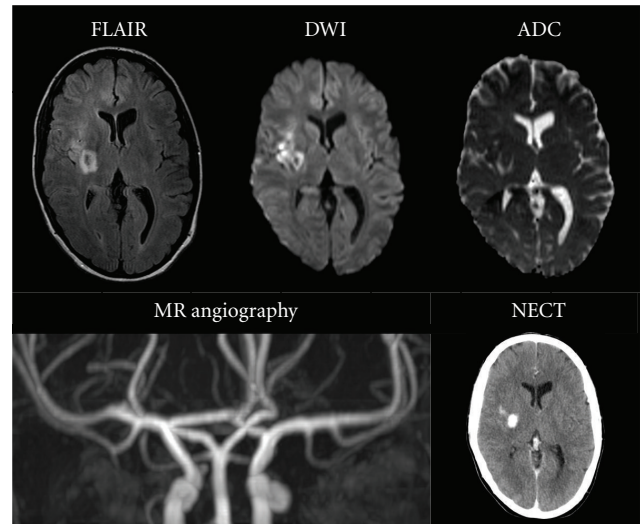


FIGURE 12: Case 4: follow-up MRI with FLAIR, DWI, ADC showing a relatively small infarction with minor hemorrhage in the right basal ganglia in comparison to the large penumbra seen on the initial CTP examination. The MRA shows complete recanalization of the previously partially revascularized right MCA. NECT shows a small hemorrhagic transformation in the right basal ganglia and parenchymal contrast leakage due to increased permeability secondary to ischemia and neurointervention.

Interpretation of the DWI images in ischemic stroke is generally simple. Misinterpretation of data in CTP can be an obstacle for the novice reader, particularly when relying overly on the computer generated viability map. The CTP software used in our study automatically generates a viability map by comparing the two hemispheres and searching for asymmetric perfusion. Therefore, the software does not detect bilateral symmetric lesions for example in patients with older lesions in the contralateral hemisphere. Furthermore, to reduce noise, the viability map has a size threshold preventing automatic detection of tiny lesions (case 3). Misinterpretation can be avoided by understanding and thoroughly reviewing the basic perfusion images and comparing them with the anatomical images from the NECT and CTA.

When NECT is used as the only radiological base for treatment decision in clinically suspected acute ischemic stroke, it may in some cases be unclear what pathophysiological process actually is being treated. The comprehensive CT examination aims at guiding stroke management in the acute setting, possibly allowing for patient stratification and individualized treatment strategies with improved clinical outcome.

## 5. Conclusion

This extended case review shows the potential of combined NECT, CTP and CTA as a fast and safe diagnostic method allowing more accurate diagnosis and making way for early individualized treatment in acute ischemic stroke. However,

the method has not yet been systematically evaluated in studies with high evidence class.

## References

- [1] P. A. Ringleb, M. G. Bousser, G. Ford et al., "Guidelines for management of ischaemic stroke and transient ischaemic attack 2008," *Cerebrovascular Diseases*, vol. 25, no. 5, pp. 457–507, 2008.
- [2] H. P. Adams Jr., G. Del Zoppo, M. J. Alberts et al., "Guidelines for the early management of adults with ischemic stroke: a guideline from the American heart association/American stroke association stroke council, clinical cardiology council, cardiovascular radiology and intervention council, and the atherosclerotic peripheral vascular disease and quality of care outcomes in research interdisciplinary working groups," *Stroke*, vol. 38, no. 5, pp. 1655–1711, 2007.
- [3] J. R. Marler, "Tissue plasminogen activator for acute ischemic stroke," *New England Journal of Medicine*, vol. 333, no. 24, pp. 1581–1587, 1995.
- [4] W. Hacke, M. Kaste, C. Fieschi et al., "Intravenous thrombolysis with recombinant tissue plasminogen activator for acute hemispheric stroke: the European Cooperative Acute Stroke Study (ECASS)," *Journal of the American Medical Association*, vol. 274, no. 13, pp. 1017–1025, 1995.
- [5] W. Hacke, M. Kaste, C. Fieschi et al., "Randomised double-blind placebo-controlled trial of thrombolytic therapy with intravenous alteplase in acute ischaemic stroke (ECASS II)," *Lancet*, vol. 352, no. 9136, pp. 1245–1251, 1998.
- [6] W. M. Clark, S. Wissman, G. W. Albers, J. H. Jhamandas, K. P. Madden, and S. Hamilton, "Recombinant tissue-type plasminogen activator (Alteplase) for ischemic stroke 3 to 5 hours after symptom onset the ATLANTIS study: a randomized controlled trial," *Journal of the American Medical Association*, vol. 282, no. 21, pp. 2019–2026, 1999.
- [7] W. Hacke, G. Donnan, C. Fieschi et al., "Association of outcome with early stroke treatment: pooled analysis of ATLANTIS, ECASS, and NINDS rt-PA stroke trials," *Lancet*, vol. 363, no. 9411, pp. 768–774, 2004.
- [8] W. Hacke, M. Kaste, E. Bluhmki et al., "Thrombolysis with alteplase 3 to 4.5 hours after acute ischemic stroke," *New England Journal of Medicine*, vol. 359, no. 13, pp. 1317–1329, 2008.
- [9] N. Wahlgren, N. Ahmed, A. Dávalos et al., "Thrombolysis with alteplase 3-4.5 h after acute ischaemic stroke (SITS-ISTR): an observational study," *The Lancet*, vol. 372, no. 9646, pp. 1303–1309, 2008.
- [10] T. Brott, H. P. Adams, C. P. Olinger et al., "Measurements of acute cerebral infarction: a clinical examination scale," *Stroke*, vol. 20, no. 7, pp. 864–870, 1989.
- [11] M. Wintermark, P. Maeder, J. P. Thiran, P. Schnyder, and R. Meuli, "Quantitative assessment of regional cerebral blood flows by perfusion CT studies at low injection rates: a critical review of the underlying theoretical models," *European Radiology*, vol. 11, no. 7, pp. 1220–1230, 2001.
- [12] M. Wintermark, A. E. Flanders, B. Velthuis et al., "Perfusion-CT assessment of infarct core and penumbra: receiver operating characteristic curve analysis in 130 patients suspected of acute hemispheric stroke," *Stroke*, vol. 37, no. 4, pp. 979–985, 2006.
- [13] H. D. Nagel, *Radiation Exposure in Computer Tomography*, CTB, Hamburg, Germany, 4th edition, 2002.
- [14] C. A. Lewandowski, M. Frankel, T. A. Tomsick et al., "Combined intravenous and intra-arterial r-TPA versus intra-arterial therapy of acute ischemic stroke: emergency management of stroke (EMS) bridging trial," *Stroke*, vol. 30, no. 12, pp. 2598–2605, 1999.
- [15] J. Broderick, "Combined intravenous and intra-arterial recanalization for acute ischemic stroke: the Interventional Management of Stroke Study," *Stroke*, vol. 35, no. 4, pp. 904–911, 2004.
- [16] J. P. Broderick, "The interventional management of stroke (IMS) II study," *Stroke*, vol. 38, no. 7, pp. 2127–2135, 2007.
- [17] J. H. Rha and J. L. Saver, "The impact of recanalization on ischemic stroke outcome: a meta-analysis," *Stroke*, vol. 38, no. 3, pp. 967–973, 2007.
- [18] G. J. Del Zoppo, R. T. Higashida, A. J. Furlan, M. S. Pessin, H. A. Rowley, and M. Gent, "PROACT: a phase II randomized trial of recombinant pro-urokinase by direct arterial delivery in acute middle cerebral artery stroke," *Stroke*, vol. 29, no. 1, pp. 4–11, 1998.
- [19] A. Furlan, R. Higashida, L. Wechsler et al., "Intra-arterial prourokinase for acute ischemic stroke. The PROACT II study: a randomized controlled trial," *Journal of the American Medical Association*, vol. 282, no. 21, pp. 2003–2011, 1999.
- [20] M. E. Mullins, P. W. Schaefer, A. G. Sorensen et al., "CT and conventional and diffusion-weighted MR imaging in acute stroke: study in 691 patients at presentation to the emergency department," *Radiology*, vol. 224, no. 2, pp. 353–360, 2002.
- [21] R. G. González, P. W. Schaefer, F. S. Buonanno et al., "Diffusion-weighted MR imaging: diagnostic accuracy in patients imaged within 6 hours of stroke symptom onset," *Radiology*, vol. 210, no. 1, pp. 155–162, 1999.
- [22] C. S. Kidwell, J. L. Saver, J. Mattiello et al., "Thrombolytic reversal of acute human cerebral ischemic injury shown by diffusion/perfusion magnetic resonance imaging," *Annals of Neurology*, vol. 47, no. 4, pp. 462–469, 2000.
- [23] M. Wintermark, R. Meuli, P. Browaeys et al., "Comparison of CT perfusion and angiography and MRI in selecting stroke patients for acute treatment," *Neurology*, vol. 68, no. 9, pp. 694–697, 2007.
- [24] P. Schramm, P. D. Schellinger, E. Klotz et al., "Comparison of perfusion computed tomography and computed tomography angiography source images with perfusion-weighted imaging and diffusion-weighted imaging in patients with acute stroke of less than 6 hours' duration," *Stroke*, vol. 35, no. 7, pp. 1652–1657, 2004.
- [25] J. L. Saver, "Time is brain—quantified," *Stroke*, vol. 37, no. 1, pp. 263–266, 2006.
- [26] M. Wintermark, M. Reichhart, O. Cuisenaire et al., "Comparison of admission perfusion computed tomography and qualitative diffusion- and perfusion-weighted magnetic resonance imaging in acute stroke patients," *Stroke*, vol. 33, no. 8, pp. 2025–2031, 2002.
- [27] E. Siebert, G. Bohner, M. Dewey et al., "320-Slice CT neuroimaging: initial clinical experience and image quality evaluation," *British Journal of Radiology*, vol. 82, no. 979, pp. 561–570, 2009.
- [28] M. Cohnen, H. J. Wittsack, S. Assadi et al., "Radiation exposure of patients in comprehensive computed tomography of the head in acute stroke," *American Journal of Neuroradiology*, vol. 27, no. 8, pp. 1741–1745, 2006.