



ELSEVIER

Contents lists available at [ScienceDirect](https://www.sciencedirect.com)

Trauma Case Reports

journal homepage: www.elsevier.com/locate/tcr

Case Report

Spontaneous improvement of levator palpebrae superioris function after traumatic transection

Craig Czyz^{a,b,1}, Kyle Blair^{a,*},¹^a Division of Ophthalmology, Section Oculofacial Plastic and Reconstructive Surgery, Ohio University/OhioHealth Doctors Hospital, Columbus, OH, United States of America^b Department of Ophthalmology, Oral and Maxillofacial Surgery, Grant Medical Center, Columbus, OH, United States of America

ARTICLE INFO

Keywords:

Levator palpebrae superioris aponeurosis
 Traumatic transection
 Oculoplastic surgery
 Neurogenic ptosis

ABSTRACT

Direct traumatic injury to the levator palpebrae superioris aponeurosis typically results in upper eyelid ptosis. The mechanisms can involve mechanical or neurogenic etiologies. Prompt surgical exploration and repair are required for restoration of normal function. In cases where prompt surgical intervention is not performed or the levator palpebrae superioris aponeurosis cannot be repaired, the restorative options are limited. The options are further restricted by concurrent ipsilateral frontalis paresis. This report details a spontaneous return of levator function nine months after complete traumatic transection of the levator palpebrae superioris aponeurosis complicated by concurrent ipsilateral frontalis paresis.

Introduction

Direct traumatic injury to the levator palpebrae superioris aponeurosis (LPSA) usually leads to its disinsertion from the tarsal plate, and can result in complete upper eyelid ptosis [1]. In certain cases, the injury mechanism may damage the nerve supply to the levator and lead to neurogenic ptosis. Fibrosis during the healing phase can result in mechanical ptosis or decreased lid excursion. The most common causes of such injuries are trauma to the upper eyelid region and ocular or adnexal surgery [2]. When the etiology involves disinsertion of the LPSA, the general recommendation is prompt surgical exploration and repair before the onset of fibrotic changes that may complicate surgical restoration of normal function.

In cases where prompt surgical intervention is not performed or the LPSA cannot be repaired, the restorative options are limited. Some clinicians recommend taking a conservative approach and waiting 3–6 months post injury to the LPSA before considering repair [2]. This report details a spontaneous return of levator function nine months after complete traumatic transection of the LPSA. In addition, this particular case was complicated by concurrent ipsilateral frontalis paresis.

Case details

A 19-year-old female was the restrained passenger in a motor vehicle accident brought to a Level 1 Trauma Center for evaluation and treatment. Initial evaluation of the patient revealed complete avulsion of the tissues of the right cheek, upper eyelid, and forehead

* Corresponding author at: 50 Old Village Road, Columbus, OH 43228, United States of America.

E-mail address: kylecoxblair@yahoo.com (K. Blair).

¹ Institution of authors: OhioHealth Doctors Hospital, 5100 W Broad St., Columbus, OH 43228

<https://doi.org/10.1016/j.tcr.2020.100375>

Accepted 1 November 2020

Available online 4 November 2020

2352-6440/© 2020 The Authors. Published by Elsevier Ltd. This is an open access article under the CC BY-NC-ND license

(<http://creativecommons.org/licenses/by-nc-nd/4.0/>).

(Fig. 1). Primary repair of the cheek, eyelid, and forehead wounds was performed. The repair of the eyelid wound was done without exploration or reinsertion of the LPSA. After the repair, oculoplastics was consulted for evaluation of complete right upper eyelid ptosis.

External exam revealed significant edema of the right upper eyelid, with no eyelid crease present. There was right brow ptosis, with the patient unable to activate the frontalis on the right with normal contraction on the left. There was complete ptosis of the right upper eyelid (margin to reflex distance (MRD1)) –3.0 mm, vertical fissure (VF) 0 mm, with a levator function of 0 mm. The left upper eyelid had a MRD1 of 3.0 mm, VF of 8.0 mm, and levator function of 13 mm.

At the one-month follow up, the patient continued to have complete ptosis with no levator function (Fig. 2). Right brow ptosis and frontalis paresis was still present. The patient returned for a six-month follow up and continued to have complete right upper eyelid ptosis with no LF, brow ptosis, and frontalis paresis. Exploratory surgery was planned for the following week, but did not occur due to difficulty with patient scheduling. The patient returned three months later with improvement of the ptosis and levator function, but no improvement of brow ptosis or frontalis function. In the right eye, MRD1 was 2 mm with a vertical fissure of 7 mm. The left eye MRD1 was 4 mm and vertical fissure 9 mm. The levator function was 8 mm on the right and 13–14 mm on the left. The patient was concerned about the contour and position of the right upper eyelid compared to the left. External levator advancement and exploration was performed the following week with good intraoperative results (Fig. 3, Video 1). The patient gave informed consent for images and video of relating to her case to be used for lectures and/or publication.

Discussion

There are few reports of spontaneous traumatic ptosis improvement in the literature, with widely varying recovery times and etiologies. The reports include iatrogenic levator injury following orbital or ocular surgery and disruption of the levator innervation [3,4]. However, there are no reports of traumatic transection of the LPSA with spontaneous recovery of function.

In the majority of cases where traumatic interruption of the LPSA occurs, timely repair or identification of the LPSA is required to restore normal function [5]. In cases where repair is delayed and LPSA function cannot be resorted, treatment options are limited. Surgical exploration should be performed if mechanical ptosis or lid retraction is suspected due to tissue fibrosis or malposition of the LPSA. If levator function does not return, frontalis suspension can be performed in the same manner as commonly done for neurogenic ptosis.

In cases where ipsilateral frontalis function is also compromised, the surgical options are extremely limited. A modified frontalis suspension with conservative elevation and improvement of MRD1 could be performed. However, this may require long-term, aggressive treatment for paralytic lagophthalmos, such as frequent lubrication and nighttime taping. There is one report of a successful modified palpebral spring procedure to correct myogenic upper eyelid ptosis in place of a frontalis suspension [6]. However, the patient in this case had measurable levator function prior to surgery.

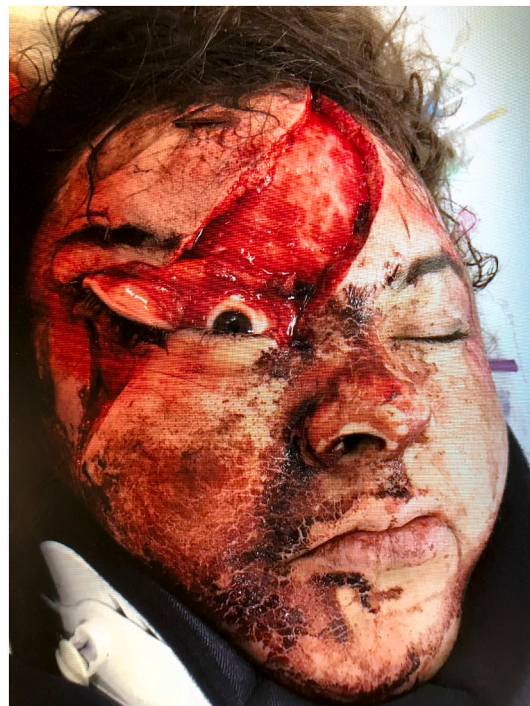

Fig. 1. Patient at time of initial presentation. There was near complete avulsion of the right upper eye lid resulting in transection of the LPSA.

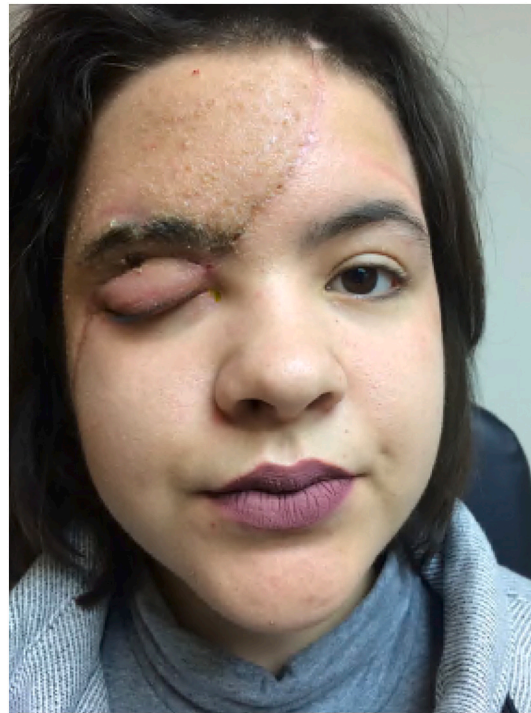

Fig. 2. Patient at one month follow up exam following direct repair of right upper eyelid avulsion without exploration for or repair of the LPSA, resulting in complete mechanical ptosis and no levator function.

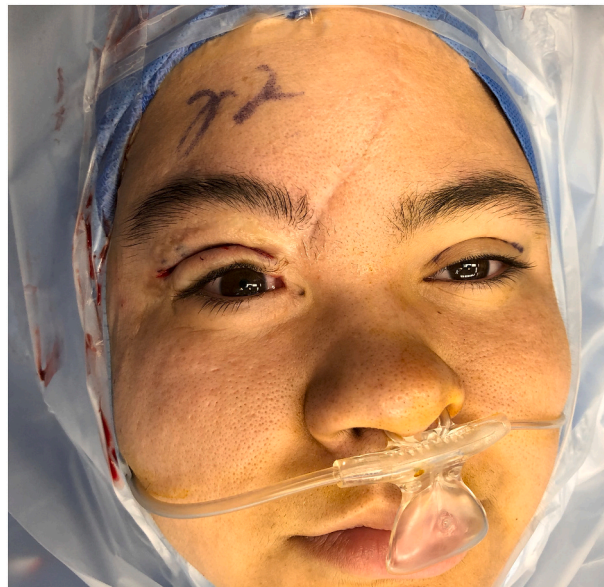


Fig. 3. Intraoperative image showing lid position and contour of right and left upper eyelids.

This patient's recovery of good levator function without intervention following LPSA transection provides evidence for delayed surgical intervention when primary repair is not performed in a timely manner. While there is no consensus as to the amount of time that should be given to assess whether levator function will return after LPSA interruption, this case shows the possibility of improvement sometime after 6 months. Premature intervention can result in unexpected lid position and potentially increased fibrosis, requiring additional surgery for correction.

Supplementary data to this article can be found online at <https://doi.org/10.1016/j.tcr.2020.100375>.

References

- [1] H. Fry, Late repair of divided levator palpebrae superioris, *Aust. N.Z. J. Surg.* 38 (1968) 58–59.
- [2] R.L. Arden, G.K. Moore, Complete post-traumatic ptosis: a mechanism for recovery? *Laryngoscope* 99 (1989) 1175–1179.
- [3] J.W. Jung, M.J. Chi, Temporal unilateral neurogenic blepharoptosis after orbital medial wall reconstruction: 3 cases, *Ophthalmologica* 222 (2008) 360–362; T.J. McCulley, R.C. Kersten, C.C. Yip, et al., Isolated unilateral neurogenic blepharoptosis secondary to eyelid trauma, *Am J. Ophthalmol.* 134 (2002) 626–627.
- [4] K. Satchi, A. Kumar, A.A. McNa, Isolated traumatic neurogenic ptosis with delayed recovery, *Ophthal. Plast. Reconstr. Surg.* 30 (2014) 57–59.
- [5] L.T. Jones, M.H. Quickert, J.L. Wobig, The cure of ptosis by aponeurotic repair, *Arch. Ophthalmol.* 93 (1975) 629–634.
- [6] A. Fay, Y.M. Santiago, A modified levine palpebral spring for the treatment of myogenic ptosis, *Ophthalmic Plast. Reconstr. Surg.* (2012) 372–375.