

# Unilateral orchiectomy of a testicular adrenal rest tumor: Case report and review of management options

Corey Able<sup>a</sup>, Brian Liao<sup>a</sup>, Elias Farran<sup>b</sup>, Abdul Majeed Abid<sup>c</sup>, Bilal Farhan<sup>b,\*</sup>

<sup>a</sup> School of Medicine, University of Texas Medical Branch, 301 University Blvd, Galveston, TX, 77555, USA

<sup>b</sup> Department of Surgery, Division of Urology, University of Texas Medical Branch, 301 University Blvd, Galveston, TX, 77555, USA

<sup>c</sup> Department of Pathology, University of Texas Medical Branch, 301 University Blvd, Galveston, TX, 77555, USA

## ARTICLE INFO

### Keywords:

Testicular adrenal rest tumor  
Leydig cell tumor  
Orchiectomy  
Infertility

## ABSTRACT

Testicular adrenal rest tumors are a rare development of patients with congenital adrenal hyperplasia. It is difficult to diagnose due to similarities with Leydig cell tumors. Treatment can be conservative or surgical. We describe the case of a 56 year old male presenting with bilateral testicular pain and irregular growth that was managed with a unilateral orchiectomy. We analyzed the distinguishing factors of testicular adrenal rest tumors compared to Leydig cell tumors, as well as the diagnostic and treatment methods.

## 1. Introduction

Testicular adrenal rest tumors (TARTs) are a manifestation of congenital adrenal hyperplasia (CAH).<sup>1</sup> CAH has a prevalence of less than 0.1% and is characterized by hyperplasia of the adrenal cortex due to defective enzymes in the cortisol synthesis pathway, including 21-alpha hydroxylase (90–95%), 11-B hydroxylase (5%), and 17-alpha hydroxylase (<1%).<sup>1</sup> Without negative feedback of cortisol, cholesterol precursors are shunted into the androgen pathway, causing precocious puberty and hyperplasia of ACTH sensitive tissues such as the testicular parenchyma. Rapid, uncontrolled growth of the testicular parenchyma can develop into a TART, which is found in up to 94% of male patients with CAH.<sup>1</sup>

It is difficult to distinguish a TART from a Leydig Cell Tumor (LCT). Both LCTs and TARTs are testicular masses associated with precocious puberty and infertility.<sup>2</sup> While TARTs are benign, it is imperative to differentiate the mass from malignancies such as LCTs.<sup>2</sup> In this case report, we present a patient with CAH and painful, bilateral steroid-resistant testicular masses.

## 2. Case report

We present the case of a 56-year old male with CAH presenting for a right testicular mass. The right testicle was irregularly shaped and larger than the left testicle. The right testicle caused discomfort at rest and was tender to light palpation. The left testicle was not painful and normal in

contour. The patient was currently taking hydrocortisone 10mg twice daily and fludrocortisone 0.1 mg once daily.

Ultrasonography of the testicles was performed. The right testicle displayed a 0.5 × 0.9 × 0.8 cm heterogeneous, hypochoic mass along the mediastinum testis (Fig. 1). The left testicle displayed a heterogeneous, hypochoic structure measuring 0.5 × 0.5 × 0.4 cm. The volume of the right and left testicles measured 6.3 mL and 5.8 mL, respectively.

The patient was lost to follow up for 10 months. At the next visit, the patient reported progression of symptoms, now experiencing constant, bilateral pain. The mass on the right testicle had increased in size and the mass on the left testicle was now grossly visible. A CT performed earlier that month displayed no lymph node involvement. A repeat ultrasound was performed, which revealed a 16 × 14 × 15 mm heterogeneous, hypochoic mass with clear boundaries on the right testicle along the mediastinum testis and a 9 × 8 × 7 mm heterogeneous, hypochoic mass with clear boundaries on the left testicle along the mediastinum testis. The right and left testicles were now measured to be 11.4 mL and 12.7 mL, respectively. There was a rich vascular supply and no calcifications bilaterally.

Due to the increase in pain and the potential of malignancy, the patient elected for right radical orchiectomy. A right inguinal incision was made, and the testicle delivered. Upon intra-op examination of the testicle, there were multiple identifiable firm 4 mm × 4 mm testicular masses. There was a yellow-brown mass on the superior rete testis and hilum. Pathology of the specimen (Figs. 2 and 3) revealed sheets, nests, lobules and cords of eosinophilic cells with enlarged nuclei, prominent

\* Corresponding author. 301 University Blvd, Galveston, TX, 77555, USA.

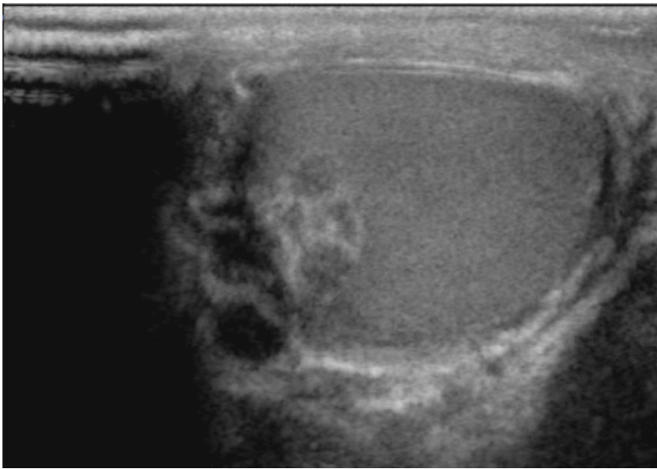
E-mail address: [bifarhan@utmb.edu](mailto:bifarhan@utmb.edu) (B. Farhan).

<https://doi.org/10.1016/j.eucr.2022.102247>

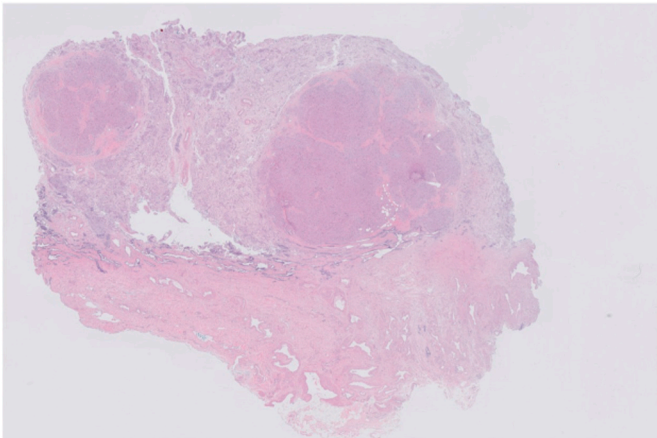
Received 14 August 2022; Received in revised form 19 September 2022; Accepted 23 September 2022

Available online 26 September 2022

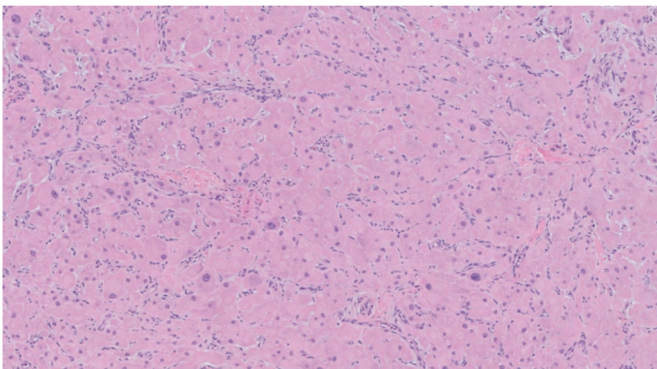
2214-4420/© 2022 Published by Elsevier Inc. This is an open access article under the CC BY-NC-ND license (<http://creativecommons.org/licenses/by-nc-nd/4.0/>).



**Fig. 1.** Ultrasonography displaying a 16 × 14 × 15 mm heterogeneous, hypoechoic mass with clear boundaries on the right testicle along the mediastinum testis.



**Fig. 2.** (Low power, 2X): The section demonstrates two circumscribed masses, without encapsulation, in the background of atrophic testes.



**Fig. 3.** (High power 20 X): Tumor cells are arranged in sheets, have eosinophilic cytoplasm and frequently pleomorphic nuclei. There is lymphocytic infiltrate interspersed between the tumor cells.

nucleoli with scattered atypia that were separated by fibrous bands and lymphocytes. The cytoplasm shows golden-brown pigment, consistent with lipochrome pigment. Adipocytic metaplasia is noted. No evidence of Reinke crystals seen. The specimen was stained, testing positive for CD 56, synaptophysin, inhibin, and calretinin.

After 1 month, the patient did not endorse any complications. Visually, the left testicle decreased in size. The pain in the retained testicle resolved less than a week after surgery. There were no reported lower urinary tract symptoms. The patient continued to follow up with endocrinology to manage the hydrocortisone and fludrocortisone treatment.

### 3. Discussion

There is only one case reported in which bilateral TARTs were treated with a unilateral orchiectomy.<sup>3</sup> Unlike our case, this patient did not have any pain and the only symptom was infertility. Additionally, the testicles were atrophied, in contrast to the hypertrophy noted in our case. To our knowledge, we present the only case in which painful, bilateral TARTs were treated with a unilateral orchiectomy, resulting in symptom resolution and size reduction in contralateral testicle mass.

Ultrasonography remains the primary diagnostic tool to detect TARTs due to its high sensitivity, accessibility and low cost.<sup>4</sup> TART characteristics on ultrasound are well described in the literature: 77% are bilateral, 90–94% are hypoechoic, and 76% demonstrate rich vascularity.<sup>4</sup> Lesions usually present in the mediastinum, show clear boundaries, and are either round or lobulated in nature. Such findings are non-specific to TARTs, making it hard to differentiate from malignancies and should be confirmed with biopsy. Distinguishing identifiers of TARTs include CD56, inhibin, vimentin, DLK1, synaptophysin, CYP11B1, and MC2R, while LCTs include Reinke's Crystals (60%) and INSL3.<sup>2,4</sup>

Current treatments for TARTs aim to restore fertility in adult patients. High-dose glucocorticoids reduce systemic ACTH levels and subsequently minimize the TART mass. However, glucocorticoids have negative side effects, including hypertension, dermal striation, and weight gain.<sup>4</sup> Additionally, steroid therapy inconsistently reduces tumor size, with studies finding reduction in 64–75% of cases.<sup>4</sup> Although controlling ACTH levels with glucocorticoid therapy is the primary mechanism in resolving TART-related infertility, treatment may be limited by irreversible fibrosis of the seminiferous tubules and persistent alterations of testicular hormones.

At the initial visit, our patient was already taking near the maximum recommended dose of oral steroids, limiting treatment options at the second visit. A testes-sparing orchiectomy may be considered when TART mass, azoospermia, and oligospermia fail to respond to steroid therapy. A biopsy should assess the quantity of functional testicular parenchyma prior to surgery.<sup>5</sup> If functional tissue is found, then a testes-sparing orchiectomy can restore fertility. However, conflicting information was presented by Claahsen-van et al. in which there was no improvement in pituitary-gonadal function in six of seven (85.7%) patients.<sup>5</sup> All patients continued to have azoospermia or oligospermia and low inhibin B concentrations.<sup>5</sup> Only two patients noted a disappearance of the testicular pain and discomfort. Such findings suggest that testes-sparing orchiectomy may be inefficient to treat pain and infertility.

### Funding

There was no funding for this manuscript.

### Attestation statement

The subjects in this trial have not concomitantly been involved in other randomized trials. Data regarding any of the subjects in the study has not been previously published unless specified. Data will be made available to the editors of the journal for review or query upon request.

### Data sharing statement

All data is available in the article and there are no restrictions on the

use of the data.

## References

1. Roberts EC, Nealon SW, Dhillon J, Tourtelot JB, McIver B, Sexton WJ. Bilateral testicular adrenal rest tumors in a patient with nonclassical congenital adrenal hyperplasia. *IJU Case Rep.* 2021 May 3;4(4):243–246. <https://doi.org/10.1002/iju5.12299>. PMID: 34258539; PMCID: PMC8255286.
2. Entezari P, Kajbafzadeh AM, Mahjoub F, Vasei M. Leydig cell tumor in two brothers with congenital adrenal hyperplasia due to 11- $\beta$  hydroxylase deficiency: a case report. *Int Urol Nephrol.* 2012 Feb;44(1):133–137. <https://doi.org/10.1007/s11255-010-9890-9>. Epub 2011 Jan 23. PMID: 21259051.
3. Rohayem J, Tüttelmann F, Mallidis C, Nieschlag E, Kliesch S, Zitzmann M. Restoration of fertility by gonadotropin replacement in a man with hypogonadotropic azoospermia and testicular adrenal rest tumors due to untreated simple virilizing congenital adrenal hyperplasia. *Eur J Endocrinol.* 2014;170(4). <https://doi.org/10.1530/eje-13-0449>.
4. Engels M, Span PN, van Herwaarden AE, Sweep F, Stikkelbroeck N, Claahsen-van der Grinten HL. Testicular adrenal rest tumors: current insights on prevalence, characteristics, origin, and treatment. *Endocr Rev.* 2019;40(4):973–987. <https://doi.org/10.1210/er.2018-00258>.
5. Claahsen-van der Grinten HL, Otten BJ, Takahashi S, et al. Testicular adrenal rest tumors in adult males with congenital adrenal hyperplasia: evaluation of pituitary-gonadal function before and after successful testis-sparing surgery in eight patients. *J Clin Endocrinol Metab.* 2007;92(2):612–615. <https://doi.org/10.1210/jc.2006-1311>.