

# Use of computed tomography-guided biopsy to detect *Peptostreptococcus micros*-induced mycotic abdominal aortic aneurysm after endovascular repair

Tomoya Takigawa, MD, Hironori Baba, MD, Manabu Hisahara, MD, Yusuke Ando, MD, Yoshie Ochiai, MD, and Shigehiko Tokunaga, MD, Fukuoka, Japan

## ABSTRACT

Mycotic aortic aneurysm (MAA) is rare but lethal. Detection of the causative bacteria is important for successful treatment. In some cases, however, no micro-organisms are detected by repeated blood cultures. Open surgery is the standard procedure for MAA, but endovascular intervention is also performed. An aneurysm specimen cannot be taken for culture when using an endovascular approach, decreasing the opportunity to detect the causative organism. We performed successful endovascular repair in a rare case of a *Peptostreptococcus micros*-induced MAA as detected by postoperative computed tomography-guided biopsy. This case may help to establish appropriate medical treatment for MAAs. (J Vasc Surg Cases and Innovative Techniques 2019;5:477-80.)

**Keywords:** Mycotic aneurysm; Endovascular; Stent graft; *Peptostreptococcus micros*; Computed tomography-guided biopsy

Mycotic aortic aneurysm (MAA) is an uncommon and high-risk lesion. Many bacterial species may cause MAA, but *Peptostreptococcus micros* has been reported as the causative agent in only one case.<sup>1</sup> Successful treatment of MAA requires detection of the causative bacteria.

Surgical intervention has been established as the traditional therapeutic procedure for MAA. Recent studies have suggested that endovascular aortic repair (EVAR) is a sufficient alternative treatment in limited cases,<sup>2-4</sup> but a drawback of the endovascular approach is that tissue samples cannot be obtained for culture.

Computed tomography (CT)-guided biopsy enables acquisition of the infective aortic wall of the MAA, and examination of such a biopsy specimen can provide critical information for treatment of MAA. We herein report a rare case of successful endovascular repair of a *P micros*-induced MAA that was detected by CT-guided biopsy after EVAR. We obtained the patient's consent to use his details and images for publication of this report.

## CASE REPORT

A 68-year-old man presented to our hospital with a 3-month history of fever (>38°C), abdominal pain, and a weight loss of 8 kg. His comorbidities were poorly controlled diabetes mellitus (hemoglobin A1c concentration of 7.1%), periodontitis, and chronic atrial fibrillation. A contrast-enhanced CT scan was performed to identify the focus of the fever and incidentally showed a saccular pseudoaneurysm at the terminal aorta within an encapsulated low-density area (Fig 1). The maximum short diameter of the aneurysm was 16 mm. Blood examination findings were suggestive of inflammation after infection: white blood cell count, 11,300 cells/ $\mu$ L; C-reactive protein, 12.49 mg/dL; procalcitonin, 0.116 ng/mL; immunoglobulin G and G4, 2265 and 116 mg/dL, respectively; and interleukin-2 receptor, 697 U/mL. Both preoperative blood cultures and interferon-gamma release assay of tuberculosis were negative. The differential diagnoses were an MAA, an inflammatory aneurysm, retroperitoneal fibrosis, malignant lymphoma, or metastasis from a malignant tumor.

The saccular pseudoaneurysm seemed to be at high risk of rupture. If the aneurysm had been an inflammatory aortic aneurysm or an aortic aneurysm with periaortic malignant lymphoma, open repair would have been complicated, requiring careful handling because of periaortic and retroperitoneal adhesions.<sup>5-7</sup> Therefore, we performed EVAR to avoid rupture before establishing a diagnosis. We were fully prepared for open repair as a second additional surgical intervention if needed. We also repeated the preoperative blood cultures and started broad-spectrum antibiotics (sulbactam sodium/ampicillin sodium at 3 g every 6 hours + gentamicin sulfate at 60 mg every 8 hours) because the aneurysm was suspected to be an MAA. We used a Gore Excluder AAA endoprosthesis (Gore Medical, Flagstaff, Ariz). The procedure was completed safely. After the operation, we confirmed the sealing of the stent graft and absence of endoleaks by CT angiography (Fig 2).

---

From the Department of Cardiovascular Surgery, Japan Community Health Care Organization Kyushu Hospital.

Author conflict of interest: none.

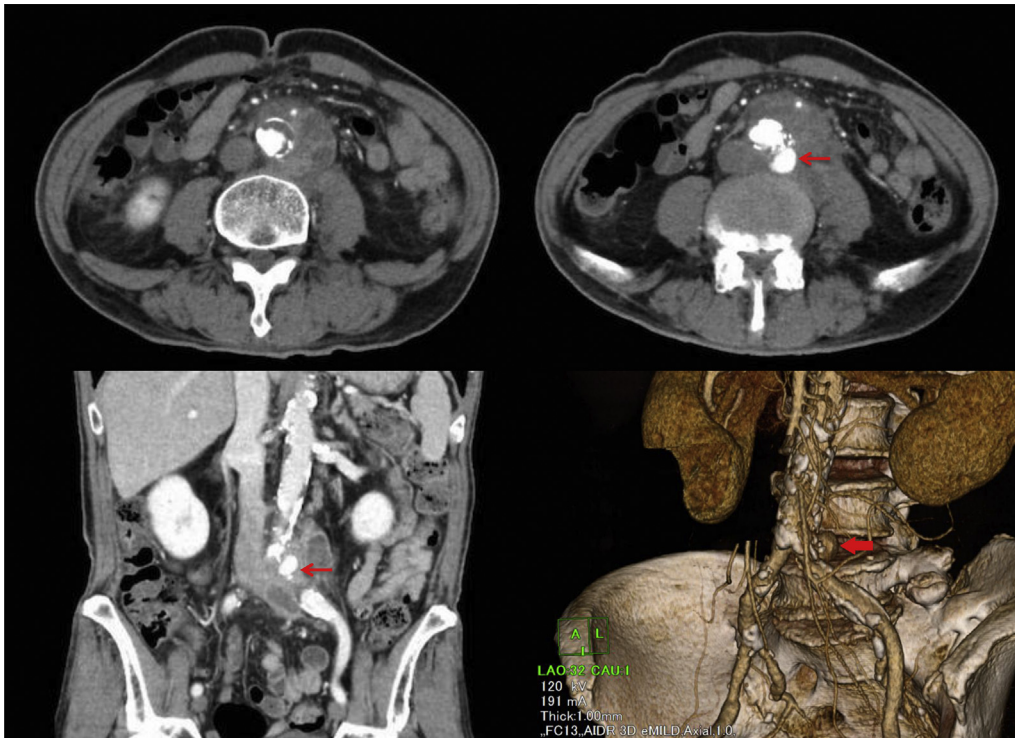
Correspondence: Tomoya Takigawa, MD, Department of Cardiovascular Surgery, Japan Community Health Care Organization Kyushu Hospital, 1-8-1 Kishinoura, Yahatanishi-ku, Kitakyushu City, Fukuoka 806-8501, Japan (e-mail: [tomoya0817cvs@gmail.com](mailto:tomoya0817cvs@gmail.com)).

The editors and reviewers of this article have no relevant financial relationships to disclose per the Journal policy that requires reviewers to decline review of any manuscript for which they may have a conflict of interest.

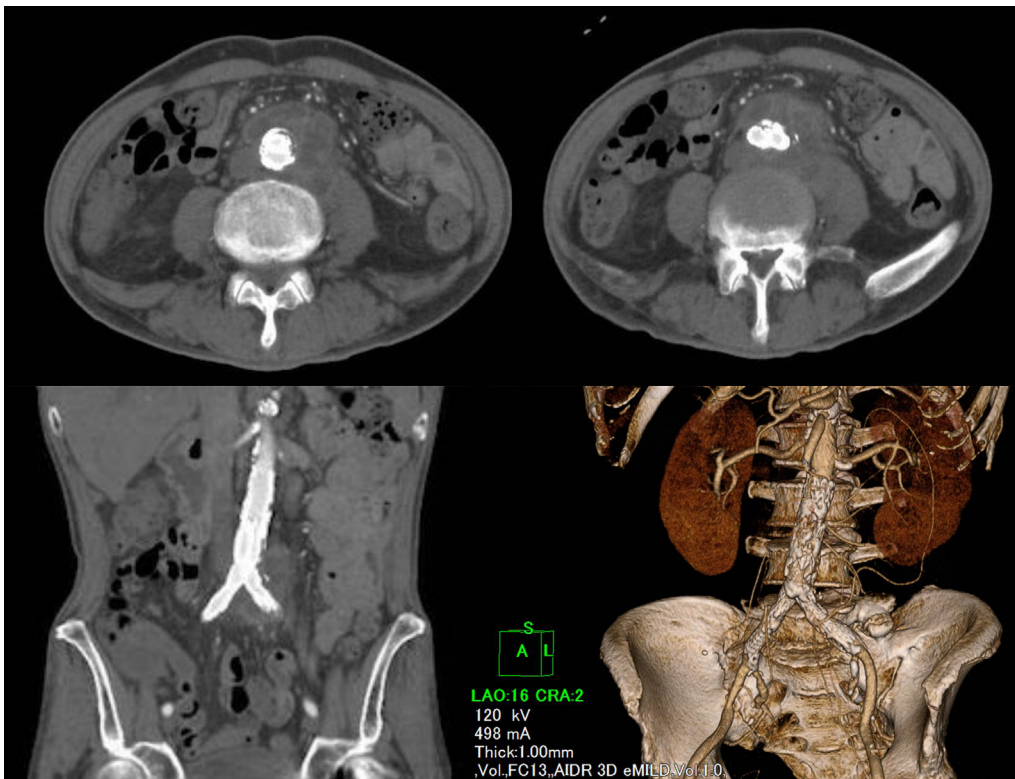
2468-4287

© 2019 The Author(s). Published by Elsevier Inc. on behalf of Society for Vascular Surgery. This is an open access article under the CC BY-NC-ND license (<http://creativecommons.org/licenses/by-nc-nd/4.0/>).

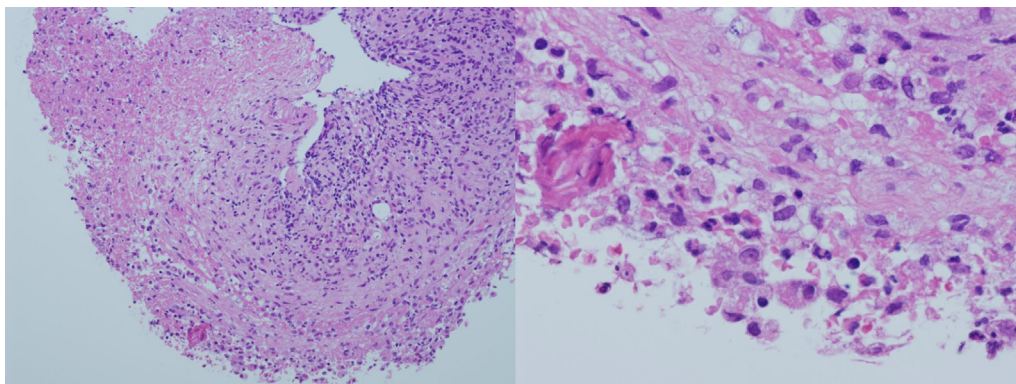
<https://doi.org/10.1016/j.jvscit.2019.07.005>



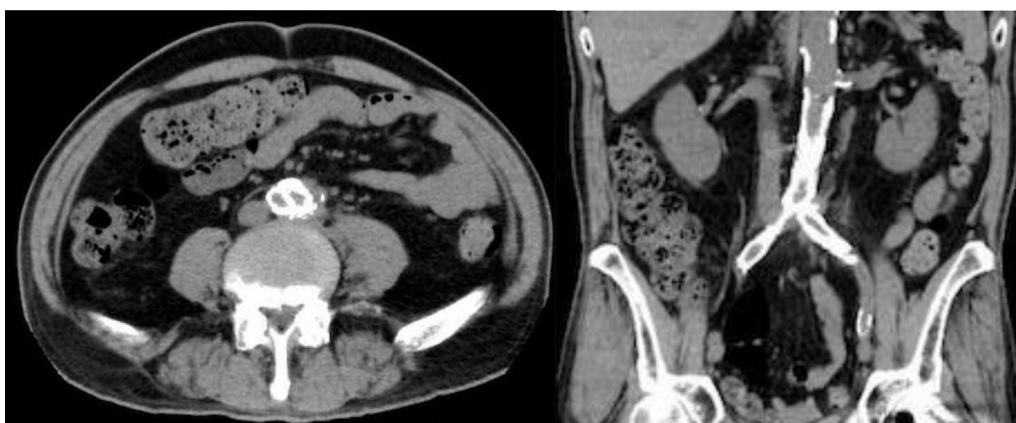
**Fig 1.** Preoperative computed tomography (CT) angiography shows an encapsulated low-density area around the terminal aorta. Arrows indicate the pseudoaneurysm.



**Fig 2.** Postoperative computed tomography (CT) angiography shows successful endovascular treatment with no endoleaks.



**Fig 3.** Periaortic tissue collected by computed tomography (CT)-guided biopsy exhibited necrotic areas and granulomatous change with fibrosis and invasion of lymphocytes (both images, hematoxylin and eosin stain; left,  $\times 100$ ; right,  $\times 400$ ).



**Fig 4.** Computed tomography (CT) 12 months after endovascular repair (EVAR) showed disappearance of the pseudoaneurysm and abscess.

Five days postoperatively, diagnostic CT-guided biopsy showed that the collected periaortic tissue included necrosis and granulomatous change with fibrosis and invasion of lymphocytes (Fig 3). We also cultured a piece of the tissue and detected *P micros*. The aneurysm was confirmed to be an MAA. We changed the antibiotics to metronidazole (500 mg every 8 hours) and continued this antibiotic therapy by intravenous administration for 4 weeks postoperatively; the therapy was then changed to oral administration. During this same period, the patient's periodontitis was treated by our dentist.

Treatment with metronidazole resulted in good control of the infection. The metronidazole was administered intravenously for 4 weeks and then orally for more than 1 week, and he was discharged from our hospital 41 days postoperatively after we had confirmed that he had no signs of recurrence of infection. He continued taking the oral metronidazole for 12 months after endovascular repair, after which CT showed that the aneurysm and abscess had disappeared (Fig 4). No complications occurred for 13 months after EVAR. The patient was still being periodically and carefully followed at the time of this writing.

## DISCUSSION

An MAA is a rare but lethal lesion. Many types of bacteria cause MAAs, but only one case report has described an MAA caused by *P micros*.<sup>1</sup> *P micros* is a gram-positive anaerobic coccus that usually exists in the gingival crevices and gastrointestinal tract. In one study, *P micros* occurred with a prevalence of 58% to 63% among 1046 adult and juvenile patients with periodontitis.<sup>8</sup> This bacterial species can trigger odontitis, sepsis, endocarditis, and abscess formation. However, in almost no cases is *P micros* alone cultured from abscesses; instead, it is usually detected in mixed anaerobic abscesses.<sup>9</sup> In addition, to our knowledge, *P micros* induces no obvious pathogenesis in the aortic wall, and only one previous case report showed paravalvular abscess formation and aortic prosthetic valve endocarditis by another species in this genus (*P magnus*).<sup>10</sup> In this patient, we believe that the periodontitis led to bacteremia and poorly controlled diabetes mellitus, which resulted in *P micros* infection of the abdominal aortic wall.

MAAs are traditionally treated by open surgery involving infective aneurysm resection and repair. However, some

recent reports have indicate that EVAR is an acceptable alternative treatment for MAAs.<sup>2-4</sup> Sörelius et al<sup>2</sup> reported that EVAR for MAAs is associated with better short-term survival than open repair and produces comparable long-term results in terms of survival and infection-related complications or reinterventions. Luo et al<sup>5</sup> reported that there was a trend toward survival in patients with negative blood cultures and that all patients with persistent infection were treated with long-term medical therapy; however, all died within 6 months of repair. The patients with negative cultures were suspected to have infection with less virulent bacteria. Additionally, *Staphylococcus aureus* infection increases the risk of aneurysm-related death,<sup>11</sup> and a non-*Salmonella*-positive blood culture is a predictor of late infection-related death.<sup>2,4</sup> We believe that detection of the causative bacteria is critical for successful treatment of MAAs because it not only facilitates the use of appropriate and efficacious antibiotics, but also helps the clinician to decide whether EVAR is likely to control the MAA without an additional surgical procedure. Even when preoperative blood cultures are negative, operative cultures detect microorganisms in some cases.<sup>11-14</sup> A drawback of the endovascular approach is that tissue samples cannot be obtained for culture. CT-guided biopsy after EVAR enables direct sampling of the periaortic wall and identification of the causative bacteria without concern about rupture. Several reports have described CT-guided drainage of abscesses of MAAs and graft infection.<sup>15-17</sup> In these cases, drainage of the abscesses by CT-guided catheterization was performed after surgical intervention; however, the drainage was not performed to detect the causative bacteria.

In the present case, we performed EVAR for treatment of an MAA and were prepared to convert the procedure to an open surgery. However, we maintained good infection control with resolution of the inflammation postoperatively; therefore, no additional interventions involving open surgery were necessary. Infection by *P micros*, which has low pathogenicity, contributed to the patient's good clinical course. We believe that the type of bacterium (eg, *Salmonella* infection, non-*Salmonella* infection, or *S aureus* infection) determines the effectiveness of EVAR for MAAs; however, we still follow patients for a long time because of implantation of an artificial graft in an infection site.

## CONCLUSIONS

We performed EVAR for an MAA infected by *P micros* and achieved a satisfactory result. MAAs caused by *P micros* may be controlled with antibiotics and EVAR without open surgical reintervention, and CT-guided biopsy can provide useful information regarding which antibiotic therapy should be chosen to control the infection.

We thank Angela Morben, DVM, ELS, from Edanz Group ([www.edanzediting.com/ac](http://www.edanzediting.com/ac)), for editing a draft of this manuscript.

## REFERENCES

1. Shuhei Y, Yukihiko N, Satoru N, Shinichiro Y. A case of ruptured infected abdominal aortic aneurysm due to *Peptostreptococcus*. *Jpn J Vasc Surg* 2010;19:509-12.
2. Sörelius K, Wanhainen A, Furebring M, Björck M, Gillgren P, Mani K, et al. Nationwide study of the treatment of mycotic abdominal aortic aneurysms comparing open and endovascular repair. *Circulation* 2016;134:1822-32.
3. Luo CM, Chan CY, Chen YS, Wang SS, Chi NH, Wu IH. Long-term outcome of endovascular treatment for mycotic aortic aneurysm. *Eur J Vasc Endovasc Surg* 2017;54:464-71.
4. Sörelius K, Mani K, Björck M, Sedivy P, Wahlgren CM, Taylor P, et al. Endovascular treatment of mycotic aortic aneurysms: a European multicenter study. *Circulation* 2014;130:2136-42.
5. Rasmussen TE, Hallett JW Jr. Inflammatory aortic aneurysms. A clinical review with new perspectives in pathogenesis. *Ann Surg* 1997;225:155-64.
6. Sethia B, Darke SG. Abdominal aortic aneurysm with retroperitoneal fibrosis and ureteric entrapment. *Br J Surg* 1983;70:434-6.
7. Kamata S, Itou Y, Idoguchi K, Imakita M, Funatsu T, Yagihara T. Abdominal aortic aneurysm with periaortic malignant lymphoma differentiated from aneurysmal rupture by clinical presentation and magnetic resonance imaging. *J Vasc Surg Cases Innov Tech* 2018;4:95-8.
8. Rams TE, Feik D, Listgarten MA, Slots J. *Peptostreptococcus micros* in human periodontitis. *Oral Microbiol Immunol* 1992;7:1-6.
9. Murdoch DA. Gram-positive anaerobic cocci. *Clin Microbiol Rev* 1998;11:81-120.
10. Pouëdras P, Donnio PY, Sire JM, Avril JL. Prosthetic valve endocarditis and paravalvular abscess caused by *Peptostreptococcus magnus*. *Clin Infect Dis* 1992;15:185.
11. Oderich GS, Panneton JM, Bower TC, Cherry KJ Jr, Rowland CM, Noel AA, et al. Infected aortic aneurysms: aggressive presentation, complicated early outcome, but durable results. *J Vasc Surg* 2001;34:900-8.
12. Lau C, Gaudino M, de Biasi AR, Munjal M, Girardi LN. Outcomes of open repair of mycotic descending thoracic and thoracoabdominal aortic aneurysms. *Ann Thorac Surg* 2015;100:1712-7.
13. Chen IM, Chang HH, Hsu CP, Lai ST, Shih CC. Ten-year experience with surgical repair of mycotic aortic aneurysms. *J Chin Med Assoc* 2005;68:265-71.
14. Gomes MN, Choyke PL, Wallace RB. Infected aortic aneurysms. A changing entity. *Ann Surg* 1992;215:435-42.
15. Kan CD, Yen HT, Kan CB, Yang YJ. The feasibility of endovascular aortic repair strategy in treating infected aortic aneurysms. *J Vasc Surg* 2012;55:55-60.
16. Mizoguchi H, Iida O, Dohi T, Tomoda K, Kimura H, Inoue K, et al. Abdominal aortic aneurysmal and endovascular device infection with iliopsoas abscess caused by *Mycobacterium bovis* as a complication of intravesical bacillus Calmette-Guérin therapy. *Ann Vasc Surg* 2013;27:1186.e1-5.
17. Pryluck DS, Kovacs S, Maldonado TS, Jacobowitz GR, Adelman MA, Charles HC, et al. Percutaneous drainage of aortic aneurysm sac abscesses following endovascular aneurysm repair. *Vasc Endovascular Surg* 2010;44:701-7.