



# Comparison of Balloon-Occluded Thrombolysis with Catheter-Directed Thrombolysis in Patients of Budd-Chiari Syndrome with Occluded Direct Intrahepatic Portosystemic Shunt

Amar Mukund<sup>1</sup> Tanya Yadav<sup>1</sup> Satender Pal Singh<sup>2</sup> Saggere Muralikrishna Shasthry<sup>2</sup>  
Rakhi Maiwall<sup>2</sup> Yashwant Patidar<sup>1</sup> Shiv Kumar Sarin<sup>2</sup>

<sup>1</sup> Department of Interventional Radiology, Institute of Liver and Biliary Sciences, New Delhi, India

<sup>2</sup> Department of Hepatology, Institute of Liver and Biliary Sciences, New Delhi, India

Address for correspondence Amar Mukund, MD, Department of Radiology, Institute of Liver and Biliary Sciences, D-1, Vasant Kunj, New Delhi 110070, India (e-mail: dramarmukund@gmail.com).

Indian J Radiol Imaging 2024;34:25–31.

## Abstract

**Objectives** Direct intrahepatic portosystemic shunt (DIPS) stent placement is an effective treatment for patients with Budd-Chiari syndrome (BCS); however, thrombotic occlusion of DIPS stent remains a cause of concern. The purpose of this study is to describe a novel technique of balloon-occluded-thrombolysis (BOT) for occluded DIPS stent, and compare it with the conventional catheter-directed-thrombolysis (CDT).

**Methods** In this retrospective study, the hospital database was searched for BCS patients who underwent DIPS revision for thrombotic stent occlusion between January 2015 and February 2021. Patients were divided into CDT group and BOT group. The groups were compared for technical success, total dose of thrombolytic agent administered, duration of hospital stay, and primary assisted stent patency rates at 1- and 6-month follow-up.

**Results** CDT was performed in 12 patients, whereas 21 patients underwent BOT. Complete recanalization was achieved in 66.7% (8 of 12) patients of CDT group as compared to 81% (17 of 21) patients of BOT group (nonsignificant difference,  $p = 0.420$ ). BOT group had a short hospital stay ( $1.8 \pm 0.7$  vs.  $3.5 \pm 1.0$  days) and required less dose of thrombolytic agent ( $[2.2 \pm 0.4] \times 10^5$  IU versus  $[8.3 \pm 2.9] \times 10^5$  IU of urokinase) as compared to the CDT group and both differences were statistically significant ( $p < 0.001$ ). Further, 6-month patency rate was higher in BOT group as compared to CDT group ( $p = 0.024$ ).

**Conclusion** The novel BOT technique of DIPS revision allows longer contact time of thrombolytic agent with the thrombi within the occluded stent. This helps in achieving fast recanalization of thrombosed DIPS stent with a significantly less dose of thrombolytic agent required, thus reducing the risk of systemic complications associated with thrombolytic administration.

## Keywords

- ▶ direct intrahepatic portosystemic shunt
- ▶ Budd-Chiari syndrome
- ▶ thrombolysis
- ▶ catheter-directed thrombolysis

article published online  
June 26, 2023

DOI <https://doi.org/10.1055/s-0043-1770343>.  
ISSN 0971-3026.

© 2023. Indian Radiological Association. All rights reserved.  
This is an open access article published by Thieme under the terms of the Creative Commons Attribution-NonDerivative-NonCommercial-License, permitting copying and reproduction so long as the original work is given appropriate credit. Contents may not be used for commercial purposes, or adapted, remixed, transformed or built upon. (<https://creativecommons.org/licenses/by-nc-nd/4.0/>)  
Thieme Medical and Scientific Publishers Pvt. Ltd., A-12, 2nd Floor, Sector 2, Noida-201301 UP, India

## Introduction

Budd-Chiari syndrome (BCS) occurs due to obstruction of the hepatic venous outflow tract that can occur at the level of hepatic veins, ostial opening of hepatic vein into inferior vena cava (IVC), or part of IVC above the level.<sup>1</sup> Direct intrahepatic portosystemic shunt (DIPS) is an endovascular side-to-side portocaval shunt created from IVC to portal vein through liver parenchyma.<sup>2</sup> This ameliorates the portal hypertension associated with BCS. Although anatomic recanalization of hepatic veins is always the initial aim in BCS, however, in absence of recanalizable hepatic vein or failure of previously placed hepatic vein stent, DIPS remains the next alternative therapy.<sup>3,4</sup> BCS is increasingly being diagnosed with high clinical suspicion leading to increased frequency of patients undergoing DIPS creation.<sup>5,6</sup> The procoagulant state in BCS has been identified in 88% by European studies and 85% by Indian studies, posing a risk of stent thrombosis and requiring anticoagulation. Primary and secondary patency rates of DIPS at 1 year range from 66 to 100% and occlusion of DIPS stent is associated with reappearance of symptoms of portal hypertension.<sup>7</sup> Failure to recanalize these occluded stent leaves the patients with only curative option of liver transplant. So, recanalizing occluded stent helps in averting an early transplant.

Early identification and recanalization of occluded DIPS stent are of utmost importance considering the risk life-threatening variceal hemorrhage. The purpose of this study is to describe an innovative way of performing thrombolysis in thrombotically occluded DIPS stent and compare it with the conventional method of continuous catheter-directed thrombolysis (CDT).

## Materials and Methods

### Patients and Group

This retrospective study was performed after obtaining institutional review board approval (IEC/2021/86/MA15) and the need for informed consent was waived (ClinicalTrials.gov ID: NCT05117684).

Patients of BCS with DIPS occlusion were identified during their scheduled follow-up (every 3 months in for the 1st year after DIPS and thereafter every 6 months) or their visit to the hospital for new onset ascites and/or upper GI bleed. All consecutive patients with thrombotic occlusion of DIPS stent underwent revision of DIPS stent (from January 2015 to February 2021) if cannulation of DIPS stent was possible from jugular approach using various hardware and technique. The data of all patients who underwent DIPS revision was collected from the Hospital Information System (HIS). Procedural details were retrieved from the electronic database and the patients were divided into two groups, based on the technique of thrombolysis used for DIPS revision. Patients were treated with conventional method of continuous CDT-group 1, or balloon occluded thrombolysis (BOT)-group 2 within 1 to 2 weeks of diagnosis. BOT was conceptualized and started in 2018, with first case being done in January and thereafter all cases of DIPS occlusion underwent BOT for recanalization.

Laboratory values including liver function tests (LFT), kidney function tests (KFT), prothrombin time (PT)/ international normalized ratio (INR), albumin-bilirubin score (ALBI), and procoagulant workup at the time of patient presentation and at 1 and 6-month follow-up were collected from the HIS. Flow velocities using Doppler ultrasound (mid-shunt velocity, shunt velocity at IVC end, and main portal vein velocity) were recorded at the time of DIPS creation and post-DIPS revision. Portosystemic gradient was measured and recorded at the time of DIPS creation and during DIPS revision (pre- and postprocedure). Stent patency was checked at 6-month follow-up using Doppler ultrasound and flow within the stent and flow velocities were recorded. All the patients received oral anticoagulant (Acitrom 2–5 mg), with individual dose titration in order to maintain the INR value between 2.0 and 3.0.

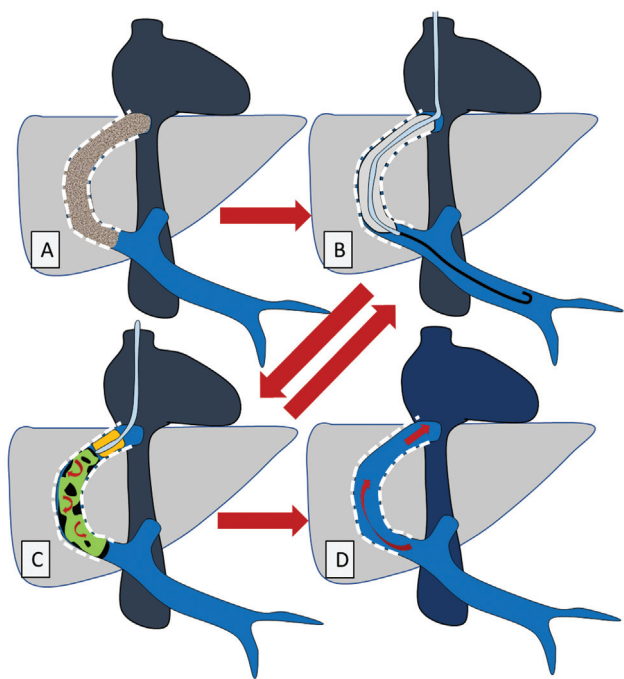
Procedure was done under conscious sedation. All the procedures were performed by an interventional radiologist (IR), having at least 10 years of experience. The thrombosed stent was cannulated using 5F multipurpose or Cobra catheter (Cook Medical, Bloomington, IN) via transjugular route. If cannulation failed despite using both catheters, then angle stiffening cannula from RUPS set (Cook Medical) was used to direct the catheter within the thrombosed stent. Heparin (2500–3000 IU) was administered via sheath at the beginning of procedure. Urokinase was used as thrombolytic agent in either technique.

### Conventional Catheter-Directed Thrombolysis

After cannulating the thrombosed stent, the 5F multipurpose or cobra catheter was advanced to the portal end and a bolus dose of 100,000 IU of Urokinase was injected all throughout the thrombi in the stent while gradually withdrawing the catheter. After 20 minutes of injection of thrombolytic agent, balloon angioplasty was performed (using 8 or 10 mm non-compliant balloon, Mustang, Boston Scientific) to macerate the thrombi and later thrombectomy was performed using manual suction and aspiration of thrombi using 10F long sheath. This was followed by sweeping a compliant balloon (Swan-Ganz catheter, Edwards Life Sciences) across the DIPS stent to aid detachment of fragmented thrombi adhered to the wall of the stent. These maneuvers though helped in debulking the thrombus load and the clearance of residual thrombus was performed by continuous thrombolytic infusion (using 40,000–60,000 IU/hour of Urokinase) using multi-sideport infusion catheter (Cook Medical) for 12 to 48 hours. Venography was repeated every 12 hours to assess the response and stopped once complete luminal recanalization (wall to wall patency within the stent) was achieved. Infusion of thrombolytic agent was continued for maximum of 48 hours and stopped thereafter irrespective of the response.

### Balloon-Occluded Thrombolysis

In BOT, after cannulating the thrombosed stent angioplasty (► **Fig. 1**) was performed using an 8 or 10 mm noncompliant angioplasty balloon (Mustang, Boston Scientific). Thereafter, a 10F long sheath was advanced up to the DIPS stent and a Swan-Ganz catheter was placed inside the caval end of the



**Fig. 1** Schematic representation of balloon-occluded thrombolysis technique for thrombotically occluded direct-intrahepatic portosystemic-shunt (DIPS) stent (A–D). (A) Thrombotically-occluded DIPS stent with thrombotic occlusion represented in gray color. (B) Balloon angioplasty with a noncompliant balloon (C) Balloon-occluded thrombolysis performed after inflating a compliant balloon at the inferior vena cava end of the DIPS stent and injecting thrombolytic agent to create a static column (balloon-occluded thrombolysis and balloon angioplasty may be performed couple of times alternatively to achieve complete recanalization) (D) Recanalized DIPS stent with wall-to-wall flow.

DIPS stent and the balloon was inflated to occlude the stent lumen at the caval end. Thereafter, 100,000 IU of urokinase mixed with iodinated contrast media (to help visualization of urokinase) was administered through the Swan-Ganz catheter to get inside the organized thrombi in the stent. The aim was to prevent the flow of thrombolytic agent into the systemic circulation and create a static column of thrombolytic agent within the stent, leading to a longer contact between thrombolytic agent and thrombus that would help in achieving a better thrombi clearance in a short duration with a limited dose of thrombolytic agent. After 15 to 20 minutes, the thrombolytic solution within the stent was aspirated. It was followed by a repeat angioplasty using an 8 or 10 mm noncompliant balloon, manual thrombo-suction using 10F sheath and a balloon sweep across the stent using Swan-Ganz catheter. In case of any residual thrombi, BOT and angioplasty were repeated one to two times (till the total dose of urokinase did not exceed 200000 IU) to achieve complete thrombus clearance.

Restenting within the existing DIPS stent was done in case of incomplete thrombi clearance by either method of thrombolysis using 10 mm covered stent (Fluency BARD) in the liver parenchymal track with or without bare stent in the portal vein (wall stent Boston). The length of stent was either same or 2 cm longer than the previously placed covered

stent. End-point of procedure was to achieve complete luminal/wall-to-wall contrast opacification of the stent, with no filling defects, no opacification of peripheral portal vein branches, and/or varices on venogram.

### Definition of Outcomes

**Successful recanalization:** Restoration of normal flow within the DIPS stent (postprocedure venogram and ultrasound Doppler showing wall-to-wall contrast opacification with no filling defects and no opacification of peripheral portal vein branches and/or varices) after thrombolysis (CDT or BOT), without the need for restenting.

Besides technical success, the groups were compared for mean total dose of thrombolytic agent administered, duration of hospital stay, and primary-assisted patency rate at 1 and 6-month follow-up. The data was analyzed for all complications associated with the procedures as per the Society of Interventional Radiology (SIR) guidelines.

### Statistical Analysis

All analyses were carried out on SPSS (version 23.0, SPSS Inc., Chicago, Illinois, United States). Qualitative data were expressed as proportion or percentages (%). Quantitative data were expressed as mean  $\pm$  SD, median, and ranges depending on data distribution. Continuous variables were compared parametrically using Student's *t*-test or nonparametrically using Mann-Whitney U test. *p*-Value less than 0.05 was taken as statistically significant in all cases. The Kaplan-Meier survival analysis method was used for calculating overall and transplant-free survival.

### Results

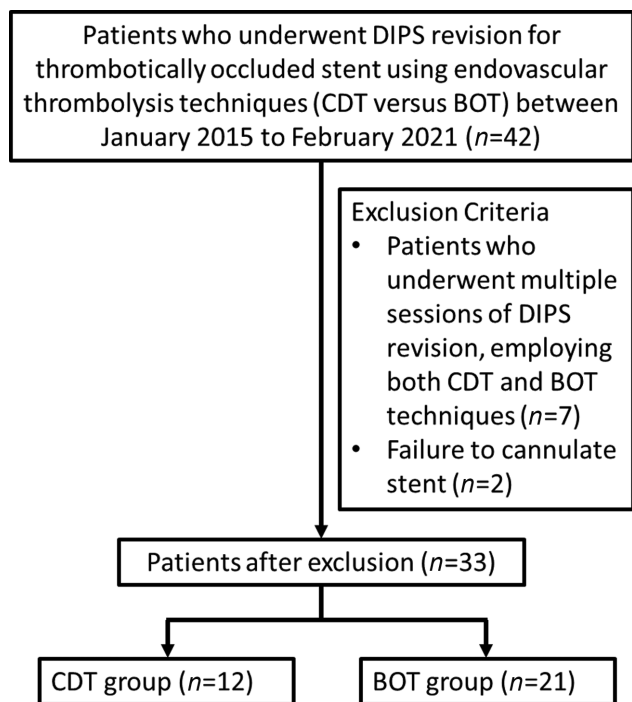
A total of 42 patients developed thrombotic occlusion of DIPS stent and 33 of them were included for analysis. No color flow was seen on ultrasound Doppler in all patients at the time of diagnosis. As per the treatment received, the patients were grouped in CDT or BOT group (**► Fig. 2**).

### Demographic, Clinical, and Laboratory Data

There were 12 patients in CDT group (11 males and 1 female) and 21 in BOT Group (13 males and 8 females). Most common clinical presentation was ascites and abdominal pain followed by variceal bleed in either groups. The patient characteristics of both groups at the time of presentation with DIPS occlusion are outlined in **► Table 1**. The groups were found to be similar with respect to age, sex, PT/INR, LFT, and KFT. The mean velocities on Doppler ultrasound at the time of DIPS creation did not show any significant difference between the two groups. The mean portosystemic gradient at the time of DIPS creation and DIPS occlusion were also compared with no significant difference found between the two groups (**► Supplementary Tables 1 and 2**). Recanalization of DIPS was performed within 1 to 2 weeks of diagnosis.

### Management and Procedure-Related Complications

**CDT group (n = 12):** Eight patients (66.7%) showed complete recanalization of blocked DIPS stent with continuous CDT,



**Fig. 2** Flowchart showing patient selection, inclusion, and exclusion criteria and group stratification. BOT, balloon-occluded-thrombolysis; CDT, catheter-directed thrombolysis; DIPS, direct intrahepatic portosystemic shunt.

while remaining four patients (33.3%) required placement of another 10 mm covered stent within the DIPS due to incomplete recanalization.

The average dose of urokinase administered in patients of this group was  $8.3 \pm 2.9 \times 10^5$  IU. One patient had developed large puncture site hematoma in neck, which was managed with manual compression (minor complication according to Society of Intervention Radiology guidelines). The mean duration of hospital stay was  $3.5 \pm 1.0$  days. At 1-month follow-up, 3 of 8 patients developed stent rethrombosis. However, the 6-month follow-up did not reveal any additional case of DIPS block (→ **Table 2**).

**BOT group (n = 21):** Seventeen patients (81%) had complete restoration of wall-to-wall flow after BOT performed two to three times using a maximum of 200000 IU of urokinase (→ **Fig. 3**), while four patients (19%) required placement of another 10 mm covered stent within the DIPS. The mean dose of urokinase administered in patients of this group was  $2.2 \pm 0.4 \times 10^5$  IU. No procedure-related major or minor adverse events were reported in this group.

Unlike CDT group, where all the patients required 2 to 5 days of hospital stay, 7 patients (33%) in BOT group could be managed in the day-care and got discharged on the same day of the procedure. The mean duration of hospital stay in BOT group was significantly lower ( $1.8 \pm 0.7$  days). There was no recurrence of stent block in any of the patients at 1- and 6-month follow-up (→ **Table 2**).

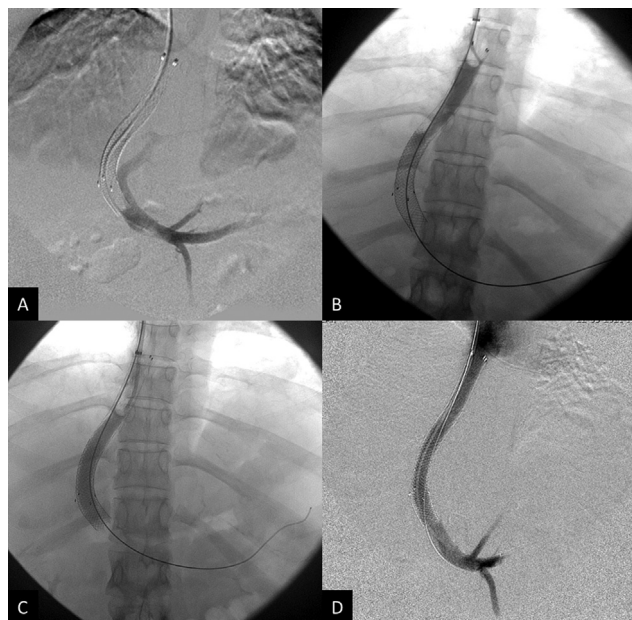
**Table 1** Demographic, clinical, and laboratory findings of study patients at the time of presentation with thrombotically-occluded DIPS stent

Characteristics	Values, n (%) or median (range)		
	Group 1 (n =12)	Group 2 (n =21)	p-Value
Age at diagnosis (years)	32.5 ± 16.8	34.7 ± 15.5	0.708
Sex (male/female)	12/1	14/8	0.065
<b>Etiology</b>			
Polycythemia rubra vera	1	2	
Myeloproliferative disorders	3	3	
Factor V Leiden gene mutation	1	2	
Methylene tetrahydrofolate reductase gene mutation	1	3	
Prothrombin gene mutation	1	0	
JAK	1	1	
Not identified	2	5	
Not evaluated	2	5	
<b>Symptoms at diagnosis</b>			
Ascites	11 (92%)	17 (81%)	
Abdominal pain	6 (50%)	10 (47.6%)	
Upper GI bleed	4 (33.3%)	5 (23.8%)	
Nonsymptomatic	1 (8.3%)	3 (14.3%)	
<b>Biochemical parameters</b>			
Serum bilirubin (mg/dL)	2.4 ± 1.0	2.1 ± 0.8	0.370
Aspartate transaminase (IU/L)	50 (IQR: 46–68)	44 (IQR: 34.7–57.7)	0.408
Alanine transaminase (IU/L)	40 (IQR: 31.5–55)	38 (IQR: 25.5–46.7)	0.400
Serum albumin (g/dL)	2.9 ± 0.4	2.8 ± 0.6	0.712
PT-INR	2.2 ± 0.9	2.7 ± 1.5	0.533
Platelets (lacs/mm <sup>3</sup> )	215 ± 114.4	150 ± 86.7	0.232
Serum creatinine (mg/dL)	0.8 ± 0.2	0.8 ± 0.4	0.796
ALBI score	1.5 ± 0.4	1.4 ± 0.5	0.903

Abbreviations: ALBI, albumin-bilirubin score; DIPS, direct intrahepatic portosystemic shunt; GI, gastrointestinal; IQR, interquartile range; PT-INR, prothrombin time-international normalized ratio.

**Table 2** Comparison of outcome in both groups

	Group I	Group II	p-Value
Length of hospital stay (days)	3.5 ± 1.0	1.8 ± 0.7	0.001
Total dose of urokinase (10 <sup>5</sup> IU)	8.3 ± 2.9	2.2 ± 0.4	0.001
Complication rate	1/12	0/21	–
Technical success	66.7% (8/12)	81% (17/21)	0.420
Primary-assisted patency rate at 1 month	62.5% (5/8)	100% (17/17)	0.024
Primary-assisted patency rate at 6 months	100% (5/5)	100% (17/17)	–



**Fig. 3** Thrombotic occlusion of direct intrahepatic portosystemic shunt (DIPS) stent, being recanalized using balloon-occluded thrombolysis. (A) DIPS venogram shows nonopacification of the stent. (B) Swan-Ganz balloon inflated at inferior vena cava end of stent with a column of contrast-urokinase mixture within proximal part of stent. (C) Swan-Ganz balloon inflated at mid-part of stent with a column of contrast-urokinase mixture within distal part of stent. (D) Post-thrombolysis venogram normal wall to wall opacification of DIPS stent.

### Comparison of Outcome between Two Groups

Success rates of 66.7 and 81% were achieved in CDT group and BOT group, respectively, with no statistically significant difference ( $p$ -value = 0.420). However, a significant difference was noted in the mean urokinase dose administered ( $p$ -value = 0.001) and length of hospital stay ( $p$  value = 0.001) between the two groups. The primary-assisted patency at 1-month follow-up was also significantly higher in BOT group compared to CDT group ( $p$ -value = 0.024). The follow-up Doppler at 6 months did not differ between the two groups (► **Table 2**).

The mean Doppler velocities and portosystemic gradients were found to be within the normal limits in either group after DIPS revision. No significant difference was found between the groups in the postrevision Doppler velocities and portosystemic gradients (► **Supplementary Tables 3 and 4**).

**Table 3** Outcomes following DIPS recanalization

Symptom/Sign	Result	p-Value
Time for ascites resolution (weeks)		
Group I	2.2 ± 0.8	0.07
Group II	2.7 ± 0.5	
Time for abdominal pain resolution		
Group I	1.75 ± 0.5	0.385
Group II	1.5 ± 0.5	

Abbreviation: DIPS, direct intrahepatic portosystemic shunt.

Similarly, time taken for resolution of ascites and abdominal pain in both the groups after DIPS recanalization did not show significant statistical difference ( $p$ -values = 0.07 and 0.385, respectively; ► **Table 3**).

Among the biochemical markers, serum albumin levels and ALBI score showed statistically significant improvement at 1 month in both the groups, while serum bilirubin, platelet counts, and serum creatinine showed significant improvement only in BOT group (► **Table 4**).

## Discussion

The study population had a mean age of 32.5 years in group I and 34.7 years in group II. The most common clinical presentation was in the form of ascites and abdominal pain followed by variceal bleed in either groups, whereas 20% patients were asymptomatic. Previous literature also showed that ascites is the most common symptom in BCS occurring in 62 to 83% of patients, while 10% of BCS patients presented with variceal bleed and another 10% patients were asymptomatic.<sup>8</sup> In the present study, three BCS patients had polycythemia rubra vera (1 in group 1 and 2 in group 2), six had myeloproliferative disorders (3 in group 1 and 3 in group 2), inherited thrombophilia (factor 5 mutation) was present in 3 patients (1 in group 1 and 2 in group 2), prothrombin mutation was present in 1 patients, and 14 patients had undiagnosed prothrombotic state. Previous studies have shown incidence of myeloproliferative disorders in 16 to 62% of patients with BCS and among various disorders, polycythemia vera was the most common type. Pregnancy and puerperium were seen more commonly in Asia, while oral contraceptive pills use was noted in 30% of patients with BCS in Western studies. Antiphospholipid antibodies were found in 18 to 25% BCS patients.<sup>9</sup>

**Table 4** Comparison between pre- and postprocedure laboratory values in both groups

Variables	Pre-DIPS revision	Post-DIPS revision (at 1 month)	p-Value
PT-INR Group I Group II	2.2 ± 0.9 2.7 ± 1.5	2.5 ± 0.7 2.7 ± 0.6	0.327 0.429
Serum total bilirubin (mg/dL) Group I Group II	2.4 ± 1.0 2.0 ± 0.8	2.1 ± 0.9 1.5 ± 0.7	0.066 0.041
Aspartate aminotransferase (IU/L) Group I Group II	50 (IQR: 46–68) 44 (IQR: 34.7–57.7)	49.5 (IQR: 42–70) 47.5 (IQR: 38.5–53.8)	0.116 0.062
Alanine aminotransferase (IU/L) Group I Group II	40 (31.5–55) 38 (IQR: 25.5–46.7)	42.5 (IQR: 34.2–53) 43.5 (IQR: 33.2–51.5)	0.674 0.953
Serum albumin (g/dL) Group I Group II	2.9 ± 0.4 2.8 ± 0.6	3.5 ± 0.4 3.3 ± 0.8	0.011 0.003
Platelet count (lakhs/mm <sup>3</sup> ) Group I Group II	215 ± 114 150 ± 86.7	231 ± 161 192.6 ± 99	0.799 0.001
Serum creatinine (mg/dL) Group I Group II	0.8 ± 0.2 0.8 ± 0.4	0.7 ± 0.4 0.6 ± 0.3	0.575 0.026
ALBI score Group I Group II	1.5 ± 0.4 1.4 ± 0.5	2.1 ± 0.3 1.9 ± 0.7	0.036 0.007

Abbreviations: ALBI, albumin-bilirubin score; DIPS, direct intrahepatic portosystemic shunt; IQR, interquartile range; PT-INR, prothrombin time-international normalized ratio.

Although DIPS has become an integral part in BCS management, shunt thrombosis poses a major concern. The patients with blocked DIPS stent present with reappearance of ascites and/or varices on upper gastrointestinal endoscopy.<sup>10</sup> Revision of thrombosed stents can be easily accomplished in most cases using CDT. However, prolonged administration and higher dose of thrombolytic agent due to the reduced contact time between the thrombus and thrombolytic agent as the thrombolytic agent quickly escape into the circulation after being released by the multi-side hole catheter. Besides, the systemic dispersion of thrombolytic agent in high doses and for longer duration may lead to hemorrhagic complications.<sup>11</sup> The use of BOT significantly increases the contact time between the thrombi and the thrombolytic agent and reduces the overall dose of thrombolytic agent. In BOT, static column of thrombolytic drug enables the administration of topical high-concentration lytic agents that is later aspirated, thus avoiding systemic effects of the thrombolytic agent (►Figs. 1C, 3B, and 3C). CDT requires longer duration of thrombolytic infusion leading to high cumulative doses of urokinase administered. This is evident from the significant difference in average dose of urokinase administered in either groups.

The duration of hospital stays in CDT group ranged from 2 to 5 days. Patients treated with CDT require ICU care during continuous infusion of thrombolytic agent. Periodic digital subtraction angiography acquisitions are needed to look for the resolution of thrombus that leads to increased patient

discomfort and additional radiation dose to the patient. In BOT hospital stay ranged from 1 day to a maximum of 3 days and the procedure was completed in a single session. Seven patients (33.3%) were treated in a day-care facility with postprocedure observation period of about 4 hours, and were discharged on the same day. BOT provides similar results, with a lower dose of thrombolytic agent and a short hospital stay. Thus, it has the potential to save time and resource and may reduce the cost of the treatment. In this study, success rates of 66.7 and 81% were achieved in CDT group and BOT group, respectively. Previous literature with CDT by Li et al, in BCS with occluded shunt showed that only 70% patients were able to achieve thrombolysis at 1-month follow-up with thrombus length and reopening IVC proportion of thrombus independently favoring thrombolysis.<sup>12</sup> Also, studies show that patients of cirrhosis and coagulation disorder have high risk of bleeding complication, thereby requiring lower dose of anticoagulation. As BOT is not a frequently used therapy, there is no data available. But BOT therapy gives advantage in patients with bleeding diathesis and Budd-Chiari-related portal hypertension with less risk of complications and good favorable outcomes.

Bleeding complications associated with thrombolytic therapy can lead to extended hospital stay, multiple transfusions, stroke, and death.<sup>13,14</sup> In this study, one such complication was documented in the form of expanding neck hematoma in CDT group. However, no hemorrhagic complication was noted in BOT group.

BOT group showed a higher technical success when compared to CDT group, that is, 81 versus 66.7%. However, this did not turn out to be statistically significant. Moreover, the two groups did not behave differently in terms of improvement in ultrasound Doppler velocities, portosystemic gradient, and clinical resolution post-DIPS revision. Thus, it can be inferred that although the technical success is similar in both groups, yet the morbidity associated with higher thrombolytic dosage and longer hospital stay in CDT group certainly places BOT group at an advantage.

Follow-up at 1 month revealed three cases of recurrence of stent thrombosis on sonography in CDT group, whereas there were no such findings in BOT group. It was postulated that this recurrence could be due to microthrombi persisting along the stent wall (not visualized on angiograms) in CDT group. These remnant microthrombi may serve as a nidus for recurrence intrastent thrombus.

The study had few limitations. The sample size is small that is due to rarity of the disease. The available follow-up was only for 6 months. Patient factors prothrombotic state may have some role to play in stent thrombosis/rethrombosis.

With the available results, it may be concluded that BOT is a quick and effective treatment for thrombosed DIPS stent requiring short hospital stay and less dose of thrombolytic agent as compared to conventional CDT. This novel technique (BOT) has a potential to expedite thrombolysis and reduce thrombolysis-related bleeding complications in thrombosed DIPS stent.

#### Author Contributions

A.M. was involved in conceptualization, methodology, reviewing, editing and finalizing the manuscript. T.Y. helped in data curation, data analysis, preparation of first draft of the manuscript. S.P.S. helped in data curation and reviewing the manuscript. S.M.S. contributed to patient enrolling, clinical management, and methodology. R.M. helped in patient enrolling, clinical management, and data analysis. Y.P. helped in imaging evaluation of patients and reviewing the manuscript. S.K.S. was involved in supervising the research, reviewing, and editing to reach the final version of manuscript. Clinical trials.gov ID: NCT05117684.

#### Ethical Approval

Approval for the study was obtained from institutional review board (IEC/2021/86/MA15). All procedures performed in studies involving human participants were in accordance with the ethical standards of the institutional and/or national research committee and with the 1964 Helsinki declaration and its later amendments or comparable ethical standards.

#### Informed Consent

This study has obtained IRB approval from (IEC/2021/86/MA15) and the need for informed consent was waived.

#### Consent for Publication

Consent for publication was obtained for every individual person's data included in the study.

#### Funding

None.

#### Conflict of Interest

None declared.

#### References

- Molmenti EP, Segev DL, Arepally A, et al. The utility of TIPS in the management of Budd-Chiari syndrome. *Ann Surg* 2005;241(06): 978–981, discussion 982–983
- Petersen BD, Clark TW. Direct intrahepatic portocaval shunt. *Tech Vasc Interv Radiol* 2008;11(04):230–234
- Mukund A, Rana S, Mohan C, Kalra N, Bajjal SS. Indian College of Radiology and imaging evidence-based guidelines for interventions in portal hypertension and its complications. *Indian J Radiol Imaging* 2022;31(04):917–932
- Mukund A, Mittal K, Mondal A, Sarin SK. Anatomic recanalization of hepatic vein and inferior vena cava versus direct intrahepatic portosystemic shunt creation in Budd-Chiari syndrome: overall outcome and midterm transplant-free survival. *J Vasc Interv Radiol* 2018;29(06):790–799
- Shukla A, Shreshtha A, Mukund A, et al. Budd-Chiari syndrome: consensus guidance of the Asian Pacific Association for the study of the liver (APASL). *Hepatol Int* 2021;15(03):531–567
- Makuuchi M, Hasegawa H, Yamazaki S, Moriyama N, Takayasu K, Okazaki M. Primary Budd-Chiari syndrome: ultrasonic demonstration. *Radiology* 1984;152(03):775–779
- Artru F, Moschouri E, Denys A. Direct intrahepatic portocaval shunt (DIPS) or transjugular transcaval intrahepatic portosystemic shunt (TTIPS) to treat complications of portal hypertension: Indications, technique, and outcomes beyond Budd-Chiari syndrome. *Clin Res Hepatol Gastroenterol* 2022;46(04):101858. Doi: 10.1016/j.clinre.2022.101858
- Liu L, Qi X-S, Zhao Y, Chen H, Meng X-C, Han G-H. Budd-Chiari syndrome: current perspectives and controversies. *Eur Rev Med Pharmacol Sci* 2016;20(15):3273–3281
- Perelló A, García-Pagán JC, Gilabert R, et al. TIPS is a useful long-term derivative therapy for patients with Budd-Chiari syndrome uncontrolled by medical therapy. *Hepatology* 2002;35(01): 132–139
- Sharma A, Keshava SN, Eapen A, Elias E, Eapen CE. An update on the management of Budd-Chiari syndrome. *Dig Dis Sci* 2021;66(06):1780–1790
- Jain SN. A pictorial essay: radiology of lines and tubes in the intensive care unit. *Indian J Radiol Imaging* 2011;21(03):182–190
- Li LH, Dang XW, Zhang G, et al. [Effect of thrombolytic therapy and influencing factors of Budd-Chiari syndrome with inferior vena cava thrombosis]. *Zhonghua Wai Ke Za Zhi* 2021;59(11):929–933 Chinese. Doi: 10.3760/cma.j.cn112139-20201219-00868.
- Swischuk JL, Smouse HB. Differentiating pharmacologic agents used in catheter-directed thrombolysis. *Semin Intervent Radiol* 2005;22(02):121–129
- Ouriel K, Gray B, Clair DG, Olin J. Complications associated with the use of urokinase and recombinant tissue plasminogen activator for catheter-directed peripheral arterial and venous thrombolysis. *J Vasc Interv Radiol* 2000;11(03):295–298