

Benign lymphoepithelial cyst of parotid gland: Review and case report

Jaya Joshi, Sonalee Shah¹, Deepak Agarwal², Ankit Khasgiwal

Departments of Oral Pathology and ²Oral Surgery, Government Dental College and Hospital, Indore, Madhya Pradesh, ¹Department of Oral Pathology, Government Dental College and Hospital, Raipur, Chhattisgarh, India

Abstract

Benign lymphoepithelial cyst (BLC), also known as branchial cyst, is an infrequent lesion usually occurs in the parotid gland or the lateral cervical area including lymph nodes. It occurs due to the process of lymphocyte-induced cystic ductular dilatation and is always diagnosed postoperatively by histopathological examination (HPE). These dysontogenetic lesions are usually found in the lateral neck but can also be located in the salivary glands, mostly in the parotids. A 35-year-old male reported to Government Dental College, Indore, before 3 years, with a soft, nontender, gradually increasing, compressible diffuse swelling involving the left parotid gland for the last 9–10 months of size 3.5 cm × 2.5 cm × 4.5 cm at the time of presentation with normal Stensen's duct and facial nerve function. ELISA test was negative, biochemistry indicated high protein content of aspirated fluid and magnetic resonance imaging showed hypertense cystic fluid in both T1- and T2-weighted images, suggesting high protein or hemorrhage and negating a solid lesion. Superficial parotidectomy was done with nonincidental healing. HPE of excisional tissue revealed it to be BLC.

Keywords: Benign lymphoepithelial cyst, branchial cyst, magnetic resonance imaging

Address for correspondence: Dr. Sonalee Shah, B-32, Staff Quarters, Government Dental College Campus, Rajbandha Maidan, Raipur - 492 001, Chhattisgarh, India.

E-mail: drsonaleeshah@gmail.com

Received: 30.11.2017, **Accepted:** 08.01.2018

INTRODUCTION

Bernier and Bhaskar introduced the term “lymphoepithelial cyst” to stress that this lesion is not an embryologic remnant and defined it as solitary or multiple cysts within lymph nodes associated with salivary glands. These authors postulated that benign lymphoepithelial cysts (BLCs) result from the cystic degeneration of salivary gland inclusions within lymph nodes. According to them, lymphoepithelial cysts (LECs) are considered distinct entities from the lymphoepithelial lesions. Other authors favor remnants of the branchial arch as the origin of BLCs and indeed, many cases have been reported as “branchial cysts.” Still

others believe it to be probably a dysontogenetic benign cyst originated from the epithelial remnants retained in lymphoid tissues during the embryogenesis or from branchial cleft epithelium.

Although these uncommon lesions have been reported in the periodical literature, and are mentioned in a variety of textbooks, their histopathologic characteristics often are incompletely described, and hence pathologists are not always familiar with them.^[1-5]

BLC has been widely recognized as a common cause of parotid gland enlargement in patients infected with HIV. In

Access this article online

Quick Response Code:



Website:

www.jomfp.in

DOI:

10.4103/jomfp.JOMFP_252_17

This is an open access article distributed under the terms of the Creative Commons Attribution-NonCommercial-ShareAlike 3.0 License, which allows others to remix, tweak, and build upon the work non-commercially, as long as the author is credited and the new creations are licensed under the identical terms.

For reprints contact: reprints@medknow.com

How to cite this article: Joshi J, Shah S, Agarwal D, Khasgiwal A. Benign lymphoepithelial cyst of parotid gland: Review and case report. J Oral Maxillofac Pathol 2018;22:S91-7.

general, cystic lesions of the parotid gland are uncommon and they comprise approximately 3% of all salivary gland tumors. Cysts of the salivary glands may originate as benign nonneoplastic entities or in association with benign and malignant tumors of the salivary glands. Nonneoplastic salivary gland cysts do require differentiation from cystadenoma, mucoepidermoid carcinoma and acinic carcinoma. Many cysts of the salivary glands may be generically attributed to an obstructive process. They can occur as a result of traumatic severance of salivary gland ducts, partial or complete blockage of the excretory ducts, or stasis of salivary flow in ducts. Patients of BLECs most commonly present in the fifth decade, and although duct obstruction appears to be the cause, the source of the obstruction is often not apparent. Most lesions are slowly enlarging painless swellings affecting a single gland. Hence, the diagnosis is seldom made preoperatively and sometimes a superficial parotidectomy is needed.^[6,7]

The cysts have equal distributions among males and females and usually present as a painless swelling in the parotid area without attachment to the facial nerve. They are rare, benign, slowly growing, uniloculated or multiloculated lesions that commonly occur in the head-and-neck region.^[7,8]

Lymphoepithelial (the so-called branchial) cysts are most often found in the lateral cervical area just below the angle

of the mandible, anterior to the sternocleidomastoid muscle. However, sometimes, they may occur in the parotid gland. They present a predilection to the lateral neck region, occurring less frequently in the oral cavity or in the parotid gland.^[7,9]

In the last few years, such cysts have been found in increasing numbers in AIDS patients as well as in the patients belonging to the AIDS risk groups. While the etiology of these cysts is controversial, the treatment is not. As the diagnosis is seldom made preoperatively, superficial parotidectomy or complete excision with sufficient margin of normal tissue surrounding is usually done.^[7,8,10]

CASE REPORT

Clinical history of patient

A 35-year-old male reported to Government Dental College, Indore, before 3 years, with a soft, non-tender compressible diffuse swelling involving the left parotid gland for the last 9–10 months. The swelling was noted to have gradually increased in size and was measuring 3.5 cm × 2.5 cm × 4.5 cm at the time of presentation [Figure 1]. It was a well-defined smooth-walled cystic lesion seen in the superficial lobe of the left parotid gland. The patient denied any history of trauma to the parotid area. The overlying skin was normal in color and freely moveable over the mass. The function of facial

Table 1: Tabulated review of online patient literature

Sex of patient	Age of patient	Lesion site	Author	Year	Number of patients
Most were males	21-30 years	Parotid gland	Lecene	1908	2
		Parotid gland	Belk	1927	10
		Parotid gland	Cunningham	1929	1
		Parotid gland	Gill	1936	2
		Parotid gland	Bernier and Bhaskar ^[2]	1958	5/468
		Left parotid region	Elmer Hofmann	1960	1
		Right parotid region	Elmer Hofmann	1960	1
		Parotid gland	Fujibayashi and Itoh ^[9]	1981	1
		Parotid gland	Gnepp and Sporck ^[3]	1980	1
		Parotid gland	Weidner <i>et al.</i> ^[11]	1986	3
		Parotid gland	Weidner <i>et al.</i> ^[11]	1986	2
		Left parotid region (multiple cysts)	Morris <i>et al.</i> ^[28]	1987	1
		Bilateral parotid involvement	Morris <i>et al.</i> ^[28]	1987	1
		Parotid gland	Camilleri and Lloyd ^[10]	1990	1
		Parotid gland	Elliot and Oertel ^[13]	1990	1
		Parotid gland	Antoniadis <i>et al.</i> ^[25]	1990	3
		Parotid gland	Townend ^[26]	1991	1
		Left parotid region	Agaton-Bonilla and Gay-Escoda ^[29]	1996	148/183
		Left parotid region	Rahman <i>et al.</i> ^[7]	2006	1
		Parotid gland	Sato <i>et al.</i> ^[27]	2008	Review of Japanese literature (52) +3
Male	18	Left posterior cervical region	Habib <i>et al.</i> ^[24]	2010	1
Male	48	Whole left parotid	Habib <i>et al.</i> ^[24]	2010	1
Female	Middle age	Parotid gland	Alves <i>et al.</i> ^[8]	2011	1
Female		Parotid gland	H Matsuzaki <i>et al.</i>	2012	1
Female		Left parotid region	Mhawej <i>et al.</i> ^[19]	2016	1
Male		Left parotid region	Pillai <i>et al.</i> ^[20]	2016	1
Female		Right parotid region	Khadiikar <i>et al.</i> ^[21]	2017	1
Male		Parotid gland	Aksoy <i>et al.</i> ^[22]	2015	1
Female		Left parotid region	Chaudhary <i>et al.</i> ^[23]	2017	1

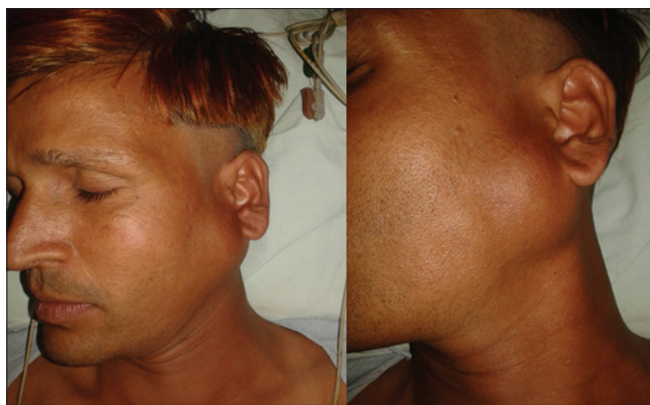

Figure 1: Soft, nontender compressible diffuse swelling involving the left parotid gland

nerve was normal. There was no associated regional lymphadenopathy or thyroid enlargement. Intraoral examination revealed a free flow of saliva from the left parotid (Stensen's duct) opening.

Provisional diagnosis

The preoperative diagnosis of this case remained uncertain as the nature and clinical symptoms resembled the other cystic lesions of the parotid gland such as retention cysts, extravasation cysts, or cystic degenerative salivary gland tumor.

Further investigations were done including orthopantomographic radiograph and lateral skull radiograph however, both revealed normal conditions.

Investigations done

1. ELISA-based HIV was nonreactive. In addition, the patient did not belong to the HIV high-risk group based on social and family histories
2. Biochemical investigation revealed high protein content
3. A simple magnetic resonance imaging (MRI) was done which showed "A well-defined, thin, smooth-walled cystic lesion within the superficial part of the left parotid gland measuring about 3.7 cm × 2.6 cm × 4.2 cm. The fluid content of the lesion appeared hypertense on T1 as well as T2-weighted imaging (WI), suggestive of high proteinaceous or hemorrhagic content with no solid component. MRI picture was, therefore, indicative of a benign cystic lesion of the left parotid gland with a differential diagnosis of branchial cleft cyst [Figure 2]
4. Fine-needle aspiration cytology (FNAC): FNA of the mass yielded a chocolate brown, hemorrhagic fluid which on cytological examination revealed sparsely cellular smear consisting of inflammatory

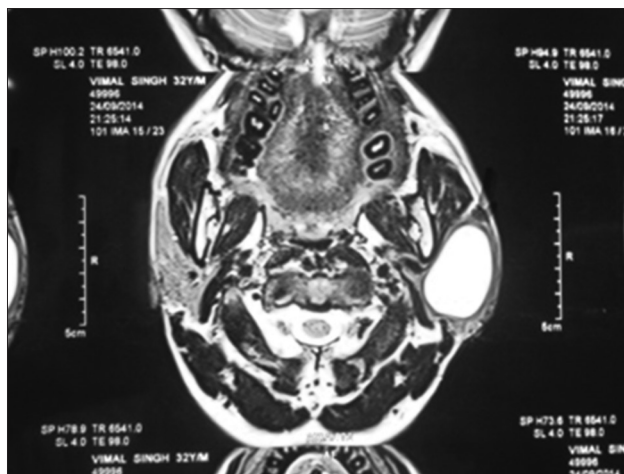


Figure 2: Simple magnetic resonance imaging of the neck

infiltrate predominantly with neutrophils, lymphocytes and cystic macrophages against a proteinaceous background suggestive of an infected cyst of the left parotid gland.

Hence, based on clinical presentation, aspiration and MRI, a final diagnosis of infected cyst of the left parotid gland was given.

The finding was explained and the patient agreed for the surgical excision of superficial parotid gland tissue under general anesthesia.

Treatment

After skin preparation with povidone solution, access to the cyst was made through the lower neck incision at the deepest neck crest which is found to be posteroinferior to the cyst. This helps to minimize the postoperative scarring and avoid from puncturing the cyst. The incision was then extended to the mastoid, posterior and inferior auricles. The incision was then performed layer by layer until it reached the platysma muscle. This muscle was dissected to expose the underneath cyst capsule. Once the plane between cyst capsule and platysma muscle was identified, the blunt dissection was carried out carefully separating the cyst from the sternocleidomastoid muscle posteriorly and the posterior belly of digastric muscle underneath with the preservation of facial nerve. However, the upper part of the cyst was found embedded in the parotid tissue, so part of the superficial lobe of the left parotid gland was excised together with the cyst. The specimen was then sent for histopathological examination (HPE).

Patient recovery was nonincidental with no evidence of facial nerve palsy and wound infection.

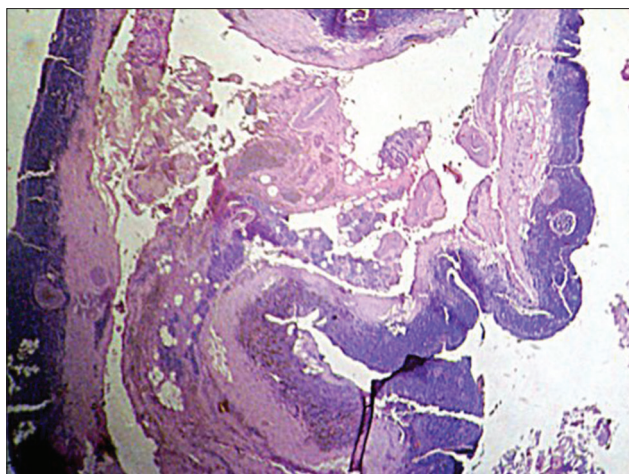


Figure 3: Scanner view shows cystic cavity lined by thin epithelium and adjacent C.T with Germinal centers

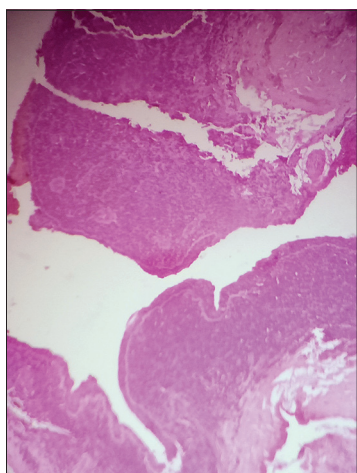


Figure 5: Highpower view of cystic cavity lined by thin epithelium & showing subadjacent C.T with germinal centers

Excisional biopsy

The HPE showed a collapsed cyst wall with adjacent salivary gland and small reactive lymphoid tissue. The cyst was lined by thin ciliated columnar epithelium in some areas, cuboidal in other areas and flat squamous cells in still other areas. However, no nuclear atypia was seen. The appearance was that of a Lymphoepithelial cyst (LEC). The lymphoid tissue was of both diffuse and follicular nature [Figures 3-7].

DISCUSSION

Clinical presentation

The clinical diagnosis of parotid cyst is often based on a slowly enlarging painless lump in the parotid region, the examination not always confirming the cystic nature of the lesion. Many authors presented the similar clinical presentation of these cysts which appears to be slow growing, painless swelling with normal movable overlying skin. The age and clinical symptoms of the present case were

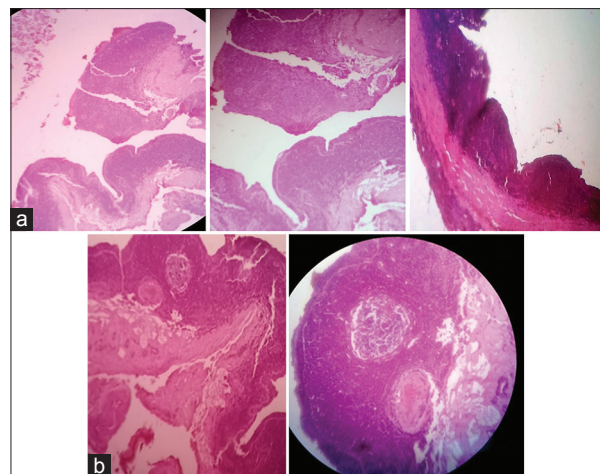


Figure 4: (a) Low-power magnification showing cystic cavity lined by thin epithelium and subadjacent connective tissue with germinal centers. (b) High-power magnification showing cystic cavity lined by thin epithelium and subadjacent connective tissue with germinal centers

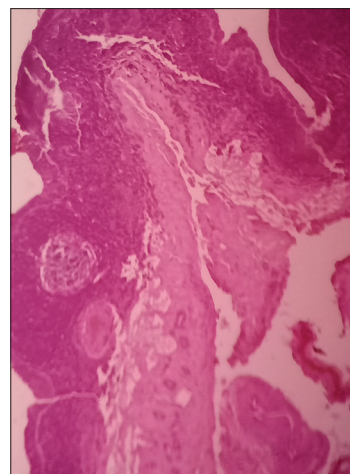


Figure 6: High-power view showing cystic cavity lined by thin epithelium and subadjacent connective tissue with germinal centers

also found to be consistent with the literature reviews.^[9,11]

Incidence

Lymphoepithelial (the so-called branchial) cysts within the parotid gland are rare. The first reported case of branchial cyst in the parotid gland was in 1895 by Hildebrant. Since then, about seventy cases of this type of cysts have been reported. Another 33 cases were found by Fujibayashi through a review of five publications which were concerning of either branchial cyst or parotid diseases. The ages of patients ranged from 16 to 69 years, with a mean age of 44 years [Table 1]. As observed by researchers as per Table 1, the distribution was found to be three times more frequent in males than in females. The majority of cases were unilateral with a greater number arising in the right parotid gland rather than the left gland.^[6,9,10,12,13] Our case was a middle-aged male patient.

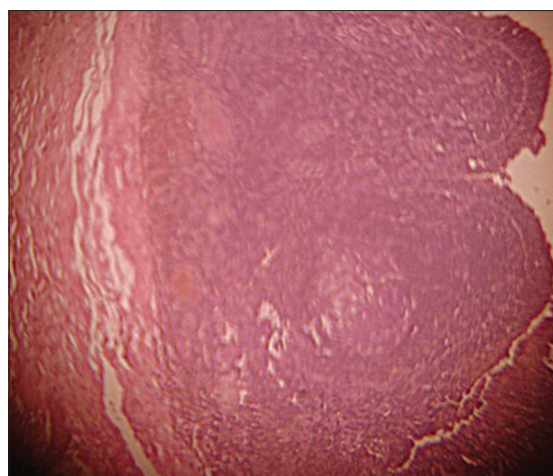


Figure 7: High-power magnification showing germinal centers with adjacent connective tissue

Site and progression

The most common sites for LECs were in the lateral cervical area. The parotid gland is the preferential site for these cysts to occur and this is probably due to the presence of intraparotid lymph nodes in the glands which are absent in all the other salivary glands. However, in the review of 468 cases of branchial cyst from the file of the Armed Forces Institute of Pathology, only five cases were located in the parotid area. In addition, a review of 149 cases of Branchial cysts reported that only 14 cases were found at the upper part of the neck above the angle of the mandible.^[1,7,11] In our case also, the lesion occurred at the left angle of mandibular region.

LEC can grow to large proportions and may lead to disfigurements. The LECs have equal gender distribution and they may be single or multiple and unilateral or bilateral [Table 1].

Etiopathogenesis

The origin and development of branchial cysts is a controversial subject, and many theories have been suggested. The theories simply attempt to collate the known embryological facts with histological and clinical findings. However, to this day, the controversy still exists and at least four theories have been put forward to explain the origins of branchial cysts, which are as follows:^[7,10]

1. Branchial apparatus cleft theory (Rickles and Little, 1967)
2. Cervical sinus theory
3. Thymus-pharyngeal duct theory (Wenglowski, 1913), later supported by Meyer and McNealy
4. Parotid gland inclusion theory (Bashkar and Bernier, 1959).

The first two theories are also known as classic theories which hold that the cysts develop from the remnants of

the branchial cleft because they occur in the area of the embryonic gill apparatus. However, for the present case, the inclusion theory or the so-called recent theory would seem the most feasible explanation for the LEC which was found in the parotid gland, where this theory considers that the cysts arise from cystic changes in parotid gland epithelium that become entrapped in the upper cervical lymph nodes during embryonic life.^[2]

Hence, it is considered that the epithelial remnants of the parotid gland can give rise to LEC inside the parotid gland and cervical lymph nodes.

These parotid cysts are usually seen in HIV-positive patients, generally as one of the signs of this infection. There are two peculiarities that distinguish the cyst associated with HIV: frequent bilateral occurrence and multicystic appearance observed in computed tomography (CT) or MRI.

Also, the greatest problem related to the LEC in HIV-positive patients seems to be the progression to a lymphoma, which increases the responsibility for HIV infection investigation, as in the present case.^[8,14,15]

Types

The main types of lymphoepithelial cyst that can be found in the parotid gland are as follows:

1. Simple cysts, comparable with both the extravasation and retention type of mucocele
2. Larger LECs, which are mainly congenital, but also reported in AIDS patients
3. A polycystic disease of the parotid gland, a developmental disorder which is seen bilaterally, especially in females
4. Cystic tumors.

A review of 100 cases found parotid cyst to be the most common nonneoplastic disease (10%). Histologically, seven were simple cysts and two were LECs in that review.^[16-18]

Investigations

Investigations are important for diagnosis and treatment planning of these lesions. FNA biopsy is useful in certain cases. Ultrasound is useful in showing cystic nature of the lesion. CT and MRI provide clear image of the lesion and reveal intraparotid cystic masses. Management of such lesions should be superficial parotidectomy when a conservative approach cannot safely remove the lesion.^[17,18]

In our case, FNAC indicated the presence of inflammatory cells in proteinaceous background and MRI indicated a cystic lesion with negative ELISA test.

The definitive diagnosis of the cystic lesion of the parotid gland depends solely on Histopathological examination (HPE) as also in our case.

Within the category of BLECs, various types of epithelium have been described. The most frequent has been squamous, but variable combinations of cuboidal, columnar, ciliated columnar and mucin-producing epithelia also have been reported. In addition, rare examples of squamous epithelium containing sebaceous differentiation have been documented.^[1,2]

The characteristic histopathologic pattern is that of a glandular or squamous epithelium-lined cleft surrounded by abundant lymphoid tissue with prominent germinal centers, with some specimens even containing salivary gland tissue and ducts,^[19] as shown in Figure 3a.

The histologic picture in the present case was in accordance with that of a LEC, where the epithelial-lined cysts were observed in a lymph node, adjacent to or embedded in a major salivary gland. In the review of literatures by Skouteris *et al.*, 1989, they reported that more than 90% of these cysts were lined by stratified squamous epithelium that might or might not be keratinized. Some cysts demonstrated respiratory epithelium. However, there were reported cases where the cysts were lined by either columnar or cuboidal epithelium which was consistent with our present case.^[12,13]

Differential diagnosis

The differential diagnosis of parotid LEC includes Warthin's tumor, intramuscular benign hemangioma (IMH), branchial cleft cyst and lymphoma. MRI is the imaging modality of choice and helps in characterizing the lesion. IMHs are typically multiloculated and resemble a "bunch of grapes." They are isointense on T1-WI and hyperintense on T2-WI and show a heterogeneous peripheral enhancement after contrast administration. Warthin's tumors show similarly low signal on T1-WI and moderate-to-high signal on T2-WI with, however, no rim enhancement after contrast injection.^[19]

Thus far, BLECs have neither been known to recur nor metastasize. For this reason, it is important that they should be differentiated from aggressive lesions, especially cystic low-grade mucoepidermoid carcinoma. The potential for this problem in differential diagnosis is underscored by the recent report of a low-grade mucoepidermoid carcinoma arising within an intraparotid lymph node.^[1,2]

As the diagnosis is seldom made preoperatively, complete excision with sufficient margin of normal tissue surroundings or superficial parotidectomy is usually done as a curative treatment.

Declaration of patient consent

The authors certify that they have obtained all appropriate patient consent forms. In the form the patient(s) has/have given his/her/their consent for his/her/their images and other clinical information to be reported in the journal. The patients understand that their names and initials will not be published and due efforts will be made to conceal their identity, but anonymity cannot be guaranteed.

Financial support and sponsorship

Nil.

Conflicts of interest

There are no conflicts of interest.

REFERENCES

- Weidner N, Geisinger KR, Sterling RT, Miller TR, Yen TS. Benign lymphoepithelial cysts of the parotid gland. A histologic, cytologic, and ultrastructural study. *Am J Clin Pathol* 1986;85:395-401.
- Bernier JL, Bhaskar SN. Lymphoepithelial lesions of salivary glands; histogenesis and classification based on 186 cases. *Cancer* 1958;11:1156-79.
- Gnepp DR, Sporeck FT. Benign lymphoepithelial parotid cyst with sebaceous differentiation – Cystic sebaceous lymphadenoma. *Am J Clin Pathol* 1980;74:683-7.
- Richardson GS, Clairmont AA, Erickson ER. Cystic lesions of the parotid gland. *Plast Reconstr Surg* 1978;61:364-70.
- Peel R, Gnepp DR. Diseases of the salivary glands. In: Barnes L, editor. *Surgical Pathology of the Head and Neck*. New York: Marcel Dekker; 1985. p. 550-2.
- Kumar KM, Soni R, Sravan C, Indira V. Diagnostic misdiagnosis of lymphoepithelial cyst of the parotid in a HIV patient. *Indian J Basic Appl Med Res* 2014;3:362-6.
- Rahman S, Shaari R, Hassan R. Parotid lymphoepithelial cyst: A case report. *Arch Orolfac Sci* 2006;1:71-5.
- Alves CA, Ribeiro Júnior O, Borba AM, Souza SC, Naclério-Homem MG. Parotid lymphoepithelial cyst in non-HIV patient. *J Clin Exp Dent* 2011;3 Suppl 1:e400-3.
- Fujibayashi T, Itoh H. Lymphoepithelial (so-called branchial) cyst within the parotid gland. Report of a case and review of the literature. *Int J Oral Surg* 1981;10:283-92.
- Camilleri AC, Lloyd RE. Lymphoepithelial cyst of the parotid gland. *Br J Oral Maxillofac Surg* 1990;28:329-32.
- Rickles NH, Little JW. The histogenesis of the branchial cyst. II. A study of the lining epithelium. *Am J Pathol* 1967;50:765-77.
- Skouteris CA, Patterson GT, Sotereanos GC. Benign cervical lymphoepithelial cyst: Report of cases. *J Oral Maxillofac Surg* 1989;47:1106-12.
- Elliott JN, Oertel YC. Lymphoepithelial cysts of the salivary glands. Histologic and cytologic features. *Am J Clin Pathol* 1990;93:39-43.
- Marmar Y, Gomori JM, Nitzan DW. Lymphoepithelial parotid cysts as presenting symptom of immunodeficiency virus infection: Clinical, sialographic, and magnetic resonance imaging findings. *J Oral Maxillofac Surg* 1990;48:981-4.
- Maynard JD. Solitary cysts of the parotid. *Br J Surg* 1988;75:1043.

16. Droese M. Cytological diagnosis of sialadenosis, sialadenitis, and parotid cysts by fine-needle aspiration biopsy. *Adv Otorhinolaryngol* 1981;26:49-96.
17. Ward-Booth RP, Williams ED, Faulkner TP, Earl PD. Ultrasound: A simple noninvasive examination of cervical swellings. *Plast Reconstr Surg* 1984;73:577-81.
18. Nisha VA, Parthiban J, Manigandan T, Amudhan A, Saravanakumar B. Infected Parotid cyst – A case Report with Review of Literature. *Biosci Biotech Res Asia* 2014;11:165-7.
19. Mhawej R, Richa T, Melkane AE. Benign lymphoepithelial cyst of unusual location: A case report. *Acta Otolaryngol Case Rep* 2016;1:110-2.
20. Pillai S, Agarwal AC, Mangalore AB, Ramaswamy B, Shetty S. Benign lymphoepithelial cyst of the parotid in HIV negative patient. *J Clin Diagn Res* 2016;10:MD05-6.
21. Khadilkar MN, Prasad V, Santhoor VS, Kamath MP, Domah H. Lymphoepithelial cyst of parotid in an immunocompetent patient with chronic otitis media. *Case Rep Otolaryngol* 2017;2017: 5169364.
22. Aksoy S, Günhan Ö. Benign lymphoepithelial cyst of parotid gland in a HIV seronegative patient. *Oral Surg Oral Med Oral Pathol Oral Radiol* 2015;119:e200.
23. Chaudhary S, Zaheer S, Sharma P, Mandal A. Benign Lymphoepithelial Cyst in an Adolescent Female Mimicking Lymphoma: A diagnostic Dilemma in a retrovirus negative patient. *Ann Pathol Lab Med* 2017; 4:C98-101.
24. Habib S, Rahman MM, Choudhury AA, Kamal M. Benign lymphoepithelial cyst – A rare case. *Bangladesh J Otorhinolaryngol* 2010;16:60-5.
25. Antoniadis K, Karakasis D, Tzarou V, Skordalaki A. Benign cysts of the parotid gland. *Int J Oral Maxillofac Surg* 1990;19:139-40.
26. Townend J. Lymphoepithelial cyst of the parotid gland. *Br J Oral Maxillofac Surg* 1991;29:138-9.
27. Sato Y, Omura K, Harada H, Shimamoto H, Sawai T. Lymphoepithelial cyst arising in the parotid gland; A report of 3 cases. *Kokubyo Gakkai Zasshi* 2008;75:162-7.
28. Morris MR, Moore DW, Shearer GL. Bilateral multiple benign lymphoepithelial cysts of the parotid gland. *Otolaryngol Head Neck Surg* 1987;97:87-90.
29. Agaton-Bonilla FC, Gay-Escoda C. Diagnosis and treatment of branchial cleft cysts and fistulae. A retrospective study of 183 patients. *Int J Oral Maxillofac Surg* 1996;25:449-52.