

Evaluation of aesthetic anteroposterior position of maxillary incisors in patients with extraction treatment using facial reference lines

Danqing He, Yan Gu and Yannan Sun

Abstract

Objective: To examine whether facial reference lines could be used to evaluate the anteroposterior position of the maxillary incisors in patients that had undergone extraction treatment.

Methods: The study enrolled Angle Class I patients who had favourable facial profiles after extraction treatment. Superimposition of post-treatment lateral photographs and cephalograms were constructed and anatomical landmarks on the forehead were identified. Reference lines of the forehead's anterior limit line (FALL) and the vertical line through the soft-tissue glabella (G line) were constructed. The distance between the maxillary incisors and the FALL and G line were measured. Regression analyses were performed between the maxillary incisor position and forehead inclination.

Results: Forty-one patients (31 females and 10 males) were included in the study. The mean \pm SD distances of the facial-axis point of the maxillary incisors (FA)–FALL and FA–G line were 1.8 ± 1.9 mm and -2.4 ± 1.8 mm, respectively. The distance of the maxillary incisors to FALL and the relative position of the maxillary incisors were both significantly correlated with forehead inclination.

Conclusions: The mean position of the maxillary incisors in patients with extraction was approximately in the middle of the G line and the FALL. Correct maxillary incisor position was correlated with forehead inclination.

Keywords

Aesthetics, soft tissue, maxillary incisors, antero-posterior position, facial reference lines

Date received: 29 October 2018; accepted: 24 April 2019

Department of Orthodontics, Peking University School and Hospital of Stomatology, National Engineering Laboratory for Digital and Material Technology of Stomatology, Beijing Key Laboratory of Digital Stomatology, Beijing, China

Corresponding author:

Yannan Sun, Department of Orthodontics, Peking University School and Hospital of Stomatology, National Engineering Laboratory for Digital and Material Technology of Stomatology, Beijing Key Laboratory of Digital Stomatology, 22 Zhongguancun Nandajie, Haidian District, Beijing 100081, China.
Email: bdsunyannan@163.com



Creative Commons Non Commercial CC BY-NC: This article is distributed under the terms of the Creative Commons Attribution-NonCommercial 4.0 License (<http://www.creativecommons.org/licenses/by-nc/4.0/>) which permits non-commercial use, reproduction and distribution of the work without further permission provided the original work is attributed as specified on the SAGE and Open Access pages (<https://us.sagepub.com/en-us/nam/open-access-at-sage>).

Introduction

Facial attractiveness, especially profile attractiveness, plays an important role in people's daily social communications. When judging the facial smiling profile, the position of the maxillary incisors is one of the most important elements people are concerned about.¹ In modern orthodontic treatment, one of the most important treatment goals is to establish a correct maxillary incisor position, which plays a critical role in achieving favourable facial profiles. For patients with extraction orthodontic treatment, the change of the soft tissue profile during orthodontic treatment is strongly associated with the horizontal movement of the maxillary incisors.² Therefore, it is very important for orthodontists to determine the correct maxillary incisor position when developing treatment plans for extraction patients.

Increasing emphasis has been given to the position and the inclination of the maxillary incisors due to their significance in the determination of favourable facial profiles.² Most of the studies suggest that a favourable maxillary incisor position exists within a certain range.²⁻⁵ However, these studies altered the anteroposterior (AP) position of the maxillary incisor and simulated the changes of the soft tissue in one photograph using a computer-aided method,²⁻⁵ which might be different from the real profile changes. The correct position of the maxillary incisors in orthodontic patients remains controversial.

Traditional cephalometric analyses have been proposed previously to evaluate the position of the incisors.⁶⁻⁸ However, measurements of the position and inclination of the maxillary incisors could not be used to predict the soft tissue profile changes directly, since soft tissue alterations were not always consistent with the hard tissue changes.^{9,10} Therefore, it is important to find a feasible way to simultaneously

evaluate the maxillary incisor position and the related facial profile changes.

The forehead contour is one of the important components of facial profile attractiveness.^{11,12} Landmarks on the forehead are stable, repeatable and easy to locate. Previous studies examined the relationship between the maxillary incisors and external facial landmarks on the forehead simultaneously and found that external facial landmarks on the forehead could be used to evaluate the AP position of the maxillary central incisors of white adult males and females with good facial profiles.¹³⁻¹⁶ These studies provided a feasible method to evaluate maxillary incisor position using facial landmarks and reference lines directly.¹⁴⁻¹⁷ However, hard and soft tissue structures showed significant differences between different ethnic groups.¹⁸⁻²⁰ In comparison with Caucasians, the Asian population showed a higher degree of lip protrusion and a more convex facial profile.¹⁸⁻²⁰ A greater vertical dimension and less prominent chin protrusion were also found in the Asian population compared with Caucasians.¹⁸⁻²⁰ Whether facial landmarks of the forehead can be used to evaluate proper maxillary incisor position of Asian orthodontic patients is an important question concerning Asian orthodontists.

This study aimed to examine whether facial reference lines and facial landmarks on the forehead could be used to evaluate the AP position of the maxillary incisors in patients that had undergone extraction treatment, and to illustrate whether facial reference lines and landmarks could help in developing treatment plans.

Patients and methods

Patient population

This retrospective study enrolled consecutive orthodontic patients who had completed extraction treatment in the Department

of Orthodontics, Peking University School and Hospital of Stomatology, Beijing, China between January 2015 and June 2017. The inclusion criteria were as follows: (i) Angle Class I patients (i.e. the mesiobuccal cusp of the upper first molar occludes with the buccal groove of the lower first molar as normal, but characterized by crowding, rotations, and other positional irregularities) of Mongolian ethnic background who had finished extraction treatment of four premolars; (ii) post-treatment profiles were considered satisfactory when evaluated by three experienced orthodontists; (iii) skeletal and soft tissue parameters of post-treatment cephalometric analyses were within the normal range (Table 1).²⁰

The Review Board of Peking University School of Stomatology approved the study design (no. PKUSSIRB-201626002). Signed informed consent was obtained from each patient's parents or legal guardians.

Study methods

Post-treatment lateral photographs of the patients with the forehead fully bared were imported into Adobe Photoshop software (Adobe Systems, San Jose, CA, USA)

and rotated to an estimated upright head position as described previously,¹⁴ which was confirmed by two independent observers (D.H. and Y.S.). Post-treatment lateral cephalograms were also imported into Adobe Photoshop and superimposed with individual photographs, using maximum superimposition of the forehead and with the Nasion point as the rotation centre. The superimposed images were used to evaluate the correct position of the maxillary incisors. Anatomical landmarks on the forehead and maxillary incisors were identified as previously described and marked on each image in Adobe Photoshop software (Figure 1).¹⁴ The superior was defined as the most superior aspect of the clinical forehead when the forehead was either rounded or angular in contour. The soft tissue glabella (G point) was defined as the most prominent point in the midsagittal plane of the forehead. The forehead's facial-axis point (FFA point) was defined as the midpoint of the forehead between the superior and the G point for foreheads with rounded or angular contours. The facial-axis point of the maxillary central incisors (FA point of U1) was defined as the central point of the clinical crown of the maxillary central incisors.

Table 1. Definitions of cephalometric measurements used in a study of patients that had completed extraction treatment.

Measurement	Definition
SNA, °	Angle between Sella-Nasion and Nasion – A point
SNB, °	Angle between Sella-Nasion and Nasion – B point
ANB, °	SNA minus SNB
UI/NA, °	Angle formed by the long axis of the upper incisor to a line from Nasion to point A
UI–NA, mm	Distance between the tip of the upper incisor and a line from Nasion to point A
UI/LI, °	Angle between the upper incisor axis and the lower incisor axis
UI/SN, °	Angle from the upper incisor to the Sella–Nasion plane
LI/MP, °	Angle between the lower incisor axis and the mandibular plane
Naso-labial angle, °	Angle between a line of the midpoint of the nostril aperture to subnasale and a line of subnasale to upper lip
Z angle, °	Angle between the Frankfore plane and a line through the pogonion and the most prominence point of the upper or lower lip

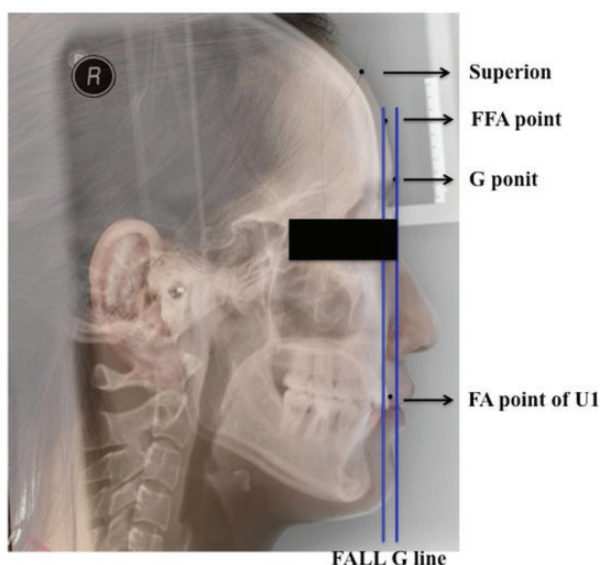


Figure 1. Anatomical landmarks and reference lines shown on a superimposed lateral image of a face. G point, soft tissue glabella; FFA point, the forehead's facial-axis point; FA point of U1, the facial-axis point of the maxillary incisors; FALL, forehead's anterior limit line, a vertical reference line through the FFA point; G line, a vertical reference line through the soft-tissue glabella point.

Two vertical facial reference lines were constructed: (i) the forehead's anterior limit line (FALL) was a vertical reference line through the FFA point; and (ii) the G line was a vertical reference line through the G point. Forehead inclination was the angle between the line through the G point to the superior and FALL. The distances from the maxillary incisors to the FALL (FA–FALL) and G line (FA–G line) were measured. A positive value was assigned when the maxillary incisors were anterior to the reference line and negative when they were posterior to the reference line. Furthermore, the distance between the FALL and G line was measured. The position of the G line was defined as 0 and the position of FALL as –1 to evaluate the relative position of the maxillary incisors to these two reference lines.

All measurements were repeated three times by the same examiner (D.H.) with a

time interval of 1 week. The mean value of these three measurements was used for statistical analyses. Intra-observer reliability was calculated by means of intra-class correlation coefficient by randomly selecting 10 patients.

Statistical analyses

All statistical analyses were performed using the SPSS[®] statistical package, version 16.0 (SPSS Inc., Chicago, IL, USA) for Windows[®]. The mean \pm SD and 95% confidence intervals (CI) were calculated for the maxillary incisor position relative to the FALL and G line. A simple second-order regression analyses was performed between the maxillary incisor position and forehead inclination. Groups with different sexes and forehead contours were compared using independent two-tailed *t*-test or one-way analysis of variance. A *P*-value < 0.05 was considered statistically significant.

Results

This study analysed data retrieved from 41 orthodontic patients who had completed extraction treatment and had post-treatment profiles that were considered satisfactory. The sample included 31 female and 10 male patients, with a mean \pm SD age of 16.8 ± 4.4 years (range, 12.0–26.0 years). Intra-observer reliability was good for all measurements with a mean correlation coefficient of 0.945

Table 2. Post-treatment cephalometric measurements of patients ($n = 41$) that had completed extraction treatment.

Measurement ^a	Normal values	Patient measurements
SNA, °	82.8 ± 4.0	82.8 ± 2.0
SNB, °	80.1 ± 3.9	80.4 ± 2.2
ANB, °	2.7 ± 2.0	2.4 ± 1.0
UI/NA, °	22.8 ± 5.7	22.9 ± 3.8
UI–NA, mm	5.1 ± 2.4	4.1 ± 2.0
UI/LI, °	125.4 ± 7.9	127.6 ± 5.3
UI/SN, °	105.7 ± 6.3	105.2 ± 4.2
LI/MP, °	92.6 ± 7.0	92.2 ± 3.8
Naso-labial angle, °	103.9 ± 9.5	103.0 ± 3.7
Z angle, °	70–80	74.7 ± 3.1

Data presented as mean \pm SD or range.

^aSee Table 1 for definitions of the cephalometric measurements.

(range 0.92–0.97). Cephalometric measurements for all patients were within the normal range (Table 2). The mean \pm SD and 95% CIs for the forehead inclination, the distance measurements and the relative position of the maxillary incisors are presented in Table 3. The mean forehead inclination was $15.2 \pm 3.3^\circ$. The mean \pm SD distance between the FALL and G line was 4.2 ± 1.1 mm. For the distance measurements of the maxillary incisors to the facial reference lines, the mean \pm SD distance for the FA–FALL and FA–G line were 1.8 ± 1.9 mm and -2.4 ± 1.8 mm, respectively. For the relative position of the maxillary incisors (FA relative position), the mean \pm SD position was -0.6 ± 0.5 . In total, 37 of 41 (90.2%) patients had their maxillary incisors positioned at the G line or between the G line and the FALL.

Significant positive correlations were observed between the distance for the FA–FALL and the relative position of the maxillary incisors with forehead inclination (Table 4), with correlation coefficients of 0.556 ($P < 0.001$) and 0.404 ($P = 0.009$), respectively (Figures 2 and 3).

No significant differences were found for the forehead inclination and the maxillary incisor position between males and females

Table 3. Forehead inclination post-treatment and distance measurements of maxillary incisors of patients ($n = 41$) that had completed extraction treatment.

Measurement	Study cohort $n = 41$	95% confidence interval	
		Lower	Upper
Forehead inclination, °	15.2 ± 3.3	14.2	16.2
FFA–G, mm	4.2 ± 1.1	2.0	6.4
FA–FALL, mm	1.8 ± 1.9	1.2	2.4
FA–G line, mm	-2.4 ± 1.8	-3.0	-1.8
FA relative position	-0.6 ± 0.5	-0.8	-0.4

Data presented as mean \pm SD.

See Figure 1 for anatomical sites: FFA, forehead's facial-axis point; G, soft-tissue glabella point; FA, facial-axis point of the maxillary incisors; FALL, forehead's anterior limit line; G line, a vertical reference line through the soft-tissue glabella point. Positive values indicate anterior to the reference line.

Table 4. Correlations between maxillary incisor position and forehead inclination measurements of patients ($n = 41$) that had completed extraction treatment.

Measurement	Mean	SD	R^2	Statistical significance ^a
Forehead inclination, °	15.2	3.3		
FA–FALL, mm	1.8	1.9	0.556	$P < 0.001$
FA–G line, mm	–2.4	1.8	0.108	NS
FA relative position	–0.6	0.5	0.404	$P = 0.009$

^aIndependent two-tailed t -test; NS, no significant correlation ($P \geq 0.05$).

See Figure 1 for anatomical sites: FA, facial-axis point of the maxillary incisors; FALL, forehead's anterior limit line; G line, a vertical reference line through the soft-tissue glabella point.

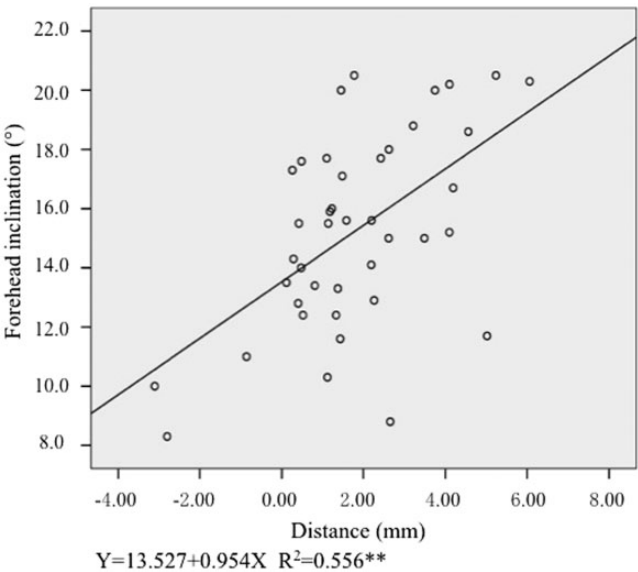


Figure 2. Correlation analysis between the distance from the facial-axis point of the maxillary incisors (FA) to the forehead's anterior limit line (FALL) and the forehead inclination in patients ($n = 41$) that had completed extraction treatment. $R^2 = 0.556$, $P < 0.001$.

(Table 5). There were no significant differences found for the maxillary incisor position between groups with different forehead contours (Table 6).

Discussion

An increasing number of investigators have put forward the idea that the maxillary incisors have an important impact on facial

profile aesthetics.^{3,18} For patients undergoing extraction orthodontic treatment, one of the major contributing factors predicting changes in the soft tissue profile is the movement of the most anterior point of the maxillary incisor.^{19,20} Determination of the correct maxillary incisor position has become very important in developing treatment plans for orthodontic patients. This current study found that both facial

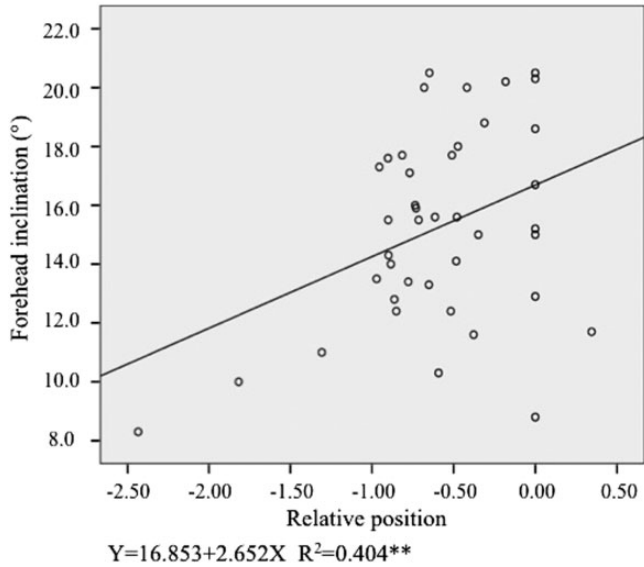


Figure 3. Correlation analysis between the relative position of the maxillary incisors and the forehead inclination in patients ($n = 41$) that had completed extraction treatment. $R^2 = 0.404$, $P = 0.009$.

Table 5. Comparison of maxillary incisor position between male and female patients ($n = 41$) that had completed extraction treatment.

Measurement	Males $n = 10$	Females $n = 31$
Forehead inclination, °	15.8 ± 3.5	15.1 ± 3.3
FA–FALL, mm	2.1 ± 1.5	1.7 ± 2.0
FA–G line, mm	-3.0 ± 1.9	-2.2 ± 1.7
FA relative position	-0.6 ± 0.3	-0.6 ± 0.5

Data presented as mean \pm SD.
Independent two-tailed t -test; no significant between group differences ($P \geq 0.05$).
See Figure 1 for anatomical sites: FA, facial-axis point of the maxillary incisors; FALL, forehead’s anterior limit line; G line, a vertical reference line through the soft-tissue glabella point.

references lines (FALL and G line), as well as landmarks on the forehead, could be used to evaluate the correct AP position of the maxillary incisor in patients that have undergone extraction treatment. In most of the patients with satisfactory post-treatment profiles in the current study, the maxillary incisors were positioned at or

Table 6. Comparison of maxillary incisor position in patients ($n = 41$) stratified according to their forehead contours.

Measurement	Angular forehead $n = 20$	Oblique forehead $n = 11$	Rounded forehead $n = 10$
FA–FALL, mm	1.5 ± 2.1	2.8 ± 1.8	1.4 ± 1.2
FA–G line, mm	-2.3 ± 1.9	-2.0 ± 2.0	-3.1 ± 1.1
FA relative position	-0.7 ± 0.6	-0.4 ± 0.4	-0.7 ± 0.2

Data presented as mean \pm SD.
One-way analysis of variance; no significant between group differences ($P \geq 0.05$).
See Figure 1 for anatomical sites: FA, facial-axis point of the maxillary incisors; FALL, forehead’s anterior limit line; G line, a vertical reference line through the soft-tissue glabella point.

between the G line and FALL, which were also correlated with forehead inclination.
The orthodontic patients in this current study were all considered to have satisfactory profiles and well-positioned maxillary incisors according to cephalometric analyses. The age range of the patients was large,

which might have led to a relatively large standard deviation of the measurements. The superimposed images of post-treatment lateral photographs and lateral cephalograms were used in this study, which presented maxillary incisor images and soft tissue profiles simultaneously. These superimposed images could assist in evaluating the proper position of the maxillary incisors using facial reference lines directly.

Cephalometric analyses are frequently used to evaluate the position and inclination of the maxillary incisors, including the distance and angulation measurements of the maxillary incisors to the hard tissue reference lines. However, it was hard to predict the soft tissue changes using only hard tissue analyses since soft tissue alterations are not always consistent with the hard tissue changes.^{9,10} Using external facial landmarks on the forehead to evaluate the AP position of the maxillary central incisors in white adults has previously been suggested.^{14,15} However, significant hard and soft tissue differences exist between Asian and Caucasian populations with normal occlusions and well-balanced faces.^{21–23} In comparison with Caucasians, Asian individuals show a higher degree of lip protrusion, a more convex facial profile, a greater vertical dimension and less prominent chin protrusion.^{21–23} Therefore, investigating whether facial landmarks on the forehead and facial reference lines can be used to evaluate proper maxillary incisor position in Asian orthodontic patients is necessary.

In this current study, the mean maxillary incisor position was 2.4 mm posterior to the G line and 1.8 mm anterior to the FALL. Moreover, these current results showed that the mean \pm SD relative position of the maxillary incisors was -0.6 ± 0.5 , which indicated that the maxillary incisors were positioned approximately in the middle of the G line and the FALL. Among the patients in the current study, 90.2% had maxillary central incisors positioned at or

between the G line and the FALL. These findings were comparable with previous studies.^{15,16} In these previous studies, 93% of white adult females and 91% of white adult males with harmonious facial profiles had maxillary central incisors positioned somewhere at or between the FFA point and the glabella.^{15,16}

These current results also showed relatively strong positive correlations between the distance of FA–FALL ($R^2=0.556$) and the relative position of the maxillary incisors ($R^2=0.404$) with forehead inclination, which was consistent with a previous study.¹⁵ These current results indicated that the facial reference lines of G line and FALL could be used as the anterior and posterior limit lines to evaluate the correct maxillary incisor position in patients who had undergone extraction treatment. The position of the maxillary incisors should be closer to the G line with increasing forehead inclination.

Although differences exist in hard and soft tissue structures between different ethnic groups, the forehead inclination is considered to be stable.²² Previous research demonstrated that the slope of the forehead showed no significant ethnic difference between Korean and European-Americans.²² Forehead position is also stable during orthodontic treatment. Unlike internal radiographic landmarks, landmarks on the forehead are easy to locate, and their relationship to the incisors is predictable and repeatable.¹⁵ Consequently, evaluating the correct maxillary incisor position and facial attractiveness of orthodontic patients using facial reference lines through facial landmarks on the forehead would be more convenient and stable.

In this current study, patients with different forehead contours were investigated to explore their influence on maxillary incisor position. The current study found that in addition to rounded and angular contours,¹⁴ some Chinese patients exhibited an oblique forehead contour. The results

of this current study showed that no difference was found in maxillary incisor position among the patients with different forehead contours, which suggests that maxillary incisor position was correlated with forehead inclination instead of forehead contour. Nevertheless, forehead morphology varies in most people of different sexes and ethnic background and thus the results should be interpreted with caution.

In addition, no significant difference was found between males and females in terms of the correct maxillary incisor position. This finding was similar to that of previous studies, which showed a similar distribution of preferred maxillary incisors in white adult females and males.^{15,16} Nevertheless, more patients should be recruited in the future to further confirm the correct position of the maxillary incisors in orthodontic patients as well as to detect whether the standard for preferred maxillary incisor position is consistent between different sexes or different forehead contours.

Many factors in addition to the AP position of the maxillary incisors, including jaw position, labiolingual inclination of the maxillary anterior teeth and soft tissue changes, should be considered in order to obtain a balanced smiling profile. A previous study found that normal incisor inclination was the best choice in both retruded and protruded mandibles, whereas retroclined incisors were regarded as the least attractive images in different kinds of mandibular position.²⁴ It has been suggested that a proclination of 5° of the maxillary incisors in the smiling profile is acceptable.²⁵ Profiles with 15° of proclination received the lowest scores.³ Therefore, when developing an orthodontic treatment plan, it is important for orthodontists to consider establishing the maxillary incisors in the correct AP position with favourable inclination, while coordinating the maxillary incisor position with jaw position in order to achieve harmonious facial profiles.

In addition, appropriate anchorage type and treatment mechanics should be chosen in order to achieve the correct maxillary incisor position and inclination.

In conclusion, the mean position of maxillary incisors in patients that had undergone extraction treatment was 2.4 mm posterior to the G line, approximately in the middle of the G line and the FALL. Correct maxillary incisor position was correlated with forehead inclination, which should be closer to the G line with increasing forehead inclination. These current results indicate that the facial reference lines, FALL and G line, are stable and practical to use to evaluate the correct position of the maxillary incisors in orthodontic patients, which can help in developing treatment plans.

Declaration of conflicting interest

The authors declare that there are no conflicts of interest.

Funding

This work was supported by grants from the National Science Foundations of China (no. 81600893) and the Youth Research Fund of Peking University School and Hospital of Stomatology (YS020215).

References

1. McKiernan EX, McKiernan F and Jones ML. Psychological profiles and motives of adults seeking orthodontic treatment. *Int J Adult Orthodon Orthognath Surg* 1992; 7: 187–198.
2. Schlosser JB, Preston CB and Lampasso J. The effects of computer-aided anteroposterior maxillary incisor movement on ratings of facial attractiveness. *Am J Orthod Dentofacial Orthop* 2005; 127: 17–24.
3. Cao L, Zhang K, Bai D, et al. Effect of maxillary incisor labiolingual inclination and anteroposterior position on smiling profile esthetics. *Angle Orthod* 2011; 81: 121–129.

4. Peck H and Peck S. A concept of facial esthetics. *Angle Orthod* 1970; 40: 284–318.
5. Czarnecki ST, Nanda RS and Currier GF. Perceptions of a balanced facial profile. *Am J Orthod Dentofacial Orthop* 1993; 104: 180–187.
6. Tourne LP, Bevis RL and Cavanaugh G. A validity test of cephalometric variables as a measure of clinical applicability in antero-posterior profile assessment. *Int J Adult Orthodon Orthognath Surg* 1993; 8: 95–112.
7. Tulloch C, Phillips C and Dann C 4th. Cephalometric measures as indicators of facial attractiveness. *Int J Adult Orthodon Orthognath Surg* 1993; 8: 171–179.
8. Bergman RT. Cephalometric soft tissue facial analysis. *Am J Orthod Dentofacial Orthop* 1999; 116: 373–389.
9. Moss JP, Linney AD and Lowey MN. The use of three-dimensional techniques in facial esthetics. *Semin Orthod* 1995; 1: 94–104.
10. Cox NH and van der Linden FP. Facial harmony. *Am J Orthod* 1971; 60: 175–183.
11. Oshagh M, Aleyasin ZS and Roeinpeikar M. The effects of forehead and neck positions on profile esthetics. *Eur J Esthet Dent* 2012; 7: 454–466.
12. Salehi P, Oshagh M, Aleyasin ZS, et al. The effects of forehead and neck position on esthetics of class I, II and III profiles. *Int J Esthet Dent* 2014; 9: 412–425.
13. Andrews LF. The 6-elements orthodontic philosophy: treatment goals, classification, and rules for treating. *Am J Orthod Dentofacial Orthop* 2015; 148: 883–887.
14. Andrews LF and Andrews WA. *Syllabus of the Andrews orthodontic philosophy*. 9th ed. San Diego: L.F. Andrews Foundation, 2001.
15. Andrews WA. AP relationship of the maxillary central incisors to the forehead in adult white females. *Angle Orthod* 2008; 78: 662–669.
16. Adams M, Andrews W, Tremont T, et al. Anteroposterior relationship of the maxillary central incisors to the forehead in adult white males. *Orthodontics (Chic.)* 2013; 14: e2–e9.
17. Fu MK and Mao XJ. Cephalometric analysis on 144 Chinese with normal occlusion. *J Beijing Medical School* 1965; 4: 251–256.
18. Sarver DM and Ackerman MB. Dynamic smile visualization and quantification: part 1. Evolution of the concept and dynamic records for smile capture. *Am J Orthod Dentofacial Orthop* 2003; 124: 4–12.
19. Kuhn M, Markic G, Doulis I, et al. Effect of different incisor movements on the soft tissue profile measured in reference to a rough-surfaced palatal implant. *Am J Orthod Dentofacial Orthop* 2016; 149: 349–357.
20. Hayashida H, Ioi H, Nakata S, et al. Effects of retraction of anterior teeth and initial soft tissue variables on lip changes in Japanese adults. *Eur J Orthod* 2011; 33: 419–426.
21. Gu Y, McNamara JA Jr, Sigler LM, et al. Comparison of craniofacial characteristics of typical Chinese and Caucasian young adults. *Eur J Orthod* 2011; 33: 205–211.
22. Hwang HS, Kim WS and McNamara JA Jr. Ethnic differences in the soft tissue profile of Korean and European-American adults with normal occlusions and well-balanced faces. *Angle Orthod* 2002; 72: 72–80.
23. Miyajima K, McNamara JA Jr, Kimura T, et al. Craniofacial structure of Japanese and European-American adults with normal occlusions and well-balanced faces. *Am J Orthod Dentofacial Orthop* 1996; 110: 431–438.
24. Zarif Najafi H, Oshagh M, Khalili MH, et al. Esthetic evaluation of incisor inclination in smiling profiles with respect to mandibular position. *Am J Orthod Dentofacial Orthop* 2015; 148: 387–395.
25. Ghaleb N, Bouserhal J and Bassil-Nassif N. Aesthetic evaluation of profile incisor inclination. *Eur J Orthod* 2011; 33: 228–235.