

## Original Article

# Seizure freedom from temporal lobe epilepsy with mesial temporal lobe tumor by tumor removal alone without hippocampectomy despite remaining abnormal discharges on intraoperative electrocorticography: Report of two pediatric cases and reconsideration of the surgical strategy

Takehiro Uda<sup>1,2</sup>, Noritsugu Kunihiro<sup>2</sup>, Kosuke Nakajo<sup>1</sup>, Ichiro Kuki<sup>3</sup>, Masataka Fukuoka<sup>3</sup>, Kenji Ohata<sup>1</sup><sup>1</sup>Department of Neurosurgery, Osaka City University Graduate School of Medicine, Departments of <sup>2</sup>Pediatric Neurosurgery and <sup>3</sup>Pediatric Neurology, Osaka City General Hospital, Osaka, JapanE-mail: \*Takehiro Uda - [uda\\_takehiro@hotmail.com](mailto:uda_takehiro@hotmail.com); Noritsugu Kunihiro - [nori9216@med.osaka-cu.ac.jp](mailto:nori9216@med.osaka-cu.ac.jp); Kosuke Nakajo - [kousuke19841984@yahoo.co.jp](mailto:kousuke19841984@yahoo.co.jp); Ichiro Kuki - [gpkichiro0926@yahoo.co.jp](mailto:gpkichiro0926@yahoo.co.jp); Masataka Fukuoka - [takataka\\_0730@yahoo.co.jp](mailto:takataka_0730@yahoo.co.jp); Kenji Ohata - [kohata@med.osaka-cu.ac.jp](mailto:kohata@med.osaka-cu.ac.jp)

\*Corresponding author

Received: 24 February 18 Accepted: 09 August 18 Published: 10 September 18

## Abstract

**Background:** In the surgical treatment of temporal lobe epilepsy with mesial temporal lobe tumor, whether to remove the hippocampus aiming for a better seizure outcome in addition to removing the tumor is a dilemma. Two pediatric cases treated successfully with tumor removal alone are presented.

**Case Description:** The first case was an 11-year-old girl with a ganglioglioma in the left uncus, and the second case was a 9-year-old girl with a pleomorphic xanthoastrocytoma in the left parahippocampal gyrus. In both cases, the hippocampus was not invaded, merely compressed by the tumor. Tumor removal was performed under intraoperative electrocorticography (ECoG) monitoring. After tumor removal, abnormal discharges remained at the hippocampus and adjacent temporal cortices, but further surgical interventions were not performed. The seizures disappeared completely in both cases.

**Conclusions:** When we must decide whether to remove the hippocampus, the side of the lesion, the severity and chronicity of the seizures, and the presence of invasion to the hippocampus are the factors that should be considered. Abnormal discharges on ECoG at the hippocampus or adjacent cortices are one of the factors related to epileptogenicity, but it is simply a result of interictal irritation, and it is not an absolute indication for additional surgical intervention.

**Key Words:** Electrocorticography, hippocampectomy, mesial temporal lobe tumor, surgical strategy, tumor-related epilepsy

Videos available on:  
[www.surgicalneurologyint.com](http://www.surgicalneurologyint.com)

### Access this article online

Website:  
[www.surgicalneurologyint.com](http://www.surgicalneurologyint.com)DOI:  
10.4103/sni.sni\_61\_18

### Quick Response Code:



This is an open access journal, and articles are distributed under the terms of the Creative Commons Attribution-NonCommercial-ShareAlike 4.0 License, which allows others to remix, tweak, and build upon the work non-commercially, as long as appropriate credit is given and the new creations are licensed under the identical terms.

For reprints contact: [reprints@medknow.com](mailto:reprints@medknow.com)

**How to cite this article:** Uda T, Kunihiro N, Nakajo K, Kuki I, Fukuoka M, Ohata K. Seizure freedom from temporal lobe epilepsy with mesial temporal lobe tumor by tumor removal alone without hippocampectomy despite remaining abnormal discharges on intraoperative electrocorticography: Report of two pediatric cases and reconsideration of the surgical strategy. *Surg Neurol Int* 2018;9:181.

<http://surgicalneurologyint.com/Seizure-freedom-from-temporal-lobe-epilepsy-with-mesial-temporal-lobe-tumor-by-tumor-removal-alone-without-hippocampectomy-despite-remaining-abnormal-discharges-on-intraoperative-electrocorticography-Report-of-two-pediatric-cases-and-reconsideration-of-the-surgical-strategy/>

## INTRODUCTION

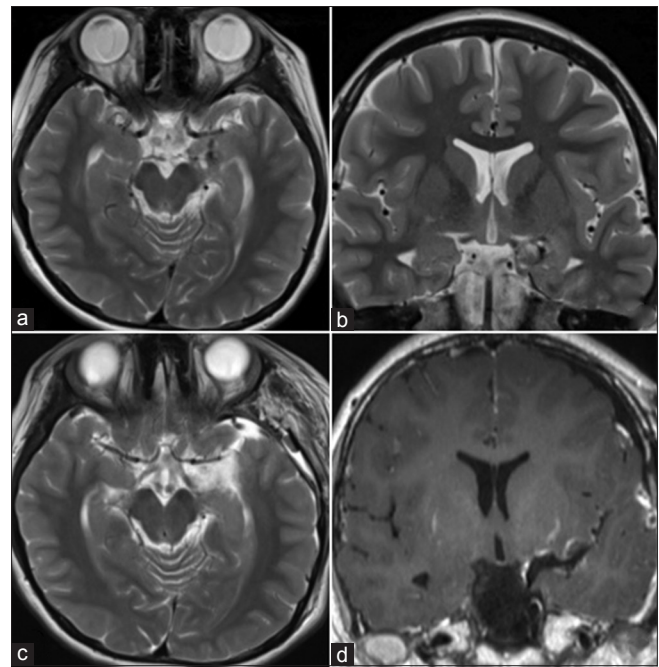
Tumors located in the mesial temporal lobe are often associated with temporal lobe epilepsy (TLE). In these cases, because the hippocampus is located close to the tumor, it may play some role in generating, amplifying, or propagating seizures. In such cases, whether the tumor invades to the hippocampus is an important factor in determining surgical strategy. When the tumor itself invades to the hippocampus, the surgical strategy is quite simple, that is, removing both the tumor and the hippocampus. On the other hand, when the hippocampus is intact or merely compressed by the tumor, there is a dilemma as to whether to remove the hippocampus aiming for a seizure-free outcome. This is because removal of a hippocampus with a normal appearance on preoperative imaging generally causes memory decline, especially on the dominant side.<sup>[6,7,21]</sup> Therefore, the hippocampus should be preserved as much as possible. However, in view of the seizure control rate, tumor removal with hippocampectomy is reported to be better than that without hippocampectomy.<sup>[3,15,27]</sup> In previous reports, additional corticectomy or hippocampectomy was considered based on intraoperative electrocorticography (ECoG).<sup>[1,9,16,18,22,26]</sup> However, when the hippocampus just amplifies or propagates seizures generated in the tumor, complete seizure-free status can be expected with tumor removal alone despite the ECoG findings.

Two pediatric cases of surgically treated TLE with mesial temporal lobe tumor are reported. In both cases, the seizures disappeared completely after surgery with removal of the tumor alone. Reviewing the literature and our cases, the appropriate surgical strategy for TLE with mesial temporal lobe tumor is discussed.

## CASE DESCRIPTION

### Case 1

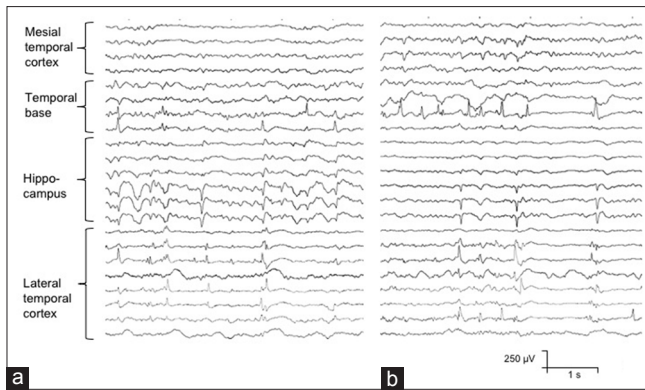
An 11-year-old girl presented with a 3-year history of complex partial seizures (CPSs). The frequency of the seizures had been less, but it was gradually increasing, and at the time surgery was considered, it was once or twice a day. Despite anticonvulsant therapy (levetiracetam, 25 mg/kg/day), the seizures were not controllable. Higher brain function had not been evaluated, but no declines of cognitive and memory functions were apparent, and she had a fully normal school-life except for the seizures. On electroencephalography (EEG), abnormal paroxysmal spikes and waves were located with maximal amplitude at the left anterior temporal area. On preoperative imaging, a heterogeneously enhanced mass with some calcification was located in the left uncus [Figure 1a and b]. The hippocampus seemed not to be invaded, merely compressed by the mass lesion.



**Figure 1: Preoperative (a and b) and postoperative (c and d) MRI in Case 1: (a and b) a mixed intensity mass lesion is located in the left uncus, but the hippocampus is intact, merely compressed by the lesion, and (c and d) the mass lesion has been completely removed with a transsylvian approach without any damage to the adjacent cortices and hippocampus**

As an initial surgical strategy, removal of the tumor alone without hippocampectomy was chosen, and if medically intractable seizures remained after tumor removal, surgical intervention to the hippocampus would be added as the second surgery.

The patient was placed in the supine position under general anesthesia. For the intraoperative ECoG, antiepileptic drugs were discontinued on the morning of surgery. Sevoflurane was maintained at 2.5% with an adequate muscle relaxant. End-tidal CO<sub>2</sub> levels were maintained at around 30 mmHg.<sup>[8,10,13]</sup> A frontotemporal craniotomy was performed using a half coronal skin incision, and the Sylvian fissure was widely opened. Through the inferior peri-insular sulcus, the inferior horn of the lateral ventricle was opened. Then, ECoG at the hippocampus, as well as at the adjacent temporal cortices, was performed using strip electrodes with six contacts at 5-mm intervals and four contacts at 1-cm intervals (Unique Medical, Tokyo, Japan). Paroxysmal typical abnormal discharges were seen on the hippocampus, as well as adjacent temporal cortices [Figure 2a]. The tumor located in the uncus was completely removed. After tumor resection, abnormal discharges on the hippocampus and adjacent temporal cortices were reduced in frequency, but remained [Figure 2b]. As planned, the hippocampus was left behind without surgical intervention [Video 1]. Postoperatively, total removal of the tumor without any



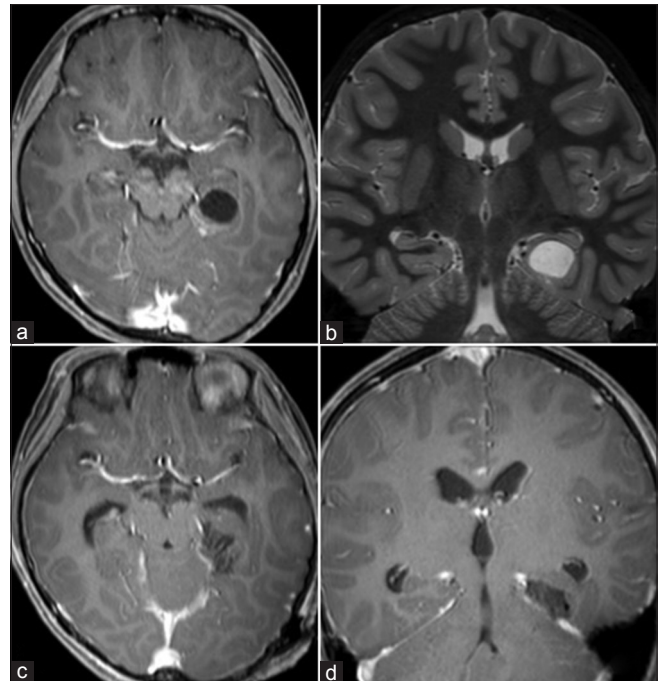
**Figure 2: Intraoperative electrocorticography before tumor removal (a) and after tumor removal (b) at the temporal cortex and hippocampus. (a) Paroxysmal abnormal discharges are confirmed at the hippocampus, as well as the temporal base and lateral temporal cortex. (b) Abnormal discharges are less frequent compared with before tumor removal, but they remain at the hippocampus, temporal base, and lateral temporal cortex**

damage to the adjacent cortices and hippocampus was confirmed on MRI [Figure 1c and d]. On pathology, the diagnosis was a ganglioglioma, and her seizures had completely disappeared (Engel classification:<sup>[2]</sup> class Ia) since the surgery for 22 months with same dosage of levetiracetam. She had no memory dysfunction and Karnofsky Performance Scale<sup>[11]</sup> was 100 postoperatively.

## Case 2

A 9-year-old girl presented with a 1-year history of CPSs. The frequency of the seizures was twice or three times a week. Sodium valproate was not effective, and levetiracetam was administered as a second-choice anticonvulsant. However, despite taking levetiracetam (35 mg/kg/day), the seizures were uncontrollable. On Wechsler Intelligence Scale for Children-IV, no declines of higher brain function or memory function were evident. On EEG, abnormal paroxysmal spikes and waves were located with maximal amplitude at the left middle temporal area. On preoperative imaging, a cystic mass with a nodular enhanced mass was located in the posterior parahippocampal gyrus on the left side [Figure 3a and b]. The hippocampus appeared not to be invaded, merely compressed by the mass lesion. In this case as well, removal of the tumor alone without hippocampectomy was chosen as the initial surgery.

The patient was placed in the right side semiprone park bench position under general anesthesia. As in the first case, sevoflurane was maintained at 2.5% for the intraoperative ECoG. An occipito-suboccipital craniotomy on the left side was made using a hockey stick skin incision. Through the supracerebellar transtentorial route, the inferior surface of the temporal lobe was exposed. ECoG was then performed at the parahippocampal and fusiform gyri using a strip electrode with four contacts at 1-cm intervals (Unique Medical), and abnormal discharges



**Figure 3: Preoperative (a and b) and postoperative (c and d) MRI in Case 2: (a and b) an enhanced small mass with cyst formation is located in the left posterior parahippocampal gyrus, but the hippocampus is intact, merely compressed by the lesion, and (c and d) the mass lesion has been completely removed with a supracerebellar transtentorial approach without any damage to the adjacent cortices and hippocampus**

were confirmed [Figure 4a]. The tumor located in the posterior parahippocampal gyrus was completely removed. After the tumor resection, abnormal discharges remained at the fusiform gyrus [Figure 4b]. However, as planned, adjacent cortex and hippocampus were left behind without surgical intervention [Video 2]. Postoperative MRI confirmed total removal of the tumor without any damage to the adjacent cortices and hippocampus [Figure 3c and d]. On pathology, the diagnosis was a pleomorphic xanthoastrocytoma, and her seizures had disappeared completely (Engel's classification:<sup>[2]</sup> class Ia) since the surgery for 23 months. The dosage of levetiracetam was reduced to 10 mg/kg/day. She had no memory dysfunction and Karnofsky Performance Scale<sup>[11]</sup> was 100 postoperatively.

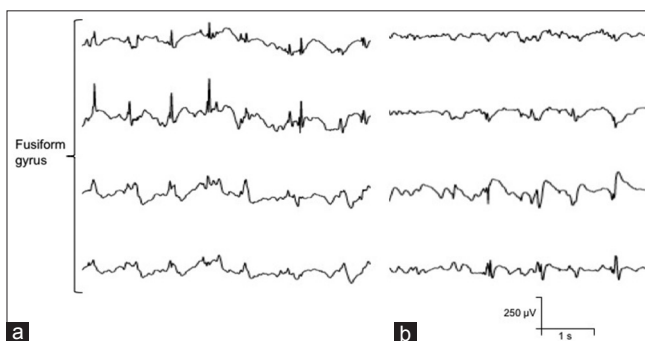
## DISCUSSION

In both of the present cases, the tumors were successfully removed by a transylvian-transventricular approach and supracerebellar transtentorial approach without hippocampectomy, and the seizures disappeared completely postoperatively. When the tumor is located far from the hippocampus, for example on the lateral temporal lobe or other part of the brain, to evaluate the seizure onset zone with chronic intracranial electrodes placement and subsequent video, ECoG

monitoring is a useful step to make a decision whether to remove the hippocampus or not. However, in the case of mesial temporal lobe tumor, precise placements of intracranial electrodes on or in the hippocampus and the tumor are much more difficult. Therefore, one-stage surgery is thought to be preferred in the case of TLE with mesial temporal lobe tumor. As described, whether to add a surgical intervention to the adjacent area with an abnormal ECoG after tumor removal has not been established.<sup>[1,9,16,18,22,26]</sup> Factors that should be considered in making this decision are (1) the side of the lesion; (2) the duration, severity, and chronicity of the seizures; and (3) the presence of invasion to the hippocampus. In addition, intraoperative ECoG findings at the hippocampus or adjacent cortices are also important.<sup>[14,20]</sup> This is because, when the lesion is located on the nondominant side, removal of the hippocampus does not lead to severe memory dysfunction, and when the seizures are not intractable, the remaining hippocampus itself may not cause seizures.

In both of the present cases, the lesions were located on the dominant side. Surgery had been performed less than 3 years since seizure onset, and the number of anticonvulsants taken before surgery was less than two. The tumors did not invade to the hippocampus, they merely compressed it. Intraoperative ECoG findings may be valuable to identify the extent of the irritative area to be removed,<sup>[1,3,4,14-16,18,20,22]</sup> but they are just part of an interictal recording over a short time (usually 10 min at most). Several studies demonstrated that satisfactory seizure control was achieved by removal of the tumor alone without intraoperative ECoG monitoring.<sup>[1,5,12]</sup> Also, in our previous report, remaining abnormal discharges on ECoG at the temporal neocortex after selective amygdalohippampectomy had no relationship to postoperative remaining seizures.<sup>[25]</sup>

Therefore, the decision was made to remove the tumor alone without hippocampectomy despite remaining



**Figure 4:** Intraoperative electrocorticography before tumor removal (a) and after tumor removal (b) at the temporal cortex. (a) Paroxysmal abnormal discharges are confirmed at the fusiform gyrus. (b) Abnormal discharges are less frequent compared with before tumor removal, but they remain

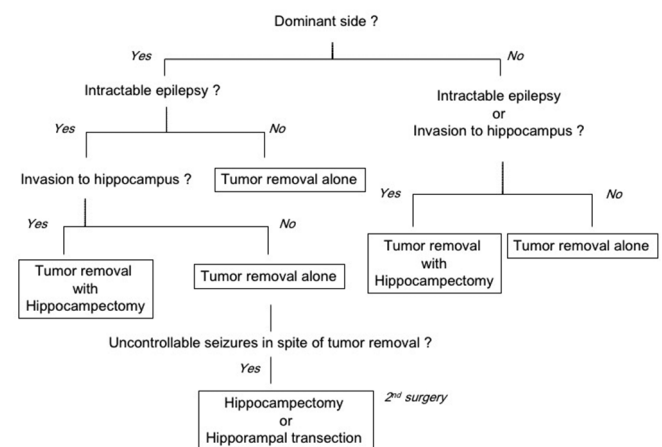
abnormal discharges on ECoG at the hippocampus and adjacent cortices after tumor removal.

One solution for better seizure outcomes is adding hippocampal transection, which was first reported in 2006.<sup>[19]</sup> Hippocampal transection is a procedure originally developed for MRI-negative mesial TLE to preserve memory function.<sup>[17,24]</sup> In hippocampal transection, the hippocampus is not removed, just transected. The theory is that the epileptogenic circuit is disrupted by parallel transection of the hippocampus and that the memory circuit from the hippocampus to the fornix via the fimbria is preserved. Recently, it has also been used for TLE with a temporal lobe tumor in some institutions.<sup>[23]</sup> However, hippocampal transection is also somewhat invasive for the hippocampus and should be avoided if possible.

Finally, we propose a flowchart of the surgical strategy for TLE with mesial temporal lobe tumor, focusing on whether to remove the tumor alone or with hippocampectomy, taking into account the side of the tumor, intractability of seizures, and the presence of tumor invasion to the hippocampus [Figure 5]. According to this flowchart, we consider preserving the hippocampus as much as possible, especially on the dominant side, and if intractable seizures remain after initial surgery, we consider removal or transection of the hippocampus thereafter. Surgeons should select the appropriate approach for tumor removal with or without hippocampectomy. It is still unknown that what percentage of the cases surgeons can preserve hippocampus when the abnormal discharges still remain after tumor removal in intraoperative ECoG. To evaluate the percentage and verify the efficacy of our flowchart, randomized controlled study is mandatory to be performed.

## CONCLUSIONS

For TLE with mesial temporal lobe tumor on the dominant side without invasion to the hippocampus,



**Figure 5:** Flow chart used to determine whether to remove the hippocampus in the surgical strategy for temporal lobe epilepsy with a mesial temporal lobe tumor

removal of tumor alone without hippocampectomy can be an appropriate initial surgical strategy. Abnormal discharges on intraoperative ECoG at the adjacent cortex or hippocampus are one of the factors related to epileptogenicity, but they are simply a result of interictal irritation. Therefore, one might conclude that their presence is not an absolute indication for adding corticectomy or hippocampectomy.

### Acknowledgment

We thank Drs. Hisashi Kawawaki, Shin Okazaki, Takeshi Inoue, Megumi Nukui, Kiyohiro Kim, Yasuhiro Matsusaka, Syugo Nishijima, and Saya Koh for their help with this study.

### Declaration of patient consent

The authors certify that they have obtained all appropriate patient consent forms. In the form the patient(s) has/have given his/her/their consent for his/her/their images and other clinical information to be reported in the journal. The patients understand that their names and initials will not be published and due efforts will be made to conceal their identity, but anonymity cannot be guaranteed.

### Financial support and sponsorship

Nil.

### Conflicts of interest

There are no conflicts of interest.

## REFERENCES

- Cataltepe O, Turanli G, Yalnozlu D, Topçu M, Akalan N. Surgical management of temporal lobe tumor-related epilepsy in children. *J Neurosurg* 2005;102:280-7.
- Engel J. *Surgical Treatment of the Epilepsies*. New York: Raven Press; 1993.
- Englot DJ, Berger MS, Barbaro NM, Chang EF. Factors associated with seizure freedom in the surgical resection of glioneuronal tumors. *Epilepsia* 2012;53:51-7.
- Gelinas JN, Battison AW, Smith S, Connolly MB, Steinbok P. Electroconvulsive therapy and seizure outcomes in children with lesional epilepsy. *Childs Nerv Syst* 2011;27:381-90.
- Giulioni M, Galassi E, Zucchelli M, Volpi L. Seizure outcome of lesionectomy in glioneuronal tumors associated with epilepsy in children. *J Neurosurg* 2005;102:288-93.
- Gleissner U, Helmstaedter C, Schramm J, Elger CE. Memory outcome after selective amygdalohippocampectomy: A study in 140 patients with temporal lobe epilepsy. *Epilepsia* 2002;43:87-95.
- Helmstaedter C, Petzold I, Bien CG. The cognitive consequence of resecting nonlesional tissues in epilepsy surgery – Results from MRI- and histopathology-negative patients with temporal lobe epilepsy. *Epilepsia* 2011;52:1402-8.
- Herrick IA, Gelb AW. Anesthesia for temporal lobe epilepsy surgery. *Can J Neurol Sci* 2000;27 Suppl 1:S64-7.
- Hu WH, Ge M, Zhang K, Meng FG, Zhang JG. Seizure outcome with surgical management of epileptogenic ganglioglioma: A study of 55 patients. *Acta Neurochir (Wien)* 2012;154:855-61.
- Jääskeläinen SK, Kaisti K, Suni L, Hinkka S, Scheinin H. Sevoflurane is epileptogenic in healthy subjects at surgical levels of anesthesia. *Neurology* 2003;61:1073-8.
- Karnofsky DA, Burchenal JH. The Clinical Evaluation of Chemotherapeutic Agents in Cancer. In: C. M. MacLeod, Ed., *Evaluation of Chemotherapeutic Agents*, Columbia University Press, New York; 1949. p. 191-205.
- Kim SK, Wang KC, Hwang YS, Kim KJ, Cho BK. Intractable epilepsy associated with brain tumors in children: Surgical modality and outcome. *Childs Nerv Syst* 2001;17:445-52.
- Kurita N, Kawaguchi M, Hoshida T, Nakase H, Sakaki T, Furuya H, et al. The effects of sevoflurane and hyperventilation on electrocorticogram spike activity in patients with refractory epilepsy. *Anesth Analg* 2005;101:517-23.
- McKhann GM 2<sup>nd</sup>, Schoenfeld-McNeill J, Born DE, Haglund MM, Ojemann GA. Intraoperative hippocampal electrocorticography to predict the extent of hippocampal resection in temporal lobe epilepsy surgery. *J Neurosurg* 2000;93:44-52.
- Morioka T, Hashiguchi K, Nagata S, Miyagi Y, Yoshida F, Shono T, et al. Additional hippocampectomy in the surgical management of intractable temporal lobe epilepsy associated with glioneuronal tumor. *Neurol Res* 2007;29:807-15.
- Ogiwara H, Nordli DR, DiPatri AJ, Alden TD, Bowman RM, Tomita T, et al. Pediatric epileptogenic gangliogliomas: Seizure outcome and surgical results. *J Neurosurg Pediatr* 2010;5:271-6.
- Patil AA, Andrews RV. Nonresective hippocampal surgery for epilepsy. *World Neurosurg* 2010;74:645-9.
- Pilcher WH, Silbergeld DL, Berger MS, Ojemann GA. Intraoperative electrocorticography during tumor resection: Impact on seizure outcome in patients with gangliogliomas. *J Neurosurg* 1993;78:891-902.
- Shimizu H, Kawai K, Sunaga S, Sugano H, Yamada T. Hippocampal transection for treatment of left temporal lobe epilepsy with preservation of verbal memory. *J Clin Neurosci* 2006;13:322-8.
- Southwell DG, Garcia PA, Berger MS, Barbaro NM, Chang EF. Long-term seizure control outcomes after resection of gangliogliomas. *Neurosurgery* 2012;70:1406-13.
- Stroup E, Langfitt J, Berg M, McDermott M, Pilcher W, Como P, et al. Predicting verbal memory decline following anterior temporal lobectomy (ATL). *Neurology* 2003;60:1266-73.
- Sugano H, Shimizu H, Sunaga S. Efficacy of intraoperative electrocorticography for assessing seizure outcomes in intractable epilepsy patients with temporal-lobe-mass lesions. *Seizure* 2007;16:120-7.
- Sugano H, Shimizu H, Sunaga S, Arai N, Tamagawa K. Temporal lobe epilepsy caused by dermoid cyst. *Neurol Med Chir (Tokyo)* 2006;46:206-9.
- Uda T, Morino M, Ito H, Minami N, Hosono A, Nagai T, et al. Transylvian hippocampal transection for mesial temporal lobe epilepsy: Surgical indications, procedure, and postoperative seizure and memory outcomes. *J Neurosurg* 2013;119:1098-104.
- Uda T, Morino M, Minami N, Matsumoto T, Uchida T, Kamei T, et al. Abnormal discharges from the temporal neocortex after selective amygdalohippocampectomy and seizure outcomes. *J Clin Neurosci* 2015;22:1797-801.
- Wallace D, Ruban D, Kanner A, Smith M, Pitelka L, Stein J, et al. Temporal lobe gangliogliomas associated with chronic epilepsy: Long-term surgical outcomes. *Clin Neurol Neurosurg* 2013;115:472-6.
- Wallace DJ, Byrne RW, Ruban D, Cochran EJ, Roh D, Whisler WW, et al. Temporal lobe pleomorphic xanthoastrocytoma and chronic epilepsy: Long-term surgical outcomes. *Clin Neurol Neurosurg* 2011;113:918-22.