

Nanoscopic Distal Clavicle Resection

Luis Filipe Senna, M.D., M.Sc., and Chad Lavender, M.D.



Abstract: Acromioclavicular joint pathology such as osteoarthritis has historically been treated with either an open or arthroscopic distal clavicle resection. Over the years the trend has been toward more minimally invasive treatment options with the arthroscope. In this article we highlight the use of the nanoscope to visualize the resection which can be performed through a small percutaneous incision. The advantages of this technique include the use of smaller portals, which should lead to improved earlier outcomes, and less iatrogenic damage to the shoulder.

Symptomatic acromioclavicular (AC) joint pathology can be caused by osteoarthritis or distal clavicle osteolysis. Patients commonly present with pain and difficulty with overhead and cross-arm adduction activities. Individuals with persistent symptoms after failed nonoperative treatment can be successfully treated with distal clavicle excision. Both open and arthroscopic approaches have been described, but the latter has been used more frequently over the last 15 years. The arthroscopic approach offers a less-invasive intervention, improved cosmesis, easier post-operative rehabilitation, and a faster return to function. The most commonly used arthroscopic technique uses an indirect approach to the AC joint through the sub-acromial space. To access the joint, the inferior portion of the AC ligament and a relevant portion of the posterior and anterior components need to be resected. A direct approach, with a standard small-size arthroscope inserted directly into the AC joint, has also been described,^{1,2} but despite offering the advantage of

preserving the AC ligament attachments, the direct approach has not gained popularity.

The introduction of needle arthroscopy has allowed easier access to tighter spaces and a percutaneous approach for arthroscopic surgery.^{3,4} We believe using a smaller diameter arthroscope can facilitate the surgery and make it more reproducible, while not causing significant damage to the AC joint capsule and ligaments. We present a modification of the direct approach for distal clavicle excision using the 1.9 mm NanoScope needle arthroscopy system (Arthrex Inc., Naples, FL) that includes a chip-on-tip single- Nanoscope use camera.

Surgical technique

Patient positioning

For this procedure, it's the author's preference to have the patient positioned the beach-chair position.

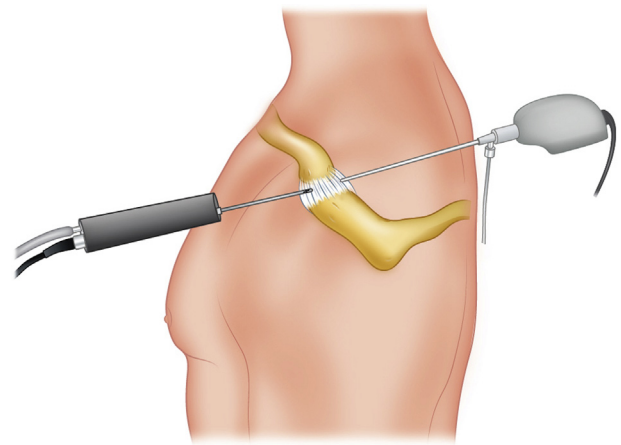


Fig 1. Illustration of the technique in a left shoulder from a lateral view. The shaver can be seen coming in anteriorly, and the Nanoscope is viewed from posteriorly.

From Tribe Medical Group (L.F.S.), Mississauga, Ontario, Canada; and Marshall University (C.L.), Scott Depot, West Virginia, U.S.A.

The authors report the following potential conflict of interest or source of funding: L.F.S. reports other from Tribe Medical Group. C.L. reports other from Arthrex Full ICMJE author disclosure forms are available for this article online, as [supplementary material](#).

Received October 14, 2021; accepted December 4, 2021.

Address correspondence to Chad Lavender, M.D., Orthopedic Surgery, Marshall University, 300 Corporate Center Dr, Scott Depot, WV 25560, U.S.A. E-mail: doclav@gmail.com

© 2022 THE AUTHORS. Published by Elsevier Inc. on behalf of the Arthroscopy Association of North America. This is an open access article under the CC BY-NC-ND license (<http://creativecommons.org/licenses/by-nc-nd/4.0/>).

2212-6287/211478

<https://doi.org/10.1016/j.eats.2021.12.006>

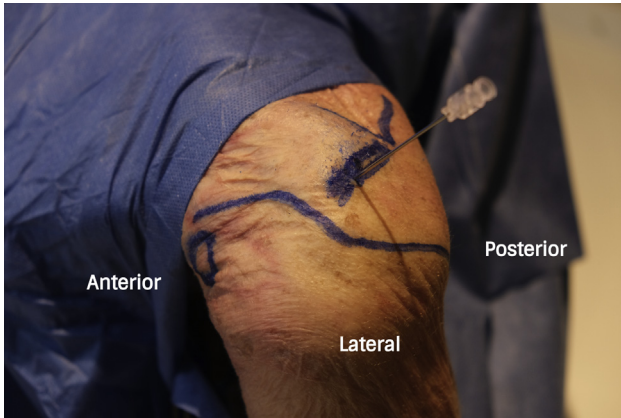


Fig 2. Left shoulder view from outside of the joint. Skin marks over the clavicle, acromion, and scapular spine. A spinal needle has been placed into the acromioclavicular joint from above.

Bony prominences of the scapula and the head are well padded, and the cervical spine should be maintained well aligned. The upper extremity is prepped and draped in the usual sterile fashion. An arm holder is usually unnecessary because the upper extremity can rest on the patient's ipsilateral hip (Video 1).

Portals

The bone contours of the acromioclavicular joint, clavicle, coracoid process, and spine of the scapula are marked using a skin pen. The technique uses two portals, named posterior-superior and anterior-superior (Fig 1). Before making the portals, we use a spinal needle to localize the acromioclavicular joint (Fig 2). The posterior-superior portal is created at the junction of the superior and posterior aspect of the AC joint in a 30° angle in the sagittal plane. To create this portal, a 2.2 mm NanoScope sheath can be percutaneously inserted using a sharp trocar (Fig 3). Inflow is then

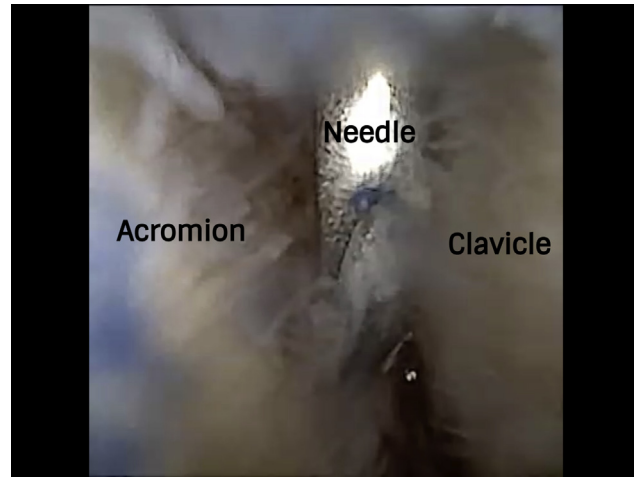


Fig 4. Viewing the left shoulder from posterior using the 0° NanoScope the spinal needle can be seen in the center of the acromioclavicular joint.

placed onto the cannula, the trocar is removed, and the 1.9-mm NanoScope is inserted for visualization. The anterior-superior portal is created just anterior to the AC joint with an outside-in technique. A spinal needle is inserted and visualized by the NanoScope (Fig 4). A nitinol wire is inserted into the needle, and the needle is removed. A small 2.7-mm cannula now be introduced over the wire, and the wire is removed (Fig 5).

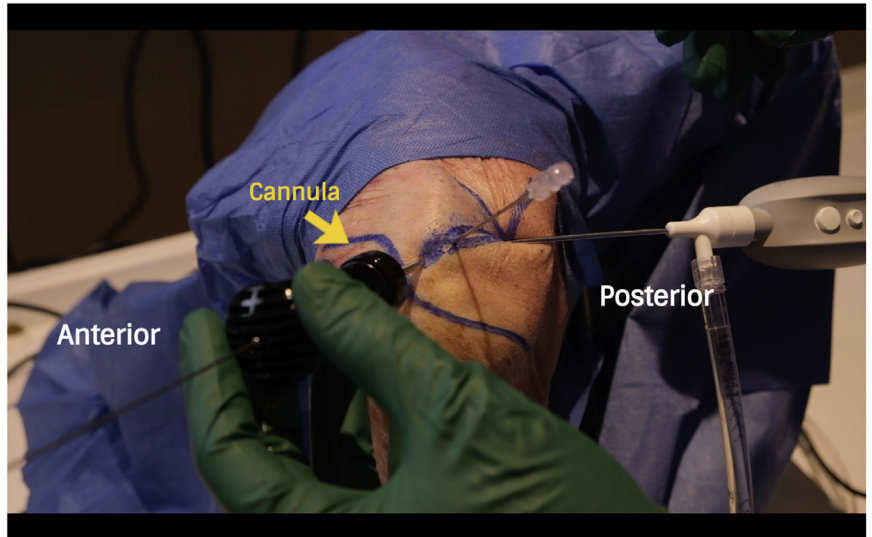
Distal clavicle excision

A 2-mm soft tissue shaver is inserted through the cannula in the anterior portal and used for excising the articular disc and any soft tissue that is obscuring visualization (Fig 6). Alternatively, the new Nano Sabre (Arthrex Inc.) can be used for more aggressive resection. After the soft tissue shaver is used, a high-speed 3.0-mm burr is inserted percutaneously for removing

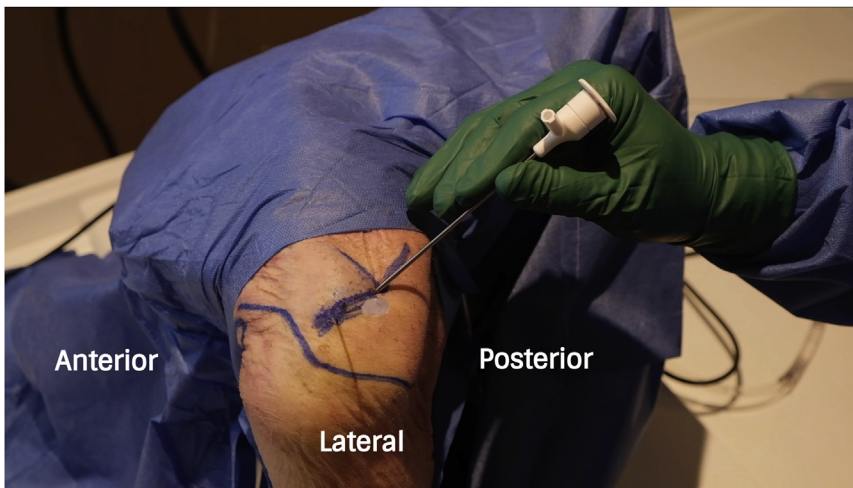

Fig 3. Left shoulder view from outside of the joint. Sharp trocar and sheath introduced percutaneously to create a posterior-superior portal.

Fig 5. View of the left shoulder from outside of the joint after Introduction of a 2.7 mm cannula percutaneously.



8 mm of the lateral end of the clavicle (Fig 7). The known diameter of the shaver blades can be used as a reference to estimate the amount of bone removed.

Discussion

In 1941 Mumford⁵ and Gurd⁶ first described, independently, open distal clavicle excision for pathologies at the AC joint. More recently, the arthroscopic approach from the subacromial space gained popularity because it showed better cosmesis, less stiffness, and lower infection rates when compared to the traditional open approach.^{7,8} However, resection of the inferior band of the AC ligament and a significant portion of the anterior and posterior bands must be performed to gain access to the joint. Violating the AC ligaments can lead to AC joint horizontal instability, and it has been

described as a complication of the arthroscopic indirect approach.^{9,10} A direct superior approach to the AC joint was described by Johnson and modified by Flatow.^{1,2} The direct approach seems logic for isolated AC joint pathology, when there's no need for violating the subacromial bursal space or the glenohumeral joint. Using a 4.0-mm arthroscope and a 4.8-mm burr, Hardeman et al.¹¹ compared the stability and force of ultimate failure of the AC joint after direct arthroscopic distal clavicle excision through superior portals and indirect arthroscopic through inferior portals in cadaveric shoulders. Their results showed greater ultimate failure strength for the direct approach group. This was attributed to the fact that the inferior joint capsule was preserved. Charron et al.⁷ compared the clinical results using a direct superior versus indirect approach for

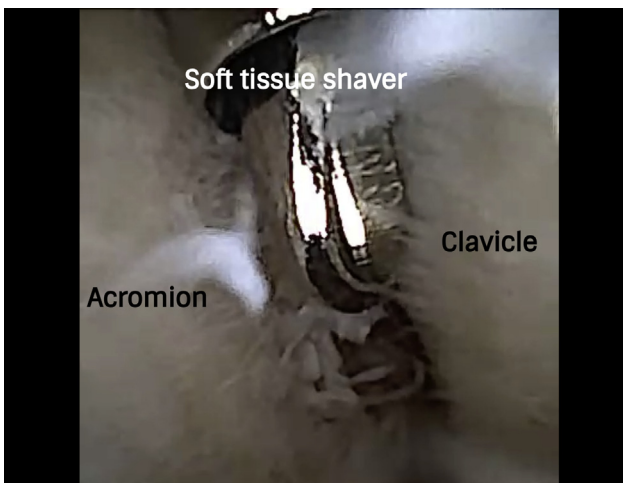


Fig 6. Viewing the left shoulder from posterior using the 0° Nanoscope the 2 mm shaver has been introduced through the cannula.

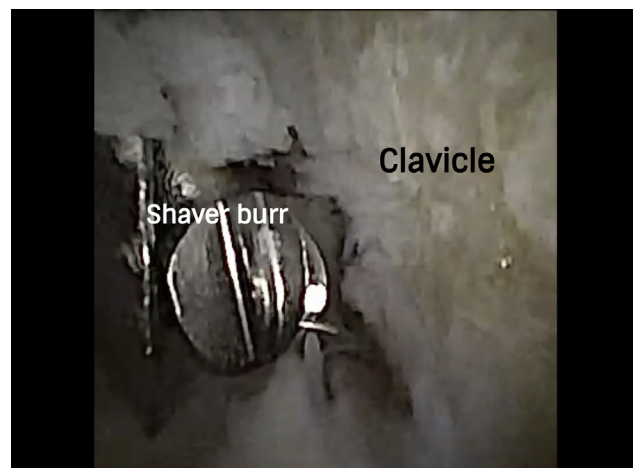

Fig 7. Viewing the left shoulder from posterior using the 0° Nanoscope a high speed burr introduced percutaneously to resect 8 mm of the distal end of the clavicle.

Table 1. Technique's Pearls and Pitfalls

Use shaver's suction intermittently to prevent emptying of the joint
 If increased flow is needed, a 3.4 mm NanoScope sheath can be used
 Use shaver burr in moderate speed (600-800 rpm) to avoid excessive turbulence

distal clavicle excision in athletes and found patients from the direct superior approach improved faster clinically and had a faster return to sports. For the direct approach, they used a 4.0 mm burr and a 2.7 mm small-joints arthroscope that was often switched to a 4.0 mm to improve visualization. Recently several minimally invasive techniques have been developed using the Nanoscope. Lavender et al.^{12,13} described their technique for partial meniscectomy using a 1.9 mm single use arthroscopy system, the NanoScope (Arthrex Inc.), and a 2.7-mm Nano Arthroscopy Canula (Arthrex Inc.) where no formal incisions are made. Nanoscopic techniques have also been described to perform a labrum repair and meniscus repair.^{12,13} In our study we used the same principles and instruments to gain direct access to the AC joint.³ Pearls and pitfalls associated with the technique are described in Table 1. It may be helpful to use the 3.4 mm portal for increased flow, and also it is important to use intermittent suction. Advantages and disadvantages of using this technique are outlined in Table 2. Advantages include decreased morbidity including less risk to the AC joint ligaments. We believe using this technology permits minimal injury to the AC joint capsule and ligaments with the potential benefit of causing less risk for post-operative AC joint instability. There is also no unnecessary violation of the subacromial space and glenohumeral joint. This approach is more technically demanding when compared to the arthroscopic indirect subacromial approach to the AC. Other disadvantages to consider are the additional cost of the NanoScope and need of special small size instruments.

There are limitations to the nanoscopic approach. Working in a tighter space with a more fragile arthroscope

Table 2. Advantages and Disadvantages of Direct Approach Using NanoScope

Advantages
Less morbidity (no need to disturb subacromial space)
Decreased risk for AC instability (no need to resect AC ligaments)
Decreased loss and need for fluid
Disadvantages
Additional cost of NanoScope
More technically demanding
Need of special small size instruments

AC, acromioclavicular.

may increase the chances of damaging the lenses when working close to shaver blades. The Nano sheaths provide sufficient flow when used with a 4.0-mm burr or smaller, but using a larger burr can empty the joint relatively quickly. In summary, needle arthroscopy can be used for a direct approach on distal clavicle excision without the need to violate the acromioclavicular ligaments, the subacromial space, or the glenohumeral joint.

References

1. Johnson LL. *Diagnostic and surgical arthroscopy*. St. Louis: CV Mosby, 1981.
2. Flatow EL, Cordasco FA, LU Bigliani. Arthroscopic resection of the outer end of the clavicle from a superior approach: A critical, quantitative, radiographic assessment of bone removal. *Arthroscopy* 1992;8:55-64.
3. Lavender C, Lycans D, Adil SA, Kopiec A, Schmicker T. Incisionless partial medial meniscectomy. *Arthrosc Tech* 2020;9:e375-e378.
4. Peters M, Gilmer B, Kassam HF. Diagnostic and therapeutic elbow arthroscopy using small-bore needle arthroscopy. *Arthrosc Tech* 2020;9, e1708.
5. Mumford EB. Acromioclavicular dislocation: A new operative treatment. *J Bone Joint Surg [Am]* 1941;23-A: 799-802.
6. Gurd FB. The treatment of complete dislocation of the outer end of the clavicle. *Ann Surg* 1941:1094-1098.
7. Charron KM, Schepesis AA, Voloshin Ilya. Arthroscopic distal clavicle resection in athletes: A prospective comparison of the direct and indirect approach. *Am J Sports Med* 2007:53-58.
8. Pensak M, Grumet RC, Slabaugh M, Bach BR Jr. Open versus arthroscopic distal clavicle resection. *Arthroscopy* 2010:679-704.
9. Strauss EJ, Barker JU, McGill K, Verma NN. The evaluation and management of failed distal clavicle excision. *Sports Med Arthrosc Rev* 2010:213-219.
10. Blazar PE, Iannotti JP, Williams GR. Anteroposterior instability of the distal clavicle after distal clavicle resection. *Clin Orthop* 1998:114-120.
11. Hardeman F, Van Rooyen K, Somers J, Doll S, Page R, De Beer J. Biomechanical comparison of indirect and direct arthroscopic excision of the distal clavicle. *Acta Orthop Belg* 2013:36-41.
12. Lavender C, Flores K, Patel T, Berdis G, Blickenstaff B. Nanoscopic medial meniscus repair. *Arthrosc Tech* 2021;10: e1943-e1947.
13. Lavender C, Lycans D, Kopiec A, Sayan A. Nanoscopic single-incision labrum repair. *Arthrosc Tech* 2020;9:e297-e301.