

## Case Report

# A simple method for reconstruction of severely damaged primary anterior teeth

Alireza Eshghi<sup>1</sup>, Raha Kowsari Esfahan<sup>1</sup>, Maryam Khoroushi<sup>2</sup>

<sup>1</sup>Department of Pediatric Dentistry and Torabinejad Dental Research Center, <sup>2</sup>Department of Operative Dentistry and Torabinejad Dental Research Center, Faculty of Dentistry, Isfahan University of Medical Sciences, Isfahan, Iran

Received: November 2010  
Accepted: June 2011

Address for correspondence:  
Dr. Maryam Khoroushi,  
Faculty of Dentistry,  
Isfahan University of Medical  
Sciences, Hezar Jerib St.,  
Isfahan, Iran, Post code:  
81746-73461.  
E-mail: khoroushi@dnt.  
mui.ac.ir

## ABSTRACT

Restoration of severely decayed primary anterior teeth is often considered as a special challenge by pedodontists. This case report presents a 5-year-old boy with severely damaged maxillary right canine. Subsequent to root canal treatment, a reversed (upside-down) metal post was put into the canal and composite build-up was performed. This new method offers a simple, practical and effective procedure for reconstruction of severely decayed primary anterior teeth, which re-establishes function and esthetics for time the tooth should be present and functional in the child's mouth.

**Key Words:** Composite resin, pediatric dentistry, post, primary tooth, restoration

## INTRODUCTION

Dental caries is the most common chronic disease of childhood.<sup>[1]</sup> Early childhood caries (ECC) involves the upper anterior teeth early in life and by the time dentist visits the child, most of the coronal structure would have been lost.<sup>[2]</sup> Until recently, the extraction of the affected primary anterior teeth was the common treatment option for ECC, which results in unattractive appearance and could interfere with the personality and behavioral development of the child. Moreover, the early loss of primary anterior teeth results in reduced masticatory efficiency, loss of vertical dimension, development of parafunctional habits including tongue thrusting, speech problems, malocclusion and space loss.<sup>[3-5]</sup>

An easy-to-perform restorative technique that is able to provide efficient, durable and functional restorations

would enhance the management of patients presenting with decayed maxillary primary anterior teeth.<sup>[5]</sup>

In cases where teeth are severely decayed, endodontic treatment and placement of some retentive features is necessary before crown reconstruction.<sup>[6-10]</sup> Restorative treatment options mentioned in the literature include direct and indirect techniques using prefabricated crowns, as well as biologic and resin composite restorations, sometimes using fiber or metal posts.<sup>[6-12]</sup> Moreover, some authors suggest using anterior stainless steel crowns with or without labial facing for full crown coverage of incisors that have lost an appreciable amount of their tooth structure,<sup>[13,14]</sup> whereas some describe the resin post and core provided with orthodontic wire.<sup>[7,12,15]</sup>

One of the most important considerations in reconstruction of primary teeth is the physiologic root resorption. Therefore, in most cases, the dentist should consider almost 3 mm of the existing root for obtaining enough retention and resistance of the severely damaged tooth restoration. The present report introduces a simple technique named "reverse metal post- insertion technique" (RMPT) using prefabricated metal post and composite resin restoration for effective reconstruction of a severely decayed primary anterior canine.

### Access this article online

Quick Response Code:



Website: [www.drj.ir](http://www.drj.ir)

DOI: 10.4103/1735-3327.86046

## CASE REPORT

A 5-year-old boy with ECC was referred to the Department of Pediatric Dentistry, School of Dentistry, in Isfahan University of Medical Sciences. The child was medically fit and well. Clinical and radiographic examinations were conducted to establish a treatment plan.

On explaining the restoration technique for the subject and his parents, they accepted the suggested treatment and signed an informed consent form before the treatment began. Following treatment of all posterior decayed teeth, the maxillary canines were considered to be restored with composite resin restoration [Figure 1]. Due to the extensive damage that had occurred in the maxillary right canine structure, this tooth was considered for treatment with the novel technique described as follows.

The patient was anesthetized, rubber dam isolation was performed, caries removal was done and pulp tissue was extirpated [Figures 2–4]. The canal was prepared using a sequence of three consecutive endodontic files #30-45 (Mailleferre, Kerr, Orange, CA, USA) under constant irrigation with physiologic saline, dried with paper points, and obturated with zinc oxide eugenol paste (ZOE BP, BDH Ltd., Germany). Three millimeters of the coronal part of the canal was prepared for future replacement of post. This part of the canal was then prepared to be almost rectangular with semi-rounded line angles in order to match with the quadrangle core of a prefabricated metal post (Dentatus, Switzerland) that was planned to be placed reversely into the prepared canal. Generally, the core length of prefabricated metal posts is 3 mm and suitable for this purpose.

The No. 1 short post was chosen because the length of the post (5 mm) was long enough to build up the coronal length of the destroyed canine and the bulk of composite resin around it was enough to ensure that it did not show the metal shadow and also there was less possibility for interference with the occlusion. The sharp four line angles of quadrangle core of the post were then semi-beveled to not exert stress to the root and the post was examined in the prepared canal [Figures 5 and 6].

Subsequent to occlusion evaluation, 1 mm end of the post which interfered with the occlusion was cut [Figure 7]. The post was then cemented into the canal using zinc phosphate cement (Harvard, Richer and Hoff-man, Berlin, Germany). After initial setting of the cement, etching with 37% phosphoric acid

and rinsing, the screws of the post were covered with one layer of flowable composite resin (Aelite flow, Kuraray Co., Osaka, Japan) and the coronal restoration was reconstructed incrementally using A2 shade composite resin (APX, Kuraray Co., Osaka, Japan) [Figures 8 and 9].

Finally, the occlusion was adjusted using articulating paper; finishing and polishing was carried out using fine diamond burs (Teezkavan, Tehran, Iran) and Soft Lex Pop On Disks (3M ESPE, St. Paul, MN, USA) [Figure 10].

The patient and his parents were instructed on proper dietary and hygiene habits and advised to come for regular check-up. In intervals of 6, 12, and 18 months, the subject was examined for regular evaluations of his orodental situation and the restored canine [Figures 11 and 12].

## DISCUSSION

Restoring primary anterior teeth with severe loss of coronal structure is challenging for the pedodontists. The principle goal of pediatric restorative dentistry is to restore the damaged teeth to enable them perform normal function and also from an esthetic point of view. Several reasons such as absence of tooth structure, poor adhesion of bonding agent to primary teeth, limited availability of techniques and materials, and youngest and least manageable children for whom these restorations are needed make these treatments difficult, with high rate of failure.<sup>[16]</sup> To get retention and provide stability for such reconstructed crowns, use of intracanal retainers after endodontic treatment is necessary.

The use of conventional prefabricated metal posts is a fast, low-cost and simple technique,<sup>[17]</sup> but is not accepted in pediatric dentistry because of the potential interference with physiologic root resorption.

The nickel–chromium cast posts, which have been utilized,<sup>[14]</sup> are not only expensive and require an additional laboratory stage, but also could pose problems during the natural tooth exfoliation.<sup>[5]</sup>

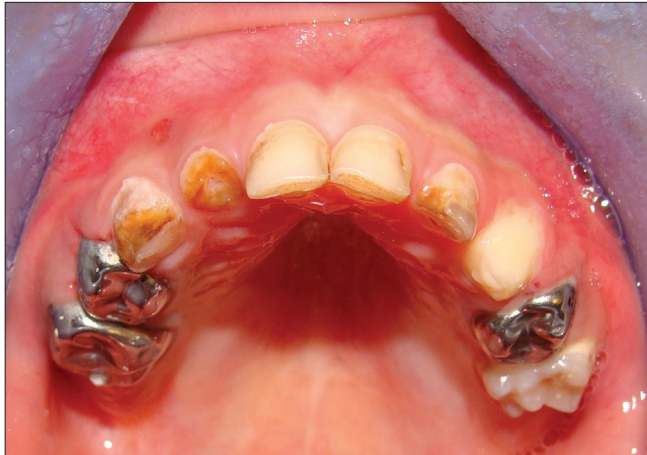Natural elements<sup>[7]</sup> may be used for more esthetic reasons, but some disadvantages like the need of tooth bank, donor and recipient acceptance and cross infection make this treatment option impractical.

The use of stainless steel orthodontic wire<sup>[7,12,15,16,18,19]</sup> as an intracanal post has also been a simple and fast technique for reconstruction of primary anterior

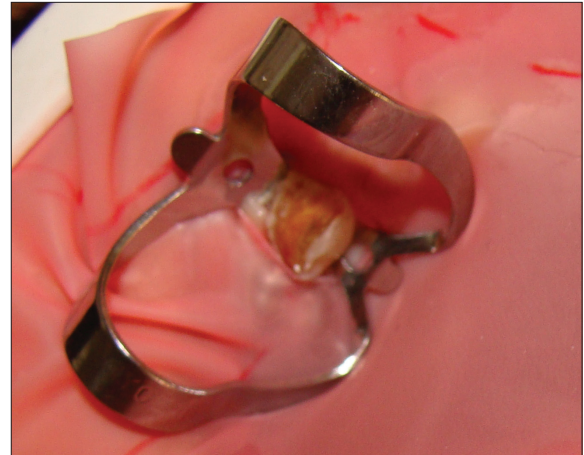
teeth. However, in most cases, the wire adaptation to the internal walls of the canal is not adequate, leading to detachment of the wire and restoration or radicular fracture, especially in cases with excessive masticatory forces.<sup>[3]</sup>

Composite resin posts provide satisfactory esthetics,<sup>[8,15,20,21]</sup> but loss of retention owing to polymerization contraction could be a risk.

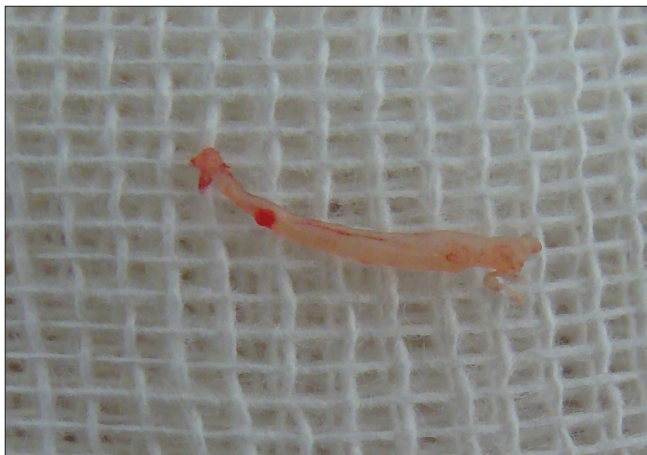According to the previous studies, the use of prefabricated nonmetallic posts such as ceramic posts,



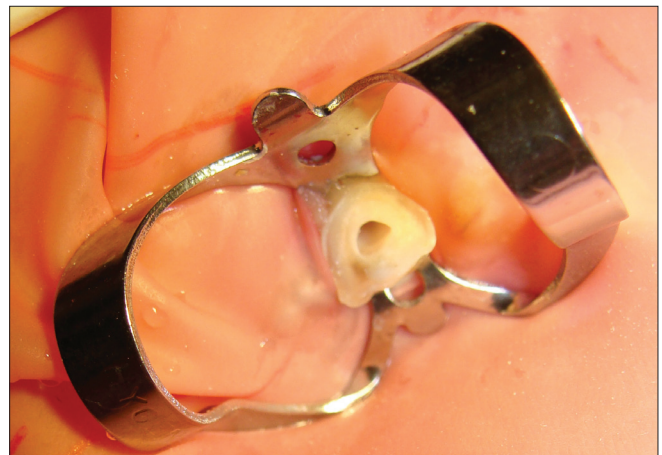**Figure 1:** Initial view of the maxillary teeth



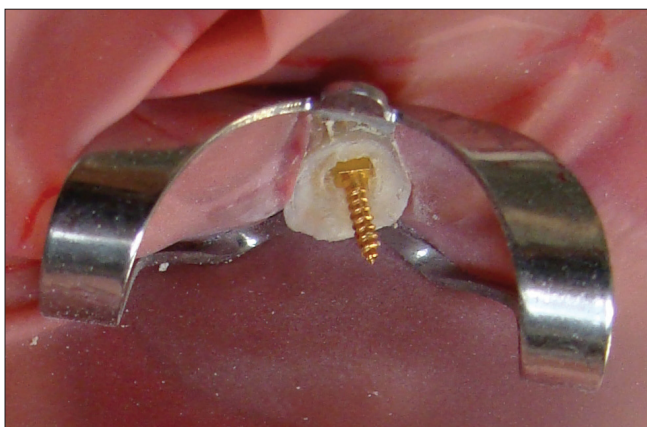**Figure 2:** Isolation of maxillary right canine with rubber dam



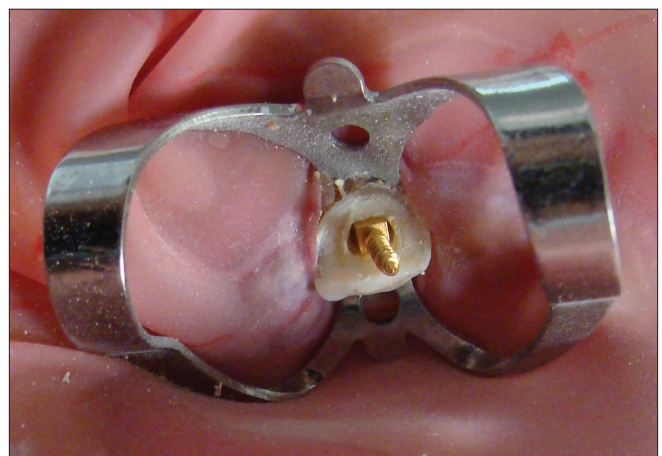**Figure 3:** Extirpated pulp



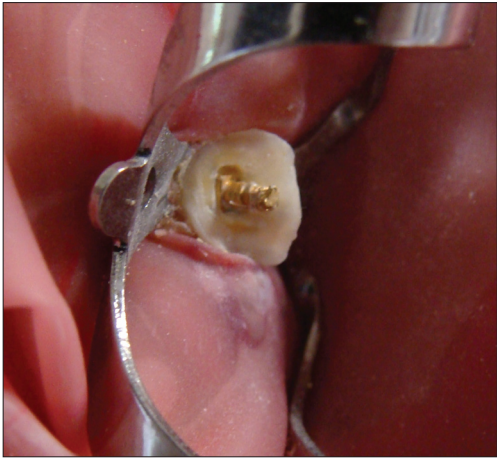
**Figure 4:** Prepared canal



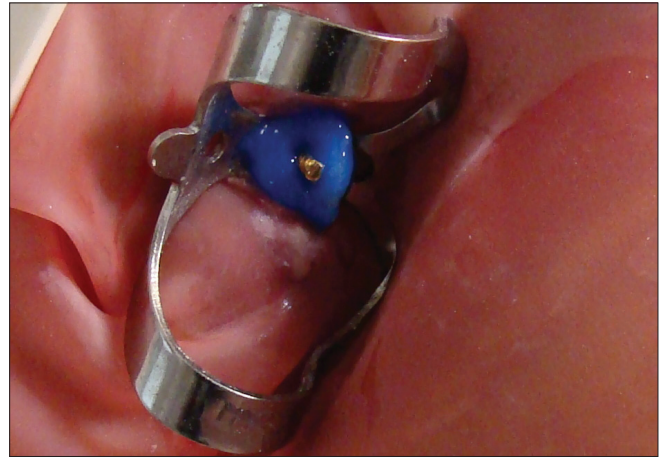**Figure 5:** Reverse metal post is trying in the entrance of the filled canal



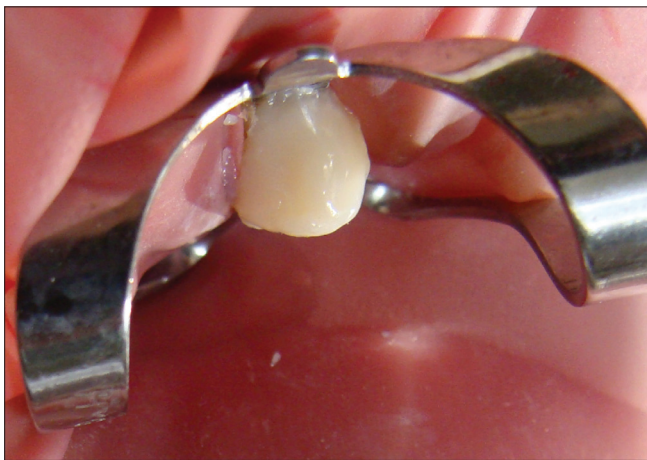**Figure 6:** Reverse metal post occlusal view



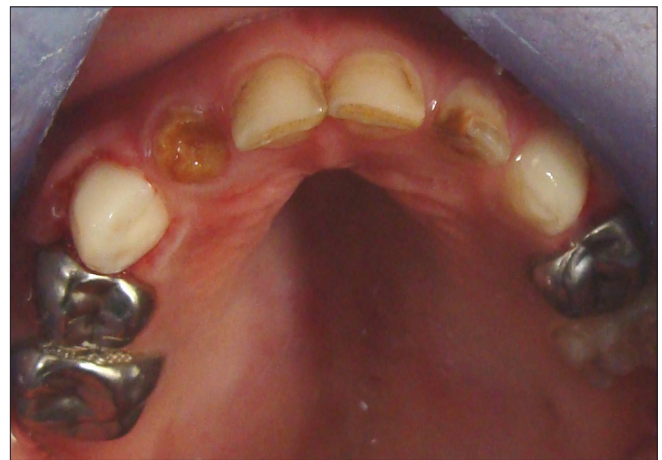**Figure 7:** Reverse metal post shortened and cemented in the canal



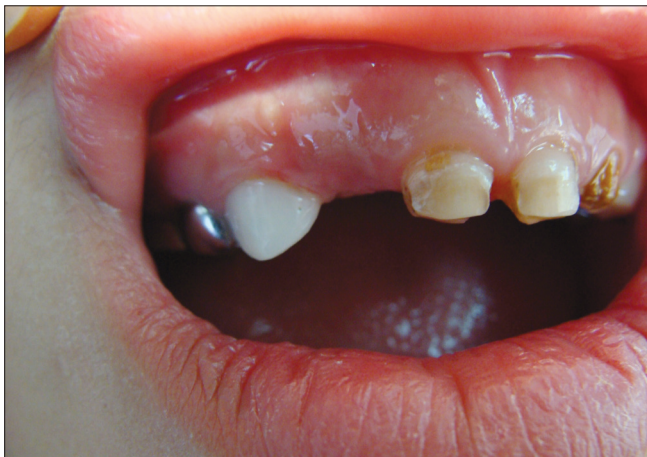**Figure 8:** Acid-etching



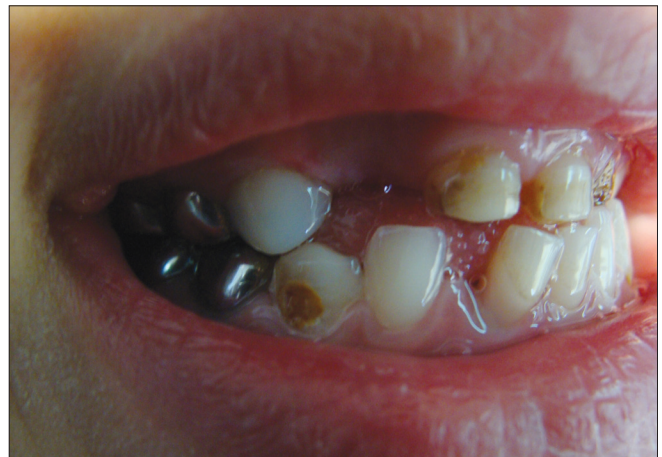**Figure 9:** Reconstructed crown with composite resin



**Figure 10:** Final restoration



**Figure 11:** Frontal view of the restoration after 18 months



**Figure 12:** Lateral view of the restoration after 18 months

carbon fibers, polyethylene fibers, ribbons or tapes, glass fibers, etc.<sup>[2,3,5,9,10,17]</sup> in the reconstruction of extremely damaged primary anterior teeth has been an acceptable treatment option. Good adaptation to the canal walls by the application of composite resin, enough retention

and stability are advantages of the treatment; but some disadvantages such as excessive cost for pediatric dentistry, technique sensitivity and time consumption due to multiple steps in a little child who is rather uncooperative make this alternative treatment luxurious.

In this report, a new and creative technique for reconstruction of severely destroyed primary anterior teeth has been presented. This direct restorative technique is user friendly and easy to perform. It is performed directly in the mouth without any additional laboratory processes; the restoration can be completed in one appointment and is a less demanding treatment for the patient. The post-initial stability in the canal attained through the quadrangle shape of the post's core is noticeable. Moreover, as there is enough composite material around the core part of the post system, more esthetics and shade adaptation is obtained, and no metallic show through the composite restoration is observed. In addition, the core length of the post system which is placed intracanal is equal to the recommended length for deciduous teeth; 3 mm occupies only the cervical one-third of the canal to avoid interfering with the process of primary tooth root resorption and permanent tooth eruption.<sup>[3,5,17]</sup>

It seems in cases with multiple severe decayed primary anterior teeth, especially in small children with rampant caries, the presented technique is simple, economical and easy to perform and practical for all dentists. However, the possibility of cracked root subsequent to long-term function, especially in children with heavy occlusion or parafunctional habits, needs more considerations. Further investigational studies are strongly recommended.

## CONCLUSION

The RMPT presented in this case report proves to be an easy-to-perform and economical procedure with adequate retention and good esthetic results in pediatric restorative dentistry. However, long-term clinical studies are needed to investigate the advantages and disadvantages of this new technique, and evaluate the clinical successes and failures of the teeth restored with the above-mentioned method.

## REFERENCES

1. Mouradian WE. The face of a child: Children's oral health and dental education. *J Dent Educ* 2001;65:821-31.
2. Sharaf AA. The application of fiber core posts in restoring badly destroyed primary incisors. *J Clin Pediatr Dent* 2002;26:217-24.
3. Viera CL, Ribeiro CC. Polyethylene fiber tape used as a post and core in decayed primary anterior teeth: A treatment option. *J Clin Pediatr Dent* 2001;26:1-4.
4. Ngan P, Fields H. Orthodontic diagnosis and treatment planning in the primary dentition. *ASDC J Dent Child* 1995;62:25-33.
5. Motisuki C, Santos-Pinto L, Giro EM. Restoration of severely

6. Kupietzky A, Waggoner WE, Galea J. Long-term photographic and radiographic assessment of bonded resin composite strip crowns for primary incisors: Results after 3 years. *Pediatr Dent* 2005;27:221-5.
7. Grewal N, Seth R. Comparative *in vivo* evaluation of restoring severely mutilated primary anterior teeth with biological post and crown preparation and reinforced composite restoration. *J Indian Soc Pedod Prev Dent* 2008;26:141-8.
8. Mendes FM, De Benedetto MS, del Conte Zardetto CG, Wanderley MT, Correa MS. Resin composite restoration in primary anterior teeth using short-post technique and strip crowns: A case report. *Quintessence Int* 2004;35:689-92.
9. Island G, White GE. Polyethylene ribbon fibers: A new alternative for restoring badly destroyed primary incisors. *J Clin Pediatr Dent* 2005;29:151-6.
10. Rocha Rde O, das Neves LT, Marotti NR, Wanderley MT, Corrêa MS. Intracanal reinforcement fiber in pediatric dentistry: A case report. *Quintessence Int* 2004;35:263-8.
11. Subramaniam P, Babu KL, Sunny R. Glass fiber reinforced composite resin as an intracanal post-clinical study. *J Clin Pediatr Dent* 2008;32:207-10.
12. Aminabadi NA, Farahani RM. The efficacy of a modified omega wire extension for the treatment of severely damaged primary anterior teeth. *J Clin Pediatr Dent* 2009;33:283-8.
13. Waggoner WF. Restorative dentistry for the primary dentition. In: Pinkham JR, Casamassimo PS, Fields HW, McTigue DJ, Nowak AJ, editors. *Pediatric dentistry, infancy through adolescence*. 4<sup>th</sup> ed. St. Louis: Elsevier Saunders; 2005. p. 366.
14. McDonald RE, Avery DR. Restorative dentistry. In: McDonald RE, Avery DR, Dean JA, editors. *Dentistry for the child and adolescent*. 8th ed. St. Louis: Mosby; 2004. p. 376.
15. Kennedy DB. *Paediatric operative dentistry*. 3<sup>rd</sup> ed. Bristol: Wright; 1986. p. 102-5.
16. Usha M, Deepak V, Venkat S, Gargi M. Treatment of severely mutilated incisors: A challenge to the pedodontist. *J Indian Soc Pedod Prev Dent* 2007;25:S34-6.
17. Bayrak S, Tunc ES, Tuloglu N. Polyethylene fiber-reinforced composite resin used as a short post in severely decayed primary anterior teeth: A case report. *Oral Surg Oral Med Oral Pathol Oral Radiol Endod* 2009;107:e60-4.
18. Rifkin AJ. Composite post-crowns in anterior primary teeth. *J Dent Assoc S Afr* 1983;38:225-7.
19. Mortada A, King NM. A simplified technique for the restoration of severely mutilated primary anterior teeth. *J Clin Pediatr Dent* 2004;28:187-92.
20. Judd PL, Kenny DJ, Johnston DH, Yacobi R. Composite resin short-post technique for primary anterior teeth. *J Am Dent Assoc* 1990;120:553-5.
21. Ram D, Fuks AB. Clinical performance of resin-bonded composite strip crowns in primary incisors: A retrospective study. *Int J Paediatr Dent* 2006;16:49-54.

**How to cite this article:** Eshghi A, Esfahan RK, Khoroushi M. A simple method for reconstruction of severely damaged primary anterior teeth. *Dent Res J* 2011;8:221-5.

**Source of Support:** Isfahan University of Medical Sciences, Isfahan, Iran, **Conflict of Interest:** The authors declare no conflicts of interest, real or perceived, financial or nonfinancial.