

Regional MRI Diffusion, White-Matter Hyperintensities, and Cognitive Function in Alzheimer's Disease and Vascular Dementia

Claudia Altamura^a

Federica Scrascia^a

Carlo Cosimo Quattrocchi^b

Yuri Errante^b

Emma Gangemi^b

Giuseppe Curcio^{c,d}

Francesca Ursini^a

Mauro Silvestrini^e

Paola Maggio^a

Bruno Beomonte Zobel^b

Paolo Maria Rossini^f

Patrizio Pasqualetti^g

Lorenzo Falsetti^h

Fabrizio Vernieri^a

^aNeurology Unit, Campus Bio-Medico University, Rome, Italy

^bRadiology Unit, Campus Bio-Medico University, Rome, Italy

^cClinical Medicine Department, Public Health, Life and Environment Sciences, University of L'Aquila, Italy

^dIRCCS S. Raffaele, Rome - S.Raffaele Clinic, Cassino (FR), Italy

^eNeurology Clinic, Università Politecnica delle Marche, Ancona, Italy

^fNeurology Clinic, Università Cattolica del Sacro Cuore, Rome, Italy

^gAssociazione Fatebenefratelli per la ricerca-AFAR, Rome, Italy

^hInternal and Subintensive Medicine, Ospedali Riuniti Ancona, Italy

Received January 6, 2015

Revised May 10, 2015

Accepted May 13, 2015

Correspondence

Claudia Altamura, MD, PhD

Unità di Neurologia, Università Campus Bio-Medico di Roma, Via Alvaro del Portillo, 200, Roma 00122, Italy

Tel +39-06-225411285

Fax +39-06-225411955

E-mail c.altamura@unicampus.it

Background and Purpose An increase in brain water diffusivity as measured using magnetic resonance imaging (MRI) has been recently reported in normal-appearing white matter (NAWM) in patients affected by cognitive impairment. However, it remains to be clarified if this reflects an overt neuronal tissue disruption that leads to degenerative or microvascular lesions. This question was addressed by comparing the regional MRI apparent diffusion coefficients (ADCs) of NAWM in patients affected by Alzheimer's disease (AD) or vascular dementia (VaD). The relationships of ADCs with the white-matter hyperintensity (WMH) burden, carotid atherosclerosis, and cognitive performance were also investigated.

Methods Forty-nine AD and 31 VaD patients underwent brain MRI to assess the WMH volume and regional NAWM ADCs, neuropsychological evaluations, and carotid ultrasound to assess the plaque severity and intima-media thickness (IMT).

Results Regional ADCs in NAWM did not differ between VaD and AD patients, while the WMH volume was greater in VaD than in AD patients. The ADC in the anterior corpus callosum was related to the WMH volume, while a greater carotid IMT was positively correlated with the temporal ADC and WMH volume. The memory performance was worse in patients with higher temporal ADCs. Constructional praxis scores were related to ADCs in the frontal, and occipital lobes, in the anterior and posterior corpus callosum as well as to the WMH volume. Abstract reasoning was related to frontal, parietal, and temporal ADCs.

Conclusions Our data show that higher regional ADCs in NAWM are associated with microcirculatory impairment, as depicted by the WMH volume. Moreover, regional ADCs in NAWM are differently associated with the neuropsychological performances in memory, constructional praxis, and abstract reasoning domains.

Key Words Alzheimer's disease, vascular dementia, diffusion magnetic resonance imaging, leukoariosis, atherosclerosis.

INTRODUCTION

White-matter hyperintensities (WMHs) are typically observed in patients affected by vascular dementia (VaD) but can also be present in patients who fulfil the clinical diagnostic criteria for typical Alzheimer's disease (AD). The impact of WMHs on cognition and the relationship between AD and cerebrovascular diseases are uncertain. However, there is an increasing body of evidence supporting that vascular factors can influence the risk of developing AD and its progression,¹ affecting brain functions both directly and via neurodegenerative processes.² Carotid diseases also reportedly play a relevant role. A greater intima-media thickness (IMT) has been consistently associated with AD, possibly as a marker of cerebral microcirculatory involvement,³⁻⁵ while severe carotid stenosis may increase the

© This is an Open Access article distributed under the terms of the Creative Commons Attribution Non-Commercial License (<http://creativecommons.org/licenses/by-nc/3.0>) which permits unrestricted non-commercial use, distribution, and reproduction in any medium, provided the original work is properly cited.

risk of dementia as a source of cerebral microembolisms and hemodynamic failure.⁶⁻⁸

In recent years there have been numerous diffusion-weighted imaging (DWI) studies describing an increase in water diffusivity in T2-weighted hyperintense areas and in normal-appearing white matter (NAWM) in patients with impaired cognitive performance.⁹⁻¹⁷ Increased random water motion may derive from a degeneration of microstructural barriers, such as loss of membrane integrity and myelin or decreased cellular density. Water diffusivity was reported to be higher in demented patients than in controls, mainly in temporal and posterior regions.¹⁸⁻²⁰ In addition, an increase in white matter (WM) water diffusivity and high WMH load can both predict the clinical progression of patients with mild cognitive impairment to dementia.^{21,22} The LADIS study showed that apparent diffusion coefficient (ADC) values within the NAWM are related to WMH severity and have a WMH-independent effect on cognitive function in patients with leukoaraiosis.²³ More recently, ADC changes in NAWM were also demonstrated to precede the development of WMH lesions.^{24,25} Finally, higher water ADCs were described in patients with carotid steno-occlusive diseases as the result of chronic low-grade ischemic damage due to an impaired cerebral hemodynamics.^{26,27} Water ADC changes in the ipsilateral hemisphere were also found to be partly reversible after carotid revascularization.^{28,29}

These findings together raise the question of whether the increased water diffusion in NAWM observed in demented patients reflects an overt neuronal tissue disruption that leads to degenerative or microvascular lesions. To address this question, this study compared regional ADCs of NAWM in patients affected by AD or VaD. We also investigated the relationships of ADCs with WMH burden, carotid atherosclerosis, and cognitive performance.

METHODS

This single-cohort, cross-sectional study included consecutive patients admitted to our Neurology Unit from January 2010 to December 2011 for a first-ever evaluation of cognitive impairment according to the following inclusion criteria:

- 1) Diagnosis of probable AD according to NINCDS-ADRDA criteria.³⁰
- 2) Diagnosis of probable VaD according to NINDS-AIREN criteria with brain magnetic resonance imaging (MRI) evidence of small-vessel disease.^{31,32}

Patients who could not undergo MRI were excluded from enrollment. Screened subjects underwent neurological and neuropsychological evaluations, and brain imaging. We enrolled 80 patients (49 AD and 31 VaD) based on the inclusion

criteria.

The clinical history were obtained from each patient using a structured clinical interview (with the involvement of caregivers where necessary) and hematochemical data with a focus on the main vascular risk factors of hypertension, diabetes, smoking habits, and hyperlipidemia. Hypertension was defined as a history of high blood pressure, a systolic blood pressure of ≥ 140 mm Hg, a diastolic blood pressure of ≥ 90 mm Hg, or the use of an antihypertensive; dyslipidemia was defined as a history of dyslipidemia, a fasting serum total cholesterol level of ≥ 6.22 mmol/L (2.4 g/L) or a triglycerides level of ≥ 2.26 mmol/L (2 g/L), or the use of a statin or fibrate; diabetes mellitus was defined as a history of diabetes mellitus, a fasting serum glucose level of ≥ 7.0 mmol/L (1.26 g/L), or the use of an oral antihyperglycemic or insulin; and smoking was defined as a history of active tobacco smoking.

All enrolled patients underwent brain MRI to assess regional ADCs and the WMH volume, and an ultrasound examination of neck vessels to investigate carotid atherosclerosis. All patients were naïve to dementia therapy. Patients displaying strategic infarct lesions in MRI were excluded from the study.

The experimental protocol was approved by our Hospital Ethical Committee and all subjects or their caregivers signed a written informed consent.

Neuropsychological evaluation

Subjects underwent cognitive testing in a single assessment during the week when the ultrasound and MRI investigations were performed. The neuropsychological evaluation battery aimed to provide a measure of general cognitive efficiency as well as to assess a wide range of definite cognitive areas. The Italian version of the Mini Mental State Examination (MMSE)³³ was used as a global measure of cognitive status. Episodic long-term memory was assessed using the Rey Auditory Verbal Learning test, assessing the immediate and 15-min delayed recall of a 15-word list. Language was assessed based on oral denomination of real-life objects.³⁴ Problem-solving and abstract reasoning were assessed using Raven's Coloured Progressive Matrices, focused attention was tested using a digit visual search task,³⁵ and constructional praxia was tested by asking the subjects to copy some simple pictures.³⁶ The raw scores of neuropsychological tasks in each test of the battery were corrected for age and education using normative validation for the Italian population.³⁵ Each test used a normative cutoff score corresponding to the lower limit of the tolerance interval on a 95% one-tailed test (for a confidence level of 95%) based on the score obtained by healthy subjects in the standardization sample.

Neuroradiological evaluation

MRI and diffusion-weighted imaging studies were performed with a 1.5-T magnet (Magnetom Avanto B13, Siemens, Erlangen, Germany). The following imaging protocols and parameters were used: fluid-attenuated inversion recovery (FLAIR) sequences (TR=11,451 msec, TE=102 msec, TI=2,360 msec, slice thickness=3 mm) acquired on the axial plane, turbo spin echo T2-weighted fat-saturated sequences (TR=10,400 msec, TE=105 msec, slice thickness=3 mm) acquired on the coronal plane, spin echo T1-weighted sequences (TR=647 msec, TE=11 msec, slice thickness=4 mm) acquired on the sagittal plane, and echo planar imaging diffusion-weighted sequences (TR=3,927 msec, TE=106 msec, slice thickness=5 mm; one with b=0 and three orthogonal gradient directions at b=1,000) acquired on the axial plane. The total WMH volume was computed on FLAIR axial images at E0 after producing segmented lesional region of interests (ROIs) through a semiautomated local thresholding approach (Osirix[®] software, version 3.9.4 Pixmeo SARI, Bernex, Switzerland).³⁷

Average ADC maps were computed on a pixel-by-pixel basis using the equation of Stejskal and Tanner.³⁸ Elliptic ROIs were positioned bilaterally on the ADC maps as described by Stahl et al.¹⁸ in NAWM in the parietal, frontal, temporal, and occipital lobes of the corpus callosum (genu and splenium), and in the posterior limb of the internal capsule (between the pallidum and the thalamus). In contrast to Stahl et al.,¹⁸ the ROI size was kept consistent (30–35 mm²) across patients in order to obtain a stable number of voxels and decrease the variance of ADCs. The correct ROI position was confirmed by simultaneous visual comparison with the corresponding slices of the FLAIR axial data sets. ROIs were positioned on the NAWM, defined as areas without WMHs on the corresponding FLAIR image. If WMHs were present, the ROI was shifted to reduce type I errors.

Carotid ultrasound

Carotid arteries were assessed in all subjects and defined by continuous-wave Doppler ultrasound and color-flow B-mode Doppler ultrasound, as described elsewhere¹ using high-resolution 7.5 MHz transducers (iU22 Philips Ultrasound, Bothell, WA, USA). IMT was measured according to standardized guidelines.³⁹ In each arterial segment, the plaque severity was quantified as follows: 0, no plaque; 1, one plaque with stenosis of <30% (mild stenosis) of the vessel diameter; 2, one plaque with stenosis of 30–50% of the vessel diameter (moderate stenosis) or multiple plaques with stenosis of <30%; and 3, one plaque with stenosis of >50% of the vessel diameter (severe stenosis) or multiple plaques with at least one moderate stenosis. A plaque index was calculated by add-

ing the scores of the right and left carotid arteries. The neurosonographers were blind to the MRI findings and cognitive performance of the patient.

Statistical analysis

The dimensionality of ADC measures (as indicated in the Methods) was reduced using principal-components analysis (PCA). The Kaiser-Meyer-Olkin measure of sampling adequacy was fair for PCA (0.72), with 74% of the total variance explained by the following six factors: frontal, parietal, temporal, and occipital lobes and the genu and splenium of the corpus callosum. We considered the mean value for the right and left sides of each area, since the results did not differ significantly between the two sides. Variables that did not conform to a normal distribution in the Kolmogorov-Smirnov test (i.e., years of education, ADCs in the frontal lobe and the genu and splenium of the corpus callosum, and WMH volume) underwent a logarithmic transformation in order to produce a better fit with a Gaussian distribution. Baseline characteristics of the sample were compared with respect to demographic, radiological, and clinical characteristics using the chi-square test, *t*-test, or Mann-Whitney test depending on the data type and distribution. Spearman's rho test was adopted to assess correlations between ADCs and cognitive performance.

Linear regression models were used to assess if regional ADCs in NAWM were related to the WMH load, ultrasound carotid findings, or vascular risk factors. Relationships between the WMH load, classical risk factors, and ultrasound carotid findings were assessed using different multiple linear regression (MLR) analyses. The first MLR model adopted the WMH load as the dependent variable and diagnosis, dyslipidemia, hypertension, diabetes, and smoking as independent factors. The second MLR model used the WMH load as the dependent factor and the mean IMT, diagnosis, and plaque index as independent variables. The third model assessed the correlation between WMH load and the PCA-selected ADCs. We included the features from the MLR models that were the most statistically significant in a general linear model (GLM) in order to assess the relationship between factors and the WMH load. A factor was deemed to be significantly associated with the dependent variable and selected for the GLM if its probability value was ≤ 0.1 in the regression analyses. Finally, we evaluated the associations of the WMH load, mean IMT, and ADC in the anterior corpus callosum in a GLM correcting for the following covariates that could influence the association: age, sex, diagnosis, education, and MMSE score. Statistical analyses were performed using the SPSS software (version 17.0, SPSS Inc., Chicago, IL, USA).

RESULTS

Table 1 summarizes the patient sociodemographic, vascular, and cognitive profiles. The VaD and AD patients did not differ in terms of age, education, prevalence of vascular risk factors, or ultrasound findings. AD patients were more frequently female ($p=0.04$) and presented more-severe memory deficits ($p=0.001$) than did VaD patients.

Table 2 summarizes the neuroradiological findings. The ADCs did not differ between VaD and AD patients, while the WMH volume was greater in VaD than in AD patients ($p=0.04$). We found no significant relationship between vascular risk factors, ADCs, and WMH volume ($p>0.1$).

Linear regression models showed that the mean IMT was associated with the temporal ADC ($\beta=85.72$, $SE=37.175$; $t=1.947$, $p=0.24$; $R^2=0.105$, $p=0.04$) and WMH volume ($\beta=4.504$, $SE=1.909$; $t=2.360$, $p=0.21$; $R^2=0.122$, $p=0.036$). No other associations were observed between radiological and ultrasound markers.

Table 3 presents the results obtained when applying the MLR model to test if ADCs can predict the WMH volume. This analysis demonstrated that ADC in the genu of the corpus callosum was related to the WMH volume ($R^2=0.272$,

$p=0.008$). Fig. 1 shows a scatterplot illustrating the relationship on a logarithmic scale between ADC in the anterior corpus callosum and the WMH volume in AD and VaD patients. The GLM was set up using the WMH load as the main dependent variable. The mean IMT and ADC in the anterior corpus callosum were both inserted in the model as predictors, since they were significantly associated with the WMH load in different regression analyses. The GLM results were significant ($p<0.0001$), confirming that both the mean IMT ($p=0.029$, partial $\eta^2=0.071$, observed power=0.597) and ADC in the anterior corpus callosum ($p=0.003$, partial $\eta^2=0.122$, observed power=0.848) were significantly associated with the WMH load. The corrected GLM results were also significant ($p=0.010$), again confirming that both the mean IMT ($p=0.031$, partial $\eta^2=0.076$, observed power=0.586) and ADC in the anterior corpus callosum ($p=0.008$, partial $\eta^2=0.110$, observed power=0.765) were significantly associated with the WMH load even after correcting for covariates.

Spearman's rho coefficients for the correlations between neuropsychological performances in different cognitive domains and neuroradiological markers are reported in Table 4. In brief, the memory performance was worse in patients

Table 1. Comparison of demographics, carotid ultrasound and neuropsychological test findings between AD and VaD patients

	AD (n=49)	VaD (n=31)	p
Sex (F; %)	53.1	29.0	0.04**
Age, years (SD)	80.4 (3.2)	80.7 (3.8)	>0.1 [§]
Education, years (SD)	7.7 (4.8)	7.7 (4.3)	>0.1
Vascular risk factors (%)			
Smoking	6.1	6.5	>0.1 [†]
Hypertension	67.3	77.7	>0.1 [†]
Hyperlipidemia	38.8	29.0	>0.1 [†]
Diabetes	18.4	22.6	>0.1 [†]
Ultrasound findings, mean (SD)			
Mean IMT (mm)	0.81 (0.14)	0.86 (0.16)	>0.1 [§]
Plaque index (%)			
No plaque	53.1	58.1	>0.1
Mild stenosis	20.4	19.4	
Moderate stenosis	22.4	19.4	
Severe stenosis	4.1	3.2	
Neuropsychological evaluation (cognitive function, test, cut-off), mean (SD)			
Memory, Rey's 15 words Memory test, >28.53	24.9 (7.1)	30.9 (7.3)	0.001 ^{†§}
Attention, attentive matrices, >31	31.1 (11.2)	29.4 (8.5)	>0.1 [§]
Constructional Praxis, drawings copying, >7.18	6.3 (2.4)	6.7 (2.1)	>0.1 [§]
Abstract Reasoning, Raven's Progressive matrices, >18.96	20.2 (7.9)	21.1 (7.3)	>0.1 [§]
Language, oral denomination, >28	22.7 (5.6)	24.8 (4.5)	>0.1 [§]
Global evaluation, Mini Mental State Examination, >24	19.7 (3.7)	21.3 (3.6)	>0.1 [§]
Mini Mental State Examination range	12–26	13–26	

Significant correlations: * $p<0.05$, [†] $p<0.01$, [‡]chi-square, [§]t-test, ^{||}Mann-Whitney. AD: Alzheimer's disease, IMT: intima-media thickness, VaD: vascular dementia.

Table 2. Comparison of demographics, carotid ultrasound and neuropsychological test findings between AD and VaD patients

	AD (n=49)		VaD (n=31)	
	R	L	R	L
ADC value (mm ² /s), mean (SD)				
Region of interest				
Frontal	854.0 (86.5)	863.4 (76.1)	862.2 (119.1)	889.7 (217.7)
Parietal	811.7 (75.8)	811.2 (65.4)	797.5 (68.4)	798.3 (65.6)
Anterior pericallosal area	856.2 (99.8)	858.7 (88.3)	877.2 (140.2)	903.8 (220.4)
Posterior pericallosal area	863.8 (80.8)	861.2 (84.2)	840.5 (90.6)	843.1 (126.3)
Temporal	841.6 (52.1)	836.8 (58.3)	836.8 (58.3)	844.9 (55.4)
Basal ganglia	774.3 (75.2)	776.2 (70.3)	783.6 (50.6)	792.4 (64.8)
Occipital	842.2 (65.5)	841.0 (65.3)	808.9 (54.6)	814.6 (66.4)
Anterior Corpus Callosum	918.6 (132.6)		1008.3 (381.5)	
Posterior Corpus Callosum	829.9 (121.7)		845.5 (102.9)	
White Matter Hyperintensities, mean (sd)				
WMH volume (cm ³)	34.4 (129.5)		146.07 (355.8)*	

Significant correlations: **p*<0.05 Mann-Whitney test.

AD: Alzheimer disease, ADC: apparent diffusion coefficient, L: left, MMSE: Mini Mental State Examination, R: right, VaD: vascular dementia, WMH: white matter hyperintensities.

Table 3. Multiple linear regression model predicting white matter hyperintensity volume in enrolled patients (n=80)

Variable	B	Standard error	t	p value
Diagnosis	0.782	0.621	1.258	0.213
Frontal	-1.860	4.007	-0.464	0.644
Temporal	0.007	0.006	1.297	0.200
Parietal	0.002	0.005	0.364	0.717
Occipital	-0.011	0.006	-1.851	0.069
Anterior Corpus Callosum	5.234	2.401	2.180	0.033*
Posterior Corpus Callosum	1.909	2.421	0.788	0.434

The table displays multiple linear regression model applied to test if different regional ADCs (independent variables) could predict WMH volume (dependent variable). This analysis demonstrated that ADC in the Genu of Corpus Callosum was related to WMH volume ($R^2=0.272$, $p=0.008$) irrespective of diagnosis. Significant correlations: **p*<0.05.

ADC: apparent diffusion coefficient, WMH: white-matter hyperintensity.

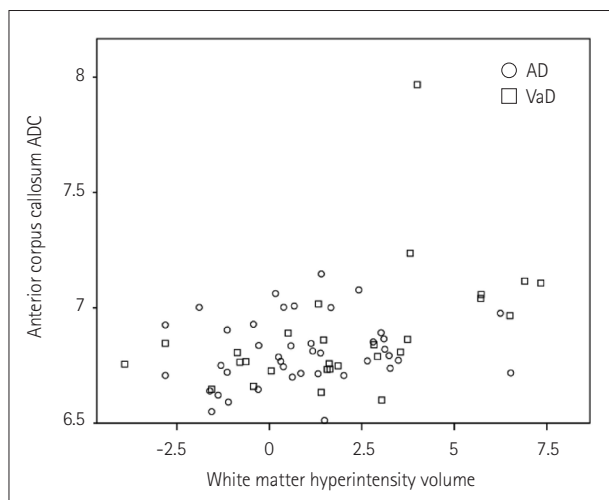


Fig. 1. Scatterplot showing the relationship on a logarithmic scale between the ADC in the anterior corpus callosum and the WMH volume in AD (circles) and VaD (squares) patients.

with higher temporal ADC scores. Attention and language status were not associated with any neuroradiological marker. Constructional praxis test scores were related to frontal and occipital ADCs, ADCs of the genu and splenium of the corpus callosum, and the WMH volume. Abstract reasoning was related to frontal, parietal, and temporal ADCs.

DISCUSSION

Whether WM is primarily involved in the physiopathology of AD or secondarily in axonal loss is still a matter of debate. DWI is a promising MRI technique for evaluating ultrastructural abnormalities in the gray matter and the NAWM in demented patients and adults without dementia.⁴⁰ We investigated if the extent and distribution of NAWM alterations, as analyzed by DWI MRI, differ between neurodegenerative processes and VaD.

Table 4. Spearman's rho correlation between neuroradiological findings and cognitive domain performances

Radiological marker	Cognitive domain					
	MMSE	Memory	Attention	Constructional praxis	Abstract reasoning	Language
ADC						
Frontal	0.028	0.096	-0.034	-0.345 [†]	-0.374 [†]	-0.102
Parietal	-0.242*	-0.076	-0.076	-0.178	-0.283*	-0.023
Temporal	-0.067	-0.290*	-0.016	-0.123	-0.253*	0.031
Occipital	-0.172	-0.133	0.070	-0.270*	-0.221	-0.180
Anterior Corpus Callosum	0.060	0.022	-0.001	-0.244*	-0.181	0.021
Posterior Corpus Callosum	-0.087	0.041	0.066	-0.286*	-0.158	-0.050
WMH volume	-0.020	-0.047	-0.200	-0.282*	-0.252	-0.035

Significant correlations: * $p < 0.05$, [†] $p < 0.01$.

ADC: apparent diffusion coefficient, MMSE: Mini Mental State Examination, WMH: white matter hyperintensity.

In our cohort, the regional ADC in NAWM did not discriminate AD from VaD patients. Nevertheless, ADC in the anterior corpus callosum was associated with WMH severity (Fig. 1) in both groups. This finding is consistent with the results of a postmortem study of the prefrontal WM in a cohort of patients with concomitant vascular and degenerative pathological changes, which found that the free-radical damage related to increased diffusivity was more severe in cases with vascular brain injury and poor degenerative pathology.⁴¹ Similarly, another MRI study of AD patients observed changes in the diffusor tensor in the limbic network and an increase in ADCs in the cortico-cortical association tracts.⁴² Those authors speculated that while degeneration and myelin damage contributed to the changes in the MRI diffusor tensor of the limbic network, microvascular pathology subtended the WM damage in the association tracts. The main involvement of the genu of the corpus callosum is also consistent with the previous observations that degenerative and vascular processes contribute equally to the disruption of the anterior corpus callosum in AD patients, while the impact of neurodegeneration is prominent in the posterior corpus callosum.⁴³ In fact, vascular pathology commonly affects the frontal and parietal WM regions to a greater extent than the temporal and occipital WM in both AD and VaD patients.⁴⁴

This was recently confirmed by a very recent study that analyzed the impact of WMHs on the WM network.⁴⁵ That study found that nodal efficiency—which is one of the parameters quantifying the importance of each node for communication within a network—was mostly affected by WMHs in the frontal regions.

On the other hand, the ADC in the temporal lobe was related to the carotid IMT, which in turn was associated with WMH severity. The carotid IMT is a surrogate of atherosclerosis that can be used to characterize the global vascular risk and, among the other markers, including carotid plaques, is the only one related to the predisposition to the develop-

ment of cognitive decline in both normal subjects and AD patients.^{1,3} Vessel degenerative changes may be better reflected by the carotid IMT than by carotid plaques, also at the cerebral microcirculation level. An altered microcirculation may produce diffuse hypoperfusion with chronic hypoxia, which might ultimately also trigger neurodegenerative changes.² The temporal lobe—more specifically the hippocampus—is known to be particularly vulnerable to hypoxia. In this view, the relationship between ADC in the temporal lobe and the carotid IMT can be explained by a neural derangement, probably with a mixed microcirculatory and degenerative origin. That is, cerebral hypoperfusion induced by small-vessel disease leads to ischemia in WM regions, causing demyelination and axonal loss in the WM network, which in turn results in secondary damage to neuronal cell bodies and atrophy of the gray matter.

Our results also indicated that the memory, abstract reasoning, and picture-copying test scores were associated with the regional NAWM ADCs in the brain areas involved in the corresponding cognitive domains. In addition, patients who experienced greater difficulties in copying pictures, which is a task involving multiple cognitive domains, presented more-severe WMHs.

However, the regional ADCs were not associated with the scores in the attention tests. One possible explanation is that the test we had selected to assess attention is specific but may not be adequately sensitive. The regional ADCs also were not correlated with language performances, suggesting that WM subtle alterations, such as those depicted by NAWM ADC analysis, do not have a relevant clinical effect on this cognitive domain.

One limitation of this study is that we did not perform an assessment of cortical atrophy. It would have been interesting to investigate the possible relationship between NAWM ADCs and cortical volumetric measures. In addition, we did not perform diffusion-tensor and fractional anisotropy imaging so as to study water diffusivity in the WM. Similarly,

to better study cerebral microcirculation, other radiological techniques (e.g., perfusion MRI using contrast agents) would have yielded more informative data. On the other hand, we chose rather simple radiological markers that can be applied rapidly in a clinical setting, which allowed us to extend the evaluation to a larger number of demented patients, for whom applying MRI can often be difficult.

Another limitation of our study is that the cohort comprised a rather cognitively homogeneous population of patients; this might have concealed some possible relationships between radiological markers and cognitive status. However, to test if ADCs could help in discriminating AD from VaD in an early stage of dementia, subjects were enrolled from among patients admitted to our department for a first evaluation of cognitive impairment.

The results of our study suggest that although the regional water diffusivity in NAWM does not discriminate AD from VaD patients, increased regional ADCs may reflect a derangement of neural tissue linked to a microcirculatory impairment, which is below the detection threshold of conventional MRI techniques but is associated with altered cognitive domains. It should be noted that these findings are consistent with previous studies demonstrating that water diffusivity measured in the cerebral cortex may be an early marker of neuronal degenerative damage.⁴⁶

Acknowledgements

We would like to thank EG for the English revision.

Conflicts of Interest

The authors have no financial conflicts of interest.

REFERENCES

- Viticchi G, Falsetti L, Vernieri F, Altamura C, Bartolini M, Luzzi S, et al. Vascular predictors of cognitive decline in patients with mild cognitive impairment. *Neurobiol Aging* 2012;33:1127.e1-e9.
- Iadecola C. The overlap between neurodegenerative and vascular factors in the pathogenesis of dementia. *Acta Neuropathol* 2010;120:287-296.
- van Oijen M, de Jong FJ, Witteman JC, Hofman A, Koudstaal PJ, Breteler MM. Atherosclerosis and risk for dementia. *Ann Neurol* 2007;61:403-410.
- Altamura C, Squitti R, Pasqualetti P, Tibuzzi F, Silvestrini M, Ventriglia MC, et al. What is the relationship among atherosclerosis markers, apolipoprotein E polymorphism and dementia? *Eur J Neurol* 2007;14:679-682.
- de la Torre JC. The vascular hypothesis of Alzheimer's disease: bench to bedside and beyond. *Neurodegener Dis* 2010;7:116-121.
- Buratti L, Balestrini S, Altamura C, Viticchi G, Falsetti L, Luzzi S, et al. Markers for the risk of progression from mild cognitive impairment to Alzheimer's disease. *J Alzheimers Dis* 2015;45:883-890.
- de la Torre JC. Carotid artery ultrasound and echocardiography testing to lower the prevalence of Alzheimer's disease. *J Stroke Cerebrovasc Dis* 2009;18:319-328.
- Marshall RS, Lazar RM. Pumps, aqueducts, and drought management: vascular physiology in vascular cognitive impairment. *Stroke* 2011;42:221-226.
- O'Sullivan M, Morris RG, Huckstep B, Jones DK, Williams SC, Markus HS. Diffusion tensor MRI correlates with executive dysfunction in patients with ischaemic leukoaraiosis. *J Neurol Neurosurg Psychiatry* 2004;75:441-447.
- Shenkin SD, Bastin ME, Macgillivray TJ, Deary IJ, Starr JM, Rivers CS, et al. Cognitive correlates of cerebral white matter lesions and water diffusion tensor parameters in community-dwelling older people. *Cerebrovasc Dis* 2005;20:310-318.
- Della Nave R, Foresti S, Pratesi A, Ginestroni A, Inzitari M, Salvadori E, et al. Whole-brain histogram and voxel-based analyses of diffusion tensor imaging in patients with leukoaraiosis: correlation with motor and cognitive impairment. *AJNR Am J Neuroradiol* 2007;28:1313-1319.
- Nitkunan A, Barrick TR, Charlton RA, Clark CA, Markus HS. Multimodal MRI in cerebral small vessel disease: its relationship with cognition and sensitivity to change over time. *Stroke* 2008;39:1999-2005.
- Viana-Baptista M, Bugalho P, Jordão C, Ferreira N, Ferreira A, Forjaz Secca M, et al. Cognitive function correlates with frontal white matter apparent diffusion coefficients in patients with leukoaraiosis. *J Neurol* 2008;255:360-366.
- Wang L, Goldstein FC, Levey AI, Lah JJ, Meltzer CC, Holder CA, et al. White matter hyperintensities and changes in white matter integrity in patients with Alzheimer's disease. *Neuroradiology* 2011;53:373-381.
- Lee DY, Fletcher E, Martinez O, Ortega M, Zozulya N, Kim J, et al. Regional pattern of white matter microstructural changes in normal aging, MCI, and AD. *Neurology* 2009;73:1722-1728.
- Gouw AA, Seewann A, Vrenken H, van der Flier WM, Rozemuller JM, Barkhof F, et al. Heterogeneity of white matter hyperintensities in Alzheimer's disease: post-mortem quantitative MRI and neuropathology. *Brain* 2008;131(Pt 12):3286-3298.
- Alves GS, O'Dwyer L, Jurcoane A, Oertel-Knöchel V, Knöchel C, Prvulovic D, et al. Different patterns of white matter degeneration using multiple diffusion indices and volumetric data in mild cognitive impairment and Alzheimer patients. *PLoS One* 2012;7:e52859.
- Stahl R, Dietrich O, Teipel SJ, Hampel H, Reiser MF, Schoenberg SO. White matter damage in Alzheimer disease and mild cognitive impairment: assessment with diffusion-tensor MR imaging and parallel imaging techniques. *Radiology* 2007;243:483-492.
- Kantarci K, Jack CR Jr, Xu YC, Campeau NG, O'Brien PC, Smith GE, et al. Mild cognitive impairment and Alzheimer disease: regional diffusivity of water. *Radiology* 2001;219:101-107.
- Agosta F, Pievani M, Sala S, Geroldi C, Galluzzi S, Frisoni GB, et al. White matter damage in Alzheimer disease and its relationship to gray matter atrophy. *Radiology* 2011;258:853-863.
- Kantarci K, Petersen RC, Boeve BF, Knopman DS, Weigand SD, O'Brien PC, et al. DWI predicts future progression to Alzheimer disease in amnesic mild cognitive impairment. *Neurology* 2005;64:902-904.
- Staekenborg SS, Koedam EL, Henneman WJ, Stokman P, Barkhof F, Scheltens P, et al. Progression of mild cognitive impairment to dementia: contribution of cerebrovascular disease compared with medial temporal lobe atrophy. *Stroke* 2009;40:1269-1274.
- Schmidt R, Ropele S, Ferro J, Madureira S, Verdelho A, Petrovic K, et al. Diffusion-weighted imaging and cognition in the leukoaraiosis and disability in the elderly study. *Stroke* 2010;41:e402-e408.
- Maillard P, Carmichael O, Harvey D, Fletcher E, Reed B, Mungas D, et al. FLAIR and diffusion MRI signals are independent predictors of white matter hyperintensities. *AJNR Am J Neuroradiol* 2013;34:54-61.
- de Groot M, Verhaaren BF, de Boer R, Klein S, Hofman A, van der Lugt A, et al. Changes in normal-appearing white matter precede development of white matter lesions. *Stroke* 2013;44:1037-1042.
- Conklin J, Fierstra J, Crawley AP, Han JS, Poubblanc J, Silver FL, et al. Mapping white matter diffusion and cerebrovascular reactivity in ca-

- rotid occlusive disease. *Neurology* 2011;77:431-438.
27. Rentsch-Granges V, Assal F, Pereira VM, Alimenti A, Mosimann P, de Ribaupierre A, et al. ADC mapping of chronic cerebral hypoperfusion induced by carotid artery stenosis. *J Neuroradiol* 2011;38:232-237.
 28. Soinnie L, Helenius J, Saimanen E, Salonen O, Lindsberg PJ, Kaste M, et al. Brain diffusion changes in carotid occlusive disease treated with endarterectomy. *Neurology* 2003;61:1061-1065.
 29. Sahin N, Solak A, Genc B, Akpinar MB, Kulu U, Cengiz H. Brain diffusion changes in unilateral carotid artery stenosis with non-shunt endarterectomy: correlation with white matter lesions. *Clin Neurol Neurosurg* 2015;133:24-29.
 30. Dubois B, Feldman HH, Jacova C, Dekosky ST, Barberger-Gateau P, Cummings J, et al. Research criteria for the diagnosis of Alzheimer's disease: revising the NINCDS-ADRDA criteria. *Lancet Neurol* 2007;6:734-746.
 31. Román GC, Tatemichi TK, Erkinjuntti T, Cummings JL, Masdeu JC, Garcia JH, et al. Vascular dementia: diagnostic criteria for research studies. Report of the NINDS-AIREN International Workshop. *Neurology* 1993;43:250-260.
 32. van Straaten EC, Scheltens P, Knol DL, van Buchem MA, van Dijk EJ, Hofman PA, et al. Operational definitions for the NINDS-AIREN criteria for vascular dementia: an interobserver study. *Stroke* 2003;34:1907-1912.
 33. Grigoletto F, Zappalà G, Anderson DW, Lebowitz BD. Norms for the Mini-Mental State Examination in a healthy population. *Neurology* 1999;53:315-320.
 34. Miceli G, Laudanna A, Burani C, Capasso R. *Batteria per l'Analisi dei Deficit Afasici (B.A.D.A.)*. Roma: CEPSAG, Università Cattolica del Sacro Cuore; 1994.
 35. Spinnler H, Tognoni G. Standardizzazione e taratura italiana dei test neuropsicologici. *Ital J Neurol Sci* 1987;78-80:97-99.
 36. Lezak MD, Howieson DB, Loring DW. *Neuropsychological assessment*. 4th ed. New York: Oxford University Press, 2004.
 37. Rosset A, Spadola L, Ratib O. OsiriX: an open-source software for navigating in multidimensional DICOM images. *J Digit Imaging* 2004;17:205-216.
 38. Stejskal E, Tanner J. Spin diffusion measurements: spin echoes in the presence of a time-dependent field gradient. *J Chem Phys* 1965;42:288-292.
 39. Touboul PJ, Hennerici MG, Meairs S, Adams H, Amarenco P, Bornstein N, et al. Mannheim carotid intima-media thickness consensus (2004-2006). An update on behalf of the Advisory Board of the 3rd and 4th Watching the Risk Symposium, 13th and 15th European Stroke Conferences, Mannheim, Germany, 2004, and Brussels, Belgium, 2006. *Cerebrovasc Dis* 2007;23:75-80.
 40. Kantarci K, Senjem ML, Avula R, Zhang B, Samikoglu AR, Weigand SD, et al. Diffusion tensor imaging and cognitive function in older adults with no dementia. *Neurology* 2011;77:26-34.
 41. Back SA, Kroenke CD, Sherman LS, Lawrence G, Gong X, Taber EN, et al. White matter lesions defined by diffusion tensor imaging in older adults. *Ann Neurol* 2011;70:465-476.
 42. Pievani M, Agosta F, Pagani E, Canu E, Sala S, Absinta M, et al. Assessment of white matter tract damage in mild cognitive impairment and Alzheimer's disease. *Hum Brain Mapp* 2010;31:1862-1875.
 43. Lee DY, Fletcher E, Martinez O, Zozulya N, Kim J, Tran J, et al. Vascular and degenerative processes differentially affect regional inter-hemispheric connections in normal aging, mild cognitive impairment, and Alzheimer disease. *Stroke* 2010;41:1791-1797.
 44. Gootjes L, Teipel SJ, Zebuhr Y, Schwarz R, Leinsinger G, Scheltens P, et al. Regional distribution of white matter hyperintensities in vascular dementia, Alzheimer's disease and healthy aging. *Dement Geriatr Cogn Disord* 2004;18:180-188.
 45. Kim HJ, Im K, Kwon H, Lee JM, Kim C, Kim YJ, et al. Clinical effect of white matter network disruption related to amyloid and small vessel disease. *Neurology* 2015;85:63-70.
 46. Acosta-Cabronero J, Alley S, Williams GB, Pengas G, Nestor PJ. Diffusion tensor metrics as biomarkers in Alzheimer's disease. *PLoS One* 2012;7:e49072.