



Contents lists available at ScienceDirect

## International Journal of Surgery Case Reports

journal homepage: [www.casereports.com](http://www.casereports.com)

# Laparoscopic splenectomy for a simultaneous wandering spleen along with an ectopic accessory spleen. Case report and review of the literature

Antonia Rizzuto<sup>a,\*</sup>, Salomone Di Saverio<sup>b</sup>

<sup>a</sup> Department of Medical and Surgical Sciences, University Magna Graecia of Catanzaro, Italy

<sup>b</sup> Maggiore Hospital Regional Emergency Surgery and Trauma Center, Bologna Local Health District, Bologna, Italy

## ARTICLE INFO

### Article history:

Received 15 November 2017

Received in revised form 8 January 2018

Accepted 21 January 2018

Available online 9 February 2018

### Keywords:

Ectopic spleen

Wandering spleen

Laparoscopic splenectomy

## ABSTRACT

**BACKGROUND:** Wandering spleen and accessory spleen are uncommon entity occurring during embryonic development. Wandering spleen results in an excessive mobility and migration of the spleen from its normal position in the left hypochondrium while accessory spleen is characterized by ectopic splenic masses or tissue disjoined from the main body of spleen.

Due to the nonspecific and multiple symptoms the clinical diagnosis of both conditions is uncertain even with imaging techniques, such as CT and MRI. The coexistence of both diseases (wandering spleen and accessory spleen) is uncommon.

**CASE REPORT:** A 17-year old European female with a history of minor beta thalassemia and recurrent attacks of abdominal pain. Pre-operative management consisted of routine laboratory tests, ultrasound, CT scan. An ectopic spleen along with an accessory spleen were diagnosed. After a multidisciplinary board a laparoscopic splenectomy was performed. Post-operative recovery was uneventful, and the patient was discharged on the 6th post-operative day with the indication to continue the therapy with low molecular weight heparin (LMWH) for 30 days

**CONCLUSIONS:** This case represents a simultaneous condition of wandering splenomegaly along with an ectopic wandering spleen. The coexistence of these two rare conditions is peculiar such as the age of the patient, as literature reports such diseases to affect children or more commonly people in the range of 20–40 years of age. Laparoscopic treatment for this particular condition is also unusual.

© 2018 The Authors. Published by Elsevier Ltd on behalf of IJS Publishing Group Ltd. This is an open access article under the CC BY-NC-ND license (<http://creativecommons.org/licenses/by-nc-nd/4.0/>).

## 1. Introduction

Wandering spleen and accessory spleen are uncommon entity occurring during embryonic development. Each one of these diseases is rare and the association of both seems extremely rare and uncommon.

In ancient times, the knowledge referring to wandering spleen was based on the humor doctrine, according to which the spleen was believed to be an organ producing black bile. Galen himself called the spleen “organum plenum mysterii” [1].

Over the centuries the condition of wandering spleen was surrounded by an *aura* of mystery, since it was associated to hypocondria, hysteria and even to neurasthenia [2].

In the middle of the 19th century, Carl von Rokitansky, one of the most influential members of the Vienna School of Medicine, described the condition of wandering spleen in the “Lehrbuch der

pathologische Anatomie” [3]. In the years from 1854 to 1863 the Polish physician Józef Dietl was the first to describe patients with wandering spleen and indicated this condition to be life threatening [4].

Twentieth century medicine described wandering spleen or hypermobile spleen as an anatomic condition characterized by excessive mobility and migration of the spleen from its normal position in the left hypochondrium mainly represented in children [5–11] or women of reproductive age [12]. An accessory spleen is present in 10% of the population, with one or more splenic masses, with an average diameter of 1 cm, developed in initial phases of fetal life. The most frequent localizations are the splenic hilum and the pancreatic tail [8–12].

Patients with a wandering spleen may be present a movable mass in the abdomen, with chronic or intermittent abdominal pain caused by partial torsion and spontaneous detorsion of the splenic peduncle [10]. Due to the nonspecific and multiple symptoms the clinical diagnosis of both conditions is uncertain even with imaging techniques, such as CT and MRI [13,14].

The first splenectomy for wandering spleen was performed in 1878 by Martin; Soleimani reported in literature only 238 cases

\* Corresponding author at: Department of Medical and Surgical Science, University Hospital Magna Graecia Catanzaro, Viale Europa, 88100 Catanzaro, Italy.  
E-mail address: [arizzuto@unicz.it](mailto:arizzuto@unicz.it) (A. Rizzuto).

of wandering spleen from 1895 to 2005 with an age distribution ranging from new-borns to age 81, with 2 peaks, in childhood and in the 3rd decade of life.

The coexistence of the two rare conditions (wandering massive splenomegaly and ectopic wandering spleen) is peculiar such as the age of the patient and the laparoscopic approach.

This case report was conducted, and is reported in accordance with the SCARE criteria [24].

## 2. Case report

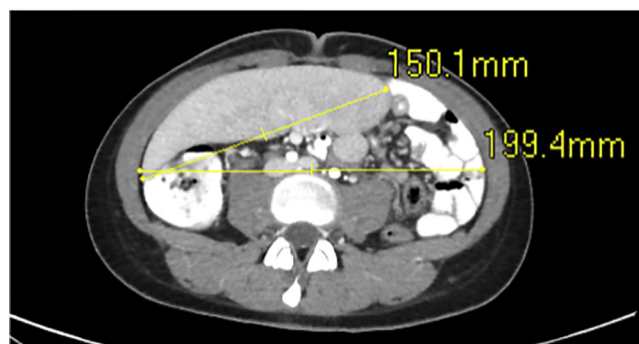
A 17 year-old-woman presented to our Institute with chronic intermittent abdominal pain without nausea vomiting or genitourinary complaints. She had history of minor beta-thalassemia, no trauma or injury. On admission, the patient presented with general condition, no fever, blood pressure 120/80 mmHg, 80 bpm and BMI 17.58.

Laboratory data showed leucopenia ( $4.65 \times 10^3/\mu\text{l}$ ) and a hemoglobin level of 11.6 g/dl, renal, liver function, amylase and lactate were within normal limits.

Examination of the abdomen reveals the triad of classic physical examination findings reported by Gindrey and Piquard in 1996 [11] unveiled a loose mobile intra abdominal slightly tender mass with well defined margins and parenchymatous consistency in right iliac fossa, right lumbar and umbilical region.

On abdominal ultrasonography an expanded spleen arising to the pelvis from right lumbar region was observed.

The abdominal intravenous contrast-enhanced computed tomography (CT) scan abdomen showed an ectopic spleen displaced in right side and mesogastrium of size  $15 \times 6 \times 12$  cm with an abnormal wandering pedicle (Figs. 1 and 2). Dilatation of the collateral veins in left ipocondrium and mesenteric site was also recognized, suggesting chronic splenic congestion. Moreover, accompanying report noted an accessory spleen of size 2 cm rear



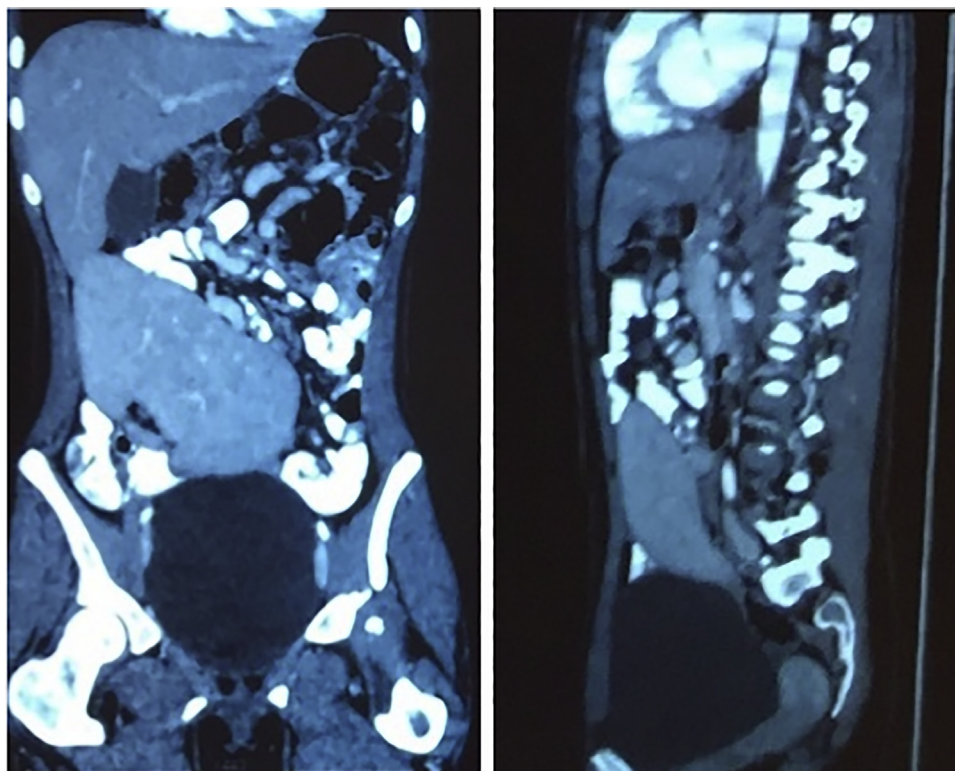
**Fig. 1.** Preoperative CT scan showed an enormous wandering spleen with dislocation of neighbor organs and an indeed bi-iliac diameter of 19 cm.

left splenic pole with abnormal long pedicle (Fig. 3). The spleen was not visualized in the left upper abdomen.

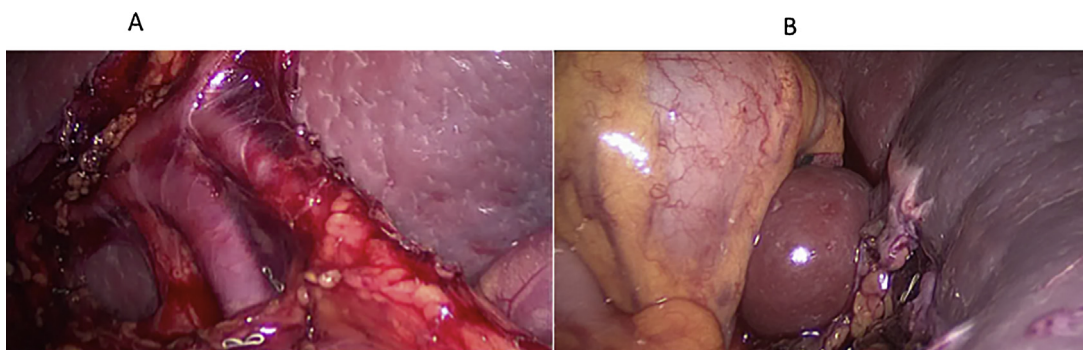
After a multidisciplinary board (surgeon, radiologist and hematologist) and a careful evaluation of the higher risk for complications (torsion, infarct and rupture) associated to the coexisting wandering and accessory spleen (on the splenic ileus), a laparoscopic splenectomy was performed. Patient's written consent was obtained.

### 2.1. Surgical technique

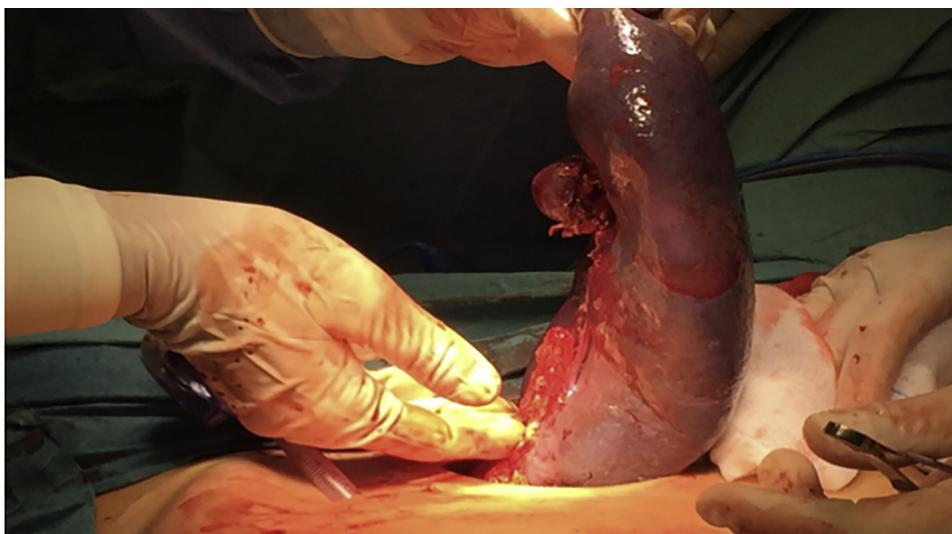
The patient was placed supine in Trendelenburg position. A lateral approach was performed: Hasson's-type trocar was inserted on the left anterior axillary line, and pneumoperitoneum was performed to an insufflation pressure of 12 mmHg. The two remaining trocars, 5 and 12 mm, were inserted under laparoscopic control. Laparoscopic exploration showed an enormous spleen with an extremely elongated winding vascular pedicle in mesogastrium, right side and right iliac fossa. Furthermore, accessory spleen on



**Fig. 2.** Preoperative CT scan showed an ectopic spleen displaced in right side and mesogastrium of size  $15 \text{ cm} \times 6 \text{ cm} \times 12 \text{ cm}$  with an abnormal wandering pedicle.



**Fig. 3.** A Image of the vascular pedicle B Image of the wandering spleen and accessory spleen.



**Fig. 4.** Removal of specimens en-bloc (spleen and accessory spleen) through Pfannestiel incision.

splenic hilum with an accessory pedicle was found. The abdominal exploration was negative for other findings.

The vascular peduncle was isolated near the splenic hilum and then we cut it with EndoGia after arterial and venous ligation with endoclips. Splenic artery was early ligated in order to reduce spleen volume. Spleen and accessory spleen were removed with Pfannenstiel incision (Figs. 4 and 5). Intraoperative blood loss was minimal.

Entire procedure was performed laparoscopically with an operative time of 118 min.

The patient's post-operative recovery was uneventful, and the patient was discharged on the 6th post-operative day with the indication to continue the therapy with low molecular weight heparin (LMWH) for 30 days. A triple vaccination against pneumococcus, meningococcus and Haemophilus influenzae were given.

The hematological parameters were within range. The histological examination of the surgical specimen confirmed the diagnosis of accessory spleen with hyperplasia of the red pulp.

### 3. Discussion

In our report we present a particular case in which a wandering spleen, an ectopic spleen and an accessory spleen occur simultaneously, and to our knowledge this is the first reported case.

Both the conditions represent developmental anomalies of the spleen, an accessory spleen is relatively common while a wandering spleen or polysplenia are rare.

An accessory spleen results from failure on the fusion between the multiple splenic primordias and the dorsal mesogastrium;

due to the rotation of the spleen during embryogenesis, accessory spleens are usually situated on the left side of the abdomen.

An abnormal fusion or foregut rotation of the dorsal mesogastrium during 5th and 6th week of development, results in an unusually long splenic pedicle and consequently in a wandering spleen [18–22].

The incomplete fixation of the spleen to the gastrosplenic and splenorenal ligaments allows to the change of spleen position in the abdomen, sometimes due to a long vascular pedicle spleen could, as in our case, shift to extra-anatomical positions.

Wandering spleen is a rare condition, associated to familial condition or parity [19]. Conversely to our cases, age at presentation may be 20–40 years and the most affected are multiparous females.

The absence or underdevelopment of ligamentous splenic apparatus results in a long pedicle which is predisposed to torsion [1–4]. This condition which increases with the weight of spleen [13] is reported in about 0.2–0–3% of patients affected by wandering spleen [11–17] and represents a possible complication in patients with accessory spleen who require splenectomy [23]. Both wandering and accessory spleen could be asymptomatic and sometimes are occasional autopsy findings.

Recurrent bouts and abdominal pain are due to short lasting ischemia caused by intermittent torsion-detorsion or resulted from direct mechanical irritation of surrounding organs [15–16]. The treatment of wandering spleen has changed over time [20–21] Studies of spleen physiology suggested that spleen should be preserved [25]. For this reason most physicians recommended splenopexy for treatment of wandering spleen especially in asymp-

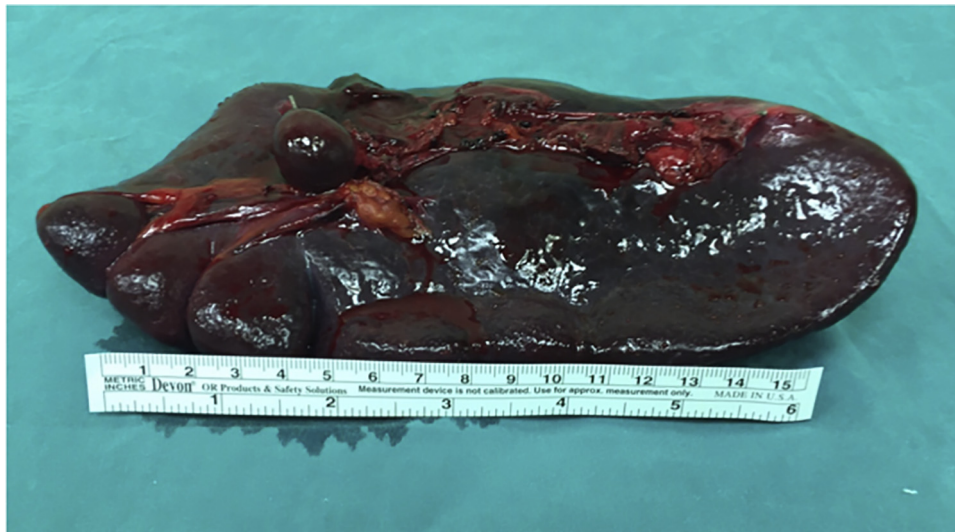

Fig. 5. Image of resected specimens.

omatic patients [26]. In the patient described here, splenopexy was possible for the symptoms referred by the patient and it was not technically feasible for the size of the spleen compared to the abdominal wall of the patient and for the presence of a simultaneous wandering ectopic spleen.

The introduction of medical technologies and the development of minimally invasive surgery [37–39] have revolutionized the clinical approach to spleen pathology including wandering spleen [27,28]. Since 1998 laparoscopy has represented the method of choice for the ultimate diagnosis of wandering spleen. In particular, laparoscopic splenectomy represents the gold standard for many elective conditions such as hereditary spherocytosis, major and intermediate thalassemia with secondary hypersplenism or severe anemia, sickle cell disease and refractory autoimmune hemolytic anemia [29–31].

However, massive splenomegaly represents a relative contraindication to the use of laparoscopy, even though good results have been reported also for patients with this condition.

Classification of splenomegaly is based on the Guidelines of the European Association of Endoscopic Surgeons (EAES) [32]. Massive splenomegaly is defined as spleen with a long axis >15 cm and weight of 600 g whereas “supramassive splenomegaly” is defined as spleen with a long axis >20 cm and weight of 1600 g.

Massive splenomegaly represents a challenge for laparoscopy, because of the reduced working space in the abdominal wall, the increased risk of bleeding due to abnormal collaterals, the major risk of injuries to enlarged veins and splenic capsule and, finally, the increased intraoperative time.

In view of the above, EAES recommended the use of hand-assisted laparoscopic splenectomy (HALS) in case of massive splenomegaly to avoid complications and conversion to open surgery [32]. Somasundaram et al. [33] demonstrated the feasibility and the effectiveness of laparoscopic splenectomy also in massive and supramassive spleen.

In the same study the authors underlined also the importance of surgical experience to avoid complications and conversion to open surgery. On the other hand, Zhou J and coworkers [34] identified appropriate positioning of ports, meticulous dissection, early ligation of the splenic artery to reduce splenic volume and perfect haemostasis as key factors to successfully complete cases of massive or supramassive splenomegaly laparoscopically. The use of some topical hemostatic devices, which are effective in traditional surgery, has recently been encouraged [35,36].

In the patient described here, an enormous wandering spleen extended itself from the stomach to the right ovary, being placed in a small crowded space that corresponded to all right semeiotic quadrants. This condition predisposes to ischemia and rupture of the spleen and dislocation of neighbour organs.

For these reasons in the treatment of the patient described here we have not used HALS as suggested by EAES guidelines [32] because HALS would have contributed to further occupy the already limited working space and would have reduced vision. It is of note that the bi-iliac diameter of the patient was 19 cm and the spleen was 15 × 6 × 12 cm, with an abnormal wandering pedicle (Fig. 1). Splenectomy was performed completely by laparoscopy.

This case shows that laparoscopic splenectomy is a safe and effective treatment of wandering massive splenomegaly. Surgical experience and technological devices are key for this kind of surgery. Limits in surgical skills or insufficient instrumentation in operation room have to be recognized for patients safety.

On the other hand sometimes *limits like fears are often just an illusion* [40].

#### 4. Conclusions

This case represents a simultaneous condition of wandering massive splenomegaly along with an ectopic wandering spleen treated completely by laparoscopy.

#### Conflicts of interest

The authors declare that they have no competing interests.

#### Funding source

Anything to declare.

#### Ethical approval

Ethical approval was not required for this case report by our institution.

#### Consent

“Written informed consent was obtained from the patient for publication of this case report and accompanying images. A copy

of the written consent is available for review by the Editor-in-Chief of this journal on request”.

Authors provide assurance that the manuscript does not contain identifying characteristics of patient and alterations do not distort scientific meaning of this case report.

#### Author contribution

AR conceived the study, participated in its design performed the operations and drafted the manuscript.

SD drafted the manuscript.

All authors have read and approved the final manuscript.

#### Guarantor

Professor Antonia Rizzuto is the Guarantor of the study. She conceived and conducted the study, had access to the data and controlled the decision to publish of the final manuscript previously approved by all authors.

#### References

- [1] S.W. Jackson, Melancholia and the waning of the humoral theory, *J. Hist. Med. Allied Sci.* 33 (1978) 367–376.
- [2] H. Meek, Of wandering wombs and wrongs of women: evolving conceptions of hysteria in the Age of Reason, *Engl. Stud. Can.* 35 (2009) 105–128.
- [3] E. Henoch, Patologia i terapia szczegolowa. Choroby przyrzeczne i w jamy brzusznej (Pathology and detailed therapy. Diseases of abdomen), *Redakcja Gazety Lekarskiej, Warsaw, 1874*, p. 220.
- [4] J. Dietl, We firdruja nca s iledziona. Zapalenie otrzewnej. S miernic i (Wandering Spleen. Peritonitis. Death), *Prz. Lek.* 2 (1863) 98–100.
- [5] M. Buehner, M.S. Baker, The wandering spleen. Collective review, *Surg. Gynecol. Obstet.* 175 (1992) 373–387.
- [6] K.B. Allen, G. Andrews, Pediatric wandering spleen – the case for splenectomy: review of 35 reported cases in literature, *J. Pediatr. Surg.* 24 (1989) 432–435.
- [7] S.A. Qasi, S.M. Mirza, A.A. Muhammad, M.H. Al Arrawi, Y.A. Al-Suhaibani, Wandering spleen, *Saudi J. Gastroenterol.* 10 (2004) 1–7.
- [8] G. Gayer, R. Zissin, S. Apter, E. Atar, O. Portnoy, Y. Itzchak, CT findings in congenital anomalies of the spleen, *Br. J. Radiol.* 74 (2001) 767–772.
- [9] D.C. Desai, A. Hebra, A.M. Davidoff, L. Schnauffer, Wandering spleen: a challenging diagnosis, *South. J. Med.* 90 (1997) 439–443.
- [10] C. Kaniklides, T. Wester, L. Olsen, Accessory wandering spleen associated with short pancreas, *Acta Radiol.* 40 (1999) 104–106.
- [11] K.L. Moore, T.V.N. Persaud, The digestive system, in: K.L. Moore, T.V.N. Persaud (Eds.), *The Developing Human, Clinically Oriented Embryology*, 6th ed., WB Saunders Co, Philadelphia, PA, 1998, pp. 271–302.
- [12] K.L. Moore, A.F. Dalley, Abdomen, in: K.L. Moore, A.F. Dalley (Eds.), *Clinically Oriented Anatomy*, 4th ed., Lippincott Williams & Wilkins, Philadelphia, PA, 1999, pp. 175–350.
- [13] C.L. Ho, Wandering spleen with chronic torsion in a patient with thalassaemia, *Singapore Med. J.* 55 (2014) e198–e200.
- [14] J.K. Clark, J. Gorman, M.H. Lee, B.C. Barbick, R.M. Marks, Dynamic MRI in the diagnosis and post surgical evaluation of wandering spleen, *J. Radiol. Case Rep.* 8 (2014) 15–22.
- [15] J. Gindrey, B. Piquard, Volvulus de rate ectopique, *Bull. Soc. Med. Afr. Noire Lang. Fr.* 11 (1966) 860–863.
- [16] M. Kapan, M. Gumus, A. Onder, H. Gumus, A wandering spleen presenting as an acute abdomen: case report, *J. Emerg. Med.* 43 (5) (2012) e303–e305, <http://dx.doi.org/10.1016/j.jemermed.2010.06.029>.
- [17] T. Satydas, N. Nasir, H.A. Bradpiece, Wandering spleen: case report and literature review, *J. R. Coll. Surg. Edinb.* 47 (2002) 512–514.
- [18] A. Sharma, G. Salerno, A torted wandering spleen: a case report, *J. Med. Case Rep.* 8 (2014) 133.
- [19] J.H.M. Dawson, N.G. Roberts, Management of the wandering spleen, *Aust. N. Z. J. Surg.* 64 (6) (1994) 441–444, <http://dx.doi.org/10.1111/j.1445-2197.1994.tb02249.x>.
- [20] M. Buehner, M.S. Baker, The wandering spleen. Collective review, *Surg. Gynecol. Obstet.* 175 (1992) 373–387.
- [21] N.A. Makhoul, K.H. Morsy, S. Ammar, R.A. Mohammed, H.A. Yousef, M.G. Mostafa, Wandering spleen in the pelvic region in adult man with symptoms of acute abdomen, *Arab J. Gastroenterol.* 17 (March (1)) (2016) 49–52.
- [22] L. Varga, P. Galfiova, M. Adamkov, L. Danisovic, S. Polak, E. Kubikova, S. Galbavy, Congenital anomalies of the spleen from an embryological point of view, *Med. Sci. Monit.* 15 (December (12)) (2009) RA269–RA276.
- [23] Y. Lam, K.K. Yuen, L.C. Chon, Acute Torsion of a wandering spleen, *Hong Kong Med. J.* 18 (April (2)) (2012) 160–162.
- [24] R.A. Agha, A.J. Fowler, A. Saetta, I. Barai, S. Rajmohan, D.P. Orgill, for the SCARE Group, The SCARE statement: consensus-based surgical case report guidelines, *Int. J. Surg.* 34 (October) (2016) 180–186.
- [25] D. Rydygier, Die Behandlung der Wandermilz durch splenopexis, *Arch. Klin. Chir.* 50 (1895) 880–886.
- [26] M.I. Montenovio, S. Ahad, B.K. Oelschlaeger, Laparoscopic splenectomy for wandering spleen: case report and review of the literature, *Surg. Laparosc. Endosc. Percutan. Tech.* 20 (October (5)) (2010) e182–e184.
- [27] F. Corcione, F. Pirozzi, G. Aragiusto, F. Galante, A. Sciuto, Laparoscopic splenectomy: experience of a single center in a series of 300 cases, *Surg. Endosc.* (2012) 1870–2876.
- [28] A.E. Park, G. Birgisson, M.J. Mastrangelo, M.J. Marcaccio, D.B. Witzke, Laparoscopic splenectomy: outcomes and lessons learned from over 200 cases, *Surgery* (2000) 660–667.
- [29] M. Rosen, F. Brody, R.M. Walsh, M. Tarnoff, J. Malm, J. Ponsky, Outcome of laparoscopic splenectomy based on hematologic indication, *Surg. Endosc.* (2002) 272–279.
- [30] F. Cordera, K.H. Long, D.M. Nagorney, E.K. McMurtry, C. Schleck, D. Ilstrup, J.H. Donohue, Open versus laparoscopic splenectomy for idiopathic thrombocytopenic purpura: clinical and economic analysis, *Surgery* (2003) 45–52.
- [31] Y.-N. Bai, H. Jiang, P. Prasoon, A meta-analysis of perioperative outcomes of laparoscopic splenectomy for hematological disorders, *World J. Surg.* (2012) 2349–2358.
- [32] B. Habermalz, S. Sauerland, G. Decker, et al., Laparoscopic splenectomy: the clinical practice guidelines of the European Association for Endoscopic Surgery (EAES), *Surg. Endosc.* (2008) 821–848.
- [33] S.K. Somasundaram, L. Massey, D. Gooch, J. Reed, D. Mizes, Laparoscopic splenectomy is emerging 'gold standard' treatment even for massive spleens, *Ann. R. Coll. Surg. Engl.* 9 (July) (2015) 1–4.
- [34] J. Zhou, Z. Wu, Y. Cai, Y. Wang, B. Peng, The feasibility and safety of laparoscopic splenectomy for massive splenomegaly: a comparative study, *J. Surg. Res.* (2011) e55–e60.
- [35] R. Vecchio, R. Catalano, F. Basile, C. Spataro, M. Caputo, E. Intagliata, Topical hemostasis in laparoscopic surgery, *G. Chir.* 37 (November–December (6)) (2016) 266–270.
- [36] G. Docimo, P. Limongelli, G. Conzo, S. Gili, A. Bosco, A. Rizzuto, V. Amoroso, S. Marsico, N. Leone, A. Esposito, C. Vitiello, L. Fei, D. Parmeggiani, L. Docimo, Axillary lymphadenectomy for breast cancer in elderly patients and fibrin glue, *BMC Surg.* 13 (Suppl. 2) (2013) S8, <http://dx.doi.org/10.1186/1471-2482-13-S2-S8>, Epub 2013 Oct 8.
- [37] A. Rizzuto, R. Serra, C. Mignogna, I. Palaia, F.U. Zittel, R. Sacco, Single incision laparoscopic cholecystectomy in geriatric patients, *Int. J. Surg.* 35 (November) (2016) 83–87.
- [38] A. Rizzuto, U. Lacamera, F.U. Zittel, R. Sacco, Single incision laparoscopic resection for diverticulitis, *Int. J. Surg.* 19 (July) (2015) 11–14.
- [39] S. Wu, H. Lai, J. Zhao, X. Deng, J. Wei, J. Liang, X. Mo, J. Chen, Y. Lin, Systematic review and meta-analysis of single-incision versus conventional multiport laparoscopic splenectomy, *J. Minim. Access Surg.* 14 (January–March (1)) (2018) 1–8.
- [40] Mark Vancil, For the Love of the Game- My Story by Michael Jordan, Crown, 1998, P 121.

#### Open Access

This article is published Open Access at [sciencedirect.com](https://www.sciencedirect.com). It is distributed under the [IJSCR Supplemental terms and conditions](#), which permits unrestricted non commercial use, distribution, and reproduction in any medium, provided the original authors and source are credited.