

Received: 2022.04.20

Accepted: 2022.05.27

Available online: 2022.06.09

Published: 2022.07.01

Can the Density of Mineralized Dental Tissues (Dentin and Enamel) Be Measured and Compared with 3D Cone Beam Computed Tomography in Cases of Ectodermal Dysplasia?

Authors' Contribution:
Study Design A
Data Collection B
Statistical Analysis C
Data Interpretation D
Manuscript Preparation E
Literature Search F
Funds Collection G

ABDEFG 1 **Yasemin Yavuz**
BF 2 **Ebru Akleyin**
BDF 3 **Mehmet Sinan Doğan**
BF 4 **Myroslav Goncharuk-Khomyn**
C 5 **Zeki Akkus**

1 Department of Restorative Dentistry, Faculty of Dentistry, Harran University, Sanliurfa, Turkey
2 Department of Pediatric Dentistry, Faculty of Dentistry, Dicle University, Diyarbakir, Turkey
3 Department of Pediatric Dentistry, Faculty of Dentistry, Harran University, Sanliurfa, Turkey
4 Department of Public Health and Humanitarian Disciplines, Uzhhorod National University, Uzhhorod, Ukraine
5 Department of Biostatistics, Faculty of Medicine, Dicle University, Diyarbakir, Turkey

Corresponding Author: Yasemin Yavuz, e-mail: yyavuz-21@hotmail.com

Financial support: None declared

Conflict of interest: None declared

Background: Since 3-dimensional cone beam computed tomography (CBCT) started to be used in dentistry, mineral density can now be examined with computer software from the data on the images obtained. Detailed and clear images at different slice intervals can be obtained with CBCT, and mineral density can be measured from the image data on a computer with a Hounsfield unit (HU) scale. In addition to the broad opportunities presented by CBCT, this feature has presented a wider perspective to researchers.

Material/Methods: In this study, the CBCT images obtained from patients with the genetic disorder of ectodermal dysplasia were compared with the images of a control group to determine differences in mineralization of the teeth and to show that these could be compared by measuring the mineral density of dentin and enamel tissues using the HU scale on data from CBCT images. This opens new opportunities for cognitive and implementation research.

Results: In the study, CBCT images of 14 ectodermal dysplasia and 14 control group cases previously obtained for various reasons were used. Mineral density measurements were made from 4 different regions of the teeth of the ectodermal dysplasia and control groups (incisor edge of the crown, the center buccal, cervicale line, and apex of the teeth), and the groups were compared.

Conclusions: The aim of this study was to provide a new overview of the feasibility and suitability of mineralization measurement of dentin and enamel dental tissues with CBCT in ectodermal dysplasia and control groups.

Keywords: **CBCT • Hounsfield Units • Mineral Density • Ectodermal Dysplasia**

Full-text PDF: <https://www.medscimonit.com/abstract/index/idArt/937003>

 2885

 1

 3

 29



Background

Enamel is the hardest and densest mineralized tissue of the human body. It has been reported that 96% by weight is mineralized material and the rest is composed of organic matter and water [1]. The mineral portion consists of hydroxyapatite crystals [2] with a diameter of about 5 μm , tightly bound together in prisms. The prisms are separated by a very thin layer of protein-based organic matrix [3,4].

Enamel prisms are perpendicular to the dentin-enamel junction and extend outward toward the tooth surface.

The analysis and density measurement of mineralized tissues are important. CBCT is an effective and non-destructive technique for measuring the mineralization and thickness of dentin and enamel, which can be used in genetic research.

CBCT software has many different useful accessory options for scientific research, one of which is the Hounsfield unit (HU) scale. This is a numerical scale developed by Godfrey Newbold Hounsfield in 1972, which can define the density of the images on X-rays, and on CBCT in particular. Quantitative assessment can be made of the density of bone and mineralized tissues using the HU scale in different patient groups, such as those with the genetic disorder of ectodermal dysplasia. In a CBCT scan, the HU is proportional to the degree of X-ray attenuation by the tissue, and is shown in gray scale. The condition of tissues, especially bone destruction, can be defined according to the HU scale. Each voxel has an HU unit between -1000 and +3000 [5-8].

Irregularities in tooth tissue development and mineralization were thought to be associated with the development and abnormalities of ectodermal dysplasia.

Ectodermal dysplasia is an uncommon, inherited, developmental disorder which affects 2 or more tissues developing from the ectoderm such as the hair, nails, skin, sweat glands, and teeth. It may be autosomal dominant, recessive, or X-chromosome transmitted. Characteristic physical features of ectodermal dysplasia patients are short, fine, and sparse hair, eyebrows, and eyelashes. When intraoral findings of the disease are evaluated, it is seen that both milk teeth and permanent dentition are affected. There may be a reduced number of teeth (oligodontia or hypodontia), and occasionally there are no teeth (anodontia). Conic shape disorders are frequently seen in the existing teeth. As a result of the absence of teeth or few teeth in the development of the jaw, the alveolar crest does not develop and there can be reduced vertical height [9-14].

Teeth, like bones, are hard tissues in the body with mineral content. The mineral content plays an important role in determining the properties of enamel and dentin tissue [15].

The ratio of mineral volume is positively related to the mechanical characteristics of tissues such as the bones and teeth. In other words, however low the mineral content of enamel is, the resistance and hardness of enamel will also be that low. It has been concluded that when there is a decrease in the mineral content and mechanical properties of enamel, this generally results in restoration failure [16].

Evaluation of enamel mineral density has been found to be helpful in the selection of the appropriate restorative treatment and materials to provide a long-lasting restoration and contributes to better quantitative evaluation of remineralization agents and the related mechanisms [15]. Despite the detailed examination of the morphology of teeth in ectodermal dysplasia (ED) cases, it was observed that the mineral density of the teeth was not evaluated in the studies.

Recent years, cone beam computed tomography (CBCT) has become one of the advanced imaging methods that is increasingly used in dentistry for diagnosis and treatment planning. CBCT is an advanced imaging method greatly facilitating the dentist in many areas such as orthodontics, orthognathic surgery, the implant planning process, evaluation of the alveolar bone, evaluation of pathological formations, diagnosis and treatment of craniomaxillofacial fractures, examination of the temporomandibular joint, measurement of dental and bone loss, dental age estimation, determination of the position of embedded teeth, and determination of the size of periapical lesions and damage to the bone tissue [17-19].

On images obtained with CBCT, there are no unwanted image distortions such as magnification and super-positioning, and therefore measurements of actual dimensions can be obtained separately from the images, and maxillofacial tissues can be examined 3-dimensionally at intervals of micron thickness in horizontal, frontal, and sagittal planes of the skull. The mineral density of maxillofacial tissues can be measured with the HU scale. CBCT provides information about healthy enamel and dentin, initial decay lesions, and affected dentin mineral density. This information can provide the basis for future studies of skin analysis and the efficacy of minimally invasive treatments of caries [20-22].

While density measurements can be made by processing CBCT DICOM image data with Mimics computer programs, density measurements can also be made with the benefit of the HU scale directly with CBCT devices.

The aim of this research was to determine utility of mineralization density measurements of dental enamel and dentin tissues with CBCT and the suitability of being able to make comparisons of cases with a developmental disorder such as ectodermal dysplasia with a control group to provide a general

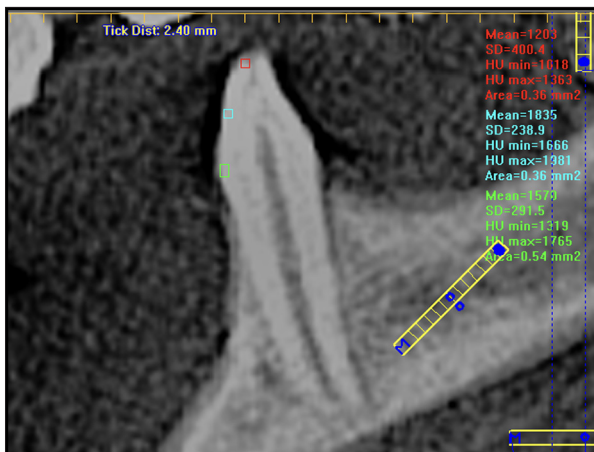


Figure 1. The measurement of the HU values on the CBCT image.

view of the differences in mineralization density in 3 separate areas of the tooth crown.

Material and Methods

The HU measurement values obtained by the CBCT device are shown in **Figure 1**. The measurement of HU values obtained from the teeth was performed with a CBCT device (Imaging Science International, Hatfield, USA) using the I-CAT Vision™ program.

In the 3D CBCT images of the patients, mineral density measurements were made with I-CAT Vision™ in an average area of 1 mm². Density measurements were made by determining an area of approximately 1 mm² from 3 different regions of the teeth (crown incisal edge/occlusal edge, buccal crown center and buccal crown cervical line) on the CBCT images, with scanning parameters of 12 KvP, 5 mA, and 8.9 s.

Each image was acquired by rotating the device 360 degrees around the patient. All acquired images were recorded in Digital Imaging and DICOM formats. Measurements were made at 3 separate times and the mean values of the measurements obtained were used.

Comparisons made the same number of teeth in both groups. All the images were from CBCT scans of 0.3 voxel dimensions.

The CBCT image data used were from ED cases (age range: 4-23 years old) who had CBCT taken for various reasons and from an age and gender-matched control group with images taken for orthodontic purposes.

CBCT images of 14 ectodermal dysplasia and 14 control group cases were used.

Since the age group of our ectodermal dysplasia cases who applied to our clinics ranged from 4-23, the control group was formed from the same age and same gender group.

The samples in the control group were selected from CBCT images taken for orthodontic purposes or in which the enamel dentin tissues were not affected by considering age and gender compatibility.

Mineral density measurements were made from the teeth in the ectodermal dysplasia cases (127 teeth) and the teeth in the same area in the control group (127 teeth). A total of 1778 enamel and dentin mineralization density were measured using the HU scale from 4 different regions of crown incisal edge/occlusal edge, buccal crown center, buccal crown cervical line and apex of the teeth on the CBCT images of the ectodermal dysplasia and control groups, and the groups were compared.

The enamel and dentin mineralization density values obtained from the 4 different regions of the teeth crowns were compared within and between the ED group and the control group. Measurements were taken from the same number of teeth in the same regions in the control group as there were in the ED cases.

Approval for the study was granted by the Ethics Committee of the Dentistry Faculty of Dicle University (investigator protocol number: 30.03.2022/2022-13).

Normal distribution of data was evaluated with the Shapiro-Wilk test. Since the data were normally distributed, we used the *t* test, which tests the mean of 2 independent groups, to compare the groups among themselves. Mean±standard deviation was used to represent descriptive statistics. According to the results of the analysis, the difference between groups was significant ($P<0.05$).

Results

The mineral density values obtained from 3 different regions (occlusal, buccal, and cervical) of the enamel in ED cases were found to be lower than the enamel mineral density values obtained from the control group ($P<0.05$).

A comparison of enamel mineralization density with HU scale data is shown in **Figure 2**.

In ED cases, the mineral density values obtained from dentin tissue in 4 different regions (occlusal, buccal, cervical, and apex) of the teeth were found to be higher than the dentin mineral density values obtained from the control group ($P<0.05$).

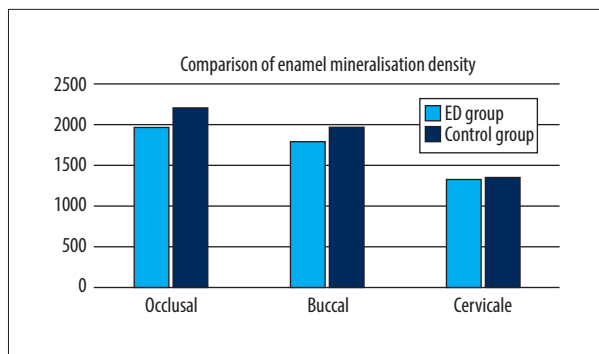


Figure 2. Comparison of Enamel Mineralization Density with HU scale value.

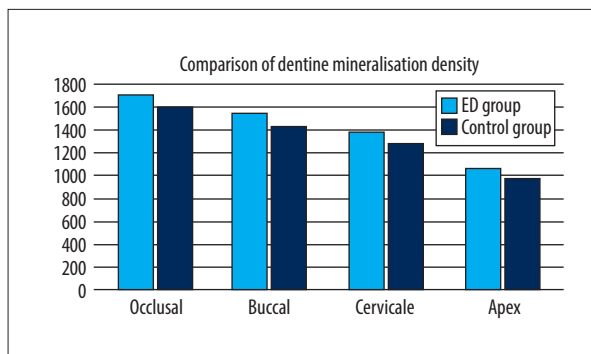


Figure 3. Comparison of dentine mineralization density with HU scale value.

Table 1. Comparison of HU scale and mineral density measurement averages in enamel and dentin in ED and Control groups.

(n=127)	Mineral density measurement averages in enamel and dentin by HU scale	
	Ectodermal dysplasia group mineral density average	Control group mineral density average
Enamel occlusal edge (n=127)	1980	2207
Enamel middle buccal (n=127)	1792	1971
Enamel cervicale (n=127)	1335	1347
Dentine occlusal edge (n=127)	1708	1589
Dentine middle buccal (n=127)	1544	1429
Dentine Cervicale (n=127)	1384	1268
Apex (n=127)	1063	978

A comparison of dentine mineralization density with HU scale data is shown in Figure 3.

The mean values of the enamel and dentin mineralization density obtained from 3 different regions of the teeth in the ED study and control group are shown in Table 1.

Discussion

Like bone tissue, which is well known in the medical field, teeth are one of the important hard tissues in the body. However, although the morphology of the teeth has been extensively studied, the mineral density of the teeth has not been adequately evaluated. In the field of dentistry, most of the dental mineral density studies have been micro-CT studies performed in vitro, and in vivo studies did not examine the differences between the mineral densities of the teeth [15,23,24].

CBCT is an effective and non-invasive diagnostic imaging modality in clinical dentistry, which produces highly accurate life-size images. Image-enhancing software such as Mimics can utilize

data from CBCT for 3-dimensional reconstruction and evaluation of the mineral density of calcified tooth structures [25]. However, it should be noted that due to the obligation to reduce the radiation dose given to the patient and the environment to the lowest level reasonably achievable, the dentist must comply with the ALARA principles (reasonably low).

Practical measures in dental practice for ALARA include field of view (for all types of imaging, including cone beam computed tomography), exposure time, and anatomy, as well as diagnostic confirmation and preservation. This principle means that even if it is a small dose, if there is no direct benefit from administering that dose, one should try to avoid it. To do this, 3 basic protective measures in radiation safety can be used: time, distance, and shielding.

Mineral density can be an essential criterion in the evaluation of genetic disorders such as ectodermal dysplasia, but study results showing the distribution of mineral density from crown to apex in intact teeth for different tooth types have not been reported. In the present study, measurements were taken of 3 regions of crown enamel and dentin density using CBCT and the HU scale.

The findings of the present study demonstrated that CBCT data have the potential to show mineral density changes in the dentin and enamel of ED patients, and that HU values were lower than in the control group.

The HU measurement values obtained from crown cervical line were lower than those obtained from the buccal center and the crown incisor/occlusal edge in both the ED group and the control group.

The study results showed that the extent to which dental tissues are affected in diseases affecting growth and development could be determined with values that can be measured on CBCT with the HU scale.

According to the results of this study, the HU values of the enamel and dentin density were lower in the cervical line than in the other measured regions, which agrees with previous studies showing that mineral density in teeth gradually was reduced toward the cemento-enamel junction [15].

Enamel and dentin mineral density measurements in all teeth tended to decrease gradually from the occlusal/incisors to the dentin-enamel junction. Dentin mineral density measurements in all teeth were lower than enamel mineral density measurements.

When the enamel and dentin mineral density HU scale measurement averages were compared in the ED and control groups, it showed a gradual decrease from the occlusal/cutting edge to the dentin-enamel junction. When enamel HU values in the ED and control groups were compared, ED enamel mineral density measurements were found to be lower, but when dentin HU values were compared, ED dentin mineral density measurements were higher. The differences were found to be statistically significant ($P<0.05$) (Table 1).

Mineral density distribution patterns are important in evaluating the mechanical properties of enamel and dentin [15]. Thus, in studies measuring to what extent dental enamel and dentin tissues are affected by a disease or genetic disorder that affects growth and development, the possibility is provided for new approaches that can be performed without damaging dental tissues.

It has been reported that hydroxyapatite crystals of the outer enamel are more concentrated than those in the inner enamel [26]. In addition, it has been reported that the volume ratio of mineralized tissue decreases and has a lower stiffness/elastic modulus in areas close to the enamel-dentin-enamel junction [27]. This explains why the HU values in cervical line enamel and dentin were lower than the buccal central and occlusal enamel and dentin HU values.

In the current study, the HU values of the enamel and dentin in the ED group were lower than those of the control group in all the evaluated regions.

The results of the present study showed a strong measurable correlation between the mineral density analyses performed with CBCT in the growth disorder of ectodermal dysplasia and in the control group.

CBCT is also considered useful when using teeth for personal identification, sex determination, and the event to which they have been exposed, in forensic cases where other tissues have decomposed underground [28].

The teeth arise from the interaction of 2 germ layers, the ectoderm and the mesoderm. The ectodermal tissue provides the enamel, while the mesodermal tissue provides the dentin [29].

When we compared the enamel mineralization densities obtained with the HU scale from 4 different regions of the crown cutting edge/occlusal edge, buccal crown center, and buccal crown cervical line in the ectodermal dysplasia and control groups, the enamel density values in the ectodermal dysplasia group were significantly higher than in the control group values in all regions ($P<0.05$). Development of tooth enamel occurs in the ectoderm germ layer [29]. It was thought that enamel density values were low in ED cases due to a developmental disorder in the ectoderm layer (Figure 2). This low density suggested that adhesive materials used for restorative purposes could cause problems in the tooth filling-cavity wall adhesions, and that dental fillings would not be long-lasting.

Dental dentin development takes place in the mesoderm germ layer, and interestingly, while dentin density values in ED cases were expected to be at normal values and equal to the control group, dentin HU values obtained from the ED groups were found to be higher than the dentin HU values obtained from the control groups. The high dentin values in the ED groups were seen as a subject to be investigated. HU scale values obtained were seen significantly higher than the control group dentin density values ($P<0.05$) (Figure 3).

To the best of our knowledge, this is the first study to have evaluated mineral density using 3D CBCT imaging in patients with ectodermal dysplasia compared with age- and sex-matched control group subjects. Therefore, the results of this preliminary study might be of value in contributing to current knowledge of ectodermal dysplasia and the evaluation of mineral density. However, although this study has demonstrated the value of CBCT in the evaluation of mineral density, this imaging method is not widely used by researchers.

This study and similar studies to be conducted in the future will provide researchers with new options and useful basic data for the early detection of caries and the early detection of caries risk, by measuring mineral density in enamel, dentin, and roots with an HU numerical standard.

Conclusions

The low enamel density values and statistically significant high dentin values in ED cases should be investigated in future multidisciplinary laboratory studies.

Also, the differences in enamel and dentin HU values in the ED and control groups suggested that further histological and chemical analysis studies should be performed in hard tissues such as other bones.

Low enamel density suggested that adhesive materials used for restorative purposes could cause problems in the tooth filling-cavity wall adhesions, and that dental fillings would not be long-lasting.

References:

1. Ten Cate R. Oral Histology: Development, structure, and function. 5th ed., Mosby 4th ed, Saint Louis; 1994
2. Eanes ED. Enamel apatite: Chemistry, structure and properties. *J Dent Res*. 1979;58(Spec Issue B):829-36
3. Weber DF. Sheath configurations in human cuspal enamel. *J Morphol*. 1973;141(4):479-89
4. Boyde A. Handbook of microscopic anatomy. V/6 Springer-Verlag. 1989;309-473
5. Razi T, Niknami M, Alavi Ghazani F. Relationship between Hounsfield unit in CT scan and Gray scale in CBCT. *J Dent Res Dent Clin Dent Prospects*. 2014;8(2):107-10
6. Mah P, Reeves TE, Mc David WD. Deriving Hounsfield units using grey levels in cone beam computed tomography. *Dentomaxillofac. Radiol*. 2010;39:323-35
7. Lamba R, Mc Gahan JP, Corwin MT, et al. CT Hounsfield numbers of soft tissues on unenhanced abdominal CT scans: Variability between two different manufacturers' MDCT scanners. *Am J Roentgenol*. 2014;203:1013-20
8. Yavuz I, Rizal MF, Kiswanjaya B. The possible usability of three-dimensional cone beam computed dental tomography in dental research. *Journal of Physics: Conference Series*. 2017;884 012041
9. Kocaeli H, Tanokor R, Yaltirk M, et al. Multidisciplinary approach to a patient with ectodermal dysplasia and suffering from severe osteomalasia: A case report. *Istanbul University Journal of Faculty of Dentistry*. 2010;44(1):27-32
10. Bhakta P, Barthunia B, Nigam H, Pawar P. Ectodermal dysplasia – a rare case report. *J Family Med Prim Care*. 2019;8(9):3054-56
11. Cantekin K, Delikan E. Dental treatment approach in pediatric patient with ectodermal dysplasia: A case report. *J Dent Fac Atatürk Uni*. 2014;24(3):413-17
12. Anboubia GM, Carmany EP, Natoli JL. The characterization of hypodontia, hypohidrosis, and hypotrichosis associated with X-linked hypohidrotic ectodermal dysplasia: A systematic review. *Am J Med Genet A*. 2020;182(4):831-41
13. Gonzaga LH, Amorim KP, Sesma N, Martin WC. Interdisciplinary rehabilitation of a patient with ectodermal dysplasia utilizing digital tools: A clinical report. *J Prosthet Dent*. 2021 [Online ahead of print]
14. Lamartine J. Towards a new classification of ectodermal dysplasias. *Clin Exp Dermatol*. 2003;28:351-55
15. Hayashi-Sakai S, Sakamoto M, Hayashi T, et al. Evaluation of permanent and primary enamel and dentin mineral density using micro-computed tomography. *Oral Radiol*. 2019;35(1):29-34
16. Farah RA, Swain MV, Drummond BK, et al. Mineral density of hypomineralised enamel. *J Dent*. 2010;38(1):50-58
17. Güller MT, Miloğlu Ö, Naralan ME. Evaluation of histopathological reports of neoplasms diagnosed with cone beam computed tomography. *Türkiye Klinikleri J Dental Sci*. 2021;27(3):372-80
18. Asif MK, Nambiar P, Mani SA, et al. Dental age estimation in Malaysian adults based on volumetric analysis of pulp/tooth ratio using CBCT data. *Leg Med (Tokyo)*. 2019;36:50-58
19. Park S, Wang DH, Zhang D, et al. Mechanical properties of human enamel as a function of age and location in the tooth. *J Mater Sci Mater Med*. 2008;19(6):2317-24
20. Sadyrin E, Swain M, Mitrin B, et al. Characterization of enamel and dentine about a white spot lesion: Mechanical properties, mineral density, microstructure and molecular composition. *Nanomaterials (Basel)*. 2020;10(9):1889
21. Tatlı U, Keleş B, Esen E, Öztunç H. Evaluation of unilateral condylar hyperplasia by cone-beam computed tomography: A report of two cases and review of the literature. *J Dent Fac Atatürk Uni*. 2010;20(3):198-204
22. Canger EM, Çelenk P. Evaluation of dental radiology in the world and Turkey. *Türkiye Klinikleri J Med Ethics*. 2016;24(2):60-66
23. Neves AA, Vargas DO, Santos TM, et al. Is the morphology and activity of the occlusal carious lesion related to the lesion progression stage? *Arch Oral Biol*. 2016;72:33-38
24. Alajaji NK, Bardwell D, Finkelman M, Ali A. Micro-CT evaluation of ceramic inlays: comparison of the marginal and internal fit of five and three axis CAM systems with a heat press technique. *J Esthet Restor Dent*. 2016;29:49-58
25. Asif MK, Nambiar P, Mani SA, et al. Dental age estimation employing CBCT scans enhanced with Mimics software: Comparison of two different approaches using pulp/tooth volumetric analysis. *J Forensic Leg Med*. 2018;54:53-61
26. Robinson C, Kirkham J, Shore RC. Revival: Dental enamel formation to destruction. ISBN 9781138558601. CRC Press. 2019

The high dentin HU values in the ED groups warrant further investigation.

With the development of CBCT technology, software programs for the measurement of HU have become very useful. The data obtained in this study may contribute to the scientific research of further studies related to mineral density measurement.

The difference in HU values obtained from the measurements in this study between the ED group and the control group shows that CBCT is a useful imaging method in comparison of mineral density.

One of the most important advantages is that CBCT HU values can be used to show whether or not the mineral density in different regions of the teeth is affected in various diseases and genetic disorders, without damaging the tissue.

Declaration of Figures' Authenticity

All figures submitted have been created by the authors, who confirm that the images are original with no duplication and have not been previously published in whole or in part.

27. Habelitz S, Marshall SJ, Marshall GW, Jr, Balooch M. Mechanical properties of human dental enamel on the nanometre scale. *Arch Oral Biol.* 2001;46:173-83
28. Şimşek HA, Gültekin T, Bilecenoğlu B, Atakan C. Sex determination from the maxillary sinus by cone beam computed tomography. *Türkiye Klinikleri. J Dental Sci.* 2021;27(3):364-71
29. Formation of Teeth. Chapter 1. Initial stages of formation. Available from: <https://pocketdentistry.com/1-formation-of-teeth/#:~:text=Teeth%20arise%20from%20the%20interaction,the%206th%20week%20after%20conception> [Last Accessed 21 April 2022]