


ORIGINAL ARTICLE

Long-term safety and efficacy of tenofovir disoproxil fumarate substitution for hepatitis B immunoglobulin following liver transplantation

Abhinav Vasudevan,*  Zaid S Ardalan,* Navera Ahmed,* Ross Apostolov,* Paul J Gow,* Adam G Testro,* Ed J Gane[†] and Peter W Angus*

*Liver Transplant Unit Victoria, Austin Health, Melbourne, Australia and [†]New Zealand Liver Transplant Unit, Auckland City Hospital, New Zealand

Key words

hepatitis B, liver transplant, Tenofovir.

Accepted for publication 27 July 2018.

Correspondence

Abhinav Vasudevan, Austin Health, 145 Studley Road, Heidelberg, Vic. 3084, Australia.
Email: abhinav.vasudevan@monash.edu

Declaration of conflict of interest: Ed Gane has been a member of the Advisory Board and on the Speakers' Bureau for Gilead Sciences.

Author contribution: All authors made substantial contributions to the conception or design of the work; or the acquisition, analysis, or interpretation of data for the work; or drafting the work or revising it critically for important intellectual content; and/or final approval of the version to be published. PA was involved in the concept design of the study, data interpretation, and critical revision of article. AV and ZA were involved in the data collection, analysis, drafting of the article, and critical revision. NA and RA were involved in data collection. AT, PG, and EG were involved in the critical revision of the article. All authors approved the article prior to submission.

Introduction

Antiviral prophylaxis to prevent recurrent hepatitis B virus (HBV) infection following liver transplantation for HBV-related acute liver failure, decompensated cirrhosis, or hepatocellular carcinoma has rapidly evolved over the past 20 years. In the era prior to prophylaxis, HBV recurrence in the graft was almost universal.^{1,2} The initial use of passive immunoprophylaxis with hepatitis B immunoglobulin (HBIg) reduced the rate of HBV recurrence to 23% over 12 months after transplantation.³ HBIg therapy was less effective when the pretransplant serum HBV DNA titer was high.⁴ In addition, long-term, high-dose HBIg has a number of disadvantages, including the high cost, inconvenient monthly parenteral administration, and local and systemic side effects.⁵

Abstract

Background and Aims: Limitations to the use of long-term Hepatitis B Immunoglobulin (HBIg) following liver transplantation for hepatitis B (HBV) have led to the substitution of HBIg with oral nucleos(t)ide analogue prophylaxis. We prospectively assessed the long-term safety and efficacy of switching to tenofovir disoproxil fumarate (TDF) from HBIg.

Methods: An open-label, multicenter switch study was conducted to evaluate the substitution of TDF for HBIg whilst continuing lamivudine (LAM) therapy in preventing the recurrence of HBV in patients who had been maintained as hepatitis B surface antigen (HBsAg)-negative posttransplantation for at least 12 months.

Results: Eighteen patients were enrolled (median age 66 years, range 42–78 years); 84% were male, and 78% on calcineurin inhibitors. Median time after transplantation was 14 years (range 5–19), and median duration of HBIg/LAM prior to the switch was 10 years (range 1–14). Median follow-up was 5 years (range 5–8). Of 18 patients, 16 (89%) remained HBsAg and HBV DNA negative at the end of follow-up. Two patients had re-emergence of HBsAg without a detectable HBV DNA and no clinical sequelae. Creatinine clearance significantly reduced (median 59 mL/min to 51 mL/min, $P = 0.03$), necessitating dose reduction of TDF in six (33%) participants, with two eventually ceasing TDF. One patient switched back to HBIg by choice. All patients who changed therapy maintained an undetectable HBsAg.

Conclusion: Substitution of HBIg with TDF in patients on LAM is well tolerated and effective for the long-term prevention of HBV recurrence posttransplantation. Renal dysfunction occurs frequently in the posttransplant setting and can require dose adjustment of TDF or change of therapy.

Graft recurrence rates reduced further through the addition of nucleoside analogue therapy to HBIg therapy. Initially, lamivudine (LAM) with HBIg was used with good short-term success and allowed a reduction in the dose of HBIg and switching to intramuscular administration while maintaining a low HBV recurrence rate.⁶ However, a systematic review suggested that HBV recurrence still occurred in approximately 6% of cases after 21 months on combination HBIg and LAM.⁷ Recurrence mainly affected patients with a high serum hepatitis B (HBV DNA) titer pretransplant and was often due to LAM-resistant HBV or discontinuation of either LAM or HBIg.⁸ As a result, HBIg was often continued indefinitely in patients on LAM prophylaxis.

The nucleos(t)ide analogues, entecavir or tenofovir, have negligible resistance rates and favorable tolerability and have largely replaced LAM in clinical use in the nontransplant setting.

The high barrier to resistance of the newer antivirals may make it possible to withdraw HBIg therapy after a finite duration and to continue oral antiviral therapy alone.

The finding that tenofovir disoproxil fumarate (TDF) is highly active against LAM-resistant viruses suggests that the combination of this drug with LAM may at least be as effective as traditional HBIg/LAM combination therapy. However, the need for additional LAM is questionable because no cases of tenofovir resistance have been identified in either treatment-naïve or nucleos(t)ide-experienced patients.⁹

Although tenofovir might be considered an ideal drug to use in patients with extensive LAM exposure, the long-term safety and efficacy of switching to long-term tenofovir-based therapy posttransplant is unknown. Furthermore, there is no consensus on the optimal duration of HBIg therapy prior to switching to oral antiviral prophylaxis, and the associated risks of late HBV recurrence following the switch to oral antiviral therapy are unclear. We therefore aimed to determine the long-term safety and efficacy of substituting TDF for HBIg in patients who remained hepatitis B surface antigen (HBsAg) negative after 12 months of HBIg and LAM therapy after liver transplantation.

Materials and methods

An open-label, multicenter switch study was performed to evaluate the safety and efficacy over a 5-year period of the switch to TDF plus LAM in patients who received a liver transplantation for HBV-related liver disease and initially received LAM/HBIg prophylaxis. Only patients who had been successfully maintained as HBsAg-negative and were negative on polymerase chain reaction (PCR) for HBV DNA for at least 12 months posttransplantation on combination HBIg and LAM were included.

Participant selection. Subjects had to be over 18 years to be enrolled in the study and had to have maintained stable renal function with a creatinine <150 µmol/L. Females of childbearing potential were required to agree to contraceptive use for the duration of the study medication. Exclusion criteria included lactating or pregnant females; a history of hypersensitivity to HBIg, LAM, or TDF; and fulminant hepatitis B and human immunodeficiency virus (HIV) seropositivity. Patients with pretransplant hepatitis C or hepatitis D coinfection were included. Patients who had received therapy with nephrotoxic drugs (e.g. aminoglycosides, amphotericin B, vancomycin, cidofovir, foscarnet, cisplatin) or competitors of renal excretion (e.g. probenecid) within 2 months prior to study screening were also excluded, as were patients who had used antiviral therapy with agents other than HBIg or LAM and demonstrated potential anti-HBV activity within the previous 3 months (e.g. adefovir dipivoxil, famciclovir, loboacavir, emtricitabine, entecavir, ganciclovir, adefovir, or others). Patients with pretransplant antiviral resistance were excluded.

Ethics approval. The trial was approved by the Austin Human Research Ethics Committee (H2010/03786). The trial was registered with the Australia and New Zealand Clinical Trials Registry (ACTRN12611001236987). Informed consent was obtained from each patient in the trial.

Medication regimen. Patients initially received 800 units of HBIg during the anhepatic phase on the day of transplantation, followed by 800 units intramuscularly daily for the first week, then 800 units twice weekly for weeks 2–4 and then monthly administration of 800 units, aiming to maintain hepBsAb >50 mIU/mL. LAM was commenced within the first 48 h after transplantation at 100 mg daily. At least 12 months after transplantation, patients who were successfully maintained on HBIg and LAM had HBIg substituted with 300 mg of TDF daily.

Follow-up. Patients were assessed every 4 weeks for the first 3 months after the substitution of HBIg with TDF and then every 12 weeks until the end of study. At each visit, routine blood tests, including a full blood examination, urea electrolyte creatinine, calcium, magnesium, phosphate, HBsAg, HBV DNA PCR, prothrombin time, and liver function tests, were performed. Subjects underwent a yearly bone mineral densitometry while on therapy. Biochemistry and bone mineral density (BMD) were assessed at the end of 5 years or at the time of cessation of tenofovir therapy, whichever occurred earlier.

Aim and study end-points. The study aimed to assess the 5-year efficacy, safety, and tolerability of TDF substitution for HBIg. The primary end-point was prevention of reinfection of the graft defined by the absence of HBsAg and HBV DNA in serum over 5 years.

The secondary end-points were development of adverse effects; a significant change in renal function, defined as serum creatinine >50 µmol/L or >25% above baseline; a decrease in phosphate by >25%; and a reduction in the femoral or vertebral t-score of >0.5. These were measured at the 5-year follow-up or, if tenofovir was discontinued earlier, the last measurement while on treatment.

Medication adherence was assessed at each clinical review, and patients were questioned regarding adverse effects related to medications. All adverse events were assessed and graded in severity by the study investigators to determine the need to stop or change medications.

Statistical analysis. Statistical analysis was performed using Prism. The Wilcoxon signed-rank test for non-parametric paired data was used to compare baseline and 5-year follow-up results for participants using a two-tail test, with $P < 0.05$ being considered significant.

Results

Eighteen patients were enrolled in the study. Table 1 details baseline demographic and clinical details at the time of switch to LAM/TDF therapy. The median baseline age was 60 years (range 37–73 years), with 84% being male; 22% were of Caucasian ethnicity. Hepatitis B e antigen (HBeAg) and HBV DNA measurement pretransplant were available in 14 and 15 patients, respectively, with 21% (3/14) being HBeAg positive. HBV DNA was not detectable in 73% (11/15) at the time of transplant. The median time since orthotopic liver transplantation was 14 years (range 5–19 years), and 72% were on a calcineurin inhibitor (CNI) at enrolment.

Table 1 Baseline characteristics at time of switch to tenofovir

Characteristic	Patients (n = 18)
Age	60 (37–73)
Gender	
Male n (%)	15 (84%)
Caucasian n (%)	4 (22%)
Asian n (%)	12 (67%)
Middle Eastern n (%)	1 (6%)
Pacific Islander	1 (6%)
Exsmoker (%)	5 (28%)
Pretransplant	
HBsAg + n (%)	13 (93%) [†]
HBsAb + n (%)	2 (20%) [‡]
HBeAg+ n (%)	3 (21%) [†]
HBV DNA detectable n (%)	4 (27%) [§]
Hepatocellular carcinoma	7 (44%)
Hepatitis D	2 (11%)
Time since transplant (years)	14 (5–19)
Time on HBIG/LAM (years)	10 (1–15)
Follow-up (years)	5 (5–8)
Calcineurin Inhibitor n (%)	13 (72%)

[†]HBsAg and HBeAg measurement was available for 14 patients

[‡]HBsAb measurement was available for 10 patients

[§]HBV DNA measurement was available for 15 patients

All values are median and range unless otherwise stated.

HBV, hepatitis B virus; LAM, lamivudine.

Hepatitis B recurrence. The results for all the patients at 5 years after the switch are summarized in Table 2. The primary end-point of being both HBV DNA and HBsAg undetectable was achieved in 89% of participants. No patient had hepatitis B surface antibody (HBsAb) levels above 10 IU/L following HBIG discontinuation at 1 year or the end of follow-up. Two patients (11%) experienced re-emergence of HBsAg 2 and 12 months after the commencement of tenofovir and cessation of HBIG. Both were males aged 56 and 61 years, and both had undetectable HBV DNA at time of transplant, but one was HBeAg positive, and one had a hepatoma at the time of transplant. Neither patient had identified hepatoma following transplantation. However, at the time of HBsAg re-emergence, HBV DNA remained undetected, and alanine aminotransferase (ALT) was unchanged in both cases. HBsAg levels were 1.01 and 13.9 IU/L at time of

recurrence. Both remained on tenofovir for the complete 5-year follow-up period and were persistently HBV DNA negative with unchanged ALT. There were no clinical sequelae associated with HBsAg re-emergence in these two patients. One patient eventually cleared HBsAg, while the other remained HBsAg positive at the end of the study.

Dose changes and renal function. Overall, there was an increase in creatinine from a baseline median of 104 µmol/L to 110 µmol/L at the end of follow-up ($P = 0.30$), with a significant reduction in creatinine clearance from a median of 59 mL/min at baseline to 51 mL/min ($P = 0.03$). Changes in creatinine clearance are shown in Figure 1. Dosing of TDF therapy and changes are summarized in Figure 2.

Almost all episodes of dose reduction or withdrawal were due to a reduction in renal function. Once-daily dosing of tenofovir was continued in most patients throughout the study (11/18, 61%). There were six (33%) patients who were changed to alternate-day dosing due to a reduction in creatinine clearance of 25% or more. Three of these patients eventually returned to daily dosing of TDF with dose reduction and withdrawal of CNI therapy. One patient was maintained on alternate-day dosing for tenofovir without HBsAg re-emergence. One patient was switched to entecavir 11 months after commencing tenofovir due to persistent renal impairment, which resolved with the change in therapy. The other patient elected to switch back to HBIG/LAM therapy after initially changing to a reduced dose of TDF. In all six patients in whom TDF doses were reduced, there was a return to baseline renal function over a period of 1–4 years. One patient developed a Fanconi's-like syndrome with persistent hypokalemia and hypophosphatemia 44 months after commencing tenofovir, which resolved after switching to entecavir monotherapy. In this patient, the drug was ceased without a trial of dose reduction. All three patients who ceased tenofovir remained HBsAg and HBV DNA negative despite the changes in therapy. Details of the patients who ceased TDF therapy are presented in Table 3.

Bone mineral density. Over the 5 years of follow-up, median femoral t-score reduced from -1.35 to -1.95, and median lumbar spine t-scores decreased from -0.5 to -1.5, although both these results were not statistically significant ($P = 0.21$ and 0.14, respectively). The median change in femoral and lumbar t-scores

Table 2 Comparison of parameters at baseline and 5 years post-TDF substitution for HBIG

Variable	Prior to TDF therapy	Five years post-TDF substitution	Change	P-value
HBV sAg negative (%)	100	89	11	0.48
HBV DNA negative (%)	100	100	0	1.00
ALT (U/L)	71 (18–368)	26 (11–85)	-45 (-283 to -7)	0.06
Creatinine (µmol/L)	104 (71–157)	110 (71–203)	2 (-34 to 90)	0.30
Creatinine clearance (mL/min)	59 (39–106)	51 (35–95)	-7 (-43 to 24)	0.03
Phosphate (mmol/L)	1.1 (0.67–1.44)	1.03 (0.77–1.43)	-0.04 (-0.52 to 0.36)	0.43
Vitamin D levels (nmol/L)	43.5 (22–66)	89 (13–175)	47 (4–120)	<0.01
t-score femur	-1.35 (-2.8 to -0.4)	-1.95 (-2.8 to -1.0)	0.1 (-0.1 to 2.6)	0.21
t-score lumbar spine	-0.5 (-2.6–1.3)	-1.5 (-3.3 to 0.2)	0.1 (10.6–1.5)	0.14

All values presented are the median, with range in brackets.

ALT, alanine transaminase; HBV, hepatitis B; ns, not statistically significant; TDF, tenofovir disoproxil fumarate.

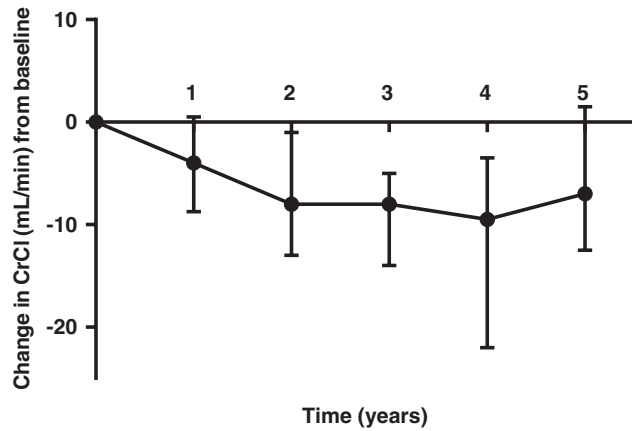


Figure 1 Median change in creatinine clearance over time from baseline.

is summarized in Figure 3. Three patients had a reduction in femoral t-scores, and two patients had a reduction in lumbar t-scores of >0.5. Five patients (27%) had a fall in phosphate levels of greater than 25%, with decreases ranging from 27% to 53%. There was no statistically significant change, however, in the median phosphate (1.10 mmol/L at baseline to 1.03 mmol/L at the end of follow-up, *P* = 0.43). There was no association between the decrease in BMD and change in serum phosphate levels. No fractures occurred during follow-up.

Discussion

Our study provides the longest prospective follow-up of the all-oral combination TDF/LAM as a substitute for long-term low-

dose HBIg therapy to prevent graft recurrence of hepatitis B in patients who are persistently HBsAg negative posttransplant. It demonstrates the durable efficacy in preventing HBV recurrence and general tolerability of the TDF/LAM combination in the posttransplant setting. There has been a recent cohort study of 77 patients assessing the use of either TDF or entecavir monotherapy following HBIg withdrawal in hepatitis B-infected individuals to prevent posttransplant recurrence, which had similarly low rates of recurrence of 9% over a median 6-year follow-up.¹⁰ This cohort had a greater proportion of Caucasians than our cohort, which primarily included people of Asian ethnicity, and our cohort was also older (median age 60 vs 53 years), with a longer period on HBIg (median 120 vs 60 months). Our cohort also utilized low-dose HBIg therapy. Our group of patients could be considered a relatively low-risk group for the re-emergence of hepatitis B given that the majority had a low viral load prior to transplantation, and all patients were on nucleotide analogues at the time of transplantation. Furthermore, they had remained stable on combination low-dose HBIg and LAM for a median of almost 10 years. There were two patients in whom the re-emergence of HBsAg was observed, but neither had detectable HBV DNA, and liver function remained stable on TDF, and thus, both could continue therapy without sequelae or change in management.

A concern with TDF use has been nephrotoxicity. This has been rare in studies on chronic hepatitis B and postliver transplant,^{9,11–14} although it has been a significant issue in some patients treated with TDF for HIV.¹⁵ One patient in our cohort had overt features of Fanconi’s syndrome, necessitating a change of therapy to entecavir, which underlines the potential for renal toxicity with TDF therapy in the posttransplant setting. The mechanism of renal dysfunction likely relates to proximal tubular injury from the active acyclic nucleoside phosphonate tenofovir

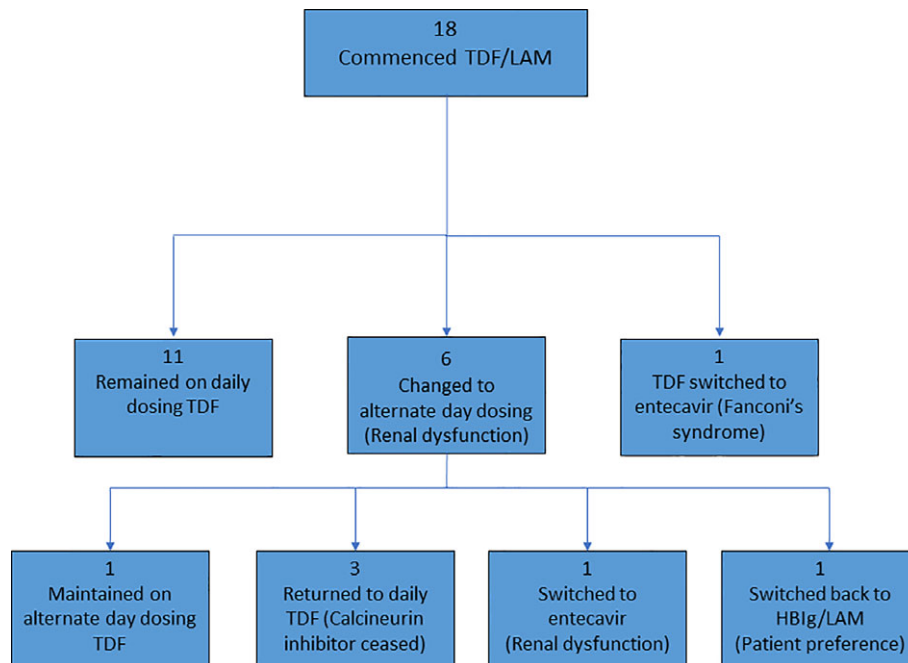


Figure 2 Changes in tenofovir dosing and antiviral treatment in cohort. TDF, tenofovir disoproxil fumarate; LAM, lamivudine.

Table 3 Patients who ceased tenofovir (TDF) therapy before 5 years of follow-up

Patient	Age at treatment commencement	Gender	Time on tenofovir (months)	Reason for ceasing therapy	Alternative therapy used	Improvement in side effect upon changing therapy	HBsAg status at the end of follow-up
1	66	Male	11	Renal impairment	Entecavir	Yes	Negative
2	69	Female	12	Patient choice (depression symptoms)	HBIg	Yes	Negative
3	56	Male	44	Fanconi's syndrome	Entecavir	Yes	Negative

TDF, tenofovir disoproxil fumarate.

(TFV).¹⁶ Of note, our study also showed a high rate of renal dysfunction with therapy, requiring either dose adjustment of TDF or CNI or cessation of therapy. Over 30% of patients required dose reduction of TDF, and one of these patients eventually required a change in therapy to entecavir. None of these subjects had a viral breakthrough despite dose reductions or change in therapy.

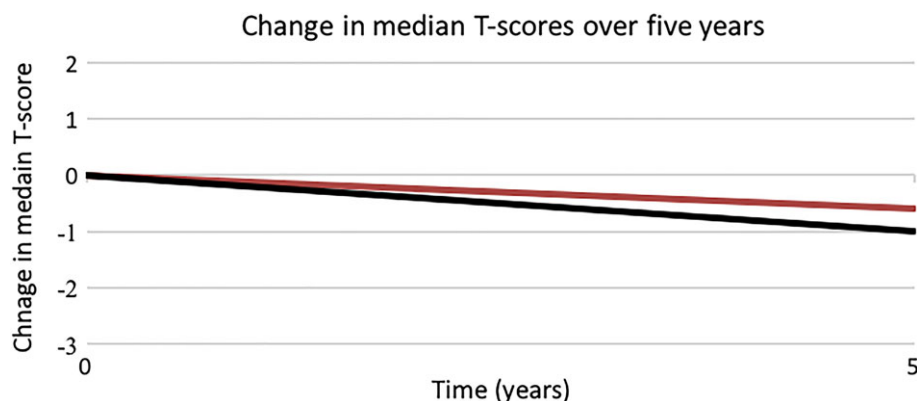
The high rates of renal dysfunction may partially be explained by more known risk factors for renal dysfunction in the affected subjects,^{17,18} such as older age (median 64 years), a lower baseline creatinine clearance compared to the rest of the cohort (48.5 $\mu\text{mol/L}$ vs 73 $\mu\text{mol/L}$), concomitant CNI use (50%), diabetes mellitus (50%), and hypertension (67%). The proportion of renal dysfunction attributable to TDF alone is unable to be assessed by our study given that other nephrotoxic therapies were adjusted or ceased following the identification of renal dysfunction. However, the fact that there was an improvement in renal dysfunction in most patients following dose reduction of TDF suggests the drug played some role. This may also be supported by the fact that the cohort study by Manini *et al.* suggested that lower rates of renal dysfunction on TDF and prespecified dose adjustments were utilized in their cohort but not in our cohort.¹⁰ The improvement in renal dysfunction following dose reduction of TDF is similar to a previous report on chronic hepatitis B by Fung *et al.*, where 67% of renal dysfunction was reversed with dose adjustment of TDF.¹⁹ Higher plasma levels of TFV have been associated with an increase in serum creatinine, and this may explain the dose-dependent nature of renal dysfunction observed in this cohort.²⁰

Our finding that substitution of TDF/LAM for HBIg/LAM therapy may be associated with a significant risk of nephrotoxicity

suggests that a switch to monotherapy with entecavir may be preferable in this setting as this drug has not been shown to promote renal injury posttransplant.²¹ Another possible choice is the novel agent tenofovir alafenamide (TAF), an alternative prodrug of TFV that can be administered at a much lower TFV equivalent oral dose, thereby reducing renal and systemic exposure to TFV.²² However, further clinical studies are needed to confirm the safety of TAF in the posttransplant setting.

There was no significant change in t-scores during our study. This was an important finding as longer-term follow-up studies of tenofovir in HIV populations have shown a reduction in BMD with long-term therapy.^{23–25} There are several factors that may have influenced these results, including an increase in vitamin D levels over the follow-up period (likely due to vitamin D supplementation) and a reduction in the proportion using corticosteroid therapy (from 55 to 28%), which may have potentially masked a deleterious effect of TDF on BMD. Nonetheless, the clinical effects of TDF on BMD in our study appeared to be minimal despite the high-risk nature of our cohort. We did not find a significant correlation between serum phosphate and bone density changes in the cohort. Interestingly, Manini *et al.* did find a reduction in serum phosphate for patients switched from LAM with or without adefovir to TDF, but BMD was not measured. Larger studies of BMD are needed to further clarify the effects of TDF on bone density in the posttransplant setting.

The limitations of our study include the small size of the cohort used and also the fact that treatment has evolved in this field such that use of HBIg in patients with low levels of viremia at the time of transplant has been suggested to not be necessary when using third-generation nucleo(s)tides.²⁶ However, our study was more focused on patients who are still on HBIg therapy, are

**Figure 3** Median change in lumbar and femoral over 5 years following switch to tenofovir. (—) Femur, and (—) spine.

stable and has the ability to withdraw treatment. Other studies suggest that LAM would not be needed in addition to TDF,^{27–29} but this could not be evaluated in our study given that all patients were on combination TDF/LAM. The major advantage of our study design is the prospective nature of follow-up, which allowed for the identification of the renal and bone effects of therapy.

In conclusion, long-term effective, safe, and relatively cost-effective antiviral prophylaxis is needed postliver transplantation to prevent hepatitis B recurrence in the graft. Substitution of HBIG with TDF in selected HBsAg-negative patients is efficacious at preventing HBV recurrence, with good tolerability and few side effects after 5 years of follow-up. The major concern with TDF appears to be renal dysfunction, especially given the common use of other nephrotoxic agents in the posttransplant setting and the relatively high frequency of concomitant risk factors for renal dysfunction. Renal dose adjustment of TDF did not reduce its efficacy in our cohort, and renal function improved in most subjects in whom this was undertaken.

This study does not answer the question of whether the addition of LAM to TDF adds any benefit in preventing late HBV recurrence post-HBIG withdrawal. Recently, TAF was approved for the treatment of patients with chronic HBV infection by the Food and Drug Administration.³⁰ TAF is a liver-targeting phosphonamide prodrug of TFV, with limited systemic exposure. The possible reduction in adverse effects on bone density and renal function because of this drug would be advantageous in patient populations at risk, including liver transplant recipients. An ongoing study is assessing the safety and efficacy of TAF monotherapy as antiviral prophylaxis following transplantation for HBV.³¹ Until then, for most patients, TDF plus LAM remains a safe and effective therapy in preventing the recurrence of HBV in the posttransplant setting.

Acknowledgment

Gilead supplied the tenofovir disoproxil fumarate used for this study. No external funding received.

References

- O'Grady JG, Smith HM, Davies SE *et al.* Hepatitis B virus reinfection after orthotopic liver transplantation. Serological and clinical implications. *J. Hepatol.* 1992; **14**: 104–11.
- Freeman RB, Sanchez H, Lewis WD *et al.* Serologic and DNA follow-up data from HBsAg-positive patients treated with orthotopic liver transplantation. *Transplantation.* 1991; **51**: 793–7.
- Samuel D, Bismuth A, Mathieu D *et al.* Passive immunoprophylaxis after liver transplantation in HBsAg-positive patients. *Lancet.* 1991; **337**: 813–5.
- Samuel D, Muller R, Alexander G *et al.* Liver transplantation in European patients with the hepatitis B surface antigen. *N. Engl. J. Med.* 1993; **329**: 1842–7.
- Cholongitas E, Papatheodoridis GV. Review of the pharmacological management of hepatitis B viral infection before and after liver transplantation. *World J. Gastroenterol.* 2013; **19**: 9189–97.
- Angus PW, McCaughan GW, Gane EJ, Crawford DH, Harley H. Combination low-dose hepatitis B immune globulin and lamivudine therapy provides effective prophylaxis against posttransplantation hepatitis B. *Liver Transpl.* 2000; **6**: 429–33.
- Cholongitas E, Goulis J, Akriviadis E, Papatheodoridis GV. Hepatitis B immunoglobulin and/or nucleos(t)ide analogues for prophylaxis against hepatitis b virus recurrence after liver transplantation: a systematic review. *Liver Transpl.* 2011; **17**: 1176–90.
- Mutimer D, Pillay D, Dragon E *et al.* High pre-treatment serum hepatitis B virus titre predicts failure of lamivudine prophylaxis and graft reinfection after liver transplantation. *J. Hepatol.* 1999; **30**: 715–21.
- Fernandez I, Loinaz C, Hernandez O *et al.* Tenofovir/entecavir monotherapy after hepatitis B immunoglobulin withdrawal is safe and effective in the prevention of hepatitis B in liver transplant recipients. *Transpl. Infect. Dis.* 2015; **17**: 695–701.
- Manini MA, Whitehouse G, Bruce M *et al.* Entecavir or tenofovir monotherapy prevents HBV recurrence in liver transplant recipients: A 5-year follow-up study after hepatitis B immunoglobulin withdrawal. *Dig. Liver Dis.* 2018.
- Cholongitas E, Vasiliadis T, Antoniadis N, Goulis I, Papanikolaou V, Akriviadis E. Hepatitis B prophylaxis post liver transplantation with newer nucleos(t)ide analogues after hepatitis B immunoglobulin discontinuation. *Transpl. Infect. Dis.* 2012; **14**: 479–87.
- Wesdorp DJ, Knoester M, Braat AE *et al.* Nucleoside plus nucleotide analogs and cessation of hepatitis B immunoglobulin after liver transplantation in chronic hepatitis B is safe and effective. *J. Clin. Virol.* 2013; **58**: 67–73.
- Saab S, Desai S, Tsoai D *et al.* Posttransplantation hepatitis B prophylaxis with combination oral nucleoside and nucleotide analog therapy. *Am. J. Transplant.* 2011; **11**: 511–7.
- Stravitz RT, Shiffman ML, Kimmel M *et al.* Substitution of tenofovir/emtricitabine for Hepatitis B immune globulin prevents recurrence of Hepatitis B after liver transplantation. *Liver Int.* 2012; **32**: 1138–45.
- Hall AM, Hendry BM, Nitsch D, Connolly JO. Tenofovir-associated kidney toxicity in HIV-infected patients: a review of the evidence. *Am. J. Kidney Dis.* 2011; **57**: 773–80.
- Fontana RJ. Side effects of long-term oral antiviral therapy for hepatitis B. *Hepatology.* 2009; **49**(5 Suppl): S185–95.
- Coppolino G, Simeoni M, Summaria C *et al.* The case of chronic hepatitis B treatment with tenofovir: an update for nephrologists. *J. Nephrol.* 2015; **28**: 393–402.
- Tsai MC, Chen CH, Tseng PL *et al.* Comparison of renal safety and efficacy of telbivudine, entecavir and tenofovir treatment in chronic hepatitis B patients: real world experience. *Clin. Microbiol. Infect.* 2015; **22**: 95.e1–95.e7.
- Fung S, Kwan P, Fabri M *et al.* Randomized comparison of tenofovir disoproxil fumarate vs emtricitabine and tenofovir disoproxil fumarate in patients with lamivudine-resistant chronic hepatitis B. *Gastroenterology.* 2014; **146**: 980–8.
- Tong L, Phan TK, Robinson KL *et al.* Effects of human immunodeficiency virus protease inhibitors on the intestinal absorption of tenofovir disoproxil fumarate in vitro. *Antimicrob. Agents Chemother.* 2007; **51**: 3498–504.
- Kamar N, Milioto O, Alric L *et al.* Entecavir therapy for adefovir-resistant hepatitis B virus infection in kidney and liver allograft recipients. *Transplantation.* 2008; **86**: 611–4.
- Ray AS, Fordyce MW, Hitchcock MJ. Tenofovir alafenamide: A novel prodrug of tenofovir for the treatment of Human Immunodeficiency Virus. *Antiviral Res.* 2016; **125**: 63–70.
- Stellbrink HJ, Orkin C, Arribas JR *et al.* Comparison of changes in bone density and turnover with abacavir-lamivudine versus tenofovir-emtricitabine in HIV-infected adults: 48-week results from the ASSERT study. *Clin. Infect. Dis.* 2010; **51**: 963–72.
- Grund B, Peng G, Gibert CL *et al.*, INSIGHT SMART Body Composition Substudy Group. Continuous antiretroviral therapy decreases bone mineral density. *AIDS.* 2009; **23**: 1519–29.
- Gallant JE, Staszewski S, Pozniak AL *et al.*, 903 Study Group. Efficacy and safety of tenofovir DF vs stavudine in combination therapy

- in antiretroviral-naïve patients: a 3-year randomized trial. *JAMA*. 2004; **292**: 191–201.
- 26 Teperman LW, Poordad F, Bzowej N *et al.* Randomized trial of emtricitabine/tenofovir disoproxil fumarate after hepatitis B immunoglobulin withdrawal after liver transplantation. *Liver Transpl*. 2013; **19**: 594–601.
- 27 Fung J, Wong T, Chok K *et al.* Long-term outcomes of entecavir monotherapy for chronic hepatitis B after liver transplantation: Results up to 8 years. *Hepatology*. 2017; **66**: 1036–44.
- 28 Radhakrishnan K, Chi A, Quan DJ, Roberts JP, Terrault NA. Short Course of Postoperative Hepatitis B Immunoglobulin Plus Antivirals Prevents Reinfection of Liver Transplant Recipients. *Transplantation*. 2017; **101**: 2079–82.
- 29 Wadhawan M, Gupta S, Goyal N, Taneja S, Kumar A. Living related liver transplantation for hepatitis B-related liver disease without hepatitis B immune globulin prophylaxis. *Liver Transpl*. 2013; **19**: 1030–5.
- 30 Vemlidy NDA 208464 Approval Letter, January 11 2016. Accessed 21 October 2016. Available from URL: http://www.accessdata.fda.gov/drugsatfda_docs/appletter/2016/208464Orig1s000ltr.pdf
- 31 Efficacy and Safety of Tenofovir Alafenamide (TAF) Versus Tenofovir Disoproxil Fumarate (TDF)-Containing Regimens in Participants With Chronic Hepatitis B Virus (HBV) Infection and Stage 2 or Greater Chronic Kidney Disease Who Have Received a Liver Transplant [Internet], 2016.