

Oncology

Infected retroperitoneal fat necrosis after laparoscopic partial nephrectomy

Daniel Nethala^{*}, Wayland J. Wu, Preeya K. Mistry, Lee Richstone

Department of Urology, Smith Institute for Urology, Hofstra Northwell School of Medicine, Lake Success NY, USA



ARTICLE INFO

Article history:

Received 14 December 2017

Accepted 17 January 2018

Available online 3 February 2018

Keywords:

Infection

Retroperitoneal

Fat necrosis

Partial nephrectomy

1. Introduction

Fat necrosis (FN) is a common surgical complication after breast and plastic surgery procedures involving reconstruction and tissue flaps with an incidence reported ranging from 10 to 39%.¹ Histologically, FN is described as a focus of lipid-laden macrophages and chronic inflammation with a foreign body giant cell reaction.² FN in breasts has a variable clinical presentation that can range from a tender mass with skin retraction to a palpable firmness, both of which can be concerning for malignancy.

In the retroperitoneum, FN is classically associated with the sequela of acute pancreatitis. In the absence of pancreatitis, FN in the retroperitoneum is exceedingly rare.^{3–5} Herein we present a case of infected retroperitoneal FN after a laparoscopic partial nephrectomy in a patient with an ileal conduit (IC).

2. Case presentation

A 69-year-old male with a history of bladder cancer status post robotic radical cystectomy and intracorporeal IC underwent a successful laparoscopic partial nephrectomy for a centrally located

renal mass (Fig. 1). Intraoperatively, the surgery was notable for entrance into the collecting system to completely resect the tumor. The collecting system was closed during renorrhaphy and a drain was left in place. His postoperative course was uneventful; the drain was removed after output was minimal and he was subsequently discharged on postoperative day (POD) four. On POD six, he presented to the emergency department with worsening right flank pain and subjective fevers of 103° Fahrenheit. He denied abdominal pain, abdominal distension, obstipation, constipation, diarrhea, changes to his wound, dyspnea, cough, chest pain, or lower leg swelling, his physical examination was unremarkable with no evidence of drainage or erythema from his incisions, peritoneal signs, or costovertebral tenderness. Computed tomogram (CT) of the abdomen and pelvis demonstrated post-surgical findings without intra-abdominal pathology. He was admitted to the hospital for treatment of presumed pyelonephritis given his history and discharged on oral antibiotics after he defervesced. After discharge from the hospital, the patient's outpatient course was complicated by intermittent low-grade fevers and general malaise. Nearly two months following surgery, he became febrile with worsening right flank pain. On exam, he was noted to have a palpable, firm, mildly tender mass located in the right upper quadrant extending to the ipsilateral flank. The remainder of his abdominal exam was unremarkable. Another CT scan showed extensive inflammatory changes with mass effect on the kidney (Fig. 2A). The previously noted fat stranding had now coalesced into a focal area of necrosis. Given there was no other source of infection, interventional radiology (IR) was consulted for percutaneous aspiration. During the procedure, 150 mL of liquefied yellow fat was aspirated (Fig. 2B). A pigtail drain was left in the retroperitoneum and the fluid was sent for culture. After the drainage, the patient felt immensely improved, his flank pain resolved, no longer felt malaise, and he did not experience any more fevers. *E. coli* was ultimately found in the retroperitoneal collection and his antibiotics were adjusted accordingly. Output from the drain decreased, and the drain was ultimately removed once tube-study revealed resolution of cavity.

3. Discussion

FN is commonly seen as a post-surgical complication after

^{*} Corresponding author. Smith Institute for Urology, Hofstra Northwell School of Medicine, 450 Lakeville Road, Suite M41, 11042 Lake Success, NY, USA.

E-mail address: dnethala@northwell.edu (D. Nethala).

Abbreviations

FN	Fat Necrosis
IC	Ileal Conduit
CT	Computer tomogram
MRI	Magnetic resonance imaging
POD	Post-operative day
IR	Interventional Radiology

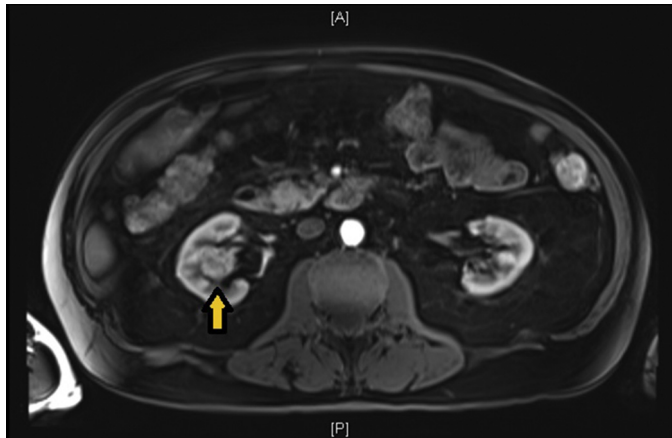


Fig. 1. Preoperative MRI Abdomen and Pelvis with contrast. Right sided central renal mass seen in the axial view.

plastic and breast surgery and is thought to be caused by trauma and ischemia,¹ while FN in the retroperitoneum commonly occurs as a sequelae of pancreatitis. While common in the setting of pancreatitis, retroperitoneal FN in the absence of pancreatitis is rare with a total of 5 cases reported in the literature,^{3–5} with this case representing the 6th (Table 1).

In the literature, retroperitoneal FN in the absence of pancreatitis is correlated with infectious, endocrinological, idiopathic, and malignant etiologies. In the small sample size of cases, there seems to be a predominance of males presenting with this disease. In 2/5 cases, infectious etiologies were thought to be directly related to causing the disease while 1/5 cases were thought to be correlated to a renal mass by unknown mechanisms. The firm consistency and mass effect of FN is illustrated by the 3 patient case series by Ross and Prout wherein FN caused obstructive uropathy requiring surgery in all patients.⁵

In the case presented, the infected retroperitoneal FN may have occurred secondary to exposure of infected urine. During the surgery, controlled transection of the urinary tract to excise the tumor was necessary. Given the patient's long history of having an IC, bacteriuria was likely present. Perhaps the small amount of urine that leaked precipitated his infection. No other source could be surmised especially since there was no evidence of bowel injury. Perhaps a therapeutic course of antibiotics instead of perioperative surgical prophylaxis may have prevented this complication by suppressing the urinary bacterial load.

4. Conclusion

Retroperitoneal FN in the absence of pancreatitis is a rare entity. This diagnosis should be entertained in patients with a history of chronic bacteriuria. Early interval imaging may be warranted to

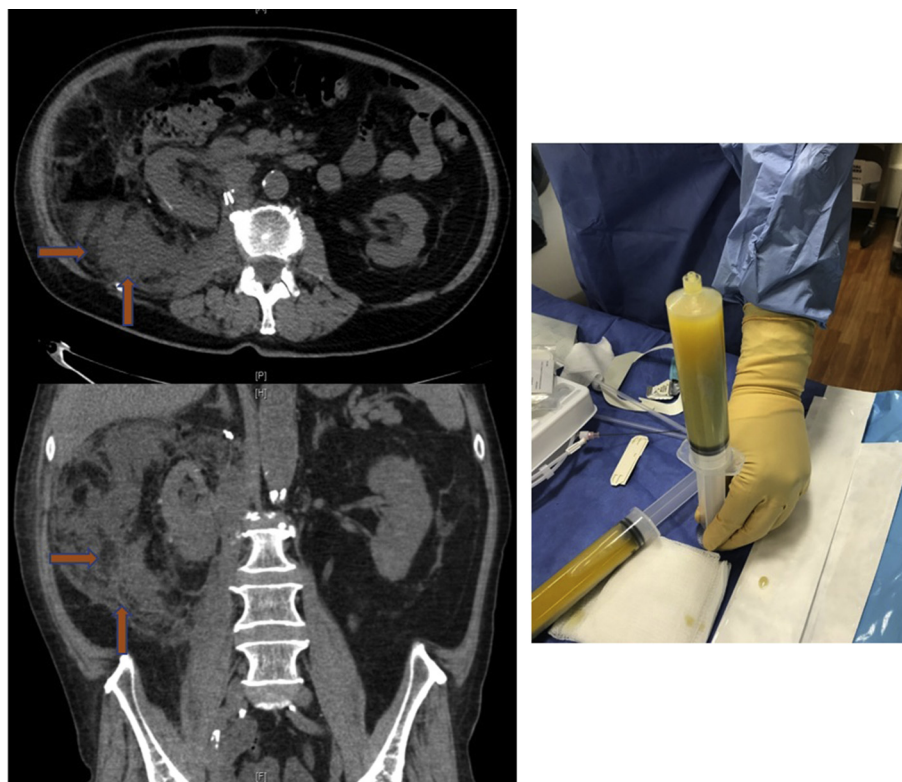


Fig. 2. A—CT scan from 2nd admission. CT abdomen non contrast. Arrows indicated coalescing fat necrosis surrounding the right kidney. Top Axial view, Bottom Coronal view. 2B—Aspirated material from IR percutaneous drainage.

Table 1
Literature Review of Cases of Retroperitoneal FN in the absence of pancreatitis.

Author/year	Demographics	Associated disease/surgery	Presentation	Treatment of FN & complications
Present case 2017	69 y/o Caucasian male	Right renal mass/Laparoscopic partial nephrectomy	Palpable RUQ/flank mass, fevers	Antibiotics/IR pigtail drainage
Amblee & Ganesh 2016 ³	33 y/o African American female	Cushing syndrome/ Adrenalectomy	Extreme weight loss after surgery	Exploratory laparotomy
Yang & Lee ⁴ 1996	61 y/o male	Right renal mass	Left sided lower abdominal pain	Excision during radical nephrectomy and colostomy closure
Ross & Prout ⁵ 1976	31 y/o Caucasian female	Groin and ischioirectal abscesses	Fevers, persistent abdominal pain, bilateral ureteral obstruction	Bilateral nephrostomies, and eventual left nephrectomy and right ureterolysis
	34 y/o Caucasian male	Ischioirectal abscess, sepsis	Back pain, bilateral obstructive uropathy	Bilateral ureterolysis, drainage of postop abscesses
	76 y/o Caucasian male	None	Lower back pain, Left mid-distal ureteral obstruction	Left nephroureterectomy

assess for phlegmon to abscess transition and prompt percutaneous drainage should be performed to minimize morbidity.

Funding

This research did not receive any specific grant from funding agencies in the public, commercial, or not-for-profit sectors.

References

1. Wagner IJ, Tong WM, Halvorson EG. A classification system for fat necrosis in autologous breast reconstruction. *Ann Plast Surg.* 2013;70(5):553–556.
2. Kumar V, et al. *Robbins basic Pathology.* Philadelphia, PA: Elsevier/Saunders.; 2013:1. online resource (xii, 910 p.).
3. Amblee A, Ganesh M. Retroperitoneal fat necrosis in a patient with extensive weight loss after adrenalectomy for ACTH-independent cushing syndrome: a case report and Review of the literature. *AACE Clin Case Rep.* 2016;2(4): e316–e320.
4. Yang MC, Lee WJ. Extensive intra-abdominal-retroperitoneal fat necrosis in a patient with renal cell carcinoma. *J Formos Med Assoc.* 1996;95(9):719–721.
5. Ross JS, Prout Jr GR. Retroperitoneal fat necrosis producing ureteral obstruction. *J Urol.* 1976;115(5):524–529.

1. Wagner IJ, Tong WM, Halvorson EG. A classification system for fat necrosis in