

Research article

## Chromosomal aberrations in benign and malignant Bilharzia-associated bladder lesions analyzed by comparative genomic hybridization

Imad Fadl-Elmula\*<sup>1</sup>, Soili Kytola<sup>2,3</sup>, Mona EL Leithy<sup>4</sup>, Mohamed Abdel-Hameed<sup>5</sup>, Nils Mandahl<sup>1</sup>, Atif Elagib<sup>4</sup>, Muntaser Ibrahim<sup>6</sup>, Catharina Larsson<sup>3</sup> and Sverre Heim<sup>7</sup>

Address: <sup>1</sup>Department of Clinical Genetics, University Hospital, SE-22185 Lund, Sweden, <sup>2</sup>Laboratory of Cancer Genetics, University of Tampere and Tampere University Hospital, FIN-33521 Tampere, Finland, <sup>3</sup>Department of Molecular Medicine, Karolinska Hospital, SE-171 76 Stockholm, Sweden, <sup>4</sup>Department of Immunology and Molecular Biology, Tropical Medicine Research Institute, Khartoum, Sudan, <sup>5</sup>Department of Pathology, Ibn Sina Hospital, Khartoum, Sudan, <sup>6</sup>Department of Molecular Biology, Institute of Endemic Diseases, University of Khartoum, Khartoum, Sudan and <sup>7</sup>Department of Cancer Genetics, The Norwegian Radium Hospital, Montebello, 0310 Oslo, Norway

E-mail: Imad Fadl-Elmula\* - fadl\_elmula@hotmail.com; Soili Kytola - Soili.Kytola@uta.fi; Mona EL Leithy - monaelethy@hotmail.com; Mohamed Abdel-Hameed - tropmed@sudanet.net; Nils Mandahl - Nils.Mandahl@klingen.lu.se; Atif Elagib - atifelagib@hotmail.com; Muntaser Ibrahim - muntaser26@hotmail.com; Catharina Larsson - Catharina.Larsson@cmm.ki.se; Sverre Heim - sverre.heim@labmed.uio.no

\*Corresponding author

Published: 22 March 2002

Received: 21 November 2001

BMC Cancer 2002, 2:5

Accepted: 22 March 2002

This article is available from: <http://www.biomedcentral.com/1471-2407/2/5>

© 2002 Fadl-Elmula et al; licensee BioMed Central Ltd. Verbatim copying and redistribution of this article are permitted in any medium for any purpose, provided this notice is preserved along with the article's original URL.

### Abstract

**Background:** Bilharzia-associated bladder cancer (BAC) is a major health problem in countries where urinary schistosomiasis is endemic. Characterization of the genetic alterations in this cancer might enhance our understanding of the pathogenic mechanisms of the disease but, in contrast to nonbilharzia bladder cancer, BAC has rarely been the object of such scrutiny. In the present study, we aimed to characterize chromosomal imbalances in benign and malignant post-bilharzial lesions, and to determine whether their unique etiology yields a distinct cytogenetic profile as compared to chemically induced bladder tumors.

**Methods:** DNAs from 20 archival paraffin-embedded post-bilharzial bladder lesions (6 benign and 14 malignant) obtained from Sudanese patients (12 males and 8 females) with a history of urinary bilharziasis were investigated for chromosomal imbalances using comparative genomic hybridization (CGH). Subsequent FISH analysis with pericentromeric probes was performed on paraffin sections of the same cases to confirm the CGH results.

**Results:** Seven of the 20 lesions (6 carcinomas and one granuloma) showed chromosomal imbalances varying from 1 to 6 changes. The most common chromosomal imbalances detected were losses of 1p21-31, 8p21-pter, and 9p and gain of 19p material, seen in three cases each, including the benign lesion.

**Conclusion:** Most of the detected imbalances have been repeatedly reported in non-bilharzial bladder carcinomas, suggesting that the cytogenetic profiles of chemical- and bilharzia-induced carcinomas are largely similar. However, loss of 9p seems to be more ubiquitous in BAC than in bladder cancer in industrialized countries.

## Background

Bladder cancer (BC) is the 5<sup>th</sup> and 7<sup>th</sup> most common malignancy among men and women, respectively, in Europe and the United States, with transitional cell carcinoma (TCC) dominating and accounting for more than 90% of all cases [1]. In the Middle East and African sub-Saharan, BC is the most common malignancy (25% of all cancers in men), with a clear dominance (87%) of the squamous cell carcinoma (SCC) sub-type [2]. In addition to the SCC differentiation and more pronounced male preponderance, a low mean age at diagnosis and rare involvement of the trigonal region characterize BC in Africa and the Middle East [3]. The geographic and clinical differences in BC behavior appear to be due mainly to etiologic differences: Whereas chemicals, including cigarette smoke and occupational exposures, cause TCC of the bladder in industrialized countries, a similarly strong association with urinary bilharziasis exists in Africa and the Middle East [4]. The mechanisms whereby urinary bilharziasis induces BC are not fully understood, but elevated urinary N-nitroso compounds [5,6], elevated levels of B-glucuronidase [7], and chronic mechanical irritation of the urothelium by calcified eggs deposited in the bladder wall have all been implicated [6–8].

In contrast to the extensive cytogenetic and molecular genetic analyses that exist of bladder TCC in Western countries [9], little is known about the genetic alterations of post-bilharzial BC [10]. Cytogenetic investigations require *in vitro* culturing of tumor cells and therefore may be difficult to perform in areas with a high frequency of bilharziasis-associated BC (BAC). Comparative genomic hybridization (CGH), on the other hand, is a powerful molecular cytogenetic technique not dependent on the presence of vital cells. The technique utilizes differentially labeled tumor DNA and normal tissue DNA as competing probes and normal metaphases as templates to detect and localize gains and/or losses of genetic material across the entire tumor genome [11]. Although CGH cannot detect balanced chromosomal changes, its ability to identify genomic imbalances even in archival, paraffin-embedded tumor materials [12] makes it uniquely well suited when fresh samples are not available. Accordingly, we planned the present experiment to characterize the genetic defects underlying the development of BAC and to determine if its distinct morphologic and clinical characteristics evolve following genetic alterations different from those detected in BC in industrialized countries.

## Material and Methods

### Tumor material

Fourteen formalin-fixed, paraffin-embedded blocks of post-bilharzial bladder carcinomas (8 SCC and 6 TCC) and 6 non-neoplastic bilharzia-associated bladder lesions from 20 Sudanese patients (12 males and 8 females) were

obtained from the pathology archives of Ibn Sina Hospital and the National Health Laboratory at Khartoum, Sudan (Table 1). All patients had a history of chronic urinary bilharziasis. No radiation therapy had been given before tumor sampling. The tumors were classified histologically according to the WHO (1973) grading system [13] and staged in accordance with the UICC tumor-node-metastasis (TNM) system [14].

### CGH analysis

From each case, 20–30 paraffin sections (thickness 3–4  $\mu$ m) were prepared for DNA extraction using the QIAamp Tissue Kit (QIAGEN GmbH, Germany). The yield of DNA was maximized with prolonged proteinase-K digestion according to previously published protocols [12]. CGH analysis was performed as previously described [11]. In brief, tumor DNA samples were labeled with FITC-dUTP (DuPont, Boston, MA, USA) by nick translation, whereas normal reference DNA was labeled with Texas Red (Vysis Inc., Downers Grove, IL, USA). In all cases, the tumor and reference DNA samples were sex-matched. Tumor and reference DNA were mixed with unlabeled Cot-1 DNA (Gibco, BRLTM), denatured, and applied onto slides with denatured metaphases of normal lymphocytes (Vysis Inc.). After hybridization at 37°C for 48 h, the slides were washed in  $0.4 \times$  SSC/0.3% NP-40 at 74°C for 2 min and in  $2 \times$  SSC/0.1% NP-40 at room temperature for 1 min. After air-drying, the slides were then counterstained with DAPI (Vysis Inc.). Two control hybridizations were also performed. In the first one, DNAs from a normal female and a normal male were labeled and hybridized to normal male metaphases. For the second experiment, DNA from a previously characterized breast cancer cell line (MPE 600, Vysis Inc.) and DNA from a normal female were labeled and hybridized to normal male metaphases. Six to 10 three-color digital images (DAPI, FITC, and Texas Red fluorescence) were collected from each hybridization using a Zeiss Axioplan 2 epifluorescence microscope (Carl Zeiss Jena GmbH, Jena, Germany) and a Sensys charge-coupled-device camera (Photometrics, Tucson, AZ, USA) interfaced to an IPLab Spectrum 10 workstation (Signal Analytics Corporation, Vienna, VA, USA). Interpretation of CGH results was carried out as previously described. Green-to-red ratios  $< 0.80$  were considered to signify losses of genetic material, ratios  $> 1.2$  gains, and ratios  $> 1.5$  high-level amplifications. Heterochromatic regions, the short arms of the acrocentric chromosomes, and the sex chromosomes were not included in the evaluation.

### Fluorescence in situ hybridization (FISH)

Pericentromeric probes for chromosomes X (pBAMX7), 9 (pHuR98), and 17 (p17H8) were labeled with FITC (DuPont) and digoxigenin using nick translation. Prior to hybridization, xylene and absolute ethanol were used to remove the paraffin from the slides. After air-drying, the

Table 1:

Lab No	Sex/Age	Histopathology				Other	FISH	CGH imbalances	
		Type	Grade	Stage	Losses		Gains		
Benign									
747-98	M/65	Ch. inflammation							
738-98	F/53	Ch. inflammation							
162-99	M/70	Ch. Inflammation	Moderate dysplasia						
548-98	M/51	Granuloma			CBO				
352-99	F/55	Granuloma			CBO	Xc 3, AR 1			
286-98	M/45	Granuloma with inflammatory polyp				9c 1, 17c 2	9p, 16p, 22q		
Malignant									
453-99	F/49	SCC	G1	?	CBO	topo 1			
2228-99	F/60	SCC	G1		CBO	9c 1, 17c 3, Xc 3	1 cen-p31, 3p,9pter-q13		19p
229-99	M/70	SCC	G2	T3	KCs	Xc 2, 17c 2			
210-99	M/70	SCC	G3	T3	KCs				
471-99	M/60	SCC	G3	?	CBO+SM	Xc 2, 17c 3			
217-98	F/51	SCC	G3	T3	CBO		9p		
476-98	M/53	SCC	G3	T3	CBO	9c 2, 17c 3	1p21-p22, 2q13-q21, 8p, 13q, 18q		19p
479-98	M/47	SCC	G2-3		CBO		2q13-q21, 8p		19p
345-98	M/61	TCC	G1	?	CBO+SM				
240-98	F/55	TCC	G2	?		Xc 1, 9c 2, 17c 2			
746-98	F/60	TCC	G2			Xc 2-3, 9c2-3, 17c 2-6(4)			
4540-98	M/62	TCC	G2	?					
5605-97	M/50	TCC	G3	T3	SM	Xc 2, AR 3-5	8p21-pter		
5653-98	F/50	TCC	G3	T3		Xc 1-3, 9c 2, 17c 2	1 cen-p31		5p, 17q, 20q

SCC, squamous cell carcinoma; TCC, transitional cell carcinoma; G1, well differentiated; G2, moderately differentiated; G3, poorly differentiated; CBO, calcified bilharzial ova; I K:C:s, keratinized cells; SM, squamous metaplasia

samples were pretreated with 0.01 M sodium citrate (pH7.3) in 92°C for 10 min, followed by proteinase digestion (10 mg in 2 × SSC) in 45°C for 30 min. The slides were then rinsed in 2 × SSC, dehydrated in an ethanol series, and air-dried. The probes with human placental DNA were denatured together with the slides on a hot plate at 75°C for 5 min, and hybridized at 37°C overnight. After washing and detection of digoxigenin with anti-digoxigenin rhodamine, the slides were counterstained with 0.1 μM 4,6-diamino-2-phenylindole (DAPI) in an antifade solution (Vectashield, Vector Laboratories, Burlingame, CA, USA). The analysis was performed using an Olympus epifluorescence microscope equipped with a CCD camera (Photometrics).

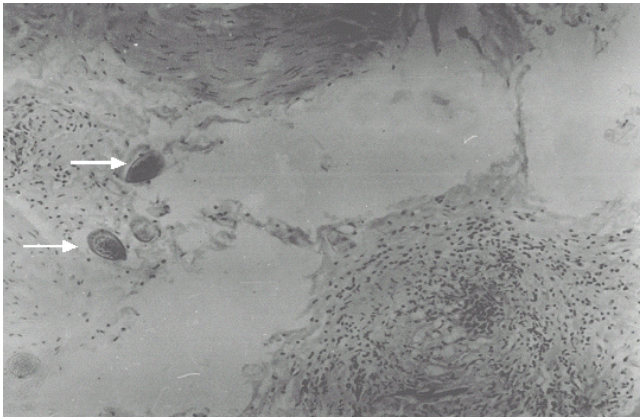
**Results**

The clinical, histopathologic, CGH, and FISH findings are summarized in Table 1 and Figures 1,2,3. The pathologic examination showed calcified bilharzial ova in at least 8

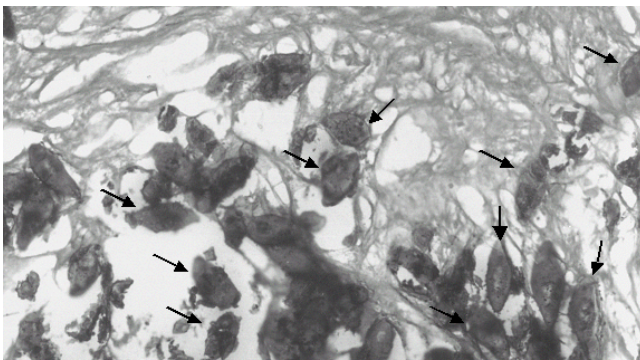
of the cases as a direct indication of urinary bilharziasis (Figures 1 and 2). The CGH results were generally characterized by a low number of genomic alterations. Of the 20 cases, 6 carcinomas (4 SCC and 2 TCC) and one benign lesion (bilharzial granuloma) showed chromosomal imbalances varying from 1 to 6 changes. In the remaining 13 samples, no DNA copy number changes could be detected. The most frequent changes (3 cases) were of chromosomes 1, 8, 9, and 19, with losses being observed from the short arms of chromosomes 1, 8, and 9 and gains of material from 19p. The FISH analyses performed on nuclei extracted from sectioned slides of 12 cases were consistent with the CGH findings (Table 1).

**Discussion**

Schistosomiasis is endemic in 74 tropical developing countries. Some 600 million of the world's population run the risk of becoming infected, of which 200 million are already infected. In most of the cases, infestation with



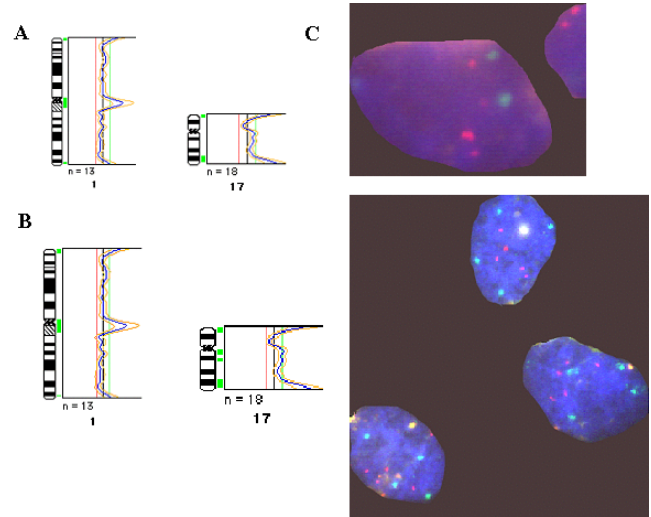
**Figure 1**  
Histologic section from invasive squamous cell carcinoma (case 217-98). *Schistosoma haematobium* eggs (arrows) embedded in bladder urothelium confirm the previous infestation with urinary schistosomiasis.



**Figure 2**  
Histologic section from patient bladder with active urinary bilharziasis (case 286-98). Arrowheads indicate calcified bilharzial ova embedded in bladder urothelium.

schistosomiasis leads to damage of the urothelium, which results in permanent loss of mature, superficial cells and an increased rate of cell division, eventually leading to the formation of a hyperplastic urothelium consisting of immature cells. The disturbed cellular differentiation pattern thus gives rise to a variety of non-cancerous phenotypes with a pronounced tendency to undergo malignant transformation.

Compared with banding cytogenetics that has the capacity to provide detailed information on balanced as well as unbalanced chromosomal rearrangements, even in cases displaying intratumor clonal heterogeneity, CGH can only detect genomic imbalances present in major tumor clones [15]. On the other hand, CGH is superior in the sense that it can be applied to both fresh and frozen tumor



**Figure 3**  
The CGH profiles and FISH results in case 746-98. The CGH profiles of chromosomes 1 and 17 with thresholds 1.2 and 0.8 are shown in panel A. The CGH profiles of chromosomes 1 and 17 with thresholds 1.15 and 0.85 are shown in panel B. Two different cell populations are seen by FISH, shown in panel C. The centromere probes for chromosomes 1 and 17 were labeled by FITC and Rhodamine, respectively. Two signals of both probes are seen above and four signals of 1cen and six signals of 17cen are seen below.

samples as well as to formalin-fixed and paraffin-embedded materials [16], thereby circumventing the culturing process with the technical and selection problems this involves and which may cause considerable interpretation difficulties in conventional cytogenetic analysis. In 13 of the studied bladder lesions (4 SCC, 4 TCC, and 5 non-malignant lesions), no chromosomal imbalances were detected, indicating that the genetic alterations, if any existed, were qualitatively or quantitatively beyond the detection limits of the CGH method. However, the positive results in the remaining 7 cases (4 SCC, 2 TCC, and 1 granuloma) demonstrate the capacity of CGH to detect chromosomal imbalances in tumor DNA obtained from archival materials. In the 11 cases in which FISH analysis with pericentromeric probes was performed, the results were consistent with those obtained by CGH analysis. In two cases (471-99 and 746-98), however, the FISH examination revealed chromosomal imbalances that had not been detected in the previous CGH analysis (Figure 3). The explanation for this discrepancy could be that too few neoplastic cells were present in the sample or that secondary intratumor genetic heterogeneity had arisen, again preventing the CGH results from reaching beyond the detection thresholds.

Several preneoplastic urothelial lesions may precede the development of BAC such as inflammatory polyp, bilharzial granuloma, and bilharzial ulcer. To our knowledge, no data are available on the karyotypic characteristics of these lesions. Preneoplastic lesions in other organs have been shown to harbor nonrandom acquired genetic aberrations; in fibrocystic disease of the breast, for instance, cytogenetic studies have revealed clonal chromosomal abnormalities resembling the ones detected in carcinomas of the same organ [17]. Hence, another objective of the present study was to find out if benign bilharzial bladder lesions also carry chromosomal aberrations, and if they do, whether they resemble those seen in bladder carcinomas. Such changes, if present, would presumably constitute the earliest steps of a putative multistage cascade of post-bilharzial carcinogenesis [18]. Of the 6 non-neoplastic lesions examined, 5 were noninformative, in-as-much as no gains or losses were detected, and only in case 286–98 were chromosomal imbalances seen, one of them loss of 9p. The data are of course meager, but viewed in concert with what has already been reported [19–21], they come across as meaningful. Thus, loss of material from 9p in both malignant and non-malignant bilharzial lesions appears to be an initiating event in BAC. However, several have shown that loss of 9p (without loss of 9q) is a common genetic event in advanced, muscle invasive TCC, and since most (80%) BACs are advanced as far as grade and stage are concerned, loss of material from 9p may be seen more frequently in these carcinomas [22–25].

With the exception of the gain of chromosome material from 19p observed in three cases (2228–99, 476–98, and 479–98), almost all changes detected in our series (complete or partial loss of 1p, 8p, 9p, and 13q, and gain of 5p, 17q, and 20q) have been previously reported as recurrent genetic changes in chemically induced TCC of the bladder [9]. However, the gain of 19p should be interpreted with caution since this chromosome is prone to hybridization variability that may result in CGH artifacts. For the latter aberrations, the available data therefore indicate that they form part of a pathogenetic pathway followed by both BAC and chemical carcinogen-induced BC. A previous study reported homozygous deletions at 9p without any involvement of 9q in 92% of bilharzial carcinomas obtained from Egyptian patients compared with only 10% in bladder TCC obtained from Swedish patients [19]. In the same study, the type and position of *TP53* mutations also differed between the two tumor types, again suggesting molecular differences in the genetic mechanisms of bladder carcinogenesis depending on underlying etiology. Tsutsumi et al. [21] also suggested that loss of 9p21 heterozygosity was associated with early carcinogenesis of SCC of the bladder; they observed homozygous deletion of p16/p19 in 45% of squamous metaplasia from bladder cancer patients, demonstrating that this change occurred

already in preneoplastic cells. Muscheck et al. [26] reached the same conclusion, and showed that different histologic subgroups of bladder tumors are characterized by distinct patterns of chromosomal alterations. The loss of 9p we observed in bilharzia-associated lesions is therefore in complete agreement with earlier findings [19–25] and could be an indication that bladder carcinogenesis with this etiology follows a more narrow pathogenetic pathway (loss of 9p) than is the case for BC in the industrialized world (the earliest genomic change in these tumors is loss of 9p, loss of 9q or loss of the entire chromosome).

At the time of the first diagnosis, more than 80% of BAC present as bulky fungating nodular tumor masses with deep infiltration into the bladder wall. This necessitates radical cystectomy and urinary diversion. Unfortunately, at this late stage even these extensive therapeutic measures are rarely curative and long-term survival is obtained only in about 27–39% of the cases. It is clear that BAC is a potentially preventable disease, but until the means are found to achieve primary prevention through the control of schistosomiasis, one is dependent on earlier diagnosis, which means that a test for early detection of malignancy in high-risk groups, especially for the detection of early tumor stages, is badly needed. One can envisage the use of a molecular genetic test based on the consistent loss of 9p in cells detected in the urine for such screening purposes.

### Acknowledgments

This work was supported by grants from the Medical Faculty of Lund University, the Swedish Cancer Foundation, the Torsten and Ragnar Söderberg Foundation, the Swedish Match AB, the Swedish Society for Medical Research, the Norwegian Society for Cancer Research, the John and Augusta Perssons Fund for Medical Research, and the Finnish Cancer Institute

### References

1. Chomczynski P, Sacchi N: **Single-step method of RNA isolation by acid guanidinium thiocyanate-phenol-chloroform extraction.** *Anal Biochem* 1987, **162**:156-159
2. Johansson SL, Cohen SM: **Epidemiology and etiology of bladder cancer.** *Semin Surg Oncol* 1997, **13**:291-298
3. El-Bolkainy MN, Mokhtar NM, Ghoneim MA, Hussein MH: **The impact of schistosomiasis on the pathology of bladder carcinoma.** *Cancer* 1981, **48**:2643-8
4. Badawi AF, Mostafa MH, Probert A, O'Connor PJ: **Role of schistosomiasis in human bladder cancer: evidence of association, aetiological factors, and basic mechanisms of carcinogenesis.** *Eur J Cancer Prev* 1995, **4**:45-59
5. Bedwani R, el-Khwsly F, Renganathan E, Braga C, Abu Seif HH, Abul Azm T, Zaki A, Franceschi S, Boffetta P, La Vecchia C: **Schistosomiasis and the risk of bladder cancer in Alexandria, Egypt.** *Br J Cancer* 1998, **77**:1186-1189
6. Tricker AR, Mostafa MH, Spiegelhalter B, Preussmann R: **Urinary nitrate, nitrite and N-nitroso compounds in bladder cancer patients with schistosomiasis (bilharzia).** *IARC Sci Publ* 1991, **105**:178-181
7. Badawi AF: **Nitrate, nitrite and N-nitroso compounds in human bladder cancer associated with schistosomiasis.** *Int J Cancer* 2000, **86**:598-600
8. Norden DA, Gelfand M: **Bilharzia and bladder cancer. An investigation of urinary glucuronidase associated with *S. haematobium* infection.** *Trans R Soc Trop Med Hyg* 1972, **66**:864-866

9. Matanoski GM, Elliott EA: **Bladder cancer epidemiology.** *Epidemiol Rev* 1981, **3**:203-229
10. Heim S, Mitelman F: **Cancer Cytogenetics.** New York, Wiley-Liss, 1995
11. El-Rifai W, Kamel D, Larramendy ML, Shoman S, Gad Y, Baithun S, El-Awady M, Eissa S, Khaled H, Soloneski S, et al: **DNA copy number changes in Schistosoma-associated and non-Schistosoma-associated bladder cancer.** *Am J Pathol* 2000, **156**:871-878
12. Kallioniemi A, Kallioniemi OP, Sudar D, Rutovitz D, Gray JW, Waldman F, Pinkel D: **Comparative genomic hybridization for molecular cytogenetic analysis of solid tumors.** *Science* 1992, **258**:818-821
13. Isola J, DeVries S, Chu L, Ghazvini S, Waldman F: **Analysis of changes in DNA sequence copy number by comparative genomic hybridization in archival paraffin-embedded tumor samples.** *Am J Pathol* 1994, **145**:1301-1308
14. World Health Organization (WHO): **Histological typing of urinary bladder tumors.** *International Histological Classification of Tumors* 1973
15. Hermanek P, Sobin LH: **Urology and the TNM classification.** *Lancet* 1987, **1495**:8626-8627
16. Gray JW, Kallioniemi A, Kallioniemi O, Pallavicini M, Waldman F, Pinkel D: **Molecular cytogenetics: diagnosis and prognostic assessment.** *Curr Opin Biotechnol* 1992, **36**:623-631
17. Ghazvini S, Char DH, Kroll S, Waldman FM, Pinkel D: **Comparative genomic hybridization analysis of archival formalin-fixed paraffin-embedded uveal melanomas.** *Cancer Genet Cytogenet* 1996, **90**:95-101
18. Petersson C, Pandis N, Mertens F, Adeyinka A, Ingvar C, Ringberg A, Idvall I, Bondeson L, Borg A, Olsson H, et al: **Chromosome aberrations in prophylactic mastectomies from women belonging to breast cancer families.** *Genes Chromosomes Cancer* 1996, **16**:185-188
19. Heim S, Mitelman F: **Primary chromosome abnormalities in human neoplasia.** *Adv Cancer Res* 1989, **52**:1-43
20. Gonzalez-Zulueta M, Shibata A, Ohneseit PF, Spruck CH, Busch C, Shamaa M, El-Baz M, Nichols PW, Gonzalgo ML, Elbaz M, et al: **High frequency of chromosome 9p allelic loss and CDKN2 tumor suppressor gene alterations in squamous cell carcinoma of the bladder.** *J Natl Cancer Inst* 1995, **87**:1383-1393
21. Ghaleb AH, Pizzolo JG, Melamed MR: **Aberrations of chromosomes 9 and 17 in bilharzial bladder cancer as detected by fluorescence in situ hybridization.** *Am J Clin Pathol* 1996, **106**:234-241
22. Tsutsumi M, Tsai YC, Gonzalgo ML, Nichols PW, Jones PA: **Early acquisition of homozygous deletions of p16/p19 during squamous cell carcinogenesis and genetic mosaicism in bladder cancer.** *Oncogene* 1998, **17**:3021-3027
23. Richter J, Wagner U, Schraml P, Maurer R, Alund G, Knonagel H, Moch H, Mihatsch MJ, Gasser TC, Sauter G: **Chromosomal imbalances are associated with a high risk of progression in early invasive (pT1) urinary bladder cancer.** *Cancer Res* 1999, **59**:5687-5691
24. Terracciano L, Richter J, Tornillo L, Beffa L, Diener PA, Maurer R, Gasser TC, Moch H, Mihatsch MJ, Sauter G: **Chromosomal imbalances in small cell carcinomas of the urinary bladder.** *J Pathol* 1999, **189**:230-235
25. Zhao J, Richter J, Wagner U, Roth B, Schraml P, Zellweger T, Ackermann D, Schmid U, Moch H, Mihatsch MJ, Gasser TC, Sauter G: **Chromosomal imbalances in noninvasive papillary bladder neoplasms (pTa).** *Cancer Res* 1999, **59**:4658-4661
26. Simon R, Burger H, Semjonow A, Hertle L, Terpe HJ, Bocker W: **Patterns of chromosomal imbalances in muscle invasive bladder cancer.** *Int J Oncol* 2000, **17**:1025-1029
27. Muscheck M, Abol-Enein H, Chew K, Moore D 2nd, Bhargava V, Ghoneim MA, Carroll PR, Waldman FM: **Comparison of genetic changes in schistosome-related transitional and squamous bladder cancers using comparative genomic hybridization.** *Carcinogenesis* 2000, **21**:1721-1726

### Pre-publication history

The pre-publication history for this paper can be accessed here: <http://www.biomedcentral.com/1471-2407/2/5/prepub>

Publish with **BioMed Central** and every scientist can read your work free of charge

"BioMedcentral will be the most significant development for disseminating the results of biomedical research in our lifetime."

Paul Nurse, Director-General, Imperial Cancer Research Fund

Publish with **BMC** and your research papers will be:

- available free of charge to the entire biomedical community
- peer reviewed and published immediately upon acceptance
- cited in PubMed and archived on PubMed Central
- yours - you keep the copyright



Submit your manuscript here:

<http://www.biomedcentral.com/manuscript/>

[editorial@biomedcentral.com](mailto:editorial@biomedcentral.com)