

Olfactory fossa depth: CT analysis of 1200 patients

Ashok Chirathalattu Babu, Mattavana Ramakrishna Pillai Balachandran Nair, Aneesh Mangalasseril Kuriakose

Department of Radiodiagnosis, Jubilee Mission Medical College and Research Institute, Thrissur, Kerala, India

Correspondence: Dr. Mattavana Ramakrishna Pillai Balachandran Nair, Department of Radiodiagnosis, Jubilee Mission Medical College and Research Institute, East Fort, Jubilee Mission P.O, Thrissur, Kerala, India. E-mail: mrbaala@gmail.com

Abstract

Background: Olfactory fossa (OF) is a depression in anterior cranial cavity whose floor is formed by cribriform plate of ethmoid. Lateral lamella, which forms its lateral boundary, is a thin plate of bone and is at risk of injury during functional endoscopic sinus surgery, especially when fossa is deep/asymmetric. **Aims:** To measure the variations in the depth of OF and categorize Kerala population as per Keros classification using computed tomography (CT). **Settings and Design:** This study was conducted in our institution from January 2016 to August 2017. Patients >16 years of age undergoing CT scan of paranasal sinuses (PNS) were included. **Materials and Methods:** Coronal PNS CT scan studies of 1200 patients were reviewed. The depth of OF was measured from vertical height of lateral lamella. **Statistical Methods:** Results were analyzed according to gender and laterality using independent sample *t*-test and Chi-square test. **Results:** The mean depth of OF was 5.26 ± 1.69 mm. Statistically significant difference was seen in the mean depth of OF between males and females but not between right and left sides. Keros type I was found on 420 sides (17.5%), type II in 1790 (74.6%), and type III on 190 sides (7.9%). Type III Keros was more on the right (9%) than left (6.8%) side, more in males (9.5%) than females (5.9%), and more among males on the right side (11.4%). Asymmetry in OF depth between two sides was seen in 75% of subjects. **Conclusion:** Prevalence of the dangerous type III OF, even though low, is significant especially among males and on the right side. Therefore, preoperative assessment of OF depth must be done to reduce iatrogenic complications.

Key words: Functional endoscopic sinus surgery; Keros; olfactory fossa

Introduction

In the recent years, functional endoscopic sinus surgery (FESS) has emerged as the common modality of treatment for diseases of nose and paranasal sinuses (PNS). Even though there is significant reduction in the incidence of associated complications in FESS when compared with traditional approaches, it is not immune to complications.

Multiplanar imaging, especially coronal reformations, offers precise information regarding the anatomy of PNS

and its variations.^[1] Various factors such as asymmetry of ethmoidal fovea, olfactory fossa (OF), anatomical variations in lateral lamella, and course of anterior ethmoid artery are critical in FESS as they may predispose to iatrogenic damages. Therefore, preoperative evaluation by computed tomography (CT) is mandatory before FESS.^[2]

The OF is a depression in the anterior cranial cavity whose floor is formed by the cribriform plate of ethmoid. This delicate bony plate separates the anterior cranial fossa from the nasal cavity. OF is bounded laterally by the lateral

Access this article online

Quick Response Code:



Website:
www.ijri.org

DOI:
10.4103/ijri.IJRI_119_18

This is an open access journal, and articles are distributed under the terms of the Creative Commons Attribution-NonCommercial-ShareAlike 4.0 License, which allows others to remix, tweak, and build upon the work non-commercially, as long as appropriate credit is given and the new creations are licensed under the identical terms.

For reprints contact: reprints@medknow.com

Cite this article as: Babu AC, Nair MR, Kuriakose AM. Olfactory fossa depth: CT analysis of 1200 patients. Indian J Radiol Imaging 2018;28:395-400.

lamella of cribriform plate and medially by crista galli.^[3] It contains the olfactory bulbs and tracts. The lateral lamella is the thinnest bone in the anterior skull base. It is dehiscent in up to 14% of patients.^[4]

The levels of the ethmoid roof/fovea ethmoidalis and cribriform plate may differ even in the same person depending on the vertical extent of the lateral lamella. The relationship between the OF and the ethmoid roof was studied by Keros in 450 skulls in 1962. He created a three-category classification system for depth of the OF in relation to the ethmoid roof. The depth of OF is measured by the vertical height of the lateral lamella of the cribriform plate (LLCP), that is, the difference between the height of the cribriform plate and ethmoid roof.^[5-7] In Keros type I, depth is 1–3 mm, type II 4–7 mm, and type III 8–16 mm.

In Keros type I, the OF is flat. The ethmoid roof is almost in the same plane as the cribriform plate. In type II relationship, the lateral lamella is higher and the OF is deeper than type I. In type III, lateral lamella is higher with a deeper OF. The ethmoid roof lies significantly above the level of cribriform plate^[1,8] [Figures 1-3]. Type III relationship is the most dangerous type for endoscopic sinus surgeries. Therefore, Keros type III is called dangerous ethmoid.^[3,9] There is high chance of penetration through the LLCP. Asymmetry in the OF depth or the height of ethmoidal roof [Figure 4] is also associated with higher risk of intracranial penetration during surgeries such as FESS.^[8,10] Iatrogenic injury can lead to various complications including ascending meningitis, intracranial hypotension from cerebrospinal fluid leak, meningocele, or meningoencephalocele.^[11] Therefore, preoperative evaluation of OF depth is of paramount importance in a successful FESS.

After Keros, many studies have been conducted on ethmoid roof and OF based on Keros classification among various populations. The ethmoid roof configuration varies between different racial populations. There exists scarcity of data regarding analysis of OF in the Indian context. Our study aims to measure the variations in the CT depth of OF among population of Kerala (southernmost state in India) using Keros classification.

Materials and Methods

The study was conducted in our institution after getting clearance from Research and Human Ethical Committee. Patients above 16 years of age, who were referred by various clinical specialties for undergoing noncontrast CT of the PNS from January 2016 to August 2017, were evaluated in the study. All patients with previous history of nasal or paranasal trauma, surgeries, congenital anomalies of face, sinonasal polyposis, tumors, or conditions involving bone destruction were excluded.

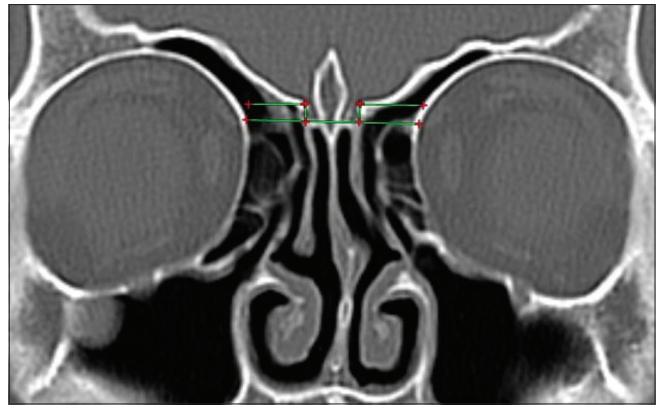


Figure 1: Coronal CT demonstrating type I Keros classification. Olfactory fossae are not very deep. Ethmoid roofs are almost in the same plane as the cribriform plate

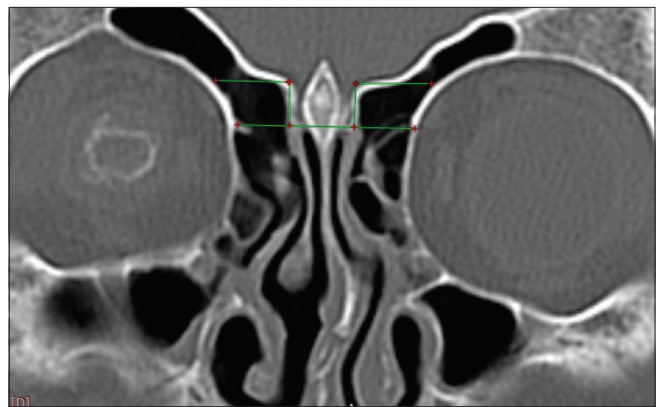


Figure 2: Coronal CT demonstrating type II Keros classification. Olfactory fossae are deeper and the lateral lamellae are longer than in type I

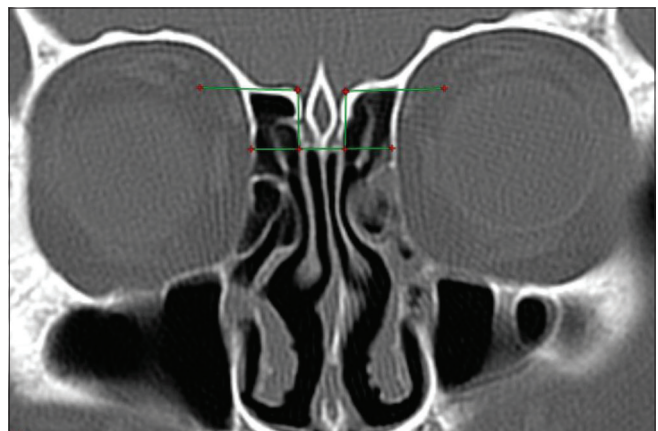

Figure 3: Coronal CT demonstrating type III Keros classification. Here the olfactory fossae are very deep compared with types I and II

All the CT images were acquired in a helical Hi-Speed tomograph (GE HiSpeed NX/i Pro Dual Slice). Images were acquired perpendicularly to the hard palate, from the anterior margin of the frontal sinus to the anterior margin of the clivus, with the patient in prone position. The technical parameters adopted in the acquisition of tomographic

images include 120-kV tube voltage, 160 effective mAs, 1 s rotation time, section thickness of 4 mm, and a field of view of 15 cm.

The CT images were analyzed using HP Workstation xw8200 having Linux operating system 2.6.15-2.5 (GEHC/CTT Linux 5.2.10). Only coronal sections were used in the study. The images were studied in the bone window.

The following anatomical structures/points were identified and used for measuring OF depth:

1. Cribriform plate
2. LLCP
3. Medial ethmoidal roof point (medial end of ethmoid roof articulating with LLCP).

Horizontal lines were drawn along the cribriform plate and at the medial ethmoid roof point. The vertical height of lateral lamella was measured between these two horizontal lines using the distance-measuring tool. The vertical height of lateral lamella corresponds to the depth of OF. The heights of both right and left lateral lamella were recorded separately. OF depth of 1–3.9 mm was categorized as Keros type I, 4–7.9 mm as type II, and ≥8 mm as type III.

Images of all the patients were coanalyzed by the first (junior resident in radiology) and second (radiologist with 35 years of experience in image data processing and analysis) authors. Interobserver agreement was obtained for measurements in each patient.

Statistical analyses were done using IBM SPSS Statistics Ver 20.0.^[12] The results were grouped according to Keros classification and their distributions were analyzed according to gender and laterality. The statistical significance was set to $P < 0.05$.

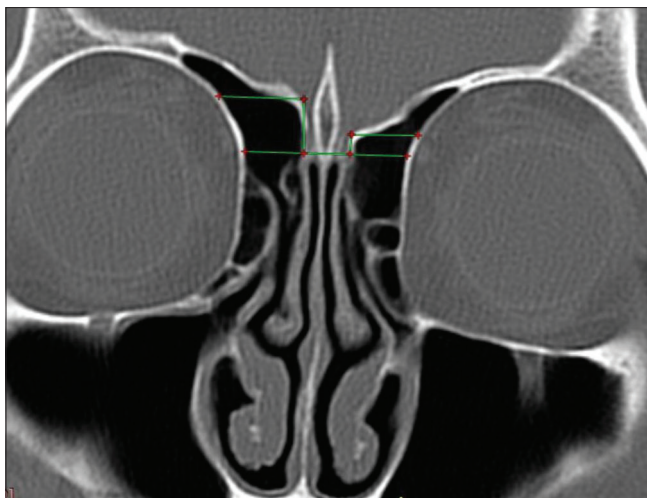

Figure 4: Coronal CT scan showing asymmetry in the depth of OF on either sides. Difference of >2 mm is seen in the OF depth between two sides. Both sides have different Keros type OF (type III on right and type I on left side)

Results

PNS CT scans of 1200 subjects were included in the study. Among 1200 subjects, 669 were males (55.8%) and 531 were females (44.3%). The youngest subject was 17 years and the eldest was of 86 years of age. The mean age [\pm standard deviation (SD)] of the study group was 36.76 (\pm 13.82) years.

The depth of OF ranged from 1 to 14 mm. The mean depth of the total 2400 OF studied was 5.26 mm with an SD of 1.69. The mean depth of OF on the right side was 5.27 mm with an SD of 1.72 and the mean depth on the left side was 5.25 mm with an SD of 1.65. Using independent sample *t*-test, *P* value was 0.479; no significant difference was seen between the mean depth of OF on both sides. The mean depth of OF in males (including both sides) was 5.33 mm with an SD of 1.73 and that in females was 5.17 mm with an SD of 1.62. Using independent sample *t*-test, *P* value was 0.022. Statistically significant difference was present in the mean depth of OF between males and females [Table 1].

Among the total 2400 sides, Keros type I was seen in 420 (17.5%), type II in 1790 (74.6%), and type III in 190 sides (7.9%). On the right side, 212 (17.7%) OF were Keros type I, 880 (73.3%) were type II, and 108 (9%) were type III. On the left side, 208 (17.3%) OF were Keros type I, 910 (75.8%) were type II, and 82 (6.8%) were type III [Table 2].

Among males, OF was Keros type I among 113 subjects (16.9%), type II among 480 (71.7%), and type III among 76 (11.4%) on the right side. Among females, OF was type I among 99 (18.6%), type II among 400 (75.3%), and type III among 32 (6%) on the right side. Using Chi-square test, *P* value was 0.006 (<0.05). So there was significant association between sex and Keros type on the right side. OF was Keros type I in 110 (16.4%), type II in 508 (75.9%), and type III in 51 (7.6%) males on the left side. Similarly, among females on the left side, OF was Keros type I in 98 (18.5%),

Table 1: Distribution of OF depth

	OF depth total	OF depth right	OF depth left	OF depth male	Of depth female
Mean	5.26	5.27	5.25	5.33	5.17
<i>n</i>	2400	1200	1200	1338	1062
Standard Deviation	1.69	1.72	1.65	1.73	1.62

Table 2: Distribution of OF according to the side and Keros classification

Keros type	Right		Left		Total	
	<i>n</i>	Percentage	<i>n</i>	Percentage	<i>n</i>	Percentage
Type I	212	17.7	208	17.3	420	17.5
Type II	880	73.3	910	75.8	1790	74.6
Type III	108	9.0	82	6.8	190	7.9
Total	1200	100	1200	100	2400	100

type II in 402 (75.7%), and type III in 31 (5.8%) females. Using Chi-square test, P value was 0.354 (>0.05), and therefore, no significant association between sex and Keros type on the left side. Among males (after including OF on both sides), 223 (16.7%) OF were Keros type I, 988 (73.8%) type II, and 127 (9.5%) type III. Similarly among females, 197 (18.5%) OF were Keros type I, 802 (75.5%) type II, and 63 (5.9%) type III. Using Chi-square test, P value was 0.004 (<0.05). So there was significant association between sex and Keros type [Table 3].

In our study, asymmetry was defined as having a difference of ≥ 0.1 mm in the depth of OF between the two sides. Among 1200 subjects studied, 900 (75%) show asymmetry between the right and left sides, and in 300 subjects (25%), symmetry was observed. Among the total 669 males, OF was symmetric on both sides in 162 (24.2%) and asymmetric in 507 (75.8%). Among 531 females, 138 (26%) and 393 (74%) were having symmetric and asymmetric OF, respectively. Using Chi-square test, P value was 0.481 (>0.05). No significant association exists between sex and distribution of symmetric and asymmetric OF on either sides [Table 4].

Among 900 subjects with asymmetry in the OF depth between the right and left sides, 581 subjects (64.6%) had a difference of ≤ 1 mm between two sides, 228 subjects (25.3%) a difference of 1–2 mm, and 91 subjects (10.1%) a difference of >2 mm. Among 507 males with asymmetry in OF depth between two sides, 327 (64.5%) had a difference of ≤ 1 mm, 124 (24.5%) a difference of 1–2 mm, and 56 (11%) a difference of >2 mm. Among 393 females with asymmetry, 254 (64.6%) had a difference of ≤ 1 mm, 104 (26.5%) a difference of 1–2 mm, and 35 (8.9%) a difference of >2 mm between two sides. Using Chi-square test, P value was 0.508 (>0.05). No significant association was found between sex and asymmetry [Table 5].

Among 900 subjects with asymmetry, 462 (51.3%) had deeper OF (i.e., fovea at higher level) on the right side and 438 (48.7%) subjects had deeper OF on the left side. Among 507 males with asymmetry in OF depth on both sides, 264 (52.1%) males had deeper fossa on the right side and 243 (47.9%) on the left side. Among 303 females with asymmetry in OF depth, 198 (50.4%) females had deeper OF on the right side and 195 (49.6%) on the left side. Using Chi-square test, P value was 0.615 (>0.05); no significant association exists between sex and side with deeper OF [Table 6].

Among 1200 subjects, 940 subjects (78.3%) showed same Keros type and 260 subjects (21.7%) showed different Keros type on both sides. Among 669 males, 525 (78.5%) had same Keros type and 144 (21.5%) had different Keros type on both sides. Among 531 females, 415 (78.3%) had same Keros type and 116 (21.8%) had different Keros type on both sides. Using Chi-square test, P value was 0.893 (>0.05). No significant association was there between sex and type of Keros on both sides [Table 7].

Discussion

There is paucity of in-depth studies regarding OF analysis in the Indian scenario, barring a few which are mentioned below. Previously, Salroo *et al.*^[13] (200 subjects), Pawar *et al.*^[14] (200 subjects), Satish Nair^[15] (180 subjects), Ali *et al.*^[16] (75 subjects), Gupta *et al.*^[17] (100 subjects), and Jacob *et al.*^[3] (32 cadaveric skulls) had done OF analysis among Indian population from various states, but the sample sizes were limited and asymmetry analysis was incomplete in most. In our study, we have tried to focus on the distribution of Keros types and various asymmetry parameters in detail and is more comprehensive than the previous Indian studies. In addition, this study is more extensive compared with the previous ones, providing a large data on the Indian population (evaluated 1200 subjects; total 2400 OF).

In this study, type II OF was the most frequent (74.6%). Type I was seen in 17.5% and type III in 7.9% [Table 2]. In the previous Indian studies too, type II OF was the most prevalent followed by types I and III. Comparison to other Indian studies is shown in Table 8. Similar studies were carried out in various parts of the world analyzing the ethmoid roof and OF according to Keros classification. There exists diversity in the distribution of configuration among different racial populations across the world and is shown in Table 9.

Statistically significant association was seen between sex and Keros type in our study especially on the right side. The dangerous type III Keros was seen more on the right (9%) than the left (6.8%) side, more in males (9.5%) than females (5.9%), and even more among males on the right side (11.4%) [Tables 2 and 3]. But in the study by Salroo *et al.*, no statistically significant difference was observed in the distribution of Keros classification between males and females.^[13]

Table 3: Distribution of OF based on Keros classification according to their sides and sex

Keros Type	Right (n (%))		Left (n(%))		Total (n (%))		Overall
	Male	Female	Male	Female	Male	Female	
Type I	113 (16.9%)	99 (18.6%)	110 (16.4%)	98 (18.5%)	223 (16.7%)	197 (18.5%)	420 (17.5%)
Type II	480 (71.7%)	400 (75.3%)	508 (75.9%)	402 (75.7%)	988 (73.8%)	802 (75.5%)	1790 (74.6%)
Type III	76 (11.4%)	32 (6%)	51 (7.6%)	31 (5.8%)	127 (9.5%)	63 (5.9%)	190 (7.9%)
Total	669 (100%)	531 (100%)	669 (100%)	531 (100%)	1338 (100%)	1062 (100%)	2400 (100%)

Table 4: Distribution of symmetric and asymmetric OF on either sides according to sex

	Symmetric		Asymmetric		Total	
	n	Percentage	n	Percentage	n	Percentage
Male	162	24.2	507	75.8	669	100
Female	138	26	393	74	531	100
Total	300	25	900	75	1200	100

Table 5: Distribution of asymmetry according to sex

	Asymmetry						Total n
	Diff ≤1mm		Diff 1-2mm		Diff >2mm		
	n	Percentage	n	Percentage	n	Percentage	
Male	327	64.5	124	24.5	56	11	507
Female	254	64.6	104	26.5	35	8.9	393
Total	581	64.6	228	25.3	91	10.1	900

Table 6: Distribution of asymmetry according to side with deeper OF and sex

	Asymmetry				Total n
	Side in which olfactory fossa is deeper				
	Right side		Left side		
	n	Percentage	n	Percentage	
Male	264	52.1	243	47.9	507
Female	198	50.4	195	49.6	393
Total	462	51.3	438	48.7	900

The mean depth of OF in our study was 5.26 mm. The mean depth in the studies by Jacob *et al.* and Salroo *et al.* was 5.08 and 4.9 mm, respectively.^[3,13] Analysis of OF depth with respect to gender showed statistically significant difference in our study with males and females having a mean depth of 5.33 and 5.17 mm, respectively [Table 1]. Similarly, Salroo *et al.* also observed significant difference in the OF depth between males and females.^[13]

No significant difference was seen in the mean depth of OF between right and left sides in this study. Jacob *et al.* also observed no significant difference in OF depth between the sides.^[3] Conversely, the study by Salroo *et al.* showed significant difference between the sides.^[13] A study by Pawar *et al.* also showed statistically significant difference in OF depth between the right and left sides but only in males.^[14]

In contrast to other Indian studies, various parameters of asymmetry were analyzed in detail in this study, but no significant association was seen between sex and any of these. In this study, 75% of the subjects showed asymmetry in the OF depth on either sides and its prevalence was almost similar in males (75.8%) and females (74%) [Table 4]. In the studies by Satish Nair and Ali *et al.*, 11.7% and 14.6% of patients, respectively, had asymmetry.^[15,16] High rate of asymmetry noted in our study population may be attributed to the precise measurement of OF depth and the more stringent

Table 7: Distribution of subjects with same and different Keros types on either sides according to sex

	Keros type on both sides				Total n
	Same		Different		
	n	Percentage	n	Percentage	
Male	525	78.5	144	21.5	669
Female	415	78.2	116	21.8	531
Total	940	78.3	260	21.7	1200

Table 8: Comparison of the Keros classification with other Indian studies

Keros	Our study	Salroo <i>et al.</i>	Pawar <i>et al.</i>	Satish Nair	Ali <i>et al.</i>	Gupta <i>et al.</i>	Jacob <i>et al.</i>
Type I	17.5%	29%	18.5%	17.2%	20%	39%	23.44%
Type II	74.6%	61%	74.5%	77.2%	78.7%	59%	70.8%
Type III	7.9%	10%	7%	5.6%	1.3%	2%	5.73%

Table 9: Comparison of the Keros classification among different racial populations

	Type I	Type II	Type III
India - our study	17.5%	74.6%	7.9%
Germany - Keros ^[6]	12%	70%	18%
USA - Solares <i>et al.</i> ^[18]	83%	15%	2%
UK - Gauba <i>et al.</i> ^[19]	34.4%	28.1%	37.5%
Australia - Floreani <i>et al.</i> ^[20]	23%	50%	27%
Brazil - Souza <i>et al.</i> ^[21]	26.3%	73.3%	0.5%
Philippines - Justin Alfred <i>et al.</i> ^[9]	81.6%	17.9%	0.5%
Thailand - Nitinavakarn <i>et al.</i> ^[22]	11.9%	68.8%	19.3%

definition of asymmetry compared with other studies. But a majority (64.6%) only had a difference of ≤1 mm and only 10.1% had >2 mm difference between two sides [Table 5].

Among the subjects with asymmetry in our study, 51.3% had deeper OF on the right side and 48.7% on the left side [Table 6]. In the study by Pawar *et al.* also, right-sided OF was deeper than the left in males.^[14] But in the studies by Jacob *et al.* and Salroo *et al.*, OF was shallower on the right side.^[3,13] In the study by Satish Nair, 71.4% showed low fovea on the right and 28.6% on the left side.^[15] Similarly, Ali *et al.* observed asymmetry with 63.6% having low fovea on the right side and 36.4% on the left side.^[16]

In this study, 260 subjects (21.7%) showed different Keros type of OF on either sides [Table 7]. But in the study by Pawar *et al.*, asymmetry in the form of different Keros type was found only in 11.5% of patients.^[14] In the study by Jacob *et al.* in cadaveric skulls, significant difference was seen in the distribution of Keros types between the right and left sides.^[3]

Conclusion

Keros classification provides an objective assessment of anterior skull base anatomy and helps guide the surgeon

during FESS to improve the safety profile of the procedure. It will help in anticipating the complications that may be encountered during surgery. The surgical approach can thus be carefully planned and the expected complications can be prevented. The most prevalent type of OF among our study population was Keros type II. Even though the prevalence of the dangerous type III OF was low, it was more among males and on the right side, and hence more susceptible to iatrogenic injury. Therefore, preoperative assessment of OF depth must be done mandatorily to reduce operative complications.

Acknowledgements

Sincere gratitude is extended to all the faculty members of Jubilee Centre for Medical Research, JMMC and RI, for editing this article. The author thank Dr. Sreeraj and Mr. Unnikrishnan for their assistance in statistical analysis.

Financial support and sponsorship

Nil.

Conflicts of interest

There are no conflicts of interest.

References

- Erdem G, Erdem T, Miman MC, Ozturan O. A radiological anatomic study of the cribriform plate compared with constant structures. *Rhinology* 2004;42:225-9.
- Cashman EC, MacMahon PJ, Smyth D. Computed tomography scans of paranasal sinuses before functional endoscopic sinus surgery. *World J Radiol* 2011;3:199.
- Jacob TG, Kaul JM. Morphology of the olfactory fossa – A new look. *J Anatomic Soc India* 2014;63:30-5.
- Vaid S, Vaid N. Normal anatomy and anatomic variants of the paranasal sinuses on computed tomography. *Neuroimag Clin* 2015;25:527-48.
- Som PM, Lawson W, Fatterpekar GM, Zinreich J. Embryology, Anatomy, physiology and imaging of the sinonasal cavities. In: Som PM, Curtin HD, editors. *Head and neck imaging*. 5th ed. St. Louis, MO: Elsevier; 2011. p. 119-28.
- Keros P. On the practical value of differences in the level of the lamina cribrosa of the ethmoid. *Z Laryngol Rhinol Otol* 1962;41:809-13.
- Reddy UD, Dev B. Pictorial essay: Anatomical variations of paranasal sinuses on multidetector computed tomography – How does it help FESS surgeons? *Indian J Radiol Imag* 2012;22:317.
- Paber JE, Salvador M, Villarta R. Radiographic analysis of the ethmoid roof based on Keros classification among Filipinos. *Philipp J Otolaryngol Head Neck Surg* 2008;23:15-9.
- Savvateeva DM, Güldner C, Murthum T, Bien S, Teymoortash A, Werner JA, et al. Digital volume tomography (DVT) measurements of the olfactory cleft and olfactory fossa. *Acta Otolaryngol* 2010;130:398-404.
- Dessi P, Moulin G, Triglia JM, Zanaret M, Cannoni M. Difference in the height of the right and left ethmoidal roofs: A possible risk factor for ethmoidal surgery. Prospective study of 150 CT scans. *J Laryngol Otol* 1994;108:261-2.
- Hoang JK, Eastwood JD, Tebbit CL, Glastonbury CM. Multiplanar sinus CT: A systematic approach to imaging before functional endoscopic sinus surgery. *Am J Roentgenol* 2010;194:W527-36.
- IBM Corp. Released 2011. IBM SPSS Statistics for Windows, Version 20.0. Armonk, NY: IBM Corp.
- Salroo IN, Dar NH, Yousuf A, Lone KS. Computerised tomographic profile of ethmoid roof on basis of keros classification among ethnic Kashmiri's. *Int J Otorhinolaryngol Head Neck Surg* 2016;2:1-5.
- Pawar A, Konde S, Bhole P. Assessment of depth of olfactory fossa in pre-functional endoscopic sinus surgery computed tomography scan of paranasal sinuses. *Int J Otorhinolaryngol Head Neck Surg* 2017;4:83-6.
- Nair S. Importance of ethmoidal roof in endoscopic sinus surgery. *Sci Rep* 2012;1:1-3.
- Ali A, Kurien M, Shyamkumar NK. Anterior skull base: High risk areas in endoscopic sinus surgery in chronic rhinosinusitis: A computed tomographic analysis. *Indian J Otolaryngol Head Neck Surg* 2005;57:5-8.
- Gupta P, Ramesh P. Radiological observation of ethmoid roof on basis of keros classification and its application in endonasal surgery. *Int J Anat Res* 2017;5:4204-7.
- Solares CA, Lee WT, Batra PS, Citardi MJ. Lateral lamella of the cribriform plate: Software-enabled computed tomographic analysis and its clinical relevance in skull base surgery. *Arch Otolaryngol Head Neck Surg* 2008;134:285-9.
- Gauba V, Saleh GM, Dua G, Agarwal S, Ell S, Vize C. Radiological classification of anterior skull base anatomy prior to performing medial orbital wall decompression. *Orbit* 2006;25:93-6.
- Floreani SR, Nair SB, Switajewski MC, Wormald PJ. Endoscopic anterior ethmoidal artery ligation: A cadaver study. *Laryngoscope* 2006;116:1263-7.
- Souza SA, Souza MM, Idagawa M, Wolosker AM, Ajzen SA. Computed tomography assessment of the ethmoid roof: A relevant region at risk in endoscopic sinus surgery. *Radiol Bras* 2008;41:143-7.
- Nitinavakarn B, Thanaviratnanich S, Sangsilp N. Anatomical variations of the lateral nasal wall and paranasal sinuses: A CT study for endoscopic sinus surgery (ESS) in Thai patients. *J Med Assoc Thai* 2005;88:763-8.