

# Four Generations of Rare Familial Lymphedema (Milroy Disease)

Sankalp Gokhale<sup>a</sup> Sanjay Gokhale<sup>b</sup>

<sup>a</sup>Department of Neurology, Duke University School of Medicine, Durham, N.C., USA; <sup>b</sup>Department of Pediatrics and Family Practice, Rajhans Hospital, Saphale, India

## Key Words

Lymphedema · Familial condition · Milroy disease

## Abstract

**Objective:** To report a rare case of familial lymphedema (Milroy disease) affecting 4 generations of individuals. **Clinical Presentation and Intervention:** A 28-year-old woman presented with bilateral pedal edema which she had since birth. A detailed evaluation including blood counts, metabolic panel and imaging studies ruled out secondary causes of lymphedema. The family history revealed many affected individuals up to 4 generations. She was reassured about the potential benign yet familial nature of this condition. She was advised to wear compression stockings and to avoid scratches or skin breakdowns in the lower extremities to prevent cellulitis. **Conclusion:** This case showed the occurrence of asymptomatic progressive lymphedema in 4 generations of individuals.

Copyright © 2013 S. Karger AG, Basel

## Introduction

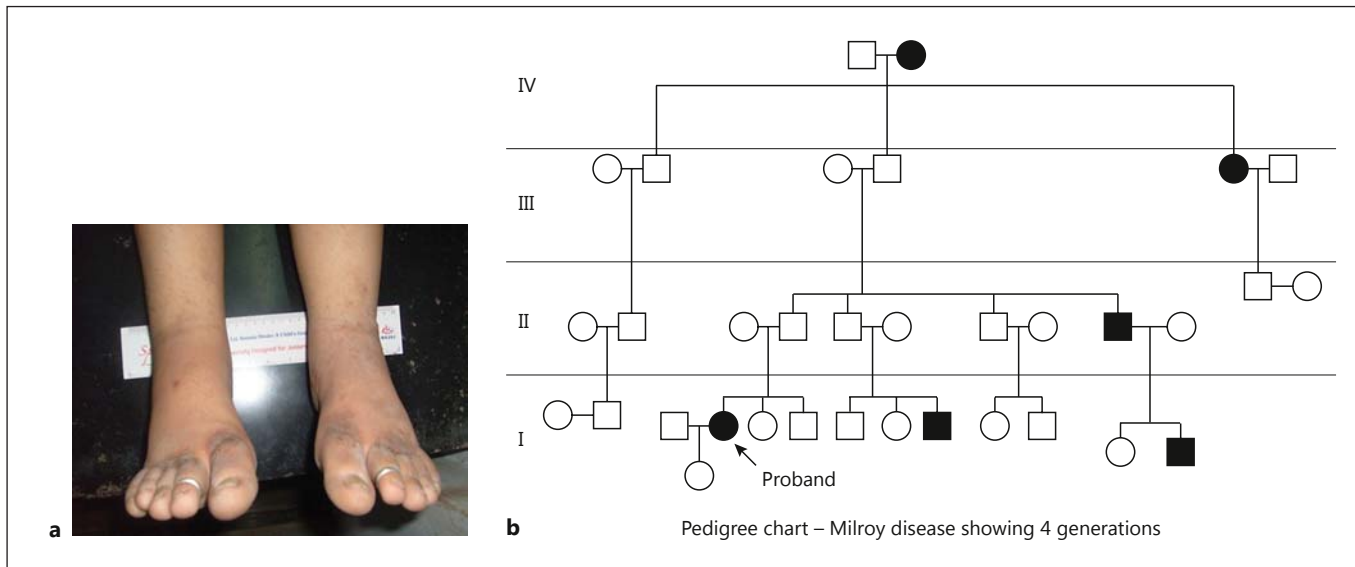
Lymphedema is a form of chronic tissue swelling due to impaired lymphatic drainage, often presenting as pedal swelling. There are congenital forms of lymphedema,

which are uncommon [1]. We report a case of Milroy disease, a rare cause of congenital lymphedema. It is a familial condition with a strong genetic predisposition. This is the first reported case with 4 generations of family members being affected.

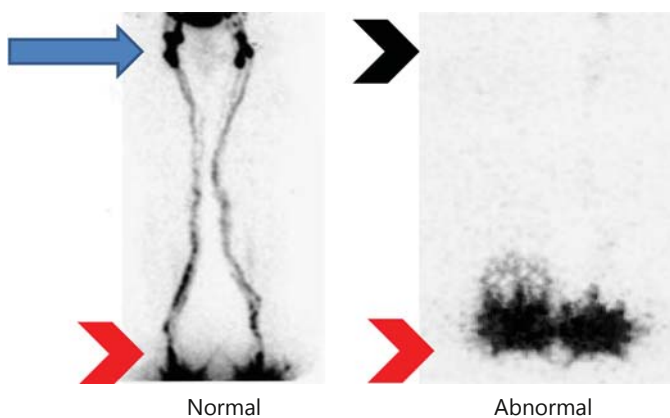
## Case Report

A 28-year-old woman presented for evaluation of painless swelling involving both lower extremities since birth. The swelling had been gradually progressive, initially affecting her feet but then involving calves, shin and lower thighs. She was noted to have painless swelling of both feet in her infancy. The swelling was prominent and involved calves and shin at the age of 10 years. During adolescence and early adulthood the swelling involved her lower thighs. The swelling was symmetric and equal in both lower extremities. Other than swelling, she did not have any other symptoms such as a history of weight loss or other constitutional symptoms. Her past medical history was unremarkable. She denied tobacco or alcohol use. She did not have known medication allergies. She had been evaluated by a few providers in the past without definitive diagnosis.

Physical examination revealed a normal-appearing young lady. She was afebrile with a heart rate of 70/min. Blood pressure was 116/76 mm Hg. Respiratory rate was 14/min. General examination revealed bilateral nonpitting pedal edema up to mid calves (fig. 1a). Otherwise, examination was normal, with no evidence of ascites, abdominal organ or lymph node enlargement. She did not have any cardiac murmurs or decreased air entry on chest examination.



**Fig. 1. a** Photograph of the proband case with bilateral pedal edema. **b** Family pedigree showing affected individuals (arrow showing the proband case).



**Fig. 2.** Anterior lymphoscintigram obtained 1 h after the injection of radionuclide distally in the feet (bottom arrowheads). Left panel shows a normal study with a symmetric uptake in the ilioinguinal lymph nodes (arrow). Right panel shows an abnormal study with little or no lymphatic drainage (uptake) in the proximal inguinal lymph nodes (top arrowhead), suggestive of failure of lymphatic drainage, as in our patient.

She underwent detailed investigations to evaluate for the possible etiology of pedal swelling. A complete blood cell count, including a differential count, and basic metabolic profile, including renal function, was normal. Liver function tests including serum albumin and inflammatory markers such as sedimentation rate and C-reactive protein were unremarkable. An ultrasound of the

lower extremities including Doppler did not show evidence of venous obstruction. Chest X-ray and an ultrasound of the abdomen and pelvis were normal. The patient underwent a radionuclide study (lymphoscintigraphy) to evaluate lymphatic drainage in the lower extremities. There was evidence of decreased uptake of radioactive tracer in proximal lymph nodes (inguinal nodes), suggesting impaired lymphatic drainage in the lower extremities (fig. 2). Genetic counseling and specialized testing were discussed. Genetic testing was not possible due to lack of availability and financial resources.

After reviewing her family history, she mentioned that a few of her family members had similar symptoms. None of them had any other associated symptom other than asymptomatic bilateral pedal edema. A detailed family pedigree was charted, as far as the 4th generation (fig. 1b). Available medical records were reviewed for the majority of the family members affected. This information is summarized in table 1.

Based on the clinical presentation, the strongly positive family history and the lymphoscintigraphy study, a diagnosis of familial congenital primary lymphedema (Milroy disease) was made.

This is a very rare condition with less than 200 cases reported in the literature so far. To the best of our knowledge, this is the first report of 4 generations of family members with Milroy disease.

### Discussion

This was a case of the occurrence of lymphedema in multiple family members as shown in table 1. By early adulthood, almost all the family members had lymphede-

**Table 1.** Clinical details of family members

Serial No.	Subject	Age years/gender	Age at onset	Clinical details	Lymphoscintigraphy
1	proband	28/F	infancy	symmetric progressive swelling of lower limbs	decreased/no uptake in inguinal nodes
2	paternal cousin	18/M	2 years	swelling started in left lower limb at age 2, progressive to involve both lower limbs up to calves by age 12	N/A
3	paternal cousin	22/M	shortly after birth	symmetric progressive swelling of lower limbs up to shins	N/A
4	paternal uncle	43/M	birth	symmetric progressive swelling of lower limbs confined to feet and lower shins	N/A
5	paternal grandfather's sister (paternal grandaunt)	68/F	birth	asymmetric to begin with (unsure which limb first), progressed to involve mid thighs by her 30s and static since; has had few episodes of cellulitis of lower limbs	N/A
6	paternal great grandmother	91/F	infancy	symmetric progressive swelling of lower limbs up to calves, asymptomatic	N/A

ma up to the shin or calves. However, there are a few interesting observations. There is some variability in phenotypic expression. Two of the 6 family members had asymmetric onset of edema. In due course of progression, the swelling was more or less bilateral and symmetric in these subjects. Also, there is variability in the degree and severity of lymphedema, as noted in table 1 (subject 6 had a milder form of phenotypic expression whereas proband and subject 5 had a moderate-to-severe form of phenotypic expression). The minimal-to-no uptake of radioactive tracer in proximal lymph nodes in proband indicates 'functional' failure of lymphatic channels in the lower extremities similar to observations made by Raffa et al. [1]. Of a family of individuals with congenital lymphedema (Milroy disease), a similar observation was made by Micheli et al. [2], where genetic testing revealed a wide spectrum of involved genes in pathophysiology (unlike our case where genetic testing was not done). Few of the implicated mutations were in the *fms*-related tyrosine kinase 4 (*FLT4*) gene and forkhead box C2 (*FOXC2*) gene [2]. There is increasing evidence to support the role of vascular endothelial growth factor receptor-3 (*VEGF-3*) as an important genetic mutation, in addition to those described above [3]. The primary defect is thought to be the altered microarchitecture and function of small lymphatics causing impaired absorption of lymphatic

fluid, accumulation in interstitial space and, thus, swelling [4, 5].

As discussed previously, it is of paramount importance to exclude other causes of secondary lymphedema before making the diagnosis of primary lymphedema. The important secondary causes include infections (filariasis), obstruction from a proximal mass such as intraabdominal tumor or postradiation lymphatic obstruction seen in patients undergoing radiation therapy for treatment of cancers. Primary lymphedema presenting at birth is Milroy disease, unlike Meigs syndrome and lymphedema tarda which present at a later age [6, 7]. Connell et al. [8] have recently proposed a comprehensive classification of primary lymphedema. The authors have stressed the importance of thorough clinical evaluation and identifying meticulous phenotypic patterns to guide molecular testing in subjects with primary lymphedema [8].

Milroy disease constitutes less than 10% of primary lymphedema cases, with less than 200 cases reported in the literature [7]. There is a genetic predisposition as discussed previously. Examination of patients with Milroy disease by lymphoscintigraphy has demonstrated a high rate of functional failure of the lymphatic system rather than absent lymphatic system as thought before. As mentioned earlier, almost all the subjects are affected at birth,

with strong family history. The other associated symptoms are large caliber leg veins, papillomatosis, toenail abnormalities, and hydrocele in men [4, 6]. The main consequences of lymphatic failure are swelling, recurrent infection such as cellulitis and, very rarely, a malignant transformation to lymphangiosarcoma [9].

## Conclusion

This case showed the occurrence of asymptomatic progressive lymphedema in 4 generations of individuals. Further, our case underlines the importance of a detailed family history as part of the evaluation of any patient.

## References

- 1 Raffa V, Campra D, Guarino R, et al: Congenital Milroy oedema: a case report of a family (in Italian). *Pediatr Med Chir* 2012;34:100–103.
- 2 Michelini S, Degiorgio D, Cestari M, et al: Clinical and genetic study of 46 Italian patients with primary lymphedema. *Lymphology* 2012;45:3–12.
- 3 Brice G, Child AH, Evans A, et al: Milroy disease and the VEGFR-3 mutation phenotype. *J Med Genet* 2005;42:98–102.
- 4 Moffatt CJ, Murray SG: The experience of children and families with lymphedema – a journey within a journey. *Int Wound J* 2010;7:14–26.
- 5 Butler MG, Dagenais SL, Rockson SG, et al: A novel VEGFR3 mutation causes Milroy disease. *Am J Med Genet A*. 2007;143A:1212–1217.
- 6 Northup KA, Witte MH, Witte CL: Syndromic classification of hereditary lymphedema. *Lymphology* 2003;36:162–189.
- 7 Kitsiou-Tzeli S, Vrettou C, Leze E, et al: Milroy's primary congenital lymphedema in a male infant and review of the literature. *In Vivo* 2010;24:309–314.
- 8 Connell F, Brice G, Jeffery S, et al: A new classification system for primary lymphatic dysplasias based on phenotype. *Clin Genet* 2010;77:438–452.
- 9 Anderson HC, Parry DM, Mulvihill JJ: Lymphangiosarcoma in late-onset hereditary lymphedema: case report and nosological implications. *Am J Med Genet* 1995;56:72–75.