




Letter to the Editor

Favipiravir-induced Liver Injury in Patients with Coronavirus Disease 2019

Pramod Kumar^{1*} , Anand Kulkarni¹, Mithun Sharma¹, Padaki Nagaraja Rao¹ and Duvvuru Nageshwar Reddy²

¹Department of Hepatology and Liver Transplantation, Asian Institute of Gastroenterology Hospitals, Hyderabad, India; ²Department of Gastroenterology, Asian Institute of Gastroenterology Hospitals, Hyderabad, India

Received: 4 January 2021 | Revised: 10 March 2021 | Accepted: 23 March 2021 | Published: 15 April 2021

Citation of this article: Kumar P, Kulkarni A, Sharma M, Rao PN, Reddy DN. Favipiravir-induced liver injury in patients with coronavirus disease 2019. *J Clin Transl Hepatol* 2021;9(2):276–278. doi: 10.14218/JCTH.2021.00011.

Favipiravir, an antiviral, was given restricted emergency use approval to treat coronavirus disease 2019 (COVID-19) in many countries. While the clinical efficacy of favipiravir in COVID-19 remains uncertain, the approval was based on findings from *in vitro* studies and a clinical trial.¹ Limited data from studies of the Ebola virus and influenza disease showed a favorable safety profile.² Herein, we provide the first report of drug-induced liver injury (DILI) due to favipiravir in patients treated for COVID-19.

The first patient is a 70-year-old female who presented with 4 days of abdominal pain and jaundice. Historically, she received tab Favipiravir for mild COVID-19 illness for 2 weeks. She denied having taken any other medications or herbal supplements, or alcohol intake. She was icteric, and laboratory evaluation revealed a cholestatic liver chemistry pattern (Table 1). Hepatitis A/B/C/E serologies, autoimmune markers, ceruloplasmin, and serologies for Epstein-Barr/Herpes simplex/cytomegalovirus, hepatic Doppler ultrasound were all negative/normal. A percutaneous liver biopsy showed moderate hepatocellular cholestasis with bilirubinostasis and mild inflammation comprised of lymphocytes with few eosinophils in the portal tracts (Fig. 1). The patient was treated with ursodeoxycholic acid (15 mg/kg), and liver biochemistry normalized after 10 weeks. In the absence of other etiologies, bland cholestasis on liver biopsy, and Rousset Uclaf causality assessment method (RUCAM) score of 7, consistent with probable DILI, the diagnosis of favipiravir-induced acute cholestatic jaundice was made.

The second patient is a 52-year-old female with essential hypertension, who presented with 5 days of jaundice and fatigue. She was treated with 12 days of tab favipiravir for mild COVID-19 illness. Aside from tablet paracetamol, the patient cited not taking any other medications or alcohol. Laboratory evaluation revealed markedly elevated liver enzymes, and workup for other causes of liver injury, as

described previously, were negative (Table 1). The patient denied a liver biopsy and was treated with ursodeoxycholic acid (15 mg/kg). The patient made an uneventful recovery, and liver chemistries normalized after 4 weeks. Diagnosis of favipiravir-induced acute hepatitis was made with a RUCAM score of 7, consistent with probable DILI.

The third patient is a 50-year-old male with hepatitis B-related cirrhosis on tab entecavir, who presented with a 2-week history of abdominal distension and jaundice. The patient received tab favipiravir for 2 weeks for mild COVID-19 illness. The patient denied having taken any other medications or alcohol. The evaluation showed cholestatic liver chemistry, with a negative hepatitis B DNA titer. A computerized tomography scan showed evidence of cirrhosis with portal hypertension (Table 1). Workup for other causes of liver injury, as described for the first case, was negative. The patient was managed with diuretics, ursodeoxycholic acid, and other supportive medication. His symptoms and liver chemistries improved over the next 6 weeks. The diagnosis of acute decompensation of hepatitis B-related cirrhosis with acute cholestatic jaundice due to favipiravir was made with a RUCAM score of 7, consistent with probable DILI.

The unprecedented COVID-19 global pandemic has led to the rapid repurposing of investigational antiviral drugs, like favipiravir. The oral prodrug favipiravir is a purine nucleoside analogue; the active metabolite favipiravir ibofuransyl-5'-triphosphate inhibits RNA-dependent RNA polymerases of systemic acute respiratory syndrome coronavirus-2 (SARS-CoV-2).³ It is metabolized in the liver by aldehyde oxidase and partially to a hydroxylated form by xanthine oxidase. Mild self-limiting transaminase elevation was reported in 2.1% of patients.^{2,4} However, icteric presentation has never been reported in the English literature, to our knowledge. We suspected favipiravir-induced DILI in our cases because of latency timing, liver biopsy findings, exclusion of alternative causes, and a complete resolution with dechallenge. Liver enzyme abnormalities are also common in patients with COVID-19 and rarely progress to acute hepatitis. However, our patient's delayed presentation after COVID-19-related symptom resolution and normal liver biochemistry at baseline rule out this possibility. Although the exact mechanism of liver injury is unknown, the liver injury could be due to an idiosyncratic reaction to favipiravir or its metabolites. Also, we speculate that a higher dose might be responsible for liver injury. The wide gap between half-cytotoxic concentration (>400 µM) and half-maximal effective concentration (61.88 µM) against SARS-CoV-2 gives a comfortable safety margin, even with a high dose of favipiravir.³ However, an increased intracellular con-

Abbreviations: COVID-19, coronavirus disease 2019; DILI, drug-induced liver injury; RUCAM, Rousset Uclaf causality assessment method; SARS-CoV-2, systemic acute respiratory syndrome coronavirus-2.

***Correspondence to:** Pramod Kumar, Department of Hepatology and Liver Transplantation, Asian Institute of Gastroenterology Hospitals, Survey No 136, Mindspace Rd, Gachibowli, Hyderabad, Telangana 500032, India. ORCID: <https://orcid.org/0000-0002-1073-6295>. Tel: +91-98-1493-3544, E-mail: dapramod@gmail.com

Table 1. Laboratory findings at presentation for the patients with favipiravir-induced liver injury

Parameter	Patient 1	Patient 2	Patient 3
Hemoglobin in g/dL	9.6	12.6	12.2
Total leucocyte count/ μ L	10,500	11,900	5,000
Differential count, %	N68/L26/E2/M4	N84/L8/E1/M7	N64/L24/E4/M8
Platelets/ μ L $\times 10^3$	3.3	2	1.4
Urea in mg/dL	42	40	45
Creatinine in mg/dL	1.4	0.9	1.1
Total /direct bilirubin in mg/dL	29.8/21	12.5/9.3	4.7/2.7
Aspartate transaminase <40 U/L	200	1,265	456
Alanine transaminase <40 U/L	352	2,031	337
Alkaline phosphatase 30-120 U/L	606	362	804
Protein in g/dL	5.2	6.2	5.3
Albumin in g/dL	3.5	3.8	2.8
International normalized ratio	1.2	1	1.1
Hospitalization	Yes	Yes	Yes
Liver chemistry before starting tab favipiravir	Normal	Normal	Normal
Liver injury pattern	Cholestatic	Hepatocellular	Cholestatic
Latency period in days	18 days	12 days	14 days
Favipiravir dose & duration	3,600 mg on day 1 followed by 1,600 mg/day for 14 days	3,600 mg on day 1 followed by 1,600 mg/day for 12 days	3,600 mg on day 1 followed by 1,600 mg/day for 10 days
RUCAM score	7: Probable DILI	7: Probable DILI	7: Probable DILI
DILI severity index	Moderate-severe	Moderate-severe	Moderate-severe
Outcome	Resolution 10 weeks	Resolution 4 weeks	Resolution 6 weeks

DILI, Drug induced liver injury; NA, Not available; RUCAM, Roussel Uclaf causality assessment method.

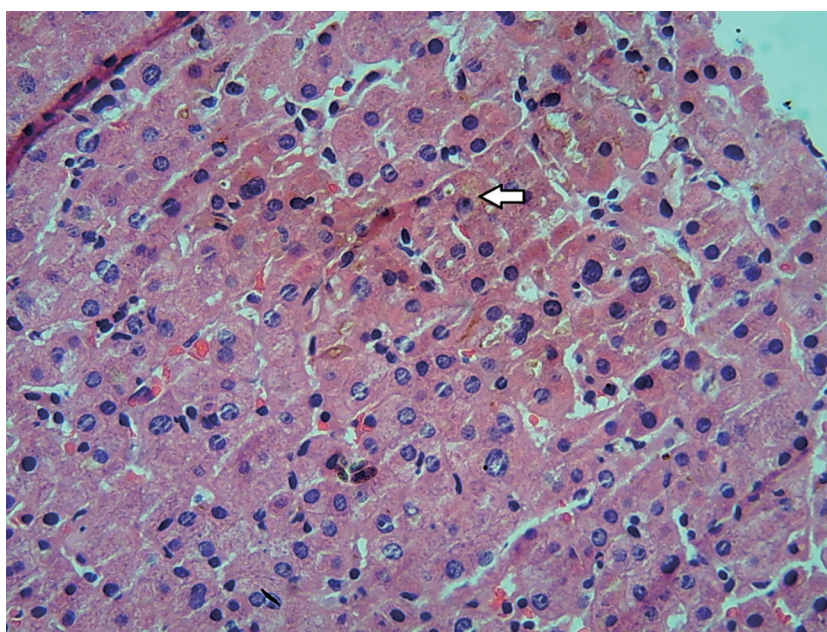


Fig. 1. Liver biopsy with a high-power view of moderate hepatocellular cholestasis (white arrow) with bilirubinostasis.

centration above the toxicity threshold cannot be ruled out owing to more considerable favipiravir plasma exposure in the Asian population, suggesting possible regional or ethnic differences in its pharmacokinetics.^{3,5} Besides, continuous use causes self-inhibition of its liver metabolism, which may increase the favipiravir/inactive metabolite ratio. More than a two-fold increase in favipiravir plasma concentrations over half-maximal effective concentration are also predicted.⁶ So, close monitoring of cardiac and hepatic function as well as of favipiravir blood concentration is recommended during the treatment period because of a lack of pharmacokinetics and safety data for higher doses.

In conclusion, we present the first report of hepatotoxicity cases in COVID-19 that were most likely due to favipiravir. Further research is needed to identify the related risk factors and mechanisms of liver injury.

Acknowledgments

We thank Dr. Gautam Bachu, Department of Pulmonary Medicine, Dr. Mohan Ramchandani, Department of Gastroenterology, and Dr. Anuradha, Department of Pathology, Asian Institute of Gastroenterology Hospitals, Hyderabad, India.

Funding

None to declare.

Conflict of interest

The authors have no conflict of interests related to this pub-

lication.

Author contributions

Study conception and design (PK, AK), compilation of information and initial drafting of the manuscript (PK), final editing and critical revision of the manuscript (PK, MS, AK, PNR, DNR). All authors approved the final draft.

Informed patient consent

Provided by all patients presented in this report.

References

- [1] Cai Q, Yang M, Liu D, Chen J, Shu D, Xia J, *et al*. Experimental treatment with favipiravir for COVID-19: an open-label control study. *Engineering (Beijing)* 2020;6(10):1192–1198. doi:10.1016/j.eng.2020.03.007.
- [2] Pilkington V, Pepperrell T, Hill A. A review of the safety of favipiravir - a potential treatment in the COVID-19 pandemic? *J Virus Erad* 2020;6(2):45–51. doi:10.1016/S2055-6640(20)30016-9.
- [3] Du YX, Chen XP. Favipiravir: pharmacokinetics and concerns about clinical trials for 2019-nCoV infection. *Clin Pharmacol Ther* 2020;108(2):242–247. doi:10.1002/cpt.1844.
- [4] Ivashchenko AA, Dmitriev KA, Vostokova NV, Azarova VN, Blinow AA, Egorova AN, *et al*. AVIFAVIR for treatment of patients with moderate COVID-19: interim results of a phase II/III multicenter randomized clinical trial. *Clin Infect Dis* 2020:ciaa1176. doi:10.1093/cid/ciaa1176.
- [5] Eloy P, Solas C, Touret F, Mentré F, Malvy D, de Lamballerie X, *et al*. Dose rationale for favipiravir use in patients infected with SARS-CoV-2. *Clin Pharmacol Ther* 2020;108(2):188. doi:10.1002/cpt.1877.
- [6] Arshad U, Pertinez H, Box H, Tatham L, Rajoli RKR, Curley P, *et al*. Prioritization of anti-SARS-Cov-2 drug repurposing opportunities based on plasma and target site concentrations derived from their established human pharmacokinetics. *Clin Pharmacol Ther* 2020;108(4):775–790. doi:10.1002/cpt.1909.