

Staphylococcus hominis carotid artery infection with septic embolization

Kirsten Dansey, BS, Lee Stratton, BS, and Brian D. Park, MD, Tampa, Fla

We present the case report of a *Staphylococcus hominis* carotid artery plaque infection, without mycotic aneurysm formation, that provided the nidus for septic embolization. The patient presented with transient neurologic symptoms, with no clinical signs or symptoms of sepsis. Multiple preoperative imaging modalities revealed critical carotid stenosis but no indication of an infection. Secondary carotid infection was discovered incidentally intraoperatively, and carotid reconstruction was completed with autogenous tissue. The patient transiently manifested sepsis only after the carotid reconstruction and recovered with the institution of parenteral antibiotics. (J Vasc Surg Cases 2015;1:81-3.)

Carotid artery infections are uncommon and generally manifest as mycotic aneurysms with signs and symptoms of sepsis. These mycotic aneurysms have the potential to cause septic embolization.¹⁻⁴ We present a report of a *Staphylococcus hominis* internal carotid artery (ICA) plaque infection with septic embolization. Consent for publications of this case report was obtained from the patient's family.

CASE REPORT

A 74-year-old man presented to the emergency department with 4 hours of left hemiplegia and dysarthria. He denied fever, chills, or neck pain. His history was significant for hypertension and type 2 diabetes mellitus. He denied illicit drug use. His neurologic symptoms completely resolved several hours after admission.

A computed tomography (CT) scan of the brain was negative. A subsequent carotid duplex assessment revealed >80% stenosis in the right ICA (Fig 1), which was also confirmed by a magnetic resonance angiogram (MRA; Fig 2). Neither the carotid duplex scan nor the MRA demonstrated any evidence of infection. Results of a magnetic resonance imaging scan were consistent with right-sided small acute-to-subacute infarcts (Fig 3). A CT angiography of the neck was deferred because the carotid duplex and MRA corroborated critical right ICA stenosis.

The patient was evaluated by vascular surgery, and a right carotid endarterectomy (CEA) was recommended. Preoperative risk stratification was completed by cardiology because the patient had resolved neurologic symptoms but had reported several

months of angina and dyspnea. An echocardiogram showed an undiagnosed decreased systolic ejection fraction (35%-40%) and critical aortic stenosis (valve area 0.9 cm² with a gradient of 36 mm Hg). The patient subsequently underwent cardiac catheterization with stenting of a 99% stenosis of the left circumflex artery.

The patient underwent CEA with plans for patch angioplasty the day after the cardiac catheterization and 3 days after admission. Aspirin (81 mg; Bayer AG, Leverkusen, Germany) and clopidogrel (75 mg; Bristol-Myers Squibb, New York, NY) were continued preoperatively. During the initial dissection, there were no findings of infection. After the carotid arteriotomy, purulent material was expressed from the plaque. Gram stains revealed gram-positive rods and cocci. Additional intravenous vancomycin (Shire Pharmaceuticals, Dublin, Ireland) and Zosyn (Pfizer Inc, New York, NY) were given.

Only the carotid plaque was friable and infiltrated with purulence. Once the CEA had been completed, it was clear that the infection only involved the intima. Patch angioplasty was completed with great saphenous vein because further débridement and resection of the artery were not required. The patient awoke neurologically intact.

Postoperatively, the patient had a leukocytosis ($15.3 \times 10^3/\mu\text{L}$), was hypotensive, and oliguric. He received aggressive fluid resuscitation, and norepinephrine (Hospira Inc, Lake Forrest, Ill) was started. By the next day, the patient was normotensive and pressors were weaned. His leukocytosis also resolved. Blood cultures, a transesophageal echocardiogram (TEE), and chest, abdomen, and pelvis CT scans were ordered to determine a source for the infection. The TEE did not demonstrate any findings suggestive of endocarditis. The blood cultures and CT scans were negative for a septic source. The tissue cultures from the plaque speciated *S hominis* (subspecies *hominis*). The final pathology results of the carotid plaque indicated moderate calcification and no evidence of microabscesses extending into the media.

The patient had no manifestations of sepsis postoperatively and was discharged on postoperative day 5. Intravenous vancomycin and Zosyn were continued for 6 weeks of total treatment, as recommended by the infectious disease specialists.

The patient was seen 2 weeks after discharge and was doing well, with no further neurologic symptoms and no wound infection. He was scheduled for further follow-up, but we were notified

From the Division of Vascular and Endovascular Surgery, Department of Surgery, The University of South Florida.

Author conflict of interest: none.

Reprint requests: Brian D. Park, MD, Division of Vascular and Endovascular Surgery, Department of Surgery, The University of South Florida, 2 Tampa General Cir, STC 7012, Tampa, FL 33606 (e-mail: bpark@health.usf.edu).

The editors and reviewers of this article have no relevant financial relationships to disclose per the Journal policy that requires reviewers to decline review of any manuscript for which they may have a conflict of interest.

2352-667X

Copyright © 2015 The Authors. Published by Elsevier Inc. on behalf of the Society for Vascular Surgery. This is an open access article under the CC BY-NC-ND license (<http://creativecommons.org/licenses/by-nc-nd/4.0/>).

<http://dx.doi.org/10.1016/j.jvsc.2015.03.001>

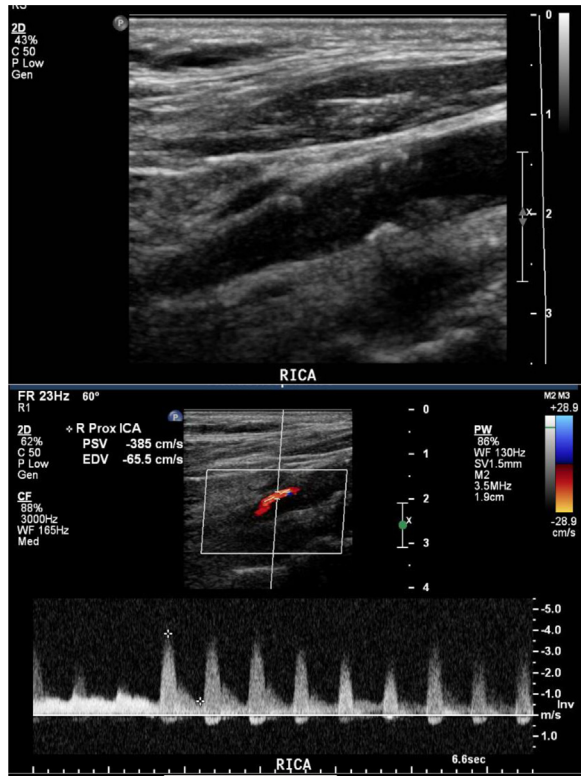

Fig 1. A carotid duplex scan indicated critical right internal carotid artery (ICA) stenosis but no indication of abscess or carotid infection.

that he had suddenly died at home 4 months after surgery. The patient had reportedly recovered to his baseline status and suddenly collapsed. He was pronounced dead at the scene, and autopsy was declined.

DISCUSSION

This is the first case report that describes a *S hominis* carotid plaque infection with septic embolization resulting in neurologic symptoms. No signs or symptoms of sepsis were present until the carotid reconstruction was completed. In this patient, TEE and CT scans of the chest, abdomen, and pelvis were negative for a source of infection. An examination failed to demonstrate any cutaneous infections, and results of blood cultures were negative. Only tissue cultures were positive for infection.

Infections involving the carotid arteries are exceedingly rare, and these cases uniformly involve mycotic aneurysms. Recent literature reviews regarding carotid mycotic aneurysms have identified only 99 cases to date.^{2,5,6} None of these reports documented a secondary carotid plaque infection with septic emboli, without evidence of mycotic aneurysm. The most common pathogens are *S aureus* and *Streptococcus pyogenes*. Additional cases of more indolent *Staphylococcus* spp have also been reported.⁵ Bacterial seeding of aortic and common femoral artery plaques has been reported,^{7,8} but to our knowledge, there are no reports of

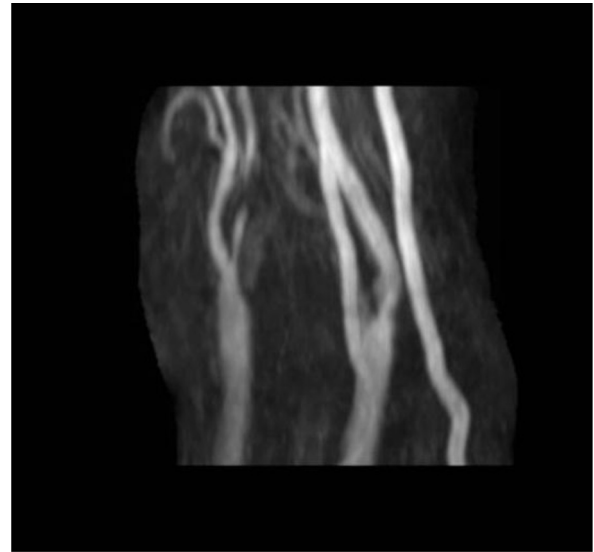


Fig 2. A magnetic resonance angiogram (MRA) indicated critical right internal carotid artery (ICA) stenosis but no indication of abscess or carotid infection.

carotid plaque infections without pseudoaneurysms. The scarcity of these cases makes it difficult to determine if more recently isolated pathogens, such as *S hominis*, are changing the clinical presentation of these infections.

S hominis (subspecies *hominis*) was first isolated in 1975 and occurs in higher concentrations in the axilla and groin.⁹ *S hominis* has been reported in blood cultures but is considered a contaminant or opportunistic infection.¹⁰ However, some strains have been shown to be resistant to an impressive list of antibiotics, including penicillin, oxacillin, methicillin, kanamycin, gentamicin, streptomycin, tetracycline, erythromycin, clindamycin, chloramphenicol, trimethoprim/sulfamethoxazole, and ciprofloxacin. *S hominis* subjected to antibiotics in cultures will manifest multidrug resistance.¹¹ More virulent strains of *S hominis* (new subspecies *novobiosepticus*) have recently been identified.¹¹ What remains unknown is what role these seemingly indolent pathogens will play in future infections.

This patient was diabetic, which does represent a form of immunocompromise. However, his initial WBC count was $7.3 \times 10^3/\mu\text{L}$. His differential indicated a moderate elevation of neutrophils (70%). Human immunodeficiency virus and hepatitis B and C panels were negative. His HbA_{1c} was 7.1, and his admission blood glucose was 147 mg/dL, which indicated good glycemic control. The patient did undergo a cardiac catheterization, which could have potentially caused bacteremia that seeded the plaque. However, the patient exhibited neurologic symptoms long before the cardiac catheterization.

Treatment principles for infected carotid artery lesions entail reducing the risk of adverse neurologic events, elimination of the source of these infections, long-term antibiotic therapy to prevent recurrent infection, and comprehensive diagnostics to determine the primary

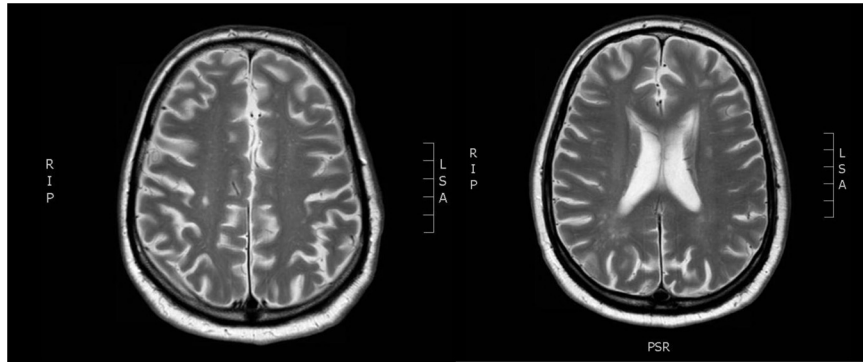


Fig 3. Magnetic resonance imaging scan of the brain was consistent with right parietal and occipital lobe small acute-to-subacute ischemic infarcts.

infectious source.^{2,5,12} Patients with neurologic symptoms or impending carotid rupture require urgent surgical repair. Upon encountering a carotid infection, arterial reconstruction with autogenous tissue that is resistant to subsequent infection is required. Long-term therapy with broad-spectrum antibiotics based on culture-specific sensitivities is recommended. The duration of treatment is a minimum of 6 weeks, with some reports of treatment up to 6 months.^{3,13,14}

CONCLUSIONS

Secondary infections of carotid artery plaques are a rare clinical entity associated with a high morbidity and mortality. The rise of newer, more indolent pathogens, such as *S hominis*, may give rise to more subtle clinical presentations. However, reconstruction strategies require local infection control and restoration of the cerebral circulation with autogenous conduits. In addition, long-term antibiotic therapy is recommended to prevent local recurrence.

REFERENCES

1. Katsenis C, Kouskouni E, Kolokotronis L, Rizos D, Dimakakos P. The significance of Chlamydia pneumoniae in symptomatic carotid stenosis. *Angiology* 2001;52:615-9.
2. O'Connell JB, Darcy S, Reil T. Extracranial internal carotid artery mycotic aneurysm: case report and review. *Vasc Endovascular Surg* 2009;43:410-5.
3. Papadoulas S, Zampakis P, Laimis A, Dimopoulos PA, Tsokalis IA. Mycotic aneurysm of the internal carotid artery presenting with multiple cerebral septic emboli. *Vascular* 2007;15:215-20.

4. Mandell GL, Bennett JE, Dolin R, editors. *Mandell, Douglas, Bennett's principles and practice of infectious diseases*. 7th ed. Philadelphia: Churchill Livingstone Elsevier; 2010. p. 1023-7.
5. Knouse MC, Madeira RG, Celani VJ. Pseudomonas aeruginosa causing a right carotid artery mycotic aneurysm after a dental extraction procedure. *Mayo Clin Proc* 2002;77:1125-30.
6. Amano M, Ishikawa E, Kujiraoka Y, Watanabe S, Ashizawa K, Oguni E, et al. Vernet's syndrome caused by large mycotic aneurysm of the extracranial internal carotid artery after acute otitis media-case report. *Neurol Med Chir* 2010;50:45-8.
7. Bul M, Reichart M, Balm R. Rupture of a non-dilated abdominal aorta due to Brucella melitensis. *Eur J Vasc Surg* 2007;34:622.
8. Tashtoush B, Gonzalez-Ibarra F, Abed M. Mycotic pseudoaneurysm of the femoral artery in a patient with psoriasis. *Intern Med* 2012;51:2831-4.
9. Kloos WE, Schleifer KH. Isolation and characterization of staphylococci from human skin. Description of four new species: Staphylococcus warneri, Staphylococcus capitis, Staphylococcus hominis, and Staphylococcus simulans. *Int J Syst Bacteriol* 1975;25:62-79.
10. Kloos WE, Bannerman TL. Update on clinical significance of coagulase-negative staphylococci. *Clin Microbiol Rev* 1994;7:117-40.
11. Kloos WE, George CG, Olgiate JS, Van Pelt L, McKinnon ML, Zimmer BL, et al. Staphylococcus hominis subsp. novobiosepticus subsp. nov., a novel trehalose- and N-acetyl-D-glucosamine-negative, novobiocin- and multiple-antibiotic-resistant subspecies isolated from human blood cultures. *Int J Syst Bacteriol* 1998;48:799-812.
12. Pirvu A, Bouchet C, Garibotti FM, Hauptert S, Sessa C. Mycotic aneurysm of the internal carotid artery. *Ann Vasc Surg* 2013;27:826-30.
13. Grossi RJ, Onofrey D, Tventenstrand C, Blumenthal J. Mycotic carotid aneurysm. *J Vasc Surg* 1987;6:81-3.
14. Hot A, Mazighi M, Lecuit M, Poiree S, Viard JP, Loulergue P, et al. Fungal internal carotid artery aneurysms: successful embolization of an Aspergillus-associated case and review. *Clin Infect Dis* 2007;45:e156-61.

Submitted Jan 14, 2015; accepted Mar 1, 2015.