

Tongue Abscess: A Case Report

Telila Mesfin¹, Gosaye Debele², Kenbon Seyoum³, Sisay Dadi⁴, Mesfin Tsegaye¹, Degefa Gomora³, Chala Kene³, Gudisa Tolosa¹

¹Department of Medicine, Madda Walabu University Goba General Hospital, Goba, Ethiopia; ²Department of Surgery, Madda Walabu University Goba General Hospital, Goba, Ethiopia; ³Department of Midwifery, Madda Walabu University Goba General Hospital, Goba, Ethiopia; ⁴Department of Internal Medicine, Madda Walabu University Goba General Hospital, Goba, Ethiopia

Correspondence: Telila Mesfin, Tel +251931504321, Email telilamesfintadesse@gmail.com

Introduction: Abscess of the tongue is a very rare disease that potentially compromises the airway. Acute tongue abscess symptoms include swelling or a lump in the deep tissues of the tongue, throbbing local pain, a discomfort that radiates to the ears, fever, difficulty swallowing, deliberate fixation of the tongue due to pain, and eventually, difficulties breathing.

Case: This is a 50-year-old male patient who presented with a complaint of severe tongue pain and swelling of three days duration. Associated with this, he had pain while swallowing, difficulty opening his mouth, shortness of breath, and drooling saliva. Likewise, he had a high-grade fever and a global type of headache. On physical examination, there was significant tongue swelling on the left anterolateral area, fluctuant on palpation, and had erythematous border. After informed consent was taken the patient was transferred to the operation room with the diagnosis of tongue abscess. Subsequently, incision and drainage were done under general anesthesia, and about 30mL of thick pus was drained. The pocket was washed with normal saline and 2% hydrogen peroxide. The patient was transferred to the surgical ward with stable vital signs and had been on antibiotics. He was discharged after two days of hospital stay.

Conclusion: Abscesses in the tongue are quite uncommon due to its rich vascular supply, lymphatic drainage, and saliva's immunologic advantage. Thorough diagnosis and successful treatment of tongue abscess prevent potential airway compromise. Antibiotic treatment should cover gram-positive and gram-negative anaerobes.

Keywords: tongue abscess, khat chewing, sonography

Introduction

Abscess of the tongue is a very rare disease that potentially compromises the airway.¹ The tongue's strong keratinized epithelium, the density of its muscle compartments, its rich vasculature, and the bactericidal properties of saliva all serve to prevent infection.² However, when host defense mechanisms are impaired, tongue abscesses are more likely to occur. Breached surface barriers, foreign bodies, and immunodeficiency states predispose to tongue infections.³ Acute tongue abscess symptoms include swelling or a lump in the deep tissues of the tongue, throbbing local pain, a discomfort that radiates to the ears, fever, difficulty swallowing, deliberate fixation of the tongue due to pain, and eventually, difficulties breathing.⁴ Therefore, it is crucial to identify tongue infections as soon as possible and treat them as an emergency, especially if dyspnea and dysphagia are present. In particular, if left untreated, abscesses around the root of the tongue could be lethal.⁵ These lesions should be opened and drained once diagnosed.⁶

Clinical Presentation

This is a 50-year-old male patient who presented with a complaint of severe tongue pain and swelling of three days duration. Associated with this, he had pain while swallowing, difficulty opening his mouth, shortness of breath, and drooling saliva. Likewise, he had a high-grade fever and a global type of headache. Otherwise, he had no trauma to his tongue, no recent dental or oral procedures, no history of cigarette smoking, and no history of chronic medical illness like diabetes mellitus, cardiac disease, and hypertension. Historically, he had severe standing dental pain for the past six months prior to his current complaint. He has been chewing khat since his childhood and had poor oral hygiene.

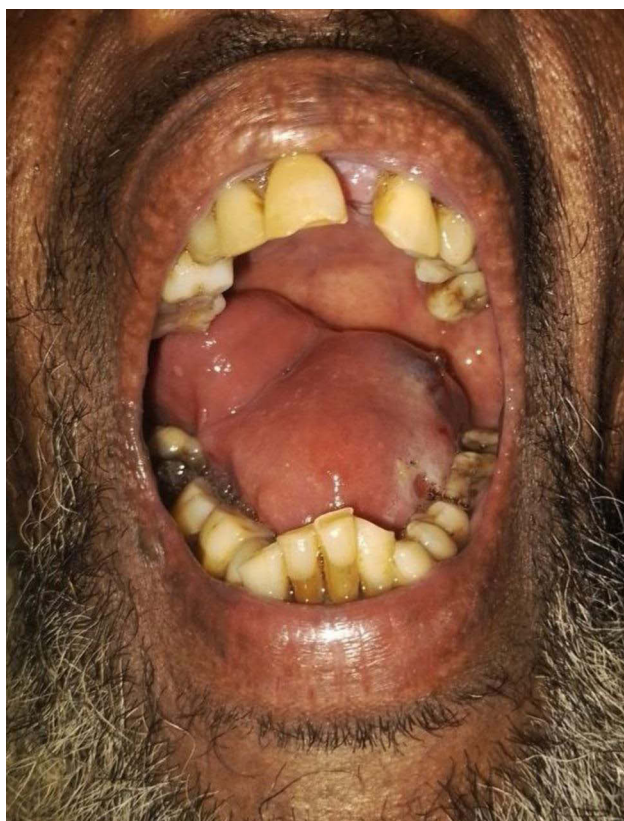


Figure 1 Swollen tongue on the left anterolateral border found during physical examination.

On physical examination, he was acutely sick looking and his vital signs were, blood pressure 115 by 70 mmHg, pulse rate 120 beats per minute, respiratory rate 20, temperature 39 degrees centigrade, and oxygen saturation 92% off oxygen. On HEENT examination there was significant tongue swelling on the left anterolateral area, fluctuant on palpation, and had a erythematous border (Figure 1). There is multiple teeth decay in both maxillary and mandibular areas. There were no pertinent findings on the remaining systems.

After informed consent was taken the patient was transferred to the operation room with the diagnosis of tongue abscess. Subsequently, incision and drainage were done under general anesthesia, and about 30mL of thick pus was drained. The pocket was washed with normal saline and 2% hydrogen peroxide. The patient was transferred to the surgical ward with stable vital signs and had been on ceftriaxone 1 gm iv twice daily (BID) and metronidazole 500 mg iv three times per day (TID) for two days. He was discharged after two days of hospital stay with improvement and Augmentin 625 mg PO TID for five days.

Discussion

Abscesses in the tongue are quite uncommon that occur in immunocompromised patients or healthy persons with pierced tongues.³ Although the tongue is exposed to numerous possible pathogens, it is comparatively immune to infection.⁴ The regular movement of the tongue, which enables the saliva to continuously generate a cleansing effect, as well as its thick layer of keratinized mucosa, which is resistant to microbial penetration; muscle tissue, which makes up the majority of its parenchyma and with its rich circulatory supply; rich lymphatic drainage; and saliva's immunologic characteristics.^{7,8}

A variety of conditions, including tumors, cysts, infarctions, edema, infections, hemorrhages, metabolic macroglossia in hyperpituitarism or hypothyroidism, developmental macroglossia in lingual thyroid, and ectopic lymphoid tissue are included in the differential diagnosis of tongue abscess.^{9,10} Most tongue abscesses are unilateral and located in the anterior two-thirds of the tongue.¹¹ The same is true for this patient which is located in the left anterolateral part of the tongue. A painful swelling that causes the tongue to protrude, dysphagia, odynophagia, and speech impairment are

common symptoms of tongue abscesses.^{12,13} The current patient also experienced severe tongue pain and swelling. Along with this, he experienced pain while swallowing, trouble opening his mouth, shortness of breath, and dribbling of saliva. He also had a high-grade fever and headache. The possible explanation for the abscess may be long-standing poor oral hygiene. This might be due to the fact that the patient was chewing the khat since his childhood.

There are two forms of tongue abscess; superficial and deep. The inflammatory process of a superficial abscess is situated right below the mucosal membrane. The back of the tongue is the primary place. It is uncomfortable to touch and is dense and swollen. With such a configuration, a pathological focus can open and spontaneously drain. After that, the patient feels a reduction in pain and a decrease in swelling. Even though the tongue wound might epithelialize fast, an abscess relapse is likely if the lesion is not properly treated.⁶ The inflammation of the deep tongue muscle tissue is a characteristic of deep abscesses. The course is more severe, with a 38 to 39 degree centigrade temperature, overall weakness, appetite loss, and headaches. A thorough physical examination reveals a significant increase in swelling of the tongue. This could impair speech and food intake. In severe circumstances, the patient has trouble even drinking liquids or breathing through their mouth. Patients with severe conditions can appear with upper airway blockage that necessitates an emergency tracheostomy.⁸ Typically, submandibular lymph nodes expand quickly, becoming painful yet movable.⁶

Sonography, CT, and MR imaging are just a few of the imaging methods that can be utilized to assess tongue swellings.^{7,8,10} Although vascular lesions and abscesses are defined and distinguished by ultrasonography, using the transducer in the mouth is challenging.¹⁴ It has been observed that a lingual abscess appears on sonography as a hypochoic lesion surrounded by a hyperechoic ring. However, sonography is not always practical since if the tongue is swollen and squeezed, the patient may feel discomfort or severe pain.^{7,8}

A correct diagnosis is the first step in the successful treatment of tongue abscesses, which also includes maintaining the airway, performing an incision, and drainage. Next, the proper antibiotic therapy should target Streptococci, Staphylococci, and Gram-negative anaerobes. Since continuous nidus of infection can cause an abscess to return, aspiration alone is frequently insufficient therapy and must be combined with incision and drainage.⁶

Conclusion

Abscesses in the tongue are quite uncommon due to its rich circulatory supply; lymphatic drainage; and saliva's immunologic characteristics. Thorough diagnosis and successful treatment of tongue abscess include maintaining the airway, performing an incision, and drainage. Antibiotic treatment should cover gram-positive and gram-negative anaerobes.

Data Sharing Statement

Data on the case clinical information, informed consent form, and images are available for review from the corresponding author upon request.

Ethical Approval

No ethical approval is required for this case report.

Consent

Informed written consent was taken from the patient.

Funding

There is no funding to report.

Disclosure

The authors declare that there are no conflicts of interest in this work.

References

1. Awai S. Lingual tonsil abscess: a rare, life-threatening cause of acute sore throat. *BMJ Case Rep.* 2019. doi:10.1136/bcr-2019-229555
2. Balatsouras DG, Eliopoulos PN, Kaberos AC. Lingual abscess: diagnosis and treatment. *Head Neck.* 2004;26(6):550–554. doi:10.1002/hed.20018

3. Antoniadis K, Hadjipetrou L, Antoniadis V, et al. Acute tongue abscess. Report of three cases. *Oral Surg.* 2004;97(5):570–573. doi:10.1016/j.tripleo.2003.11.011
4. Ozturk M, Mavili E, Erdogan N, et al. Tongue abscesses: MR imaging findings. *Am J Neuroradiol.* 2006;27(6):1300–1303.
5. Pallagatti S, Sheikh S, Kaur A, et al. Tongue abscess: a rare clinical entity. *J Investig Clin Dent.* 2012;3(3):240–243. doi:10.1111/j.2041-1626.2011.00101.x
6. Mesolella M, Allosso S, Iorio B, et al. Clinical and diagnostic aspect of tongue abscess. *Ear Nose Throat J.* 2021;100(10_suppl):1012S–1014S. doi:10.1177/0145561320933961
7. Ozturk M, Durak AC, Ozcan N, et al. Abscess of the tongue: findings on MR imaging. *Am J Roentgenol.* 1998;170(3):797–798. doi:10.2214/ajr.170.3.9490978
8. Munoz A, Ballesteros AI, Castelo JB. Primary lingual abscess presenting as acute swelling of the tongue obstructing the upper airway: diagnosis with MR. *Am J Neuroradiol.* 1998;19(3):496–498.
9. Rubin MM, Gatta CA, Cozzi GM, et al. Painful tongue mass. *J Oral Maxillofacial Surg.* 1990;48(7):728–731. doi:10.1016/0278-2391(90)90059-B
10. Renehan A, Morton M. Acute enlargement of the tongue. *Br J Oral Maxillofacial Surg.* 1993;31(5):321–324. doi:10.1016/0266-4356(93)90071-4
11. Schweigert J, Christian R, Kemp WL. Challenges in the diagnosis of a posterior lingual abscess, a potential lethal disorder: a case report and review of the literature. *Am J Forensic Med Pathol.* 2020;41(1):64–66. doi:10.1097/PAF.0000000000000514
12. Mesolella M, Ricciardiello F, Cavaliere M, et al. Papillary carcinoma arising in a submental intralingual thyroglossal duct cyst. *Acta Otorhinolaryngologica Italica.* 2010;30(6):313–316.
13. Srivanitchapoom C, Yata K. Lingual abscess: predisposing factors, pathophysiology, clinical manifestations, diagnosis, and management. *Int J Otolaryngol.* 2018;2018:1–8. doi:10.1155/2018/4504270
14. Pandey MK, Srivastava A, Kushwaha RAS, et al. Tongue is an unusual site of abscess development-an experience of two cases. *The Indian Journal of Tuberculosis.* 2016;64:47–49. doi:10.1016/j.ijtb.2016.06.004

International Medical Case Reports Journal

Dovepress

Publish your work in this journal

The International Medical Case Reports Journal is an international, peer-reviewed open-access journal publishing original case reports from all medical specialties. Previously unpublished medical posters are also accepted relating to any area of clinical or preclinical science. Submissions should not normally exceed 2,000 words or 4 published pages including figures, diagrams and references. The manuscript management system is completely online and includes a very quick and fair peer-review system, which is all easy to use. Visit <http://www.dovepress.com/testimonials.php> to read real quotes from published authors.

Submit your manuscript here: <https://www.dovepress.com/international-medical-case-reports-journal-journal>