



# Effect of relative head position on the anesthetic efficacy of inferior alveolar nerve block during endodontic treatment of patients with irreversible pulpitis

Vivek Aggarwal<sup>1</sup>, Mamta Singla<sup>2</sup>, Sanjay Miglani<sup>1</sup>

<sup>1</sup>Department of Conservative Dentistry & Endodontics, Faculty of Dentistry, Jamia Millia Islamia, New Delhi, India

<sup>2</sup>Department of Conservative Dentistry & Endodontics, SGT Dental College, Gurgaon, India

**Background:** The purpose of this prospective randomized single-blind clinical trial was to evaluate the effect of tilting the head on the anesthetic efficacy of inferior alveolar nerve block (IANB) in patients with symptomatic irreversible pulpitis.

**Methods:** Ninety-two patients were divided into two groups: the first group received IANB and the head was tilted in the direction of the block for 15 min, whereas the second group received IANB and the head was tilted to the opposite side. Access cavity preparation was initiated after 15 min. Success was defined as no pain or faint/weak/mild pain during endodontic access preparation and instrumentation. The anesthetic success rates were analyzed by Pearson chi-square test at 5% significance levels.

**Results:** The same side position and opposite side position yielded 41% and 30% anesthetic success rates, respectively; there was no significant difference between the two sides.

**Conclusions:** Relative head position has no effect on the anesthetic success rate of IANB.

**Keywords:** Anesthesia, Local; Nerve Block; Patient Positioning; Pulpitis.



This is an Open Access article distributed under the terms of the Creative Commons Attribution Non-Commercial License (<http://creativecommons.org/licenses/by-nc/4.0/>) which permits unrestricted non-commercial use, distribution, and reproduction in any medium, provided the original work is properly cited.



## INTRODUCTION

Symptomatic pulpitis of the mandibular molar requires endodontic intervention under local anesthesia [1]. Mandibular local anesthesia is traditionally given via direct inferior alveolar nerve block (IANB). The IANB involves deposition of local anesthetic solution into the pterygomandibular space [1], which is a small cleft that is filled with loose alveolar tissue [2]. The local anesthetic solution spreads through this tissue and anesthetizes the inferior alveolar nerve at the entry of the mandibular

foramen.

An increased spread of local anesthetic solution results in longer sections of the nerve receiving exposure to the solution, thus decreasing the nerve activity [3,4]. The spread of the solution may be affected by the speed of injection or the use of additives, such as hyaluronidase [4-11]. A study evaluating the speed of injection on the anesthetic efficacy of IANB in symptomatic patients revealed that the rate of injection does not affect the anesthetic success of IANB [6]. Various authors have tested hyaluronidase to improve the spread of different local anesthetic solutions and have reported mixed results [8-11].

Received: December 12, 2017 • Revised: January 28, 2018 • Accepted: February 1, 2018

Corresponding Author: Vivek Aggarwal, Department of Conservative Dentistry & Endodontics, Faculty of Dentistry, Jamia Millia Islamia, New Delhi, 110024, India  
E-mail: [drvivekaggarwal@gmail.com](mailto:drvivekaggarwal@gmail.com)

Copyright© 2018 Journal of Dental Anesthesia and Pain Medicine

Another factor that may affect the spread of local anesthetic solution is the relative position of the head, following administration of local anesthesia. It has been well documented in spinal anesthesia that both the baricity of the local anesthetic solution and the position of the patient can affect the distribution and action of the drug [12-14]: hypobaric solutions float to the least dependent areas, whereas hyperbaric solutions move down to the dependent areas because of gravitational forces [14,15]. Further, isobaric solutions remain near the vicinity of the injection site [14,15]. As mentioned previously, the pterygomandibular space is filled with loose connective tissue [2]. The spread of local anesthetic solution in this space may depend upon the relative position of the head.

The purpose of this prospective, randomized, single-blind clinical trial was to comparatively evaluate the effect of relative head position (bending the head toward the injection site) on the anesthetic efficacy of inferior alveolar nerve block during endodontic management of symptomatic mandibular molars. The null hypothesis tested was that head position did not affect the success rates.

## METHODS

The study protocol was approved by the local ethics committee (4/10/102/XXX/IEC/2016). The trial has been submitted for registration to Clinical Trial Registry of India with reference number REF/2017/01/013019. The sample size calculation was performed using data from a previous work [16]. The  $\alpha$ -level of the type I error was maintained at 0.05 for a one-tailed test and  $\beta$ -level of the type II error was set at 0.20. The calculations indicated that a total of 92 subjects should provide 80% power to detect a 20% difference in the success rates of two groups. The primary outcome of the clinical trial, or the “end point,” was defined as success/failure, which was indicated as the ability to undergo pulp access and canal instrumentation with no or mild pain.

All patients who participated in this randomized,

single-blind trial provided an informed written consent; 97 patients, who reported with active pain in a mandibular molar, participated in this study. An important inclusion criteria was the presence of a symptomatic, carious, exposed mandibular molar with sharp and lingering pain upon thermal and electrical stimulus; concomitant presence of vital pulp tissue was also required on endodontic access opening. Other inclusion criteria comprised an American Society of Anesthesiologists class I or II medical history, and the ability to understand the use of pain scales. Exclusion criteria included patients with known allergies or contraindications to any type of local anesthetic solution, patients who were pregnant or breast-feeding, patients with a history of known or suspected drug abuse, and patients taking any drugs that could affect pain perception. Patients with active pain in > 1 tooth were excluded from the study. Moreover, patients with cervical spondylitis, or with difficulty tilting the head for extended durations, were excluded. The treatment procedure and the use of pain scales were explained to the patients. A combined visual analog scale (VAS), the Heft-Parker scale, was used in the present study [17]. It comprised six categorical scales (faint, weak, mild, moderate, severe, and intense) on a 170-mm VAS line with ends labeled “no pain” and “unbearable pain.” The patient was asked to mark the line corresponding to his/her pain, with cues from the different categorical points [17-19]. The “faint, weak, or mild” pain corresponded to 1-54 mm and was used as a cut off for assessing successful anesthesia. If the patient reported no pain, or pain up to 54 mm on the HP VAS scale during the treatment, the anesthesia was marked as successful.

The experiment involved two treatment groups. An online random generator, using a permuted block stratified randomization protocol (randomization.com) was used to randomly allocate patients to each group. The patients in the first group received IANB and the head was tilted in the direction of the block. Briefly, in the supine position, each patient received an IANB. The area of injection was dried using sterile gauze and topical anesthesia of 20% benzocaine was applied using a sterile cotton tip applicator for 60 s. The anesthetic solution was

injected via a 5-ml disposable syringe with a 31-mm 24-G needle, using a direct Halstead technique. After reaching the target area, aspiration was performed, and 2.2 ml of 2% lidocaine with 1:200, 000 epinephrine was deposited over a period of 120 s. After depositing the solution and after verifying the alertness of the patient (no signs of syncope or discomfort), the patient was asked to tilt his/her head to the side of injection. If the patient received IANB for left mandibular molar, the head was tilted on the left side; the reverse orientation was also true. The patient was asked to keep the head position tilted for 15 min and was allowed to take small rests in between, if required. The patients in the second group received similar IANB and were asked to tilt the head to the opposite side from the IANB injections. The patients were given an alpha-numeric codes. Only the codes were noted on the evaluation sheet. The codes were broken only after the completion of study. A second clinician, who was blind to the initial IANB injections, performed the endodontic treatment.

After 15 min, the patient was asked for presence of lip numbness. In the absence of profound lip numbness, the

block was considered as ‘missed’ and the patient was excluded from the study. However, the excluded patients received the planned endodontic treatment after supplemental anesthesia. A conventional access opening was initiated after isolation with a dental dam. Patients were instructed to raise their hand if any pain was felt during the procedure. In the case of pain during the treatment, the procedure was stopped, and patients were asked to rate the pain on the HP VAS. Success was defined as no pain or faint/weak/mild pain during endodontic access preparation and instrumentation (HP VAS score of < 55 mm).

The age and gender of patients were analyzed using Student’s t-test, with  $P < 0.05$ . The anesthetic success rates were analyzed via Pearson chi-square test.

## RESULTS

Ninety-two patients, 40 men and 52 women, with an average age of 37 years (range: 21-48 years), participated in this prospective, randomized, single-blind study (Fig. 1). There were no differences in the age and sex of the

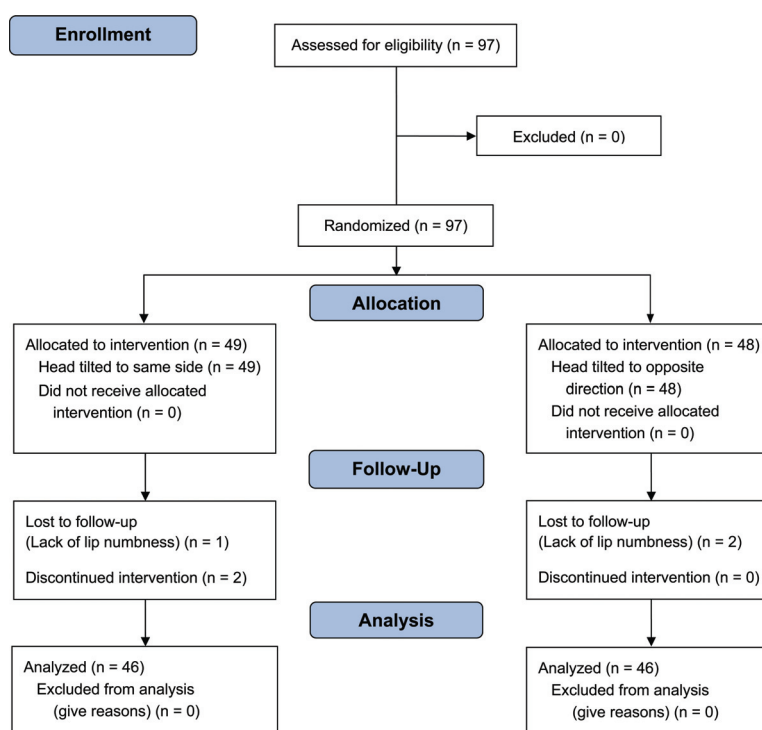


Fig. 1. CONSORT Flow Diagram.

Table 1. Comparison of age and gender

	Same side position	Opposite side position
Age* (mean $\pm$ SD years (range))	35 $\pm$ 5 (21-45)	37 $\pm$ 6 (21-48)
Gender* (males : females)	18 : 28	22 : 24

\*There was no significant difference ( $P > 0.05$ ) between the groups.

Table 2. Comparison of percentage of successful anesthesia

	Same side position	Opposite side position
Successful anesthesia*	19 out of 46 patients (41%)	14 out of 46 patients (30%)

\*There were no significant differences between the groups (chi square = 1.2,  $P = 0.28$ ).

patients between the groups (Table 1). Of the initial 97 patients, five patients were excluded from the study. One patient from same side position and two patients from the opposite side position group did not exhibit profound lip numbness after 15 min. Two patients from the same side group had difficulty in maintaining the tilted head position and opted out of the study. A total of 92 patients (46 in each group) were ultimately evaluated in the experiment.

A comparison of the percentage of patients with successful anesthesia (“no pain” or “weak/mild” pain during endodontic access preparation and instrumentation) is presented in Table 2. The same side position group exhibited a 41% success rate, whereas the IANB group exhibited a 30% success rate. However, there was no significant difference between the two experimental groups ( $\chi^2 = 1.2$ ,  $P = 0.28$ ) (Table 2).

## DISCUSSION

The present study evaluated the hypothesis that the relative position of head affects the spread of local anesthetic solution in the pterygomandibular space, thus affecting the anesthetic efficacy. The increased spread of the solution may lead to larger sections of inferior alveolar nerve being exposed to the anesthetic solution [1,3]. The initial assessments of nerve blockade stated that nerve conduction will be blocked when three nodes of Ranvier are blocked, irrespective of the length of the nerve being exposed [1,20]. However, this concept has been challenged by recent studies, which state that the

nerve conduction blockade is cumulatively dependent upon the length of the nerve exposed to anesthetic solution [3]. Thus, increasing the spread of the local anesthetic solution should have a positive effect on the anesthetic efficacy of the block.

The spread of local anesthetic solution is governed by different factors such as the speed of injection or the use of hydrolyzing additives (e.g., hyaluronidase) [3-11,15]. It is quite possible that increasing the speed of injection may increase the spread of the anesthetic solution [6,15]. Aggarwal et al. [6] evaluated the effect of the speed of injection on the anesthetic success rates of IANB in symptomatic patients. The authors concluded that the rate of injection does not affect the success rates. Conversely, Kanaa et al. [5] reported that the slow injections were more effective in providing pulpal anesthesia in asymptomatic patients. The authors suggested deeper penetration of local anesthetic solution by slow deposition. Adding hyaluronidase in local anesthetic solutions has proven to improve the local anesthetic solution spread in ophthalmological surgeries [10]. In dentistry, it has been reported that addition of hyaluronidase increases the duration of mepivacaine in IANB [11]. However, Ridenour et al. [8] have reported that adding hyaluronidase did not increase the incidence of pulpal anesthesia, but increased post-operative pain and trismus; thus, the authors cautioned its use in IANB because of tissue damage.

In spinal anesthesia, the spread of the local anesthetic solution depends upon its specific gravity and the specific gravity of the cerebrospinal fluid (CSF) [12-15]. Solutions with specific gravity less than that of CSF (1.006) tend to rise above the CSF and provide anesthesia

in superior regions of the injection site. Similarly, hyperbaric solutions move down and provide anesthesia below the injection site [12,14]. This would, however, depend upon the patient position [12]. In IANB, the solution is injected into the pterygomandibular space, which is quite different from the subarachnoid space, where spinal anesthesia is given. The pterygomandibular space is a cleft formed by the medial pterygoid muscle, medial surface of the ramus of the mandible, parotid gland, buccinator and superior constrictor muscles [2]. The space is filled with loose alveolar tissue, which allows the movement of the injected local anesthetic solution. The inferior alveolar nerve is not present in the center of the pterygomandibular space. Notably, it is not always possible to deposit the solution near the inferior alveolar nerve. The solution must move toward the nerve trunk to sufficiently anesthetize the nerve [2,21]. In the present study, it was hypothesized that by tilting the head position, the movement of local anesthetic solution could be controlled. In the absence of any tissue fluid, the baricity of the local anesthetic solution will not contribute, and the spread of the solution will depend upon the mass movement of the solution, which may further depend upon the gravitational forces.

The present study evaluated the effect of relative head position on the anesthetic success rate of 2% lidocaine in the endodontic management of symptomatic mandibular molars. The patient was placed in a supine position and the patient's head was tilted toward/against the injection site, to control the solution spread. The results of the study indicated that head positioning did not affect the success rates of IANB in symptomatic molars. As stated previously, the pterygomandibular space is a small cleft that is surrounded by various anatomical structures [2]. The 2.2 ml of solution may have rapidly filled the pterygomandibular space, negating any effects of gravitational force on the mass movement of the local anesthetic solution.

In conclusion, the relative head position does not affect the anesthetic success rate of IANB, administered by 2% lidocaine, in patients with symptomatic irreversible pulpitis.

#### AUTHOR ORCIDS

Vivek Aggarwal: <https://orcid.org/0000-0002-9792-4554>

Mamta Singla: <https://orcid.org/0000-0002-1016-1014>

Sanjay Miglani: <https://orcid.org/0000-0003-1981-0516>

**ACKNOWLEDGEMENTS:** The authors deny any conflicts of interest. This research did not receive any specific grant from funding agencies in the public, commercial, or not-for-profit sectors. The trial has been submitted for registration to Clinical Trial Registry of India with reference REF/2017/01/013019

#### REFERENCES

1. Hargreaves KM, Keiser K. Local anesthetic failure in endodontics: mechanisms and management. *Endod Topics* 2002; 1: 26-39.
2. Khoury JN, Mihailidis S, Ghabriel M, Townsend G. Applied anatomy of the pterygomandibular space: improving the success of inferior alveolar nerve blocks. *Aust Dent J* 2011; 56: 112-21.
3. Raymond SA, Steffensen SC, Gugliano LD, Strichartz GR. The role of length of nerve exposed to local anesthetics in impulse blocking action. *Anesth Analg* 1989; 68: 563-70.
4. Rucci F, Pippa P, Boccaccini A, Barbagli R. Effect of injection speed on anaesthetic spread during axillary block using the orthogonal two-needle technique. *Eur J Anaesthesiol* 1995; 12: 505-11.
5. Kanaa MD, Meechan JG, Corbett IP, Whitworth JM. Speed of injection influences efficacy of inferior alveolar nerve blocks: a double-blind randomized controlled trial in volunteers. *J Endod* 2006; 32: 919-23.
6. Aggarwal V, Singla M, Miglani S, Kohli S, Irfan M. A prospective, randomized single-blind evaluation of effect of injection speed on anesthetic efficacy of inferior alveolar nerve block in patients with symptomatic irreversible pulpitis. *J Endod* 2012; 38: 1578-80.
7. Whitworth JM, Kanaa MD, Corbett IP, Meechan JG. Influence of injection speed on the effectiveness of

- incisive/mental nerve block: a randomized, controlled, doubleblind study in adult volunteers. *J Endod* 2007; 33: 1149-54.
8. Ridenour S, Reader A, Beck M, Weaver J. Anesthetic efficacy of a combination of hyaluronidase and lidocaine with epinephrine in inferior alveolar nerve blocks. *Anesth Prog* 2001; 48: 9-15.
  9. Wohlrab J, Finke R, Franke WG, Wohlrab A. Efficacy study of hyaluronidase as a diffusion promoter for lidocaine in infiltration analgesia of skin. *Plast Reconstr Surg* 2012; 129: 771e-2e.
  10. Remy M, Pinter F, Nentwich MM, Kampik A, Schönfeld CL. Efficacy and safety of hyaluronidase 75 IU as an adjuvant to mepivacaine for retrobulbar anesthesia in cataract surgery. *J Cataract Refract Surg* 2008; 34: 1966-9.
  11. Tempestini Horliana AC, de Brito MA, Perez FE, Simonetti MP, Rocha RG, Borsatti MA. Hyaluronidase increases the duration of mepivacaine in inferior alveolar nerve blocks. *J Oral Maxillofac Surg* 2008; 66: 286-90.
  12. Loubert C, Hallworth S, Fernando R, Columb M, Patel N, Sarang K, Sodhi V. Does the baricity of bupivacaine influence intrathecal spread in the prolonged sitting position before elective cesarean delivery? A prospective randomized controlled study. *Anesth Analg* 2011; 113: 811-7.
  13. Yang MK, Kim JA, Ahn HJ, Choi DH. Influence of the baricity of a local anaesthetic agent on sedation with propofol during spinal anaesthesia. *Br J Anaesth* 2007; 98: 515-8.
  14. Fettes PD, Hocking G, Peterson MK, Luck JF, Wildsmith JA. Comparison of plain and hyperbaric solutions of ropivacaine for spinal anaesthesia. *Br J Anaesth* 2005; 94: 107-11.
  15. Stienstra R, Gielen M, Kroon JW, Van Poorten F. The influence of temperature and speed of injection on the distribution of a solution containing bupivacaine and methylene blue in a spinal canal model. *Reg Anesth* 1990; 15: 6-11.
  16. Aggarwal V, Jain A, Kabi D. Anesthetic efficacy of supplemental buccal and lingual infiltrations of articaine and lidocaine following an inferior alveolar nerve block in patients with irreversible pulpitis. *J Endod* 2009; 35: 925-9.
  17. Heft MW, Parker SR. An experimental basis for revising the graphic rating scale for pain. *Pain* 1984; 19: 153-61.
  18. McCartney M, Reader A, Beck M. Injection pain of the inferior alveolar nerve block in patients with irreversible pulpitis. *Oral Surg Oral Med Oral Pathol Oral Radiol Endod.* 2007; 104: 571-5.
  19. Aggarwal V, Singla M, Rizvi A, Miglani S. Comparative evaluation of local infiltration of articaine, articaine plus ketorolacand dexamethasone on anesthetic efficacy of inferior alveolar nerve block with lidocaine in patients with irreversible pulpitis. *J Endod* 2011; 37: 445-9.
  20. Takeuchi T, Tasaki I. Übertragung de nervenimpulse in der polarisierten nervenfaser. *Pfluegers Arch Gesamte Physiol Menschchen Tiere* 1942; 246: 32-43.
  21. Coleman RD, Smith RA. The anatomy of mandibular anesthesia: review and analysis. *Oral Surg Oral Med Oral Pathol* 1982; 54: 148-53.