

Contents lists available at [ScienceDirect](https://www.sciencedirect.com)

Respiratory Medicine Case Reports

journal homepage: www.elsevier.com/locate/rmcr

Case Report

Not always embolism: A case of pulmonary artery intimal sarcoma – The role of the radiologist in early diagnosis

Marco Catalano^a, Luca Crimi^a, Federica Galioto^{a,*}, Maria Coronella^a,
Pietro Valerio Foti^a, Stefano Palmucci^a, Antonio Basile^a

^a Department of Medical Surgical Sciences and Advanced Technologies “GF Ingrassia”, Radiology Unit 1, University Hospital Policlinico “G. Rodolico-San Marco”, Catania, 95123, Italy

ARTICLE INFO

Handling Editor: DR AC Amit Chopra

ABSTRACT

Introduction: Pulmonary artery intimal sarcoma (PAIS) is a rare malignant neoplasm with imaging features that can mimic pulmonary embolism (PE). It must be recognized early because a radical resection may be useful to prolong survival.

Case description: A clinical case of a 57-year-old Caucasian male affected by PAIS is presented, which describes the computed tomography (CT) findings found in PAIS and the elements of overlap and differentiation with PE. The main common element is represented by the endoluminal filling defect of the pulmonary arterial vessels in contrast-enhanced CT examinations; a characteristic polypoid morphology or polylobulated contours are typical findings of PAIS. Other specific elements of the neoplasm such as wall eclipse sign, extension beyond the arterial wall, and metastasis are also explained.

Conclusions: The overlap of the clinical–radiological findings and the epidemiological difference between PAIS and PE cause a diagnostic delay. By knowing the differential elements, the radiologist can detect the neoplasm early to accelerate diagnosis and suggest optimal management.

1. Introduction

Pulmonary artery intimal sarcoma (PAIS) is a rare malignant neoplasm that usually originates from the intima of pulmonary artery (PA) [1]; pathologists consider PAIS to be a mesenchymal neoplasm poorly differentiated with fibroblastic or myofibroblastic differentiation [2]. PAIS can occur at any age, with prevalence in the middle age. The prognosis is poor, with a median survival of 1.5 months, extended up to 10 months if the patient undergoes surgery [3]. Because of the rarity of the condition, which is poorly treated in the literature, it is not possible to have accurate data about the incidence. Clinical presentation depends on the disease stage and, therefore, on the degree of involvement of the pulmonary vessels and the possible distant progression of the disease: usually the symptoms and signs of right ventricular failure are the early features [4] that may lead to a difficult differential diagnosis with non-neoplastic conditions, such as chronic pulmonary embolism (CPE). PAIS and CPE demonstrate a strong overlap of the radiological findings; hence, diagnosis is complicated and often delayed [1–6]. The aim of this study is to illustrate contrast-enhanced computed tomography (CECT)-typical findings of PAIS, showing a case followed at our center, to help radiologists recognize the elements of differential diagnosis with CPE (Table 1).

* Corresponding author.

E-mail address: federicagalioto91@gmail.com (F. Galioto).

<https://doi.org/10.1016/j.rmcr.2023.101822>

Received 10 January 2023; Received in revised form 14 February 2023; Accepted 16 February 2023

Available online 19 February 2023

2213-0071/© 2023 Published by Elsevier Ltd.

This is an open access article under the CC BY-NC-ND license

(<http://creativecommons.org/licenses/by-nc-nd/4.0/>).

Table 1

Prevalence of different CTA signs identified in patients with PAIS or CPE, according to the data suggested by Kim C. et al. [1].

CTA signs	PAIS	CPE
Diameter:		
Maximum longitudinal diameter (mean value, mm)	45	27
Maximum transverse diameter (average value, mm)	22	11
Morphology (%):		
a) Cauliflower-like lesion	15	0
b) Parietal thickening	23	15
c) Lumen occlusion	62	6
d) Tubular/polypoid shape	0	79
Appearance:		
Heterogeneous (%)	92	0
Homogeneous (%)	8	100
Typical finding:		
Wall eclipsing sign (%)	42	0
Contours		
Irregular or lobulated (%)	92	10
Angle formed with the wall (%):		
a) Acute	85	17
b) Obtuse	15	83
Number:		
a) Multifocal (%)	42	77
b) Single (%)	58	23
Location (%):		
a) Central	85	42
- Peripheral	15	58

2. Case description

We report a case of a 57-year-old Caucasian male, who was admitted to our hospital for dyspnea and mild respiratory failure. According to his anamnestic data, he had no allergies or previous traumatic events; his father was affected by colon cancer. As an ex-smoker of 20 cigarettes/day for 35 years, he was also affected by anemia because of vitamin B12 deficiency and lupus anticoagulant, either of which was treated.

In August 2021, because of pain in the right hemithorax, a chest X-ray (Fig. 1) was performed, which depicted an area of parenchymal thickening initially suggestive of pneumonia, but not regressed after adequate medical therapy.

Therefore, the patient underwent a chest CT scan, which demonstrated the presence of pseudonodular thickening of the right lower pulmonary lobe. Hence, the patient was hospitalized for 8 days and the diagnostic process was continued with chest CT angiography (CTA) and PET-CT examination.

Chest CTA revealed the presence of a filling defect along the common pulmonary arterial trunk, extending from the valve plane to the bifurcation, with eccentric distribution and irregular margins, partly polylobulated (Fig. 2).

Additional filling defects were also observed along the right PA, with extension to the segmental branches for the middle lobe, which appear partly occluded (Fig. 3).

The radiologist defined the CT examination of uncertain interpretation and proposed a differential diagnosis between PE and heteroplastic tissue.

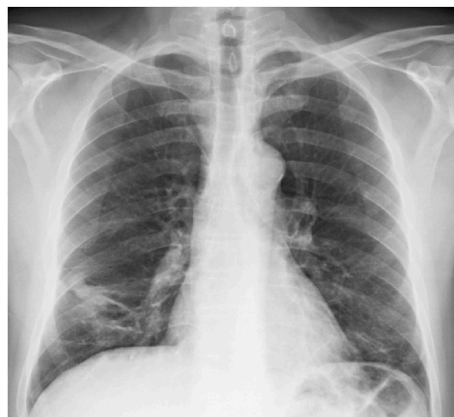

Fig. 1. The patient's chest X-ray was taken because of the suspicion of pneumonia. The posteroanterior (PA) views of the chest radiograph show the presence of an area of parenchymal radiopacity, with the bronchovascular bundles thickening in the right suprabasal region (white arrow).

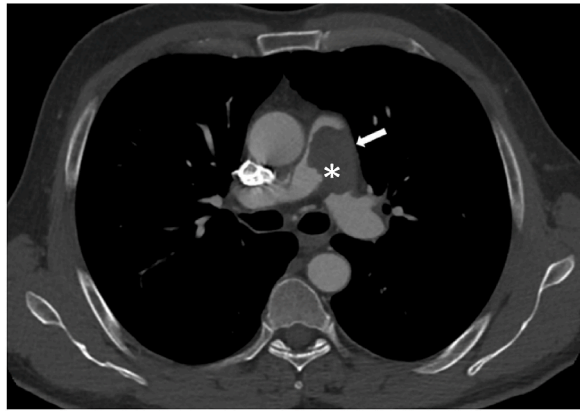


Fig. 2. Axial CTA scans demonstrate the characteristic sign of PAIS. A hypodense area extends along the entire left wall of the common pulmonary trunk (white arrow), resembling the wall-eclipsing sign. The polylobulated margin (asterisk) depicted on the luminal side is another differential element with CPE.

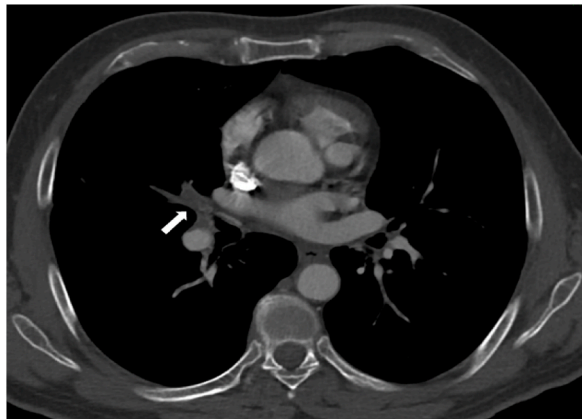


Fig. 3. Same CTA examination, in a scan acquired at the pulmonary veins level, demonstrates other peripheral segmental branches' involvement, with occlusion of the pulmonary arterial branches for the middle lobe (white arrow). These may be findings of SIAP advanced stages.

The PET-CT examination shows tracer accumulation in the lower field of the right lung (SUV max 2.6, average hepatic SUV 1.5), in association with minute accumulation in the ipsilateral hilar region, probably of lymph node nature (SUV max 2.9) and also in the trunk and right PA (SUV max 3.1).

Clinical, radiological, and nuclear medicine data suggest a neoplastic condition, probably of sarcomatoid nature, and, therefore, a candidate for surgical treatment.

In December 2021, the patient underwent surgical removal of the endoluminal neof ormation of the trunk of the PA and atypical resection of the right middle lobe. Histological examination showed poorly differentiated, high-grade pleomorphic sarcoma (G3 - FN-CLCC), with high mitotic index, large areas of necrosis, and endovascular growth with endothelial lining. The clinical, morphological, and immunophenotypic features are more compatible with the diagnosis of PAIS.

On February 2022, the patient underwent a head and body CECT evaluation (Fig. 4), which showed the recurrence and progression of the disease with multiple filling defects of the pulmonary arterial branches appreciable in the common pulmonary trunk – and involving the valvular plane, and the right and left main pulmonary arteries.

Other filling defects were also found in the lobar branches for the upper right lobe, with subtotal occlusion of the lumen of the branches for the apical and dorsal segment being appreciated, and the middle lobe, and some segmental branches of the upper left lobe and inferior left lobe. The filling defects confirm the suspicion of secondary lesions of the known intimal sarcomatous pathology of the PA. Then, the patient started life-saving chemotherapy treatment.

3. Conclusion

PAIS is a very rare and malignant mesenchymal neoplasia that affects the wall of the pulmonary arteries. It has a predominant central location, affecting the pulmonary trunk in 80% of cases, the right or left PA in 50–70%, or both in 40% [5]. In a high percentage of cases, the disease spreads very quickly, with extrathoracic metastasis at the diagnosis, involving the brain, kidneys, bones, and skin.

The diagnosis of PAIS is hard: the presence of nonspecific symptoms and imaging findings may lead to a diagnostic delay. The main challenge is the differential diagnosis with CPE.

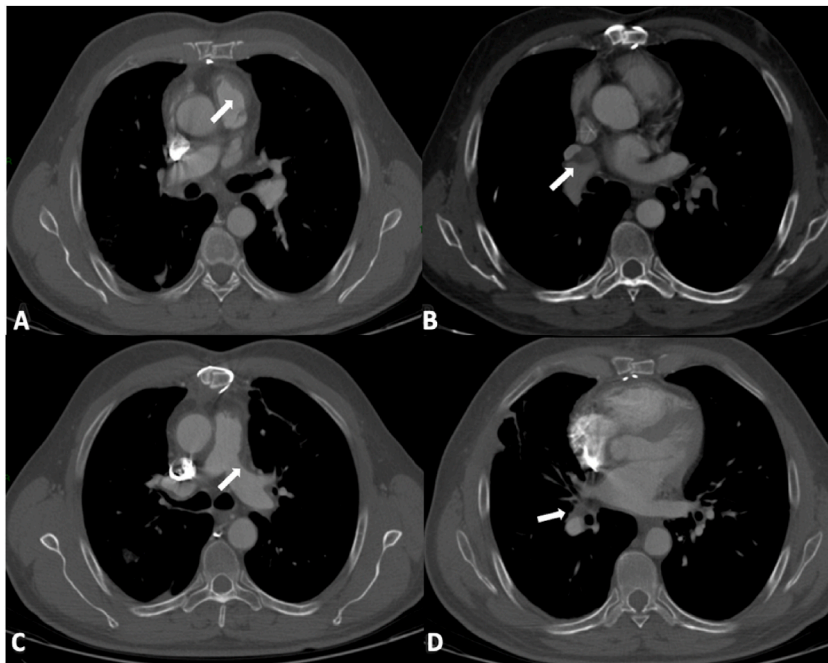


Fig. 4. Recurrence and progression of PAIS after surgical resection. Staging CECT examination shows the involvement of common pulmonary truncus with extension to the valve plane (white arrow in A), the involvement of right pulmonary artery (white arrow in B) and left pulmonary artery (white arrow in C), and also the involvement of the peripheral branches (white arrow in D).

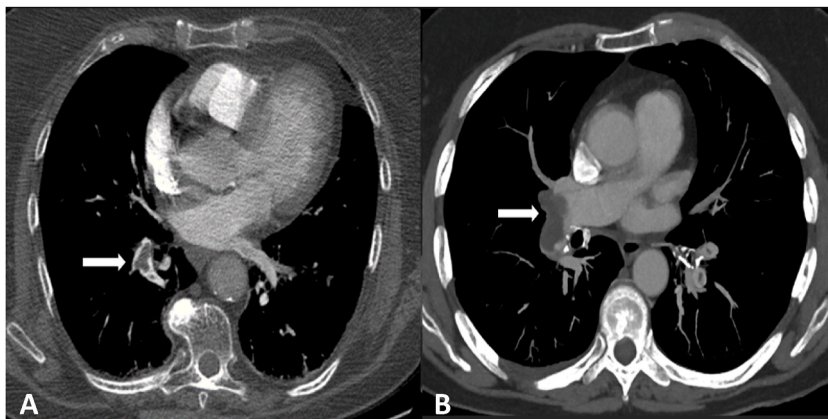


Fig. 5. Axial CTA images (A and B) demonstrate some endoluminal filling defects of pulmonary arterial vessels in CTA (arrows), often referred to as CPE.

Chest CTA is the gold standard for the detection of tumors involving pulmonary arteries [5,6] and allows us to study the local characteristics of the neoplasia – such as the location, size, morphology, and also the stage of disease – and the possible presence of metastasis. Nevertheless, CTA also poses some problems because of the overlap between PAIS and CPE: the main common element is represented by the endoluminal filling defect of the pulmonary arterial vessels [7], which in the vast majority of cases is referred to as CPE (Fig. 5).

In our clinical case, we reported the CTA characteristic findings of PAIS that differentiate it from CPE: central location (Fig. 6) – unlike CPE, which prefers peripheral sites, acute angle with the wall (Fig. 7), larger size, and cauliflower morphology (Fig. 8) – instead, CPE presents a saddle-shaped lump on imaging [6], polylobed contours (Figs. 5–2), and greater densitometric attenuation in the late phase. Sometimes, CTA detects some features that are strongly indicative of neoplastic pathology that are never found in CPE, such as the wall-eclipsing sign (Fig. 2) – indicative of the presence of a mass inside the vessel's lumen that is adhered to its wall along the entire extension until determining obliteration [8], the extension beyond the wall, and the presence of metastasis (Fig. 9) – the most frequent site is the lung, where it is possible to find nodular lesions different from wedge-shaped pulmonary infarction caused by CPE [9].

In conclusion, although the diagnosis is exclusively histological, CTA imaging can identify the typical features of the neoplasia. A radiologist must have the knowledge of different radiological features of the two conditions to achieve an early diagnosis; an ade-

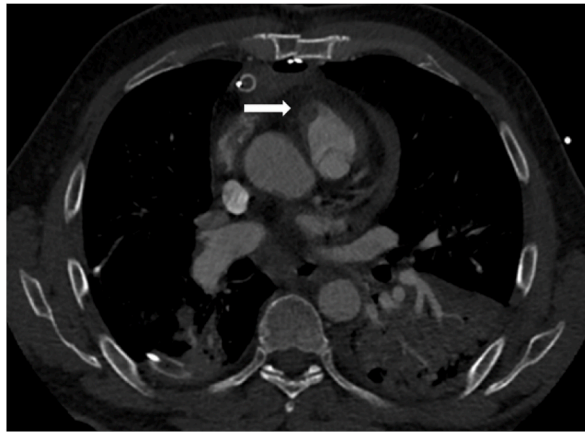


Fig. 6. CTA image shows the presence of a pulmonary endoluminal filling defect localized in the proximal portion of the common pulmonary trunk affecting the valve plane too (white arrow), a rare localization in PE.

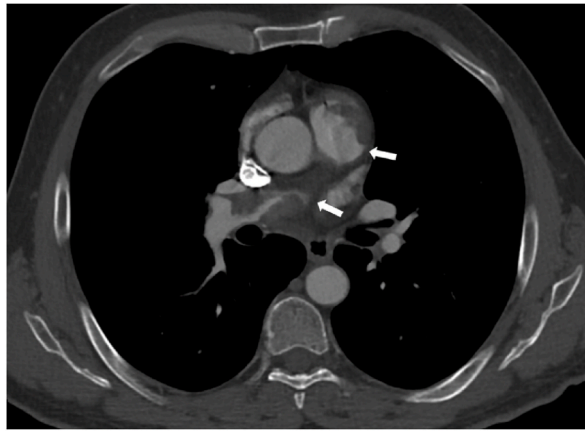


Fig. 7. Characteristic of PAIS disease. The presence of acute angles between the lesions and the walls of the vessel (white arrows), demonstrated in axial CT scans, is a finding that helps us to distinguish SIAP from PE.

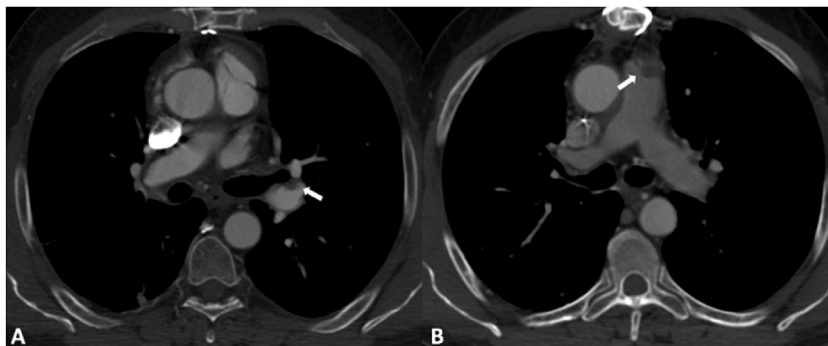


Fig. 8. "Cauliflower-like" morphology. Axial CT images demonstrate the presence of endoluminal filling defects, with adherence to the wall and convex and finely irregular morphology on the luminal side (white arrows in A and B). This aspect is very specific to PAIS.

quate surgical treatment is the only hope of prolonging survival for these patients [10,11]. As demonstrated by Kim C. et al., overall survival is significantly reduced when there is a delay in diagnosis [1]; hence, an early diagnosis is the key to extending and increasing the survival of these patients.

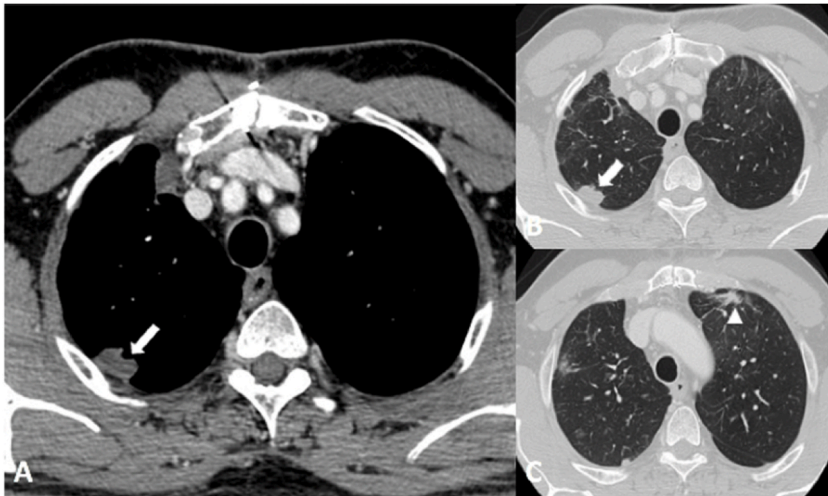


Fig. 9. Follow-up CT evaluation. Some areas of parenchymal consolidation, with irregular margins and adhering to the costal pleura, are appreciated in the dorsal segment of the upper right lobe (white arrows in A and B) and in the anterior segment of the upper left lobe (arrowhead in C). These alterations correspond to repetitive lesions of the disease.

References

- [1] C. Kim, M.Y. Kim, J.W. Kang, J.S. Song, K.Y. Lee, S.S. Kim, Pulmonary artery intimal sarcoma versus pulmonary artery thromboembolism: CT and clinical findings, *Korean J. Radiol.* 19 (4) (2018) 792–802, <https://doi.org/10.3348/kjr.2018.19.4.792>.
- [2] D. Attinà, F. Niro, P. Tchouanté, et al., Pulmonary artery intimal sarcoma. Problems in the differential diagnosis, *Radiol. Med.* 118 (8) (2013) 1259–1268, <https://doi.org/10.1007/s11547-013-0943-x>.
- [3] A.M. Ropp, A.P. Burke, S.J. Kligerman, J.S. Leb, A.A. Frazier, Intimal sarcoma of the great vessels, *Radiographics* 41 (2) (2021) 361–379, <https://doi.org/10.1148/rg.2021200184>.
- [4] D.Y. Chang, K.C. Lin, J.Y. Pan, H.W. Liu, S.H. Kuo, L. Lee, Pulmonary artery intimal sarcoma: a case report and literature review, *Respirol Case Rep* 8 (2) (2020), e00530 <https://doi.org/10.1002/rcr2.530>, Published 2020 Feb 5.
- [5] P. Lu, B.B. Yin, Misdiagnosis of primary intimal sarcoma of the pulmonary artery as chronic pulmonary embolism: a case report, *World J Clin Cases* 8 (5) (2020) 986–994, <https://doi.org/10.12998/wjcc.v8.i5.986>.
- [6] Y.C. Li, L.Y. Li, H.C. Tong, et al., Pulmonary artery intimal sarcoma mimicking pulmonary thromboembolism: a case report, *Medicine (Baltim.)* 100 (6) (2021) e24699, <https://doi.org/10.1097/MD.0000000000024699>.
- [7] C.A. Yi, K.S. Lee, Y.H. Choe, D. Han, O.J. Kwon, S. Kim, Computed tomography in pulmonary artery sarcoma: distinguishing features from pulmonary embolic disease, *J. Comput. Assist. Tomogr.* 28 (1) (2004) 34–39, <https://doi.org/10.1097/00004728-200401000-00005>.
- [8] H.L. Gan, J.Q. Zhang, X.Y. Huang, W. Yu, The wall eclipsing sign on pulmonary artery computed tomography angiography is pathognomonic for pulmonary artery sarcoma, *PLoS One* 8 (12) (2013), e83200 <https://doi.org/10.1371/journal.pone.0083200>, Published 2013 Dec 31.
- [9] B. Pan, S.C. Wang, Z.K. Chen, X. Chen, Primary pulmonary artery sarcoma with intrapulmonary metastases based on PET/CT imaging: a case report and literature review, *Ann. Palliat. Med.* 10 (6) (2021) 7013–7018, <https://doi.org/10.21037/apm-20-630>.
- [10] S.H. Blackmon, D.C. Rice, A.M. Correa, et al., Management of primary pulmonary artery sarcomas, *Ann. Thorac. Surg.* 87 (3) (2009) 977–984, <https://doi.org/10.1016/j.athoracsur.2008.08.018>.
- [11] M.C. Wyler von Ballmoos, E.Y. Chan, M.J. Reardon, Imaging and surgical treatment of primary pulmonary artery sarcoma, *Int. J. Cardiovasc. Imag.* 35 (8) (2019 Aug) 1429–1433 <https://doi.org/10.1007/s10554-018-1489-8>, Epub 2018 Dec 8. PMID: 30535656.