

Acute Respiratory Distress Syndrome after the Use of Gadolinium Contrast Media

Jihye Park,¹ Il Hwan Byun,² Kyung Hee Park,¹ Jae-Hyun Lee,¹ Eun Ji Nam,³ and Jung-Won Park¹

Departments of ¹Internal Medicine, ²Medicine, and ³Obstetrics and Gynecology, Yonsei University College of Medicine, Seoul, Korea.

Received: April 22, 2014

Revised: August 26, 2014

Accepted: August 29, 2014

Corresponding author: Dr. Jung-Won Park,
Department of Internal Medicine,
Severance Hospital, Yonsei University
College of Medicine, 50-1 Yonsei-ro,
Seodaemun-gu, Seoul 120-752, Korea.
Tel: 82-2-2228-1961, Fax: 82-2-2227-7932
E-mail: parkjw@yuhs.ac

The authors have no financial conflicts of interest.

Acute respiratory distress syndrome (ARDS) is a medical emergency that threatens life. To this day, ARDS is very rarely reported by iodine contrast media, and there is no reported case of ARDS induced by gadolinium contrast media. Here, we present a case with ARDS after the use of gadobutrol (Gadovist) as a magnetic resonance imaging (MRI) contrast medium. A 26 years old female without any medical history, including allergic diseases and without current use of drugs, visited the emergency room for abdominal pain. Her abdominopelvic computed tomography with iodine contrast media showed a right ovarian cyst and possible infective colitis. Eighty-three hours later, she underwent pelvis MRI after injection of 7.5 mL (0.1 mL/kg body weight) of gadobutrol (Gadovist) to evaluate the ovarian cyst. She soon presented respiratory difficulty, edema of the lips, nausea, and vomiting, and we could hear wheezing upon auscultation. She was treated with dexamethasone, epinephrine, and norepinephrine. Her chest X-ray showed bilateral central bat-wing consolidative appearance. Managed with mechanical ventilation, she was extubated 3 days later and discharged without complications.

Key Words: Gadolinium, gadobutrol, acute respiratory distress syndrome

INTRODUCTION

Gadolinium-based contrast media have been used since 25 years ago because of their safety and low rates of side effects. Gadobutrol is a second-generation extracellular non-ionic macrocyclic gadolinium based contrast agents with high thermostability. Its gadolinium ion concentration is twice as high as other gadolinium agents, effectively resulting in high-quality images with low amount.¹

Adverse reactions due to radiologic contrast media are not rare, but those accompanied with acute respiratory distress syndrome (ARDS) by contrast media are extremely rare. To our best knowledge, only two cases of noncardiogenic pulmonary edema induced by ionic computed tomography (CT) contrast media, such as diatrizoate and iohalamatemeglumine, have so far been reported.^{2,3} Also, no case of ARDS induced by magnetic resonance imaging (MRI) gadolinium contrast media has been reported yet. Here, we present a young woman who developed ARDS after the use of gadobutrol.

© Copyright:

Yonsei University College of Medicine 2015

This is an Open Access article distributed under the terms of the Creative Commons Attribution Non-Commercial License (<http://creativecommons.org/licenses/by-nc/3.0>) which permits unrestricted non-commercial use, distribution, and reproduction in any medium, provided the original work is properly cited.

CASE REPORT

A 26 years old female without allergic diseases or history of taking medical image studies by using contrast media visited the emergency room for abdominal pain. Her abdominopelvic CT with contrast media showed a right ovarian cyst and possible infective colitis. Her chest X-ray and blood tests on the day of admission did not show anything significant. To evaluate the ovarian cyst, she underwent pelvis MRI after injection of 7.5 mL (0.1 mL/kg body weight) of gadobutrol (Gadovist, Bayer Inc., Toronto, Canada) 83 hours after the CT examination. Fifty minutes after the injection of gadobutrol, she presented respiratory difficulty, edema of the lips, nausea, vomiting, and wheezing upon auscultation. Her blood pressure (124/75 mm Hg) and body temperature (37.2°C) were normal, but she had tachycardia (pulse rate 109/minute) and tachypnea (respiratory rate 32/minute). Under the impression of anaphylaxis, she was given 0.5 mg of epinephrine 1:1000 intramuscularly and 5 mg of dexamethasone twice intravenously. While applying 15 L/min of oxygen via mask, arterial blood gas analysis showed pO_2 of 50.8 mm Hg and PaO_2/FiO_2 ratio of 63.5, and the chest X-ray showed bilateral central bat-wing consolidation (Fig. 1A). She rapidly developed acute respiratory failure that required mechanical ventilation (Fig. 1B). Three hours after the injection, she had hypotension (blood pressure 59/39 mm Hg) and tachycardia (pulse rate 112/min). Blood pressure did not recover after administration of 2 L of crystalloid and norepinephrine (10 mcg per minute). Six hours after the infusion, ARDS was improved on the X-ray, and transthoracic echocardiogram showed good left ventricular contractility with left ventricular ejection fraction of 60%. The ratio of mitral peak velocity of early filling to early diastolic mitral annular velocity was 9. Norepinephrine was stopped 16 hours after

intubation, and the patient was extubated 3 days later and discharged without complications (Fig. 1C). She was diagnosed with endometriotic cyst and underwent laparoscopic right ovarian cyst enucleation.

DISCUSSION

A recent study shows that gadobutrol is highly safe, with 0.55% of adverse drug reaction and less than 0.01% of serious adverse drug reaction requiring admission such as anaphylaxis.⁴ Besides minor adverse effects such as feeling of warmth and taste alteration, MRI contrasts could rarely induce nephrogenic systemic fibrosis.⁵ However, we could not find direct association between MRI contrasts and the lung adverse reactions, and this case has a meaningful value as the first reported case of ARDS after the use of gadobutrol. Drug-induced ARDS is a progressive clinical condition when a drug causes alveolar degradation and flooding with protein-rich material and cellular debris with subsequent increases in pulmonary vascular resistance. A complex array of endothelial injury, epithelial injury, neutrophil-mediated damage, cytokine-mediated inflammation and injury, oxidant-mediated injury, ventilator-induced lung injury, and dysregulation of coagulation and fibrinolytic pathways are all implicated in the development.⁶

Risk of adverse reactions by MR contrast media have been reported to be lower than those of CT contrast media, and cross-reactivity between MR and CT contrast media has not yet been reported. Therefore, MR contrast study has been recognized as the safe alternative for iodide contrast media allergy patients.⁷ However, our patient did not show adverse reaction to CT contrast agent, suggesting the possibility of using CT contrast media as a safe alternative for MR contrast allergy patients.

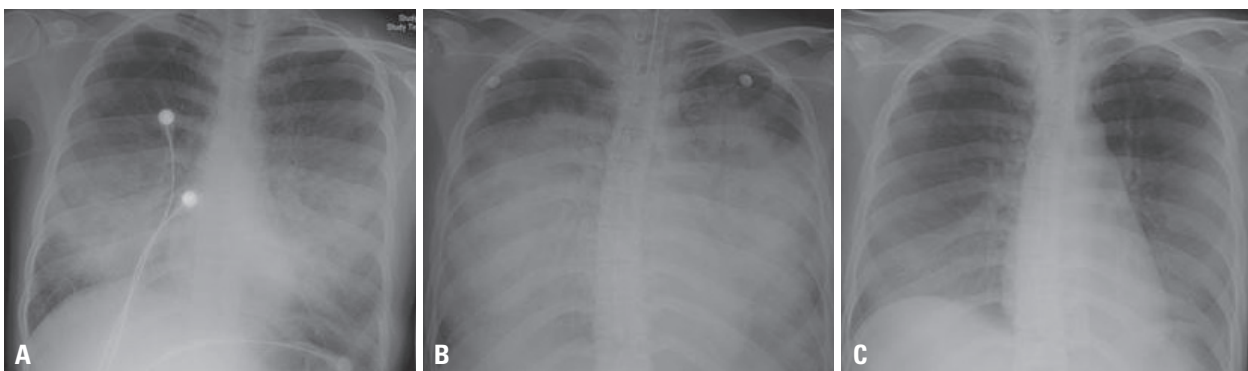


Fig. 1. Chest X-ray features of the patient: (A) when the symptoms presented, (B) immediately after intubation, (C) before discharge from the intensive care unit.

We diagnosed our patient with ARDS. She showed some clinical symptoms of anaphylaxis such as dyspnea and wheezing, but these can be explained by ARDS. Her clinical manifestations were not compatible to anaphylaxis; she developed the symptoms 50 minutes after the injection of gadobutrol, and the blood pressure was normal at the early phase of the event and then dropped 3 hours after the administration. Most cases of anaphylaxis after the use of contrast media occur within 15 minutes, and a study on gadobutrol states that 82.4% of the side effects occur within 5 minutes after the injection and 95.7% in 10 minutes.⁸ The hypotension episode was not corrected despite epinephrine and massive administration of crystalloid fluid. The clinical feature of this patient was quite similar to the previously reported anaphylactoid pulmonary edema induced by ionic iodide contrast media.^{2,3} Intradermal skin test and the measurement of serum tryptase at the time of the episode might have helped the differentiation of the diagnosis, but they were not done. Some investigators suggest the usefulness of 1:10 diluted intradermal skin test for IgE mediated gadolinium contrast media allergy,⁹ but IgE mediated mechanism may not be critical for the development of ARDS. Furthermore, positive and negative predictive values of skin test for the diagnosis of IgE mediated gadolinium allergic diseases are yet unknown.

Besides gadobutrol, the MRI contrast media which our patient used, there are other gadolinium-based contrast media such as gadoteric acid, gadobenate, and gadodiamide. Controversy exists whether the allergic reactions of gadolinium contrast media are structure dependent. Several investigators have reported higher rate of allergic reaction by gadomenate dimeglumine than other MR contrast media,¹⁰ suggesting the presence of specificities of gadolinium contrast media for provoking adverse reactions.

Recently, increased need for health check-ups led to increased use of MRI with contrast media as well. Doctors and other practitioners should always keep in mind the risk of ARDS after the use of gadolinium contrast media and

consider the possibility of using CT contrast media as a safe alternative.

ACKNOWLEDGEMENTS

This research was supported by a grant from Ministry of Food and Drug Safety to operation of the regional pharmacovigilance center in 2015.

REFERENCES

1. Scott LJ. Gadobutrol: a review of its use for contrast-enhanced magnetic resonance imaging in adults and children. *Clin Drug Investig* 2013;33:303-14.
2. Boden WE. Anaphylactoid pulmonary edema ("shock lung") and hypotension after radiologic contrast media injection. *Chest* 1982; 81:759-61.
3. Solomon DR. Anaphylactoid reaction and non-cardiac pulmonary edema following intravenous contrast injection. *Am J Emerg Med* 1986;4:146-9.
4. Herborn CU, Honold E, Wolf M, Kemper J, Kinner S, Adam G, et al. Clinical safety and diagnostic value of the gadolinium chelate gadoterate meglumine (Gd-DOTA). *Invest Radiol* 2007;42:58-62.
5. Nicholas BA, Vricella GJ, Smith M, Passalacqua M, Gulani V, Ponsky LE. Contrast-induced nephropathy and nephrogenic systemic fibrosis: minimizing the risk. *Can J Urol* 2012;19:6074-80.
6. Bakowitz M, Bruns B, McCunn M. Acute lung injury and the acute respiratory distress syndrome in the injured patient. *Scand J Trauma Resusc Emerg Med* 2012;20:54.
7. Brochow K, Sánchez-Borges M. Hypersensitivity to contrast media and dyes. *Immunol Allergy Clin N Am* 2014;34:547-64.
8. Forsting M, Palkowitsch P. Prevalence of acute adverse reactions to gadobutrol--a highly concentrated macrocyclic gadolinium chelate: review of 14,299 patients from observational trials. *Eur J Radiol* 2010;74:e186-92.
9. Hasdenteufel F, Luyasu S, Renaudin JM, Paquay JL, Carbutti G, Beaudouin E, et al. Anaphylactic shock after first exposure to gadoterate meglumine: two case reports documented by positive allergy assessment. *J Allergy Clin Immunol* 2008;121:527-8.
10. Jung JW, Kang HR, Kim MH, Lee W, Min KU, Han MH, et al. Immediate hypersensitivity reaction to gadolinium-based MR contrast media. *Radiology* 2012;264:414-22.