

Correction of iatrogenic injury of the obturator nerve during pelvic laparoscopic lymphadenectomy by the use of sural nerve grafts



A.R. Dias Jr.^{a,*}, A. Silva e Silva^a, J.P. Carvalho^a, E.C. Baracat^b, G. Favero^a

^a Gynecology, Instituto do Câncer do Estado de São Paulo – ICESP, São Paulo, Brazil

^b Gynecology, Faculdade de Medicina da Universidade de São Paulo, São Paulo, Brazil

ARTICLE INFO

Article history:

Received 17 April 2014

Accepted 3 August 2014

Keywords:

Endometrial cancer
Iatrogenic section
Iliac lymphadenectomy
Autologous sural nerve grafts
Obturator nerve

Introduction

The interposition of sural nerve grafts for the correction of an iatrogenic sectioning of the obturator nerve during oncologic pelvic surgeries has been rarely described in the literature (Zhang et al., 2013; Benes, 1999).

The obturator nerve is an important landmark during pelvic lymph node dissection and its identification is mandatory. Intraoperative injury of the obturator nerve is not an infrequent complication of gynecological surgeries. This injury (indirect thermal or direct mechanical injury as a result of a sharp dissection) can occur in association with pelvic lymphadenectomy for uterine or cervical cancer and its incidence does not appear to differ between open surgical and laparoscopic approaches. Also gynecologic oncology patients undergoing exenterating or extensive retroperitoneal surgery are at increased risk of this injury (Harma et al., 2014).

Clinical consequences of this type of lesions vary and may include pain down the medial thigh, variable gait disturbance, weakness of adduction of the thigh and inconstant sensory loss over the medial thigh (Rothmund et al., 2011).

Nerve grafting is a reconstructive procedure extensively described in the literature for the correction of different instances of nerve injury. Some variation can be observed in the technique, concerning materials utilized, choice of donor site, number of grafts used and specific characteristics of the injury to be treated. This range of technical possibilities depicts the ongoing pursuit of the ideal surgical method

and may explain the variability in the currently observed outcomes (Ricciardi et al., 2012; Spiliopoulos and Williams, 2011).

The sural nerve is the most commonly used source of donor nerve graft. This nerve can provide large tracts of grafts without significant morbidity. Other nerves are also used less frequently: the superficial branch of the radial nerve (upper limb), the medial cutaneous nerve of the forearm (upper limb), the greater auricular nerve (cervical), and the saphenous nerve (lower limb). What they have in common is that all are sensitive nerves and its removal causes only sensory deficits without motor alteration. The caliber of the obturator nerve is usually much larger than the sural nerve. The number of grafts has to be sufficient to occupy the whole area of the transected nerve and to allow the bulk of regenerating axons reaching the distal stump of the nerve. Thus, it is common to utilize the maximum possible grafts (Martins et al., 2013).

Case presentation

A 58 year-old woman was referred to the Sao Paulo State Cancer Institute with a histologically confirmed poorly differentiated endometrioid endometrial carcinoma. Pelvic examination did not provide any relevant additional information. A preoperative CT-scan showed no evidence of secondary lesions or enlarged retroperitoneal lymph nodes, therefore a video laparoscopy was indicated for total hysterectomy, bilateral salpingo-oophorectomy, pelvic and paraaortic lymphadenectomy. During the right iliac lymphadenectomy, an iatrogenic complete transection of the obturator nerve occurred and was immediately recognized.

The nerve was transected by the vessel sealing system. Because nerves consist mostly of connective tissue and not neural tissue, at the time of any section, the collagen and elastin present in the nerve cause a retraction of the divided ends, hindering primary anastomosis. At this moment, a neurosurgeon experienced in peripheral nerves was involved.

The laparoscopy was interrupted and converted to a laparotomy because the neurosurgeon who performed the correction of the lesion was more used to laparotomy, and reconstruction of the obturator nerve requires the use of delicate instruments and magnification by a microscope, which are difficult to achieve with laparoscopy.

After careful analysis of the characteristics of the lesion (mechanical total section plus thermal injury and presence of a considerable gap between the extremities), the neurosurgeon proceeded to a microsurgical repair of the nerve injury through the interposition of three sural nerve grafts (Figs. 1 to 3), because the epineural end to end tension free anastomosis was not possible.

* Corresponding author at: Rua Capote Valente, 432- conjunto 103, São Paulo- S.P.-Brazil.

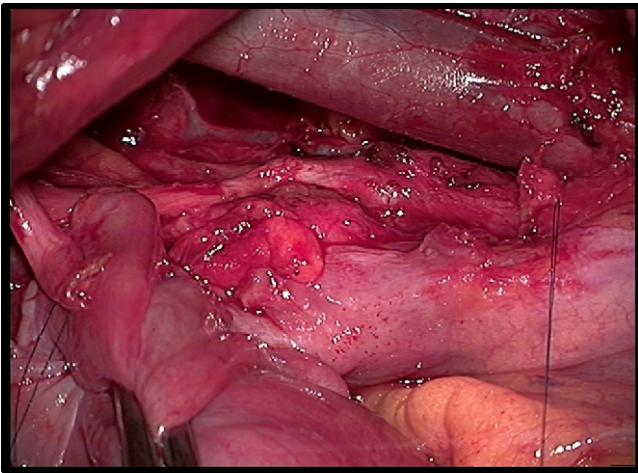


Fig. 1. Nerve injury. Surgical sutures show ends of the nerve stumps.

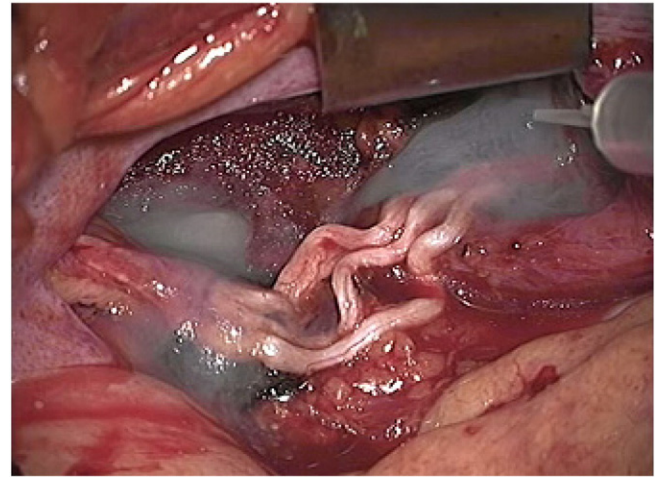
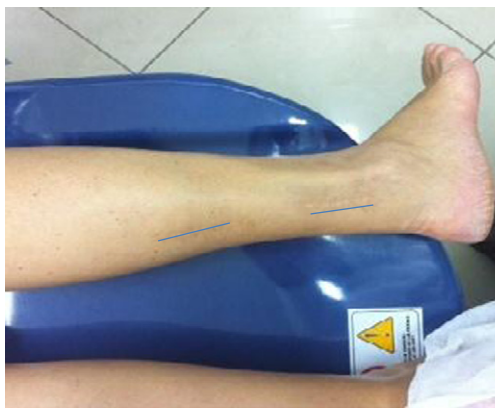

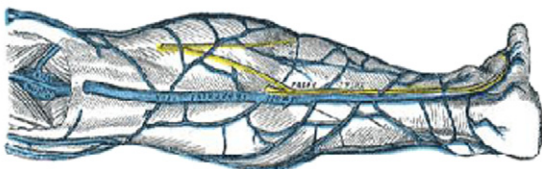
Fig. 3. Interposition of 3 sural nerve grafts.

To obtain a sample of the sural nerve, a continuous longitudinal incision was employed. It has started at the most distal portion of the incision, the ankle, where the sural nerve was located in the subcutaneous tissue between the lateral malleolus and the Achilles tendon. The saphenous vein was located immediately anterior to the nerve. Once identified, the nerve was dissected proximally. When the dissection approached the proximal third of the leg, it was necessary to open the fascia of the leg on the gastrocnemius and soleus muscles, to expose the nerve. At the end of the dissection, the nerve was transected at the distal end of the incision. Then, under magnification, the excess soft tissue (fascia and fat) adhering to the graft was removed while maintaining it in a saline solution (Martins et al., 2013).

After intense physiotherapy, the patient showed complete recovery of the adduction of the right leg, and electroneuromyography performed six months later showed clear signs of reinnervation of the adductor longus muscle.



A)



B)

Fig. 2. A. Picture of the leg with the blue lines showing the exact place where the sural nerve was removed. B. Schematic picture of the leg showing the sural nerve in yellow.

Discussion

The anatomy and function of the obturator nerve have been well studied, and are known to be occasionally damaged during extensive pelvic surgery, which most noticeably causes impairment of ipsilateral leg adduction. The obturator nerve arises from the second, third and fourth lumbar nerves. It traverses along the medial border of the psoas muscle, passes lateral to the hypogastric vessels and ureter, and follows along the lateral wall of the lesser pelvis until reaching the obturator foramen with the medially converging obturator vessels. Before emerging from the obturator canal, the nerve divides into anterior and posterior branches. These branches provide motor function to leg adductor muscles and sensory fiber to the hip joint, knee joint and the medial aspect of the middle and lower thirds of the thigh (Fishman et al., 1993; Kendir et al., 2008).

Ideally, a complete section of the obturator nerve should be immediately repaired, preferably using microsurgical techniques (Gürbüz et al., 2012). Although epineural end-to-end tension-free coaptation is currently considered the most efficient method to restore anatomy and function of the structure, in the present case the loss of neural substance led to the impossibility of a tension-free reattachment of the ends (Kavoussi et al., 1993). Consequently, the interposition of neural autologous grafts was necessary.

Prognosis of obturator nerve transection depends on the nature and the severity of the injury. However, patients with a repaired nerve transection usually develop complete resolution of the symptoms within one year after the incident (Hallgren et al., 2013).

In this case, the correction was performed by a neurosurgeon. If intraoperative evaluation by a neurosurgeon is not possible, the correction should be performed in a second operation. The postoperative fibrosis associated with a tissue retraction, makes the identification of the retracted stumps difficult. At the time of the injury and with unsuitable conditions to perform the repair, a way to try to avoid excessive shrinkage and to facilitate the subsequent identification of the stumps, can be obtained by passing a prolene suture of 5-0 or 6 between the epineurium (the tissue that surrounds the nerve) and a fixed structure of the region as a fascia. The repair should be performed as soon as possible (1–3 days after the injury) (Ghaemmaghami et al., 2009).

We performed the correction of the obturator nerve injury using the technique of sural nerve graft interposition.

The sural nerve receives sensory afferents from the lateral part of the foot, i.e. it is related to the sensitivity of this region. Their withdrawal is generally well tolerated by patients, with complications being rare (such as infection of the incision or dehiscence). The sensory loss is well tolerated and, over time, there is a progressive reduction of this loss (Ghaemmaghami et al., 2009).

This strategy may be considered when primary anastomosis is not possible.

Conflict of interest statement

All authors declare no conflict of interests.

References

- Benes, J., 1999. Immediate grafting of the damaged obturator nerve by gynaecological surgery. *Acta Neurochir. (Wien)* 141 (4), 435–438.
- Fishman, J.R., Moran, M.E., Carey, R.W., 2009. Obturator neuropathy after laparoscopic pelvic lymphadenectomy. *Urology* 42 (2), 198–200.
- Ghaemmaghami, F., Behnamfar, F., Saberi, H., 2009. Immediate grafting of transected obturator nerve during radical hysterectomy. *Int. J. Surg.* 7 (2), 168–169.
- Gürbüz, Y., Sügün, T.S., Özaksar, K., Kayalar, M., Toros, T., Ademoğlu, Y., 2012. Peroneal nerve injury surgical treatment results. *Acta Orthop. Traumatol. Turc.* 46 (6), 438–442.
- Hallgren, A., Björkman, A., Chemnitz, A., Dahlin, L.B., Sep 2013. Subjective outcome related to donor site morbidity after sural nerve graft harvesting: a survey in 41 patients. *BMC Surg.* 13, 39.
- Harma, M., Sel, G., Bektas, A., Ibrahim Harma, M., 2014. Successful obturator nerve repairing: intraoperative sural nerve graft harvesting in endometrium cancer patient. *Int. J. Surg. Case Rep.* 5, 345–346.
- Kavoussi, L.R., Sosa, E., Chandhoke, P., Chodak, G., Clayman, R.V., Hadley, H.R., Loughlin, K.R., Ruckle, H.C., Rukstalis, D., Schuessler, W., et al., 1993. Complications of laparoscopic pelvic lymph node dissection. *J. Urol.* 149 (2), 322–325 (Feb).
- Kendir, S., Akkaya, T., Comert, A., Sayin, M., Tatlisumak, E., Elhan, A., Tekdemir, I., 2008. The location of the obturator nerve: a three-dimensional description of the obturator canal. *Surg. Radiol. Anat.* 30 (6), 495–501 (Aug).
- Martins, R.S., Bastos, D., Siqueira, M.G., Heise, C.O., Teixeira, M.G., 2013. Traumatic injuries of peripheral nerves: a review with emphasis on surgical indication. *Arq. Neuropsiquiatr.* 71 (10), 811–814.
- Ricciardi, E., Jakimovska, M., Maniglio, P., Schimberni, M., Frega, A., Kobal, B., Moscarini, M., 2012. Laparoscopic injury of the obturator nerve during fertility-sparing procedure for cervical cancer. *World J. Surg. Oncol.* 10, 177.
- Rothmund, R., Huebner, M., Kraemer, B., Liske, B., Wallwiener, D., Taran, F.A., 2011. Laparoscopic transection and immediate repair of obturator nerve during pelvic lymphadenectomy. *J. Minim. Invasive Gynecol.* 18 (6), 807–808.
- Spiliopoulos, K., Williams, Z., 2011. Femoral branch to obturator nerve transfer for restoration of thigh adduction following iatrogenic injury. *J. Neurosurg.* 114 (6), 1529–1533 (Jun).
- Zhang, Z., Kou, Y., Yin, X., Wang, Y., Zhang, P., Jiang, B., 2013. The effect of a small gap sleeve suture at the distal anastomosis of a nerve graft on promoting nerve regeneration and functional recovery. *Artif. Cells Nanomed. Biotechnol.* 41 (4), 282–288 (Aug).